



Mediwheel
...Your wellness partner

Arcofemi Healthcare Pvt Ltd

(Formerly known as Arcofemi Healthcare Ltd)

F-701A, Lado Sarai, Mehrauli, New Delhi - 110030

Email: wellness@mediwheel.in, Website: www.mediwheel.in

Tel: +91-11-41195959, Fax: +91-11-29523020

CIN: U24240DL2011PTC216307

MEDICAL FITNESS CERTIFICATE

(To be signed by a registered medical practitioner holding a Medical degree)

This is to certify that **Mr. David Haokip** aged , 29yr. Based on the examination, I certify that he is in good mental and physical health and it is free from any physical defects such as deafness, color blindness, and any chronic or contagious diseases.

Place: Noida

Date: 25/06/2024

Dr. Nitesh Kumar

M.B.B.S
M.B.B.S
MR 47093

Name & Signature of

Medical officer

W - 56 kg

H - 158 cm

B.P - 101/75

P - 79% min

S - 98% min



भारत सरकार
Government of India



DAVID THANGGOU HAOKIP

Father : NGAMKHOLET

HAOKIP

DOB : 15/03/1995

Male



7228 5187 0204

भाषार = उम आदमी का अधिकार

David Thanggou Haokip

25-06-2024

Contact 6009567848



29 Years

Male

slm hospital
sector 63
Gautam Budhia Nagar, UP-201307

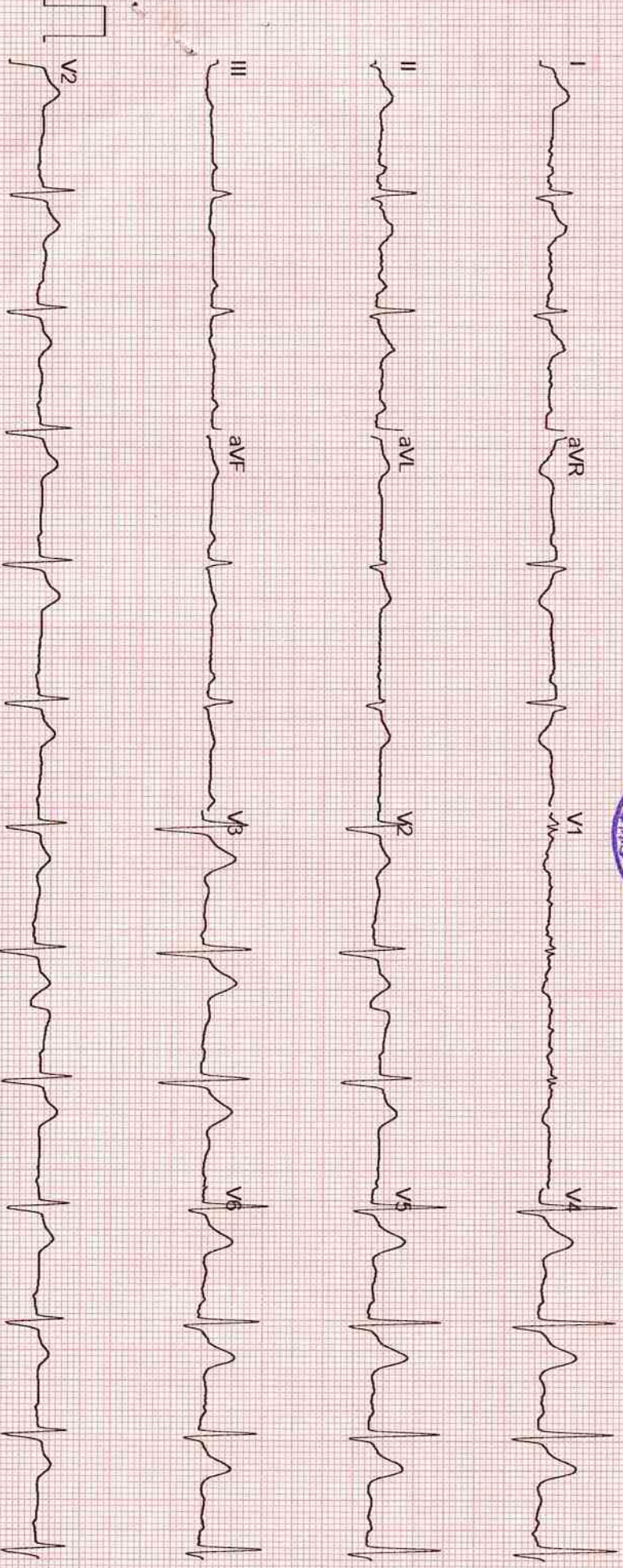
Room:
Order Number:
Indication:

Medication 1:
Medication 2:
Medication 3:

Technician:
Ordering Ph:
Referring Ph:
Attending Ph:

QRS : 92 ms
QT / QTcBaz : 394 / 434 ms
PR : 178 ms
P : 98 ms
RR / PP : 822 / 821 ms
P / QRS / T : 62 / 71 / 28 degrees

Normal sinus rhythm with sinus arrhythmia
Normal ECG





SJM SUPER SPECIALITY HOSPITAL

100 Bedded Super Speciality Hospital

Sector-63, Noida, NH-9, Near Hindon Bridge

Ph.: 0120-6530900 / 10, Mob.: +91 9599259072

E-mail: sjmhospital@yahoo.com / Website: sjmhospital.com

(24 Hours Emergency, NICU/ICU, Pharmacy & Ambulance Available)



(IVF SPECIALIST)

Dr. Pushpa Kaul (IVF)

M.B.B.S, MD(Obst. & Gynae)

Dr. Neha Zutshi (Embryologist)

OTHER SPECIALIST

Dr. Pushpa Kaul (IVF)

M.B.B.S, MD(Obst. & Gynae)

Dr. Smritee Virmani (Endoscopy)

MBBS, DGO, DNB, ICOG (Obst. & Gynae)

Dr. Vinod Bhat

M.B.B.S, MD (General Medicine)

Dr. Vineet Gupta, MS (ENT)

Dr. Naveen Gupta, MS (EYE)

Dr. Ashutosh Singh, MS (Urology)

Dr. Rahul Kaul (Spine Surgeon)

MBBS, MS, (Orthopaedic)

Dr. Jaideep Gambhir, M.D(Psychiatrist)

Consultant Psychiatry, Mob.: 8006888664

Dr. Monica Gambhir, MBBS

Family Therapist & Relationship Counsellor

Mob.: 8006888663

Dr. B.P. Gupta, MS (Surgeon)

Dr. Deepa Maheshwari

M.B.B.S., MD, FRM, (IVF Specialist)

Dr. Vivek Kumar Gupta

MBBS, MS (General Surgeon)

M.Ch. (Plastic Surgery)

Dr. Anand Kumar

MBBS, MD (Paediatrics)

Dr. Amit kumar Kothari

MBBS, MD (Medicine)

Dr. Amit Aggarwal

M.B.B.S., M.S. Ortho.

Facilities:

100 Beds. Private & Public wards

Inpatient & Outpatient - (OPD)Facilities

24-Hour ambulance and emergency

3 Operation theatres

Laparoscopic & Conventional Surgery

In vitro fertilization centre (IVF)

Intensive Care Unit. (ICU)

Neonatal ICUs (NICU)

Dental Clinic

Computerized pathology lab

Digital X-ray and ultrasound

Physiotherapy facilities

24-Hour Pharmacy

Cafeteria & Kitchen

Mr. David Thangyou Haokip.

Age - 29 male.

Mr David Thangyou Haokip

Age - 29 male.

No action compared physician
to monetary fit.



25/06/24.

CGHS & AYUSHMAN BHARAT

+ Not for medico legal purpose + No substitution of drugs allowed

Panels: Raksha TPA Pvt Ltd., Vipul Med Corp TPA Pvt Ltd., E-Meditek (TPA) Services Ltd., Medi-Assit India TPA Pvt Ltd, Park Mediclaim, Genins India TPA Pvt Ltd., Family Healthcare TPA Pvt Ltd., Medsave Healthcare TPA Pvt Ltd, Vidal Health Care TPA Pvt Ltd., MD India Healthcare, DHS TPA (India) Private Ltd., Medicate TPA Service (I) Pvt. Ltd., East West Assist TPA Pvt Ltd., United Healthcare Parekh TPA Pvt Ltd., Good Health TPA Services Ltd., Bajaj Allianz General Insurance Co. Ltd., IFFCO Tokio General Insurance Co. Ltd., IFFCO Tokio General Insurance Co. Ltd., Universal Insurance General Co. Ltd., TATA AIG General Insurance Co. Ltd., Cholamandalam General Insurance Co. Ltd., Liberty Videocon General Insurance Ltd., SBI General Insurance Co. Ltd., Kotak Mahindra General Insurance Co. Ltd., HDFC Standard Life Insurance Co. Ltd., The Orient Insurance Co. Ltd.(Corporate), National Insurance Co. Ltd.(Corporate), The New India Insurance Co. Ltd. (Corporate) United India Insurance Co Ltd. (Corporate)



SJM SUPER SPECIALITY HOSPITAL



100 Bedded Super Speciality Hospital
Sector-63, Noida, NH-9, Near Hindon Bridge
Ph.: 0120-6530900 / 10, Mob.: +91 9599259072

E-mail: sjmhospital@yahoo.com / Website: sjmhospital.com
(24 Hours Emergency, NICU/ICU, Pharmacy & Ambulance Available)

25/6/24

IVF SPECIALIST

- Dr. Pushpa Kaul (IVF)
- M.B.B.S, MD(Obst. & Gynae)
- Dr. Neha Zutshi (Embryologist)

OTHER SPECIALIST

- Dr. Pushpa Kaul (IVF)
- M.B.B.S, MD(Obst. & Gynae)
- Dr. Smritee Virmani (Endoscopy)
- MBBS, DGO, DNB, ICOG (Obst. & Gynae)
- Dr. Vinod Bhat
- M.B.B.S, MD (General Medicine)
- Dr. Vineet Gupta, MS (ENT)
- Dr. Naveen Gupta, MS (EYE)
- Dr. Ashutosh Singh, MS (Urology)
- Dr. Rahul Kaul (Spine Surgeon)
- MBBS, MS, (Orthopaedic)
- Dr Jaideep Gambhir, M.D(Psychiatrist)
- Consultant Psychiatry, Mob.: 8006888664
- Dr Monica Gambhir, MBBS
- Family Therapist & Relationship Counsellor
- Mob.: 8006888663
- Dr. B.P. Gupta, MS (Surgeon)
- Dr. Deepa Maheshwari
- M.B.B.S., MD, FRM, (IVF Specialist)
- Dr. Vivek Kumar Gupta
- MBBS, MS (General Surgeon)
- M.Ch. (Plastic Surgery)
- Dr. Anand Kumar
- MBBS, MD (Paediatrics)
- Dr. Amit kumar Kothari
- MBBS, MD (Medicine)
- Dr. Amit Aggarwal
- M.B.B.S., M.S. Ortho.

Facilities:

- 100 Beds. Private & Public wards
- Inpatient & Outpatient - (OPD)Facilities
- 24-Hour ambulance and emergency
- 3 Operation theatres
- Laposcopic & Conventional Surgery
- In vitro fertilization centre (IVF)
- Intensive Care Unit. (ICU)
- Neonatal ICUs (NICU)
- Dental Clinic
- Computerized pathology lab
- Digital X-ray and ultrasound
- Physiotherapy facilities
- 24-Hour Pharmacy
- Cafeteria & Kitchen

Mr. David (29/11)

— No complaint

WV 616
616
NB

Plan - 616
Ace - Plan - 616, NB

Blue cut lens
(for computer use only)

Wbx-Ds (CBs)
Eye Drops - 2/10 x 2mm



CGHS & AYUSHMAN BHARAT

+ Not for medico legal purpose + No substitution of drugs allowed

Panelists: Raksha TPA Pvt Ltd., Vipul Med Corp TPA Pvt Ltd., E-Meditek (TPA) Services Ltd., Medi-Assit India TPA Pvt Ltd., Park Mediclaim, Genins India TPA Pvt Ltd., Family Healthcare TPA Pvt Ltd., Medsave Healthcare TPA Pvt Ltd., Vidal Health Care TPA Pvt Ltd., MD India Healthcare, DHS TPA (India) Private Ltd., Medicate TPA Service (I) Pvt. Ltd., West Assist TPA Pvt Ltd., United Healthcare Parekh TPA Pvt Ltd., Good Health TPA Services Ltd., Bajaj Allianz Insurance Co. Ltd., IFFCO Tokio General Insurance Co. Ltd., IFFCO Tokio General Insurance Co. Ltd., Universal Insurance General Co. Ltd., TATA AIG Insurance Co. Ltd., Cholamandalam General Insurance Co. Ltd., Liberty Videocon General Insurance Ltd., SBI Insurance Co. Ltd., Kotak Mahindra General Insurance Co. Ltd., HDFC Standard Life Insurance Co. Ltd., The New India Insurance Co. Ltd. (Corporate), National Insurance Co. Ltd. (Corporate), The New India Insurance Co. Ltd. (Corporate), United India Insurance Co Ltd. (Corporate)

Laboratory Report

Lab Serial no. : LSHHI290135	Mr. No : 117262
Patient Name : Mr. DAVID THANGGOU HAOKIP	Reg. Date & Time : 25-Jun-2024 02:10 AM
Age / Sex : 29 Yrs / M	Sample Receive Date : 25-Jun-2024 03:18 PM
Referred by : Dr. SELF	Result Entry Date : 25-Jun-2024 07:41PM
Doctor Name : Dr. AMIT KOTHARI	Reporting Time : 25-Jun-2024 07:41 PM
OPD : OPD	

HAEMATOLOGY

results unit reference

CBC / COMPLETE BLOOD COUNT

HB (Haemoglobin)	14.5	gm/dL	12.0 - 17.0
TLC	5.6	Thousand/mm	4.0 - 11.0
DLC			
Neutrophil	67	%	40 - 70
Lymphocyte	23	%	20 - 40
Eosinophil	08	%	01 - 06
Monocyte	02	%	02 - 08
Basophil	00	%	00 - 01
R.B.C.	4.74	Thousand / UI	3.8 - 5.10
P.C.V	44.2	million/UI	00 - 40
M.C.V.	93.2	fL	78 - 100
M.C.H.	30.6	pg	27 - 31
M.C.H.C.	32.8	g/dl	32 - 36
Platelet Count	2.45	Lacs/cumm	1.5 - 4.5

INTERPRETATION:

To determine your general health status; to screen for, diagnose, or monitor any one of a variety of diseases and conditions that affect blood cells, such as anemia, infection, inflammation, bleeding disorder or cancer

technician :

Typed By : Mr. BIRJESH



Laboratory Report

Lab Serial no.	: LSHHI290135	Mr. No	: 117262
Patient Name	: Mr. DAVID THANGGOU HAOKIP	Reg. Date & Time	: 25-Jun-2024 02:10 AM
Age / Sex	: 29 Yrs / M	Sample Receive Date	: 25-Jun-2024 03:18 PM
Referred by	: Dr. SELF	Result Entry Date	: 25-Jun-2024 07:41PM
Doctor Name	: Dr. AMIT KOTHARI	Reporting Time	: 25-Jun-2024 07:41 PM
OPD	: OPD		

BIOCHEMISTRY

	results	unit	reference
BLOOD SUGAR (PP), Serum			
SUGAR PP	91.9	mg/dl	80 - 140

Comments:

Accurate measurement if glucose in body fluid is important in diagnosis and management of diabetes, hypoglycemia, adrenal dysfunction and various other conditions. High levels of serum glucose may be seen in case of diabetes mellitus, in patients receiving glucose containing fluids intravenously, during severe stress and in cerebrovascular accidents. Decreased levels of glucose can be due to insulin administration, as a result of insulinoma, inborn errors of carbohydrate metabolism or fasting.

METHOD:- GOD-POD METHOD, END POINT

BLOOD SUGAR F, Sodium Fluoride Pla

Blood Sugar (F)	75.3	mg/dl	70 - 110
-----------------	------	-------	----------

Comments:

Accurate measurement if glucose in body fluid is important in diagnosis and management of diabetes, hypoglycemia, adrenal dysfunction and various other conditions.

High levels of serum glucose may be seen in case of Diabetes mellitus, in patients receiving glucose containing fluids intravenously, during severe stress and in cerebrovascular accidents.

Decreased levels of glucose can be due to insulin administration, as a result of insulinoma, inborn errors of carbohydrate metabolism or fasting.

technician :

Typed By : Mr. BIRJESH






SJM SUPER SPECIALITY HOSPITAL

Sector-63, Noida, NH-9, Near Hindon Bridge
Tel.: 0120-6530900 / 10 Mob.: +91 9599259072
E-mail.: email@sjmhospital.com
Web.: www.sjmhospital.com



Laboratory Report

Lab Serial no. : LSHHI290135	Mr. No : 117262
Patient Name : Mr. DAVID THANGGOU HAOKIP	Reg. Date & Time : 25-Jun-2024 02:10 AM
Age / Sex : 29 Yrs / M	Sample Receive Date : 25-Jun-2024 03:18 PM
Referred by : Dr. SELF	Result Entry Date : 25-Jun-2024 07:41 PM
Doctor Name : Dr. AMIT KOTHARI	Reporting Time : 25-Jun-2024 07:41 PM
OPD : OPD	

HAEMATOTOLOGY

results	unit	reference
---------	------	-----------

ESR / ERYTHROCYTE SEDIMENTATION RATE

ESR (Erythrocyte Sedimentation Rate)	10	mm/1hr	00 - 22
--------------------------------------	----	--------	---------

Comments

The ESR is a simple non-specific screening test that indirectly measures the presence of inflammation in the body. It reflects the tendency of red blood cells to settle more rapidly in the face of some disease states, usually because of increases in plasma fibrinogen, immunoglobulins, and other acute-phase reaction proteins. Changes in red cell shape or numbers may also affect the ESR.

BIOCHEMISTRY

results	unit	reference
---------	------	-----------

CREATININE-SERUM

Serum Creatinine	0.82	mg/dl	0.7 - 1.3
------------------	------	-------	-----------

Comments:

A creatinine test is a measure of how well your kidneys are performing their job of filtering waste from your blood. Creatinine is a chemical compound left over from energy-producing processes in your muscles. Healthy kidneys filter creatinine out of the blood. Creatinine exits your body as a waste product in urine.


BUN / BLOOD UREA NITROGEN, Serum

BUN/ Blood Urea Nitrogen	8.83	mg/dL	7 - 18
--------------------------	------	-------	--------



technician :

Typed By : Mr. BIRJESH


Dr. Rajeev Goel
M.D. (Pathologist)
36548 (MCI)

Dr. Bupinder Zutshi
(M.B.B.S., MD)
Pathologist & Microbiologist

Dr. B.S.

Technician :
Typed By : Mr. BIRJESH



An enzyme found in the liver and other tissues. A high level of SGPT released into the blood may be a sign of liver damage, cancer, or other diseases. Also called alanine transerase and serum glutamate pyruvate transaminase.

Comments:

SGPT / ALT Serum
SGPT/ALT

17.9 IU/L
00 - 45

Comment:-
Bilirubin is a waste product that forms when the liver breaks down red blood cells. Bilirubin exits the body as bile in stool. High levels of bilirubin can cause jaundice - a condition in which the skin and whites of the eyes turn yellow - and may indicate liver damage.

Bilirubin- Total
Bilirubin- Direct
Bilirubin- Indirect

0.90 mg/dL
0.41 mg/dL
0.49 mg/dL
0.1 - 2.0
0.0 - 0.20
0.2 - 1.2

BILIRUBIN TOTAL / DIRECT / INDIRECT Serum

BIOCHEMISTRY

results unit reference

Lab Serial no. : LSHH290135
Patient Name : Mr. DAVID THANGOU HAOKIP
Age / Sex : 29 yrs / M
Referred by : Dr. SELF
Doctor Name : Dr. AMIT KOTHARI
OPD : OPD
Mr. No : 117262
Reg. Date & Time : 25-Jun-2024 02:10 AM
Sample Receive Date : 25-Jun-2024 03:18 PM
Result Entry Date : 25-Jun-2024 07:41PM
Reporting Time : 25-Jun-2024 07:41 PM

Laboratory Report

Sector-63, Noida, NH-9, Near Hindon Bridge
Tel.: 0120-6530900 / 10 Mob.: +91 9599259072
E-mail: email@sjmhospital.com
Web.: www.sjmhospital.com

SJM SUPER SPECIALITY HOSPITAL



SJM SUPER SPECIALITY HOSPITAL

Sector-63, Noida, NH-9, Near Hindon Bridge
 Tel.: 0120-6530900 / 10 Mob.: +91 9599259072
 E-mail.: email@sjmhospital.com
 Web.: www.sjmhospital.com

**Laboratory Report**

Lab Serial No. : LSHHI290135	Reg. No. : 117262
Patient Name : MR. DAVID THANGGOU HAOKIP	Reg. Date & Time : 25-Jun-2024 02:10 AM
Age/Sex : 29 Yrs /M	Sample Collection Date : 25-Jun-2024 03:18 PM
Referred By : SELF	Sample Receiving Date : 25-Jun-2024 03:18 PM
Doctor Name : Dr. AMIT KOTHARI	ReportingTime : 25-Jun-2024 07:41 PM
OPD/IPD : OPD	:

TEST NAME**VALUE**

ABO

"A"

Rh

POSITIVE

Comments:

Human red blood cell antigens can be divided into four groups A, B, AB AND O depending on the presence or absence of the corresponding antigens on the red blood cells. There are two glycoprotein A and B on the cell s surface that are responsible for the ABO types. Blood group is further classified as RH positive an RH negative.

Centre for Excellent Patient Care



Mr. BIRJESH

Rajeev
<http://rgcipac3/SJM/Design/Finanace/LabTextReport.aspx>

6/26/2024

Dr. Rajeev Goel
 M.D. (Pathologist)
 36548 (MCI)

Dr. Bupinder Zutshi
 (M.B.B.S., MD)
 Pathologist & Micrbiologist

Sector-63, Noida, NH-9, Near Hindon Bridge
Tel.: 0120-6530900 / 10 Mob.: +91 9599259072
E-mail.: email@sjmhospital.com
Web.: www.sjmhospital.com

Laboratory Report

Lab Serial No. : LSHHI290135 Reg. No. : 117262
Patient Name : MR. DAVID THANGGOU HAOKIP Reg. Date & Time : 25-Jun-2024 02:10 AM
Age/Sex : 29 Yrs /M Sample Collection Date : 25-Jun-2024 03:18 PM
Referred By : SELF Sample Receiving Date : 25-Jun-2024 03:18 PM
Doctor Name : Dr. AMIT KOTHARI ReportingTime : 25-Jun-2024 07:41 PM
OPD/IPD : OPD :

URINE EXAMINATION TEST

PHYSICAL EXAMINATION

Quantity: 20 ml
Color: Yellow
Transparency: clear

CHEMICAL EXAMINATION

Albumin: nil
Glucose: nil
PH: Acidic

MICROSCOPIC EXAMINATION

Pus cells: 1-2 /HPF
RBC's: nil
Crystals: nil
Epithelial cells: 0-1 /HPF
Others: nil

Note:-

A urinalysis is a test of your urine. It's used to detect and manage a wide range of disorders, such as urinary tract infections, kidney disease and diabetes. A urinalysis involves checking the appearance, concentration and content of urine.



Mr. BIRJESH

PATIENT ID	: 28534 OPD	X-Ray Report	PATIENT NAME	: MR. DAVID HAOKIP
AGE	: 029Y		SEX	: Male
REF. PHY.	:		STUDY DATE	: 25-Jun-2024

RADIOLOGY REPORT EXAM: X RAY CHEST

TECHNIQUE:

Frontal projections of the chest were obtained

FINDINGS:

Fibrosis without volume loss and distortion of the lung parenchyma in the left upper zone without calcification, without cavitation.

Opacity is seen in the left costophrenic angle with blunting of the costophrenic angle and blurring of the outlines of the hemidiaphragm with tracking along the chest wall with a concave inner margin. This is indicative of moderate and simple pleural effusion. Haziness is seen in the underlying lung adjacent to the area of pleural effusion, this is indicative of compressive atelectasis.

The right costophrenic angle appears normal.

The tracheal lucency is centrally placed.

The mediastinal and diaphragmatic outlines on the unaffected side appear normal.

The heart shadow is normal.

The bony thoracic cage and soft tissues are normal.

IMPRESSION:

- 1) The above findings are indicative of fibrosis in the left upper zone. This could be a sequel of a prior infection.
- 2) The above findings are indicative of moderate, simple pleural effusion to the left.

V.S. Sai Naren

Dr Sai Naren
Consultant Radiologist
MBBS, MD
Regn No: 2017/08/3835

Dr Sai Naren
25th Jun 2024

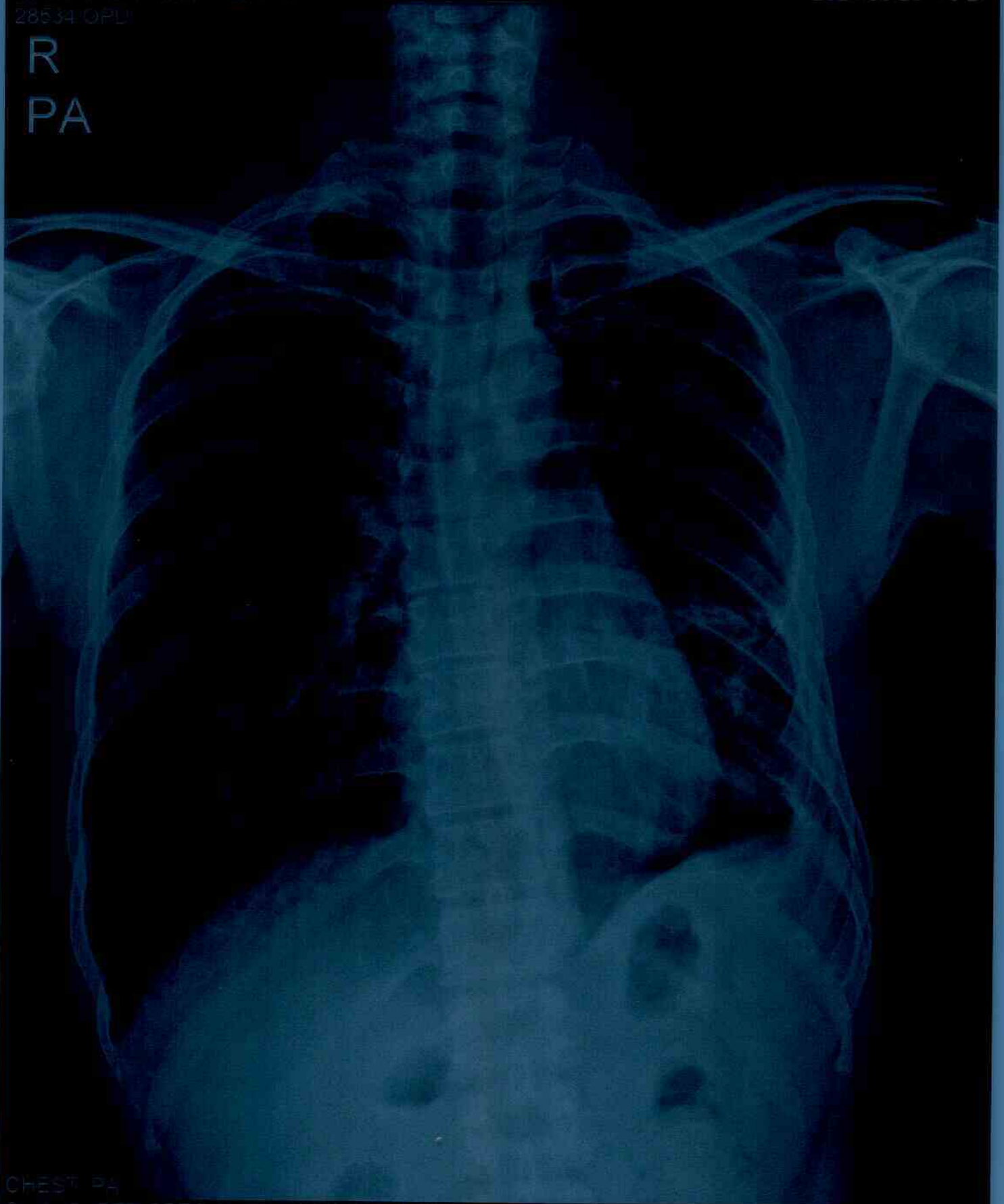Centre for Excellent Patient Care



MR. DAVID RAOK P. 29Y M
28534 DPL

2024.06.25 10:27

R
PA



CHEST PA
S. J. S. PERSPECTAL TV HOSPITAL NOIDA