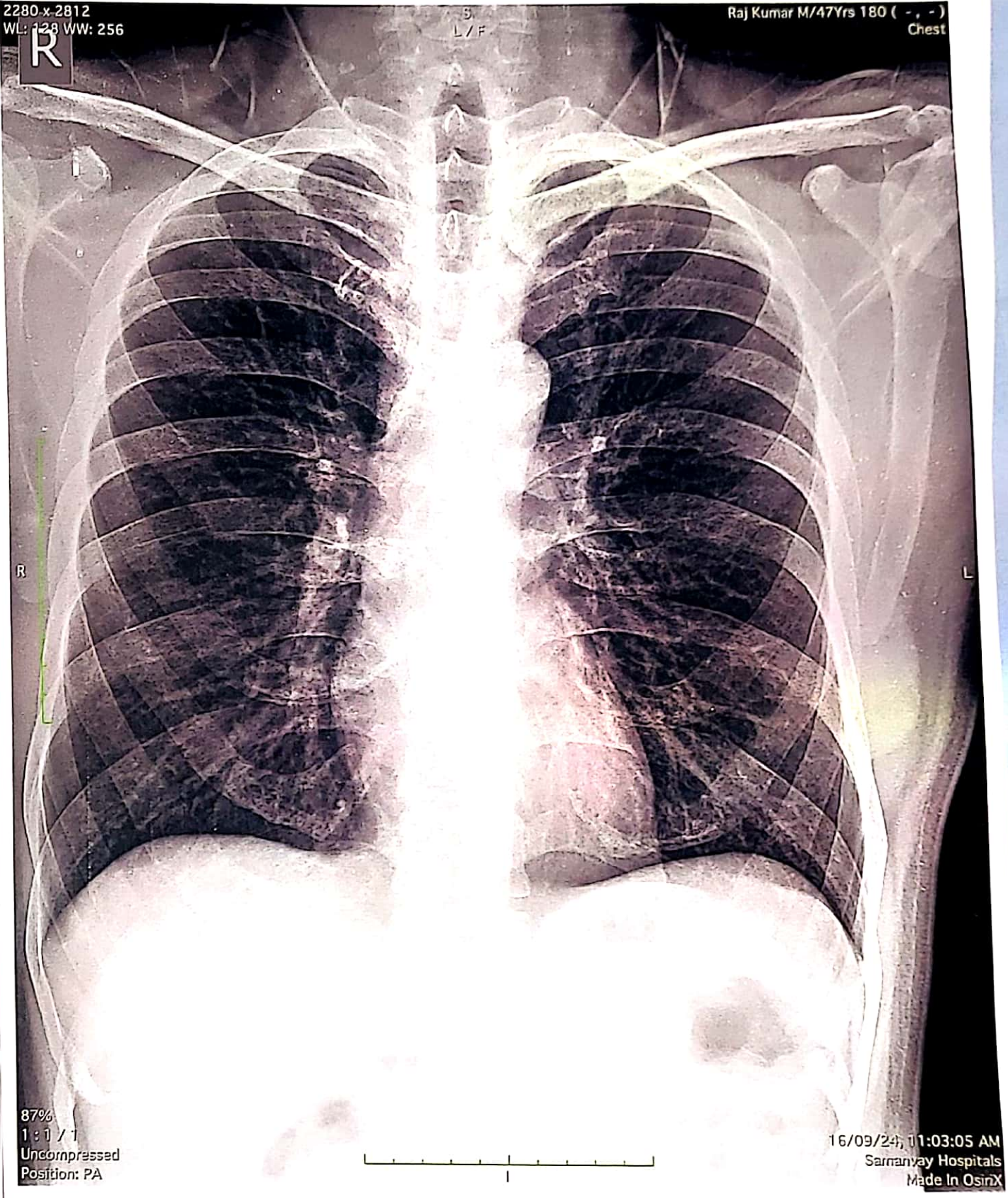


Raj Kumar m/47y

16-09-24

2280 x 2812  
WL: 128 WW: 256

Raj Kumar M/47Yrs 180 ( - , - )  
Chest



87%  
1:1/1  
Uncompressed  
Position: PA

16/09/24, 11:03:05 AM  
Sarnanay Hospitals  
Made In OsirX

Patient Name : MR. RAJ KUMAR      Bill No. : OPB/1/24/8275  
Age & Sex. : 47Y /M      Reg No. : REG-13060  
Bill date : 16/09/2024 11:54 AM      Sponsor : MEDIWHEEL

**X-RAY CHEST PA**

Both the lung fields appear normal.  
Both costophrenic angles appear clear.  
Cardiac silhouette appear normal.  
Both hila appears normal.  
Bony thorax appears normal.  
No evidence of free gas seen under dome of diaphragm.

**COMMENTS:**

- NORMAL BOTH LUNG FIELDS.
- NORMAL CARDIAC SIZE.

Impression :  
Conclusion :



**Dr. Sarjan Vasava**  
**Radiology**

(Reg No-G-26527)

**DR SARJAN VASAVA**  
M.B.B.S., D.M.R.D.  
Reg. No. G-26527  
**SAMANVAY HOSPITALS**



RAJ KUMAR

M / 47 YEARS

DATE: 16/09/2024

**REAL TIME SONOGRAPHY OF THE ABDOMEN & PELVIS**

**LIVER** - It is normal in size (13.4 cm). It shows normal echo pattern. No evidence of solid or cystic focal lesion is seen. The intrahepatic biliary system is normal and shows no dilatation of the radicles. The portal vein, CBD and hepatic veins appear normal.

**GALL BLADDER** - It is distended and appears normal. No evidence of sludge or calculus is seen. The wall appears normal.

**PANCREAS** - It is visualized and appears normal.

**SPLEEN** - It appears normal in size (8.1 cm), normal in shape and echotexture. No focal lesions.

**KIDNEYS** - . Both the kidneys appear normal in size, shape and show normal corticomedullary differentiation. Normal echogenicity of both kidneys.

Right kidney measures 8.4 X 4.5 cm. Left kidney measures 9.0 X 4.5 cm.

No calculus or hydronephrosis is seen on either side.

Urinary bladder is distended and appears normal. No cystitis or mass lesion noted.

Prostate appears normal in size vol - 23 cc. No focal lesion.

No evidence of any lymphadenopathy or ascites is noted.

No evidence of dilated bowel loops or bowel wall thickening noted.

**IMPRESSION:**

**NO SONOGRAPHIC ABNORMALITY IS DETECTED.**



**DR. SARJAN VASAVA,**  
CONSULTANT RADIOLOGIST.

**DR SARJAN VASAVA**  
M.B.B.S., D.M.R.D.  
Reg. No. G-26527  
SAMANVAY HOSPITALS



**2D ECHOCARDIOGRAPHY AND COLOUR DOPPLER STUDY**

NAME : MR.RAJKUMAR PRASAD

DATE :16 -09-24

AGE/SEX :46 YRS / M WARD:HCP REF BY : SAMANVAY HOSPITAL

**OBSERVATION:**

- NORMAL LV SIZE WITH NORMAL LV SYSTOLIC FUNCTION
- LVEF 56 %, NO RWMA AT REST
- MILD CONCENTRIC LVH
- E/O GRADE-II LV DIASTOLIC DYSFUNCTION, NORMAL LA SIZE
- AORTIC VALVE, NO AR, NO AS
- MITRAL VALVE, MILD MR , NO MS
- MILD TR, MILD PAH, RVSP 36 MMHG
- NORMAL SIZED RA, RV WITH NORMAL RV FUNCTION
- PULMONARY VALVE- NO PR, NO PS, NORMAL SIZED PA & ITS BRANCHES
- IAS, IVS ARE INTACT
- NO INTRACARDIAC CLOT, VEGETATION
- PERICARDIUM NORMAL, MILD PERICARDIAL EFFUSION
- IVC NORMAL ( 15 MM) AND >50% COLLAPSING

**CONCLUSION:**

NORMAL LV SIZE AND LV SYSTOLIC FUNCTION  
LVEF 56%, NO RWMA AT REST  
MILD CONCENTRIC LVH  
MILD MR, MILD TR, MILD PAH  
E/O GRADE II LV DIASTOLIC DYSFUNCTION



**DR. PAVAN ROY**  
MD, DM (CARDIOLOGY)  
CONSULTANT CARDIOLOGIST  
**DR. PAVAN ROY**  
REG. NO. 9305988158  
MD, DM (CARDIOLOGY) REG. NO G-23390  
CONSULTANT INTERVENTIONAL CARDIOLOGIST

Patient

Exam

ID 16092024-095613AM  
Name RAJ KUMAR M/47Y  
Birth Date  
Gender

Accession #  
Exam Date 16-09-2024  
Description  
Operator

