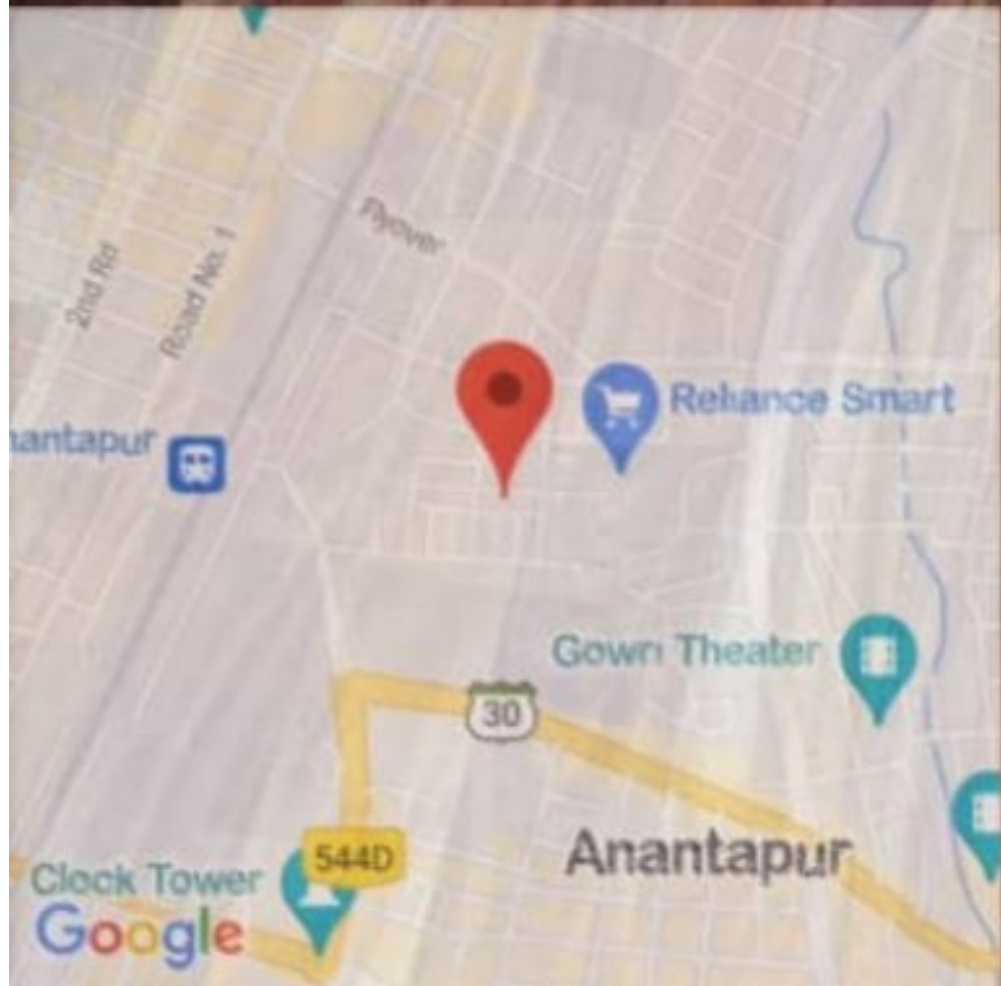

Apr 6, 2023 7:41:48 AM
279° W
Srinivas Nagar
Anantapur
Andhra Pradesh
Index number: 1589



ಭಾರತ ಸರ್ಕಾರ
Government of India

ಭಾರತೀಯ ವಿಶಿಷ್ಟ ಗುರುತು ಪ್ರಾಧಿಕಾರ
Unique Identification Authority of India

ನೋಂದಣಿ ಸಂಖ್ಯೆ / Enrolment No.: 0648/16719/03292

To
ಶ್ರೀ ರಾಜಿಶ
G Rajitha
C/O: Thulasidhar Reddy
#2-79
kalikivandlapalli
Ganthimarru
Ananthapuramu Andhra Pradesh - 515101
9618761518

Signature Not Verified
Digital Signature
OFFICIAL USE ONLY
NOT FOR REPRODUCTION
Date: 20/08/2015



ನಿಮ್ಮ ಆಧಾರ್ ಸಂಖ್ಯೆ / Your Aadhaar No. :

6553 8560 5329

VID : 9173 5325 7901 7040

ನನ್ನ ಆಧಾರ್, ನನ್ನ ಗುರುತು



ಭಾರತ ಸರ್ಕಾರ
Government of India



ಶ್ರೀ ರಾಜಿಶ
G Rajitha
ಜನನ ದಿನಾಂಕ/DOB: 20/08/1996
FEMALE

6553 8560 5329

VID : 9173 5325 7901 7040

ನನ್ನ ಆಧಾರ್, ನನ್ನ ಗುರುತು



Government of India



ಮಾಹಿತಿ

- ಆಧಾರ್ ಗುರುತಿನ ಪುರಾವೆಯೇ ಹೊರತು ವಾಸ್ತವದಲ್ಲಿ
- ಸುರಕ್ಷಿತ ಕ್ಯೂಆರ್ ಕೋಡ್/ಆಫ್ಲೈನ್ XML/ಆನ್ಲೈನ್ ದೃಢೀಕರಣ ಬಳಸಿ ಗುರುತನ್ನು ಪರಿಶೀಲಿಸಿ
- ಎಲೆಕ್ಟ್ರಾನಿಕ್ ಪ್ರಕ್ರಿಯೆ ಮೂಲಕ ಮುದ್ರಿತವಾದ ವಿದ್ಯುನ್ಮಾನ ದಾಖಲೆ ಇದಾಗಿದೆ

INFORMATION

- Aadhaar is a proof of identity, not of citizenship.
- Verify identity using Secure QR Code/ Offline XML/ Online Authentication.
- This is electronically generated letter.

- ಆಧಾರ್ ದೇಶದಾದ್ಯಂತ ಮಾನ್ಯತೆಯನ್ನು ಪಡೆದಿದೆ
- ಸುಲಭವಾಗಿ ಸರ್ಕಾರಿ ಹಾಗೂ ಸರ್ಕಾರೇತರ ಸೇವೆಗಳನ್ನು ಪಡೆಯಲು ಆಧಾರ್ ಸಹಾಯವಾಗಿದೆ.
- ನಿಮ್ಮ ಮೊಬೈಲ್ ಸಂಖ್ಯೆ ಮತ್ತು ಇ-ಮೇಲ್ ಐಡಿ ಅನ್ನು ಆಧಾರ್ ನಲ್ಲಿ ಸವಿಕರಿಸಿ
- ಆಧಾರ್ ನ್ನು ನಿಮ್ಮ ಸ್ಮಾರ್ಟ್ ಫೋನ್ ನಲ್ಲಿ ಕೊಂಡೊಯ್ಯಿರಿ- mAadhaar ಅಪ್ಲಿಕೇಶನ್ ಬಳಸಿ

- Aadhaar is valid throughout the country
- Aadhaar helps you avail various Government and non-Government services easily.
- Keep your mobile number & email ID updated in Aadhaar.
- Carry Aadhaar in your smart phone – use mAadhaar App.



ಭಾರತೀಯ ವಿಶಿಷ್ಟ ಗುರುತು ಪ್ರಾಧಿಕಾರ
Unique Identification Authority of India



ವಿಳಾಸ:
ಶ್ರೀ ರಾಜಿಶ್, ತುಳಸಿದರ್ ರೆಡ್ಡಿ #2-79,
ಕಾಲಿಕವಂದಲಪಲ್ಲಿ, ಗಂಥಿಮರ್ರು,
ಅನಂಥಪುರಮು,
ಆಂಧ್ರ ಪ್ರದೇಶ - 515101

Address:
C/O: Thulasidhar Reddy, #2-79,
kalikivandlapalli, Ganthimarru,
Ananthapuramu,
Andhra Pradesh - 515101



6553 8560 5329

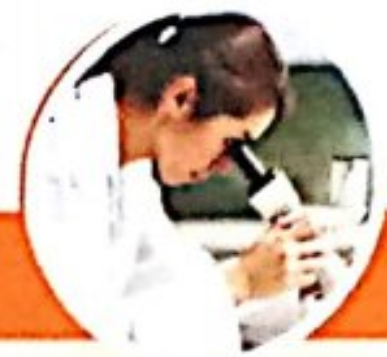VID : 9173 5325 7901 7040

1947 | help@uidai.gov.in | www.uidai.gov.in

G Rajitha



AMRUTHA SAI DIAGNOSTIC CENTRE



Cell: 868 898 4900, 9966 77 4621

email: amruthasailab@gmail.com

ISO.9001:2015 Certificate Number: Q91864141412

Name :- Mrs G Rajitha

Age/Sex :- 26 Y/Female

Date :- 06-04-2023

Ref.by :- Mediwheel (BOB)

ID.No:- D4/2023, BOBS 37478, , BC-75940

EMPLOYEE MEDICAL CHEK UP FORM

Physical Examination :-

Height :- 161 cms.

Weight :- 55 kgs.

Abdomen (CMS) : 82cms

Chest Expir(CMS):- 70

Chest Insp(CMS) : 75

Body mass index(BMI) :- 21.2

Pulse Rate :- 72 minute. (Regular / Abnormal)

Skin :- Normal Open Lesions :- N/C

Oral Hygeine : Heavy

Complaints if Any :- N/C

Family History :- H/C

Complaints if Any :- H/C

Systemic Examination (Abnormality - if Yes Please Explain) :-

CVS - Yes / No

CNS - Yes/ No

Gi Tract - Yes/No

Abdomen - Yes/ No

Respiratory Tract - Yes/ No

INVESTIGATIONS : (N= Normal, R= See Report)

Complete Blood Picture With ESR = Normal

Complete Urine Examination = Normal

FBS, PLBS = Normal

Colour Vision = Normal

USG = Normal

Chest X-Ray = Normal

* ECG = Normal

* SGPT = Normal

* Cholesterol = Normal

* Eye&ENT Examination = Normal

* 2D ECHO = Normal

Diagnosis (If Any) :- N/C

RECOMMENDATIONS / IMPRESION :- N/C

Dr. V. Narayanappa
M.B.B.S,FCGP.
PHYSICIAN SIGNATURE
PHYSICIAN & SURGEON
Regd.No. 88543
Authorised Doctor,
For State Bank of India
ANANTAPUR.

Under AP Govt. Regd. Diagnostic Centre R.No.98/2012-2013

Genuineness is our gene



2D ECHOCARDIOGRAM- COLOUR DOPPLER STUDY

NAME:-MRS.C.RAJITHA	AGE/GENDER 26Y/FEMALE	DATE:06/04/2023
REFERRED BY:-	MRNO:-2302821	OP/IP NO:-
ECHO DONE BY:- DR.R.KATYAYINI	S.NO:-	TAPE NO:-

MITRAL VALVE :- NORMAL
AORTIC VALVE :- NORMAL
TRICUSPID VALVE :- NORMAL
PULMONARY VALVE :- NORMAL
RIGHT ATRIUM :- NORMAL
RIGHT VENTRICLE :- NORMAL
LEFT ATRIUM :-2.9 cm
LEFT VENTRICLE : NO LV RWMA
*EDD :- 4.2 cm IVSD :- 0.9 cm EF:- 61 %
*ESD :- 2.9 cm PWD :- 1.0 cm FS:- 31 %
*EDV :- MI ESV :- MI EF:- %
IAS :- INTACT
IVS :- INTACT
AORTA :-2.7 cm
PULMONARY ARTERY :- NORMAL
PERICARDIUM :-NO
INTRACARDIAC MASSES :-NO
IVC/SVC/CS :- NORMAL
PULMONARY VEINS :- NORMAL
OTHERS :-

COLOUR FLOW MAPPING & DOPPLER MR:-1+ AR:-NO TR:- 1+ PR:- NO

DOPPLER

MITRAL :- E= 1.0 m/sec A= 0.6 m/sec EDT= ms
TDI :- E/E'- A':-
AORTA :- VMAX = 1.3 m/sec
PULMONARY :- VMAX = 0.9 m/sec
TRICUSPID :- RVSP mmHg
OTHERS :-NO COARCTATION OF AORTA

ECHO DIAGNOSIS

- 1 NORMAL VALVES & CHAMBERS
- 2 NO LV RWMA
- 3 TRIVIAL MR/TR, NO PAH
- 4 NORMAL LV SYSTOLIC FUNCTION (EF: 61%)
- 5 NORMAL RV FUNCTION
- 6 NO PE/CLOT/ CO-A/VEGETATION

Dr. R. KATYAYINI
MBBS., MD(Gen Med), DrNB(Cardiology)
Consultant Interventional Cardiologist
APMC Reg.No:77567

CONSULTANT CARDIOLOGIST

#13-2-392-4, Care & Cure Circle, NTR Marg, Near RTC Bus-Stand, Ananthapuramu - 515001.
Ph:08554 - 220555, 278999 Cell: 74166 84286, e-mail: careandcureatp@gmail.com website:www.careandcurehospitals.com

1st Cross, Sai Nagar,
Near Surya Nagar Bus Stop,
ANANTAPURAMU - 515001.
Contact : +91 79893 30974



VASUNDHARA
DIAGNOSTICS
FETAL MEDICINE CENTRE

Patient Name : Mrs. C.Rajitha

Patient Id : 230406-021

Gender/Age : Female / 26 Y

Referred By : Amrutha Sai diagnostic center

Reg Date : 06-04-2023

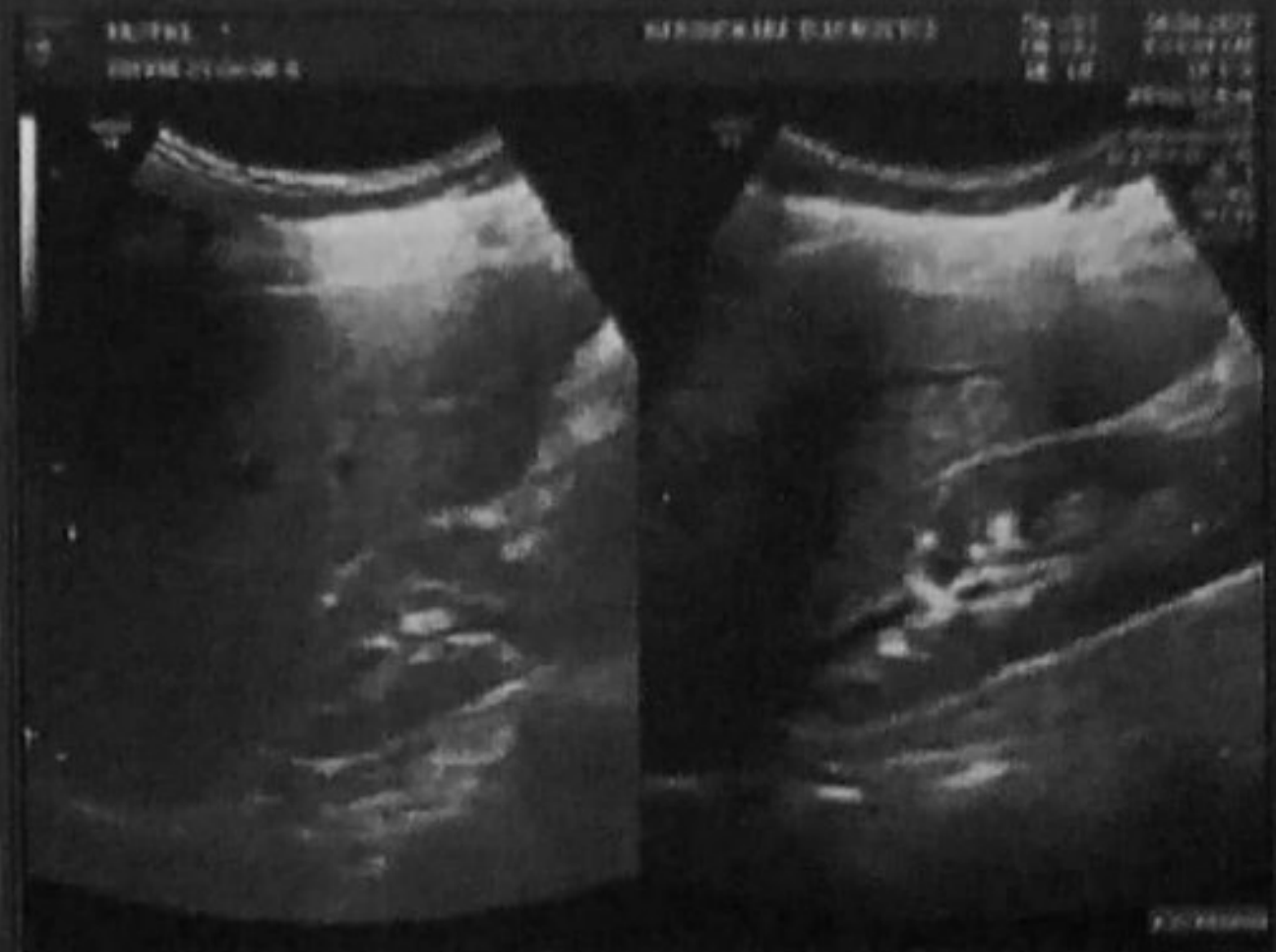
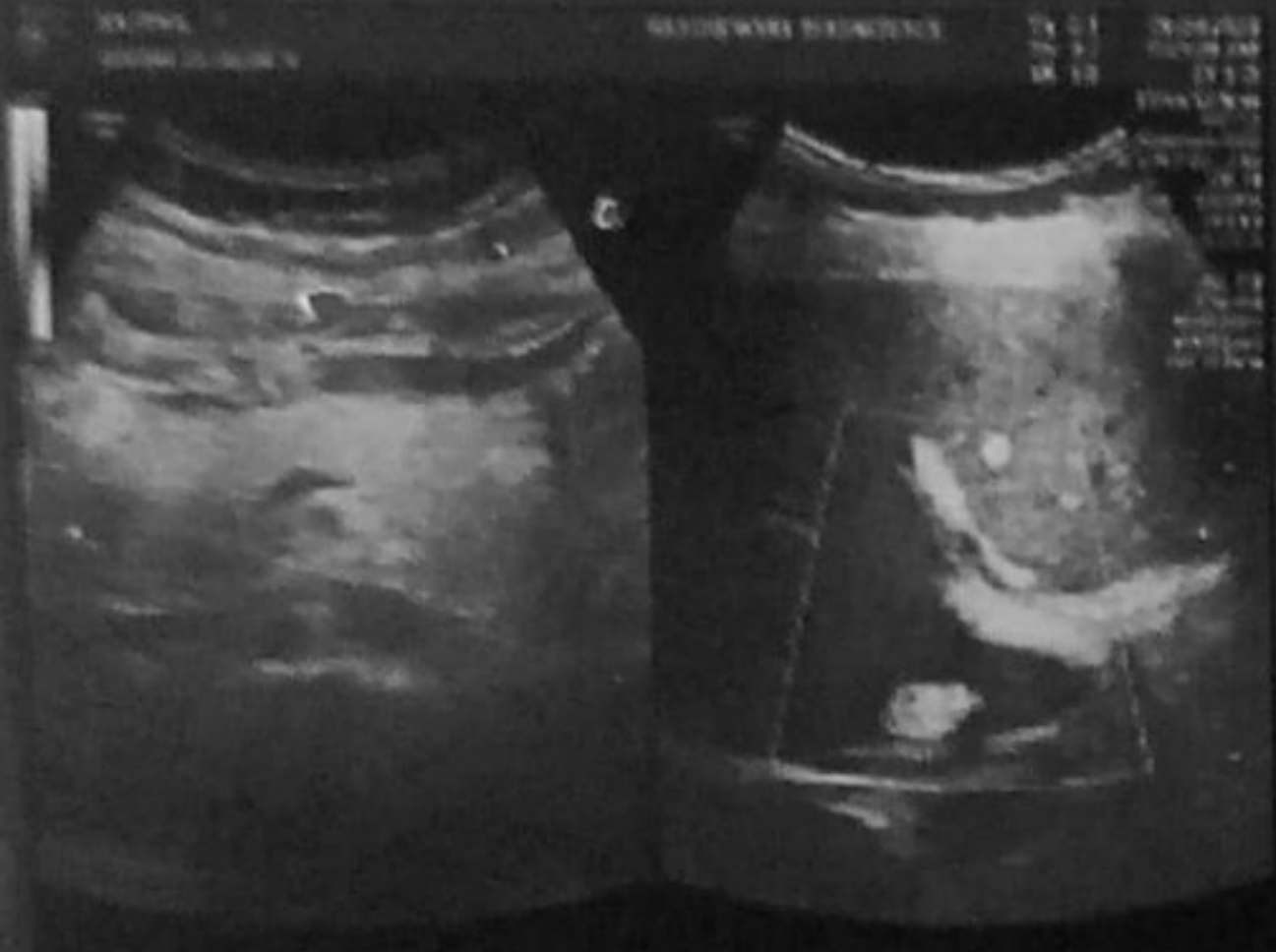ULTRASONOGRAPHY OF WHOLE ABDOMEN

- Liver** : Normal in size(12.5 cm) with normal echotexture.
No focal lesions or dilated biliary radicles.
No IHBD / CBD dilatation. Portal vein is normal.
- Gall bladder** : Well distended . No calculi .No wall thickening.
- CBD** : Normal in course and calibre .Lumen echo free.
- Portal vein** : Normal in size and course. Lumen echo free .
- Spleen** : Normal in size(8 cm) with normal echotexture. No focal lesions.
- Pancreas** : Head, body, visualized parts of tail are normal. No focal lesions
or peripancreatic collections are seen.
- Kidneys** : Right kidney: 9.0x4.0 cm, Left kidney: 9.5 x 4.5 cm.
Normal in size, shape and echotexture.Corticomedullary junction is made out.
No calculi or hydronephrosis on both sides.
- Urinary bladder** : Well distended. No calculi are seen.
- Uterus** : Anteverted ,normal in size measuring 7.1x2.6x3.9 cm and normal in echotexture
No focal lesions. Cervix measuring 2 cm.
Endometrial thickness measuring 7 mm.IUCD in situ in uterus
- Ovaries** : Right ovary measuring 2.2x1.7 cm
Left ovary measuring 2.2x3.2 cm.
No focal lesions .No adnexal lesions .
- Others** : No evidence of ascites .Appendix not seen due to bowel gas.
No evidence of lymph node enlargement. No obvious inflammed bowel seen.
- Impression** : Normal Study.

For clinical correlation please...

Dr.N.Vasundhara
MD Radiology
Consultant in fetal medicine

G. Rajitha

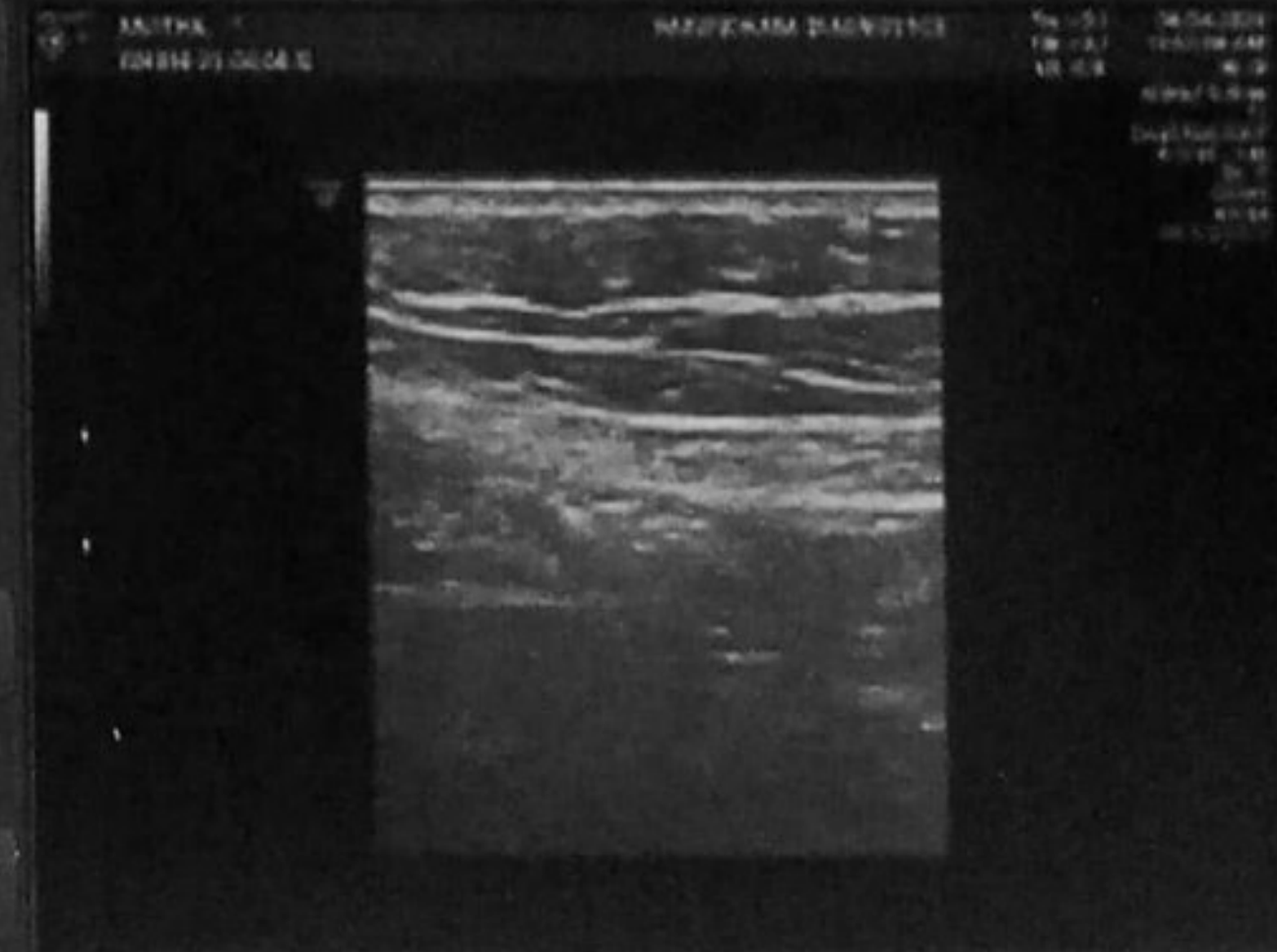
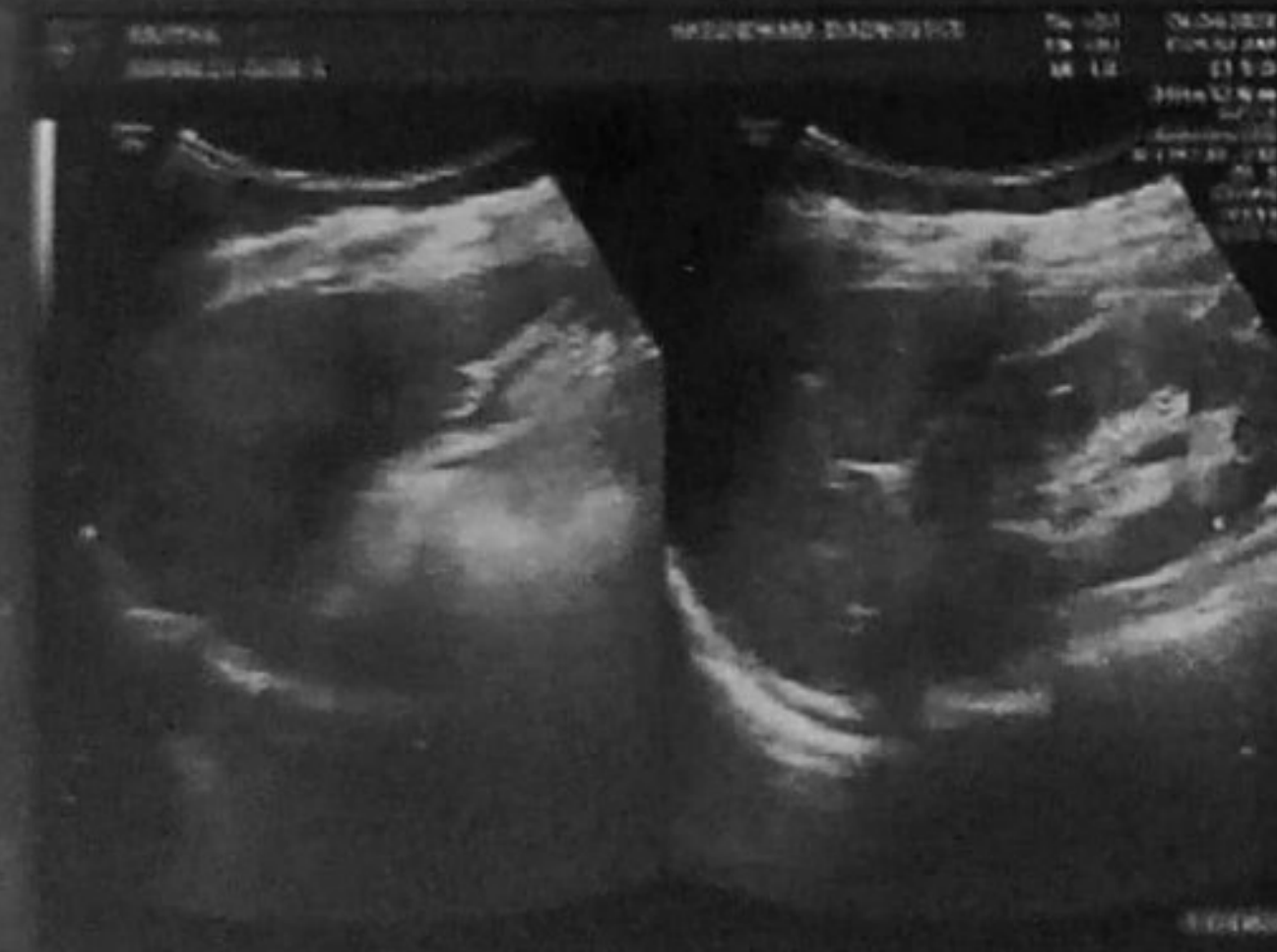

Reload Full Data

HDF

Reload Full Data

2D



Reload Full Data

2D

Reload Full Data

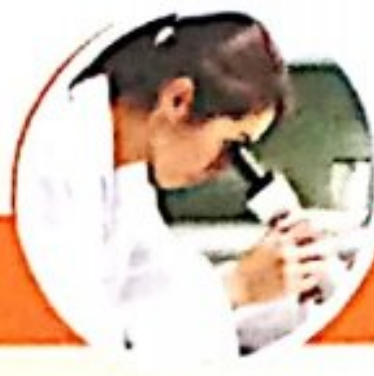2D

- Select All
- De-select All
- Freeze
- Unfreeze
- Next Frame
- Previous Frame
- Next Frame
- Previous Frame





AMRUTHA SAI DIAGNOSTIC CENTRE



Cell: 868 898 4900, 9966 77 4621

email: amruthasailab@gmail.com

ISO.9001:2015 Certificate Number: Q91864141412

Patient Name : Mrs G Rajitha

Sex: Female

Age : 26 Yrs

Id.No : 04/23

Bill Date : 06-04-2023

Report Date : 06-04-2023

Ref. by : BOB Mediwheel Check up

Address : A T P

LAB REPORT

Blood For :-

Parameter	Findings	Reference Range
Complete Haemogram (CBP) :-		
Haemoglobin % (C M G)	: 10.3 gm %	F : 11.0- 16.0 gms %
Total WBC Count	: 5600 ce/cu mm	A : 4000 – 11000 ce/cu mm
Differential WBC Count	: Neutrophils – 52 % Lymphocytes – 38 % Eosinophils – 06 % Monocytes – 04 % Basophils – 00 %	45 – 65 % 25 – 45 % 01 – 06 % 02 – 08 % 00 – 01 %
E S R (Westergren Method)	: 30 mm/ 1 hr	F : 02 - 20 mm/ 1.hr
RBC Count	: 3.1 mill/cu mm	F : 3.5 – 5.5 mill/cu mm
Platelet Count	: 2.7 Lach/cu mm	1.5 – 4.0 Lach/cu mm
Packed Cell Volume (PCV)	: 34.3 %	F : 36 – 47 %
Mean Corpuscular Volume (MCV)	: 82.5 fl	82 – 92 fl
Mean Corpuscular Haemoglobin (MCH)	: 28.3 pg	27 – 32 pg
Mean Corpuscular Haemoglobin Concentration (MCHC)	: 32.4 %	32 – 36 %

TEST NAME	METHOD	VALUE	UNITS
GLYCOSYLATED HAEMOGLOBIN (Hb A1 c) %	TURBIDOMETRY	5.66	%

Reference Range :-

BELOW 6.0 %	- NORMAL VALUE
6.0 % - 7.0 %	- GOOD CONTROL
7.0 % - 8.0 %	- FAIR CONTROL
8.0 % - 10.0 %	- UNSATISFACTORY CONTROL
ABOVE 10.0 %	- POOR CONTROL

@ Suggested clinical Correlation, If there is need, kindly discuss.

LAB INCHARGE

S. Vijaya Lakshmi
M.Sc (Biochemistry)

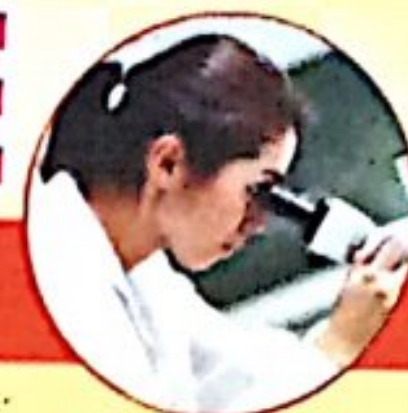Under AP Govt. Regd. Diagnostic Centre R.No.98/2012-2013

Genuineness is our gene



AMRUTHA SAI DIAGNOSTIC CENTRE

Cell : 868 898 4900, 9966 77 4621



email : amruthasailab@gmail.com

ISO.9001 : 2015 Certificate Number : Q91864141412

Patient Name : Mrs G Rajitha

Sex: Female

Age : 26 Yrs

Id.No : 04/23

Bill Date : 06-04-2023

Report Date : 06-04-2023

Ref. by : BOB Mediwheel Check up

Address : A T P

LAB REPORT

Blood For :-

Parameter	Findings	Reference Range
LIPID PROFILE :-		
Cholesterol Total	: 175 mg/dl	150 - 260 mg/dl
H D L Cholesterol	: 40 mg/dl	F : 45 - 65 mg/dl
L D L Cholesterol	: 92 mg/dl	66 - 178 mg/dl
V L D L Cholesterol	: 37 mg/dl	5 - 40 mg/dl
Triglycerides	: 175 mg/dl	36 - 165 mg/dl
CHOL : HDL Chole	: 4.1 : 1	3.0 - 5.0 : 1
Fasting Blood Sugar	: 72 mg/dl	65 - 110 mg/dl
Post Prandial Blood Sugar	: 132 mg/dl	80 - 160 mg/dl
Renal Function Test (RFT) :-		
B U N	: 10 mg/dl	7 - 18 mg/dl
Serum Creatinine	: 1.0 mg/dl	0.7 - 1.4 mg/dl
Serum Uric Acid	: 4.9 mg/dl	3.0 - 5.7 mg/dl
Serum Calcium	: 8.2 mg/dl	8.7 - 10.4 mg/dl
LIVER FUNCTION TEST (LFT) :-		
Bilirubin Total	: 0.5 mg/dl	0.1 - 1.0 mg/dl
Bilirubin Direct	: 0.11 mg/dl	0.0 - 0.25 mg/dl
Bilirubin Indirect	: 0.4 mg/dl	0.2 - 0.8 mg/dl
Total Proteins	: 6.9 gm/dl	6.0 - 8.0 gm/dl
Albumin	: 4.1 gm/dl	3.7 - 5.3 gm/dl
Globulins	: 2.7 gm/dl	2.5 - 4.5 gm/dl
A / G Ratio	: 1.6 : 1	1.2 - 2.5 : 1
S G O T (A S T)	: 28 IU/L	Upto - 40 IU/L
S G P T (A L T)	: 32 IU/L	Upto - 47 IU/L
Alkaline Phosphatase (ALP)	: 175 IU/L	A : 100 - 290 IU/L
Gamma Glutamyl Transferase (GGT)	: 28 IU/L	F : Upto - 30 IU/L

@ Suggested clinical Correlation, If there is need, kindly discuss.

LAB INCHARGE
S. Vijaya Lakshmi
M.Sc (Biochemistry)

Under AP Govt. Regd. Diagnostic Centre R.No. 98/2012-2013

Genuineness is our gene



AMRUTHA SAI DIAGNOSTIC CENTRE

Cell : 868 898 4900, 9966 77 4621



email : amruthasailab@gmail.com

ISO.9001 : 2015 Certificate Number : Q91864141412

Patient Name : Mrs G Rajitha

Sex: Female

Age : 26 Yrs

Id.No : 04/23

Bill Date : 06-04-2023

Report Date : 06-04-2023

Ref. by : BOB Mediwheel Check up

Address : A T P

LAB REPORT

Complete Urine Analysis(C U A) :-

Physical Examination :-

Colour	: Yellow	Transparency	: Clear
Reaction	: Acidic	Sediment	: NIL
Sp.Gravity	: 1.010	pH	: 6.0

Chemical Examination :-

Sugar	: Absent	Proteins	: Absent
Bile Salts	: Absent	Bile Pigments	: Absent
Urobilinogen	: Normal	Ketone Bodies	: Negative
Blood	: Absent		

Microscopic Examination :-

Pus Cells	: 2 - 3 /hpf	E.P.Cells	: 4 - 5 /HPF
RBC's	: Absent	Casts	: Absent
Crystals	: Absent	Deposits	: Absent
Bacteria	: Absent		

@ Suggested clinical Correlation, If there is need, kindly discuss.

Note:- Amrutha Sai Diagnostic Centre . (Fully Automated A/C Laboratory)
***** Since - 25 Years *****

Opp.Balaji Kalyana Mantapam, Near RTC Bus Stand, Reliance Mart Road,
Srenivasa Nagar, ANANTHAPURAM. CELL - 86 88 984900.

S. Vijaya Lakshmi
LAB INCHARGE
M.Sc (Biochemistry)

Under AP Govt. Regd. Diagnostic Centre R.No.98/2012-2013

Genuineness is our gene



AMRUTHA SAI DIAGNOSTIC CENTRE

Cell : 868 898 4900, 9966 77 4621

email : amruthasailab@gmail.com

ISO.9001 : 2015 Certificate Number : Q91864141412



Patient Name : Mrs G Rajitha

Sex: Female

Age : 26 Yrs

Id.No : 04/23

Bill Date : 06-04-2023

Report Date : 06-04-2023

Ref. by : BOB Mediwheel Check up

Address : A T P

XRAY-CHEST (PA) VIEW

- Trachea is central
- Both th lung fields appear normal.
- Hilar shadows are with in normal limits.
- Pulmonary vasculatures are normal.
- Cardia is normal in size.
- Both domes of the diaphragm are smooth.
- Both costophrenic recesses are clear.
- Visualized bones and soft tissue shows appear normal.

IMPRESSION :- NORMAL X-RAY.

Dr. K. RADHARANI, MD
Specialist in Ultra Sound
Diagnosis & C.T. Scan
Assoc. Civil Surgeon
Govt. Medical College &
General Hospital
ANANTHAPUR

@ Suggested clinical Correlation, If there is need, kindly discuss.

Note:- Amrutha Sai Diagnostic Centre . (Fully Automated A/C Laboratory)

***** Since - 25 Years *****

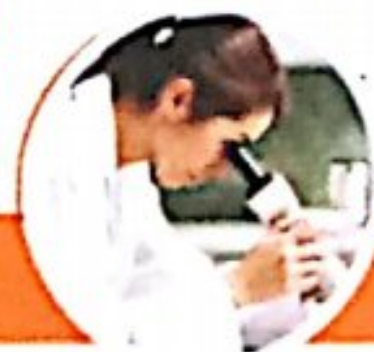Opp. Balaji Kalyana Mantapam, Near RTC Bus Stand, Reliance Mart Road,
Srenivasa Nagar, ANANTHAPURAM. CELL - 86 88 984900.

Under AP Govt. Regd. Diagnostic Centre R.No.98/2012-2013

Genuineness is our gene



AMRUTHA SAI DIAGNOSTIC CENTRE



Cell: 868 898 4900, 9966 77 4621

email: amruthasailab@gmail.com

ISO.9001:2015 Certificate Number: Q91864141412

Name : Mrs. G RAJITHA
Age/Gender : 26 Years / Female
Ref.By : BOB HEALTH CHECK UP
Req No. : SMN2335135
Sample Type : Serum
Client Name : AMRUTHA SAI LAB

Vial ID : 383559
Collected On : 06-Apr-2023 08:18 AM
Registered On : 06-Apr-2023 10:11 AM
Reported On : 06-Apr-2023 12:25 PM
Client Code : CMLAPF10

THYROID PANEL-I

Test Name	Observed Values	Units	Biological Reference Intervals
* TOTAL TRIIODOTHYRONINE (T3) Method:ECLIA	1.75	ng/mL	0.82 - 2.0
* TOTAL THYROXINE (T4) Method:ECLIA	8.23	ug/dl	5.1 - 14.1
* THYROID STIMULATING HORMONE (TSH) Method:ECLIA	3.76	µIU/mL	Adult : 0.35 – 5.5

Pregnancy:

1 st trimester: 0.3- 4.5

2 nd trimester: 0.5- 4.6

3 rd trimester: 0.8- 5.2

INTREPRATATION:

The determination of T3 is utilized in the diagnosis of T3hyperthyroidism, the detection of early stages of hyperthyroidism and for indicating a diagnosis of thyrotoxicosis factitia.

The determination of T4 can be utilized for the following indications: the detection of hyperthyroidism, the detection of primary and secondary hypothyroidism, and the monitoring of TSH-suppression therapy.

The determination of TSH serves as the initial test in thyroid diagnostics. Even very slight changes in the concentrations of the free thyroid hormones bring about much greater opposite changes in the TSH level. Accordingly, TSH is a very sensitive and specific parameter for assessing thyroid function and is particularly suitable for early detection or exclusion of disorders in the central regulating circuit between the hypothalamus, pituitary and thyroid.

U Mehatha.M.Sc
BIOCHEMIST

Dr. Tamkinath Fatima, MD
CONSULTANT BIOCHEMIST

----- End Of The Report -----



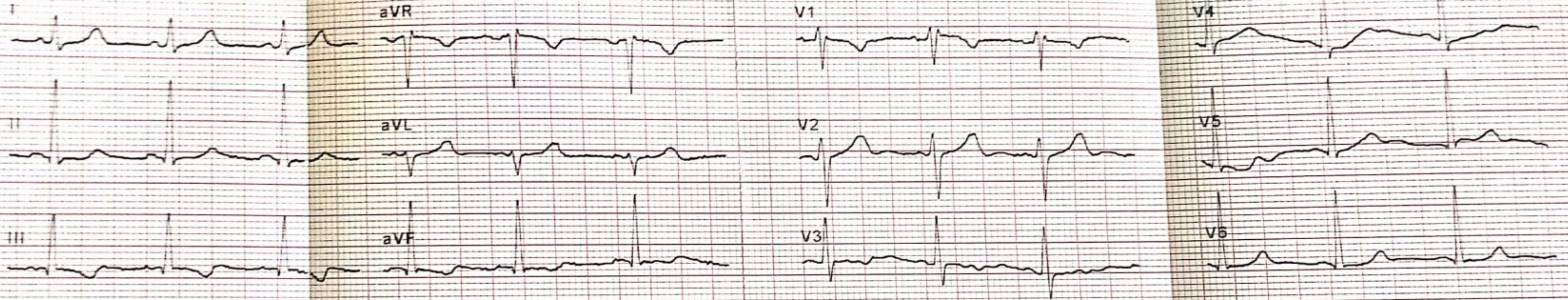
Please Correlate With Clinical Findings If Necessary Discuss This is an Electronically Authenticated Report

Under AP Govt. Regd. Diagnostic Centre R.No.98/2012-2013

Genuineness is our gene

HR 84 /bpm

06.04.2023 07:22:18



25 mm/s, 10 mm/mV

LP 25 Hz, AC 50 Hz

Sequential

Lead reversal

AT-1 G2 (1070.006301). 1.2.1

SCHILLER Part No. 2.157044M © 0123

SCHILLER Part No. 2.157044M © 0123

SCHILLER Part No. 2.157044M © 0123 N.88

SCHILLER Part No. 2.157044M © 0123

06.04.2023 07:22:18

Abnormal ECG

- Sinus rhythm
- Normal electrical axis
- T abnormality (inversion).
- T abnormality in inferior leads

Unconfirmed report

Mrs. G. Rajitha
26/8/2023
Dental Officer

Dr. V. Narayanappa,
M.B.B.S, FCGP.
PHYSICIAN & SURGEON
Regd. No. 88543
Authorised Doctor,
For State Bank of India
ANANTAPUR.

HR 84 /bpm

RR	716 ms	P axis	50°
P	82 ms	QRS axis	68°
PR	106 ms	T axis	0°
QRS	84 ms		
QT	372 ms		
QTc	440 ms		
(Bazett)			
Sokolow	2.41 mV		
Cornell	0.56 mV		
Lewis	-0.70 mV		
Romhilt			

06.04.2023 07:22:18

Name

Patient ID

Date of Birth

Gender

Pacemaker

Height cm

Weight kg

BP / mmHg

Medication

Remark

AT-1 G2 (1070.006301). 1.2.1

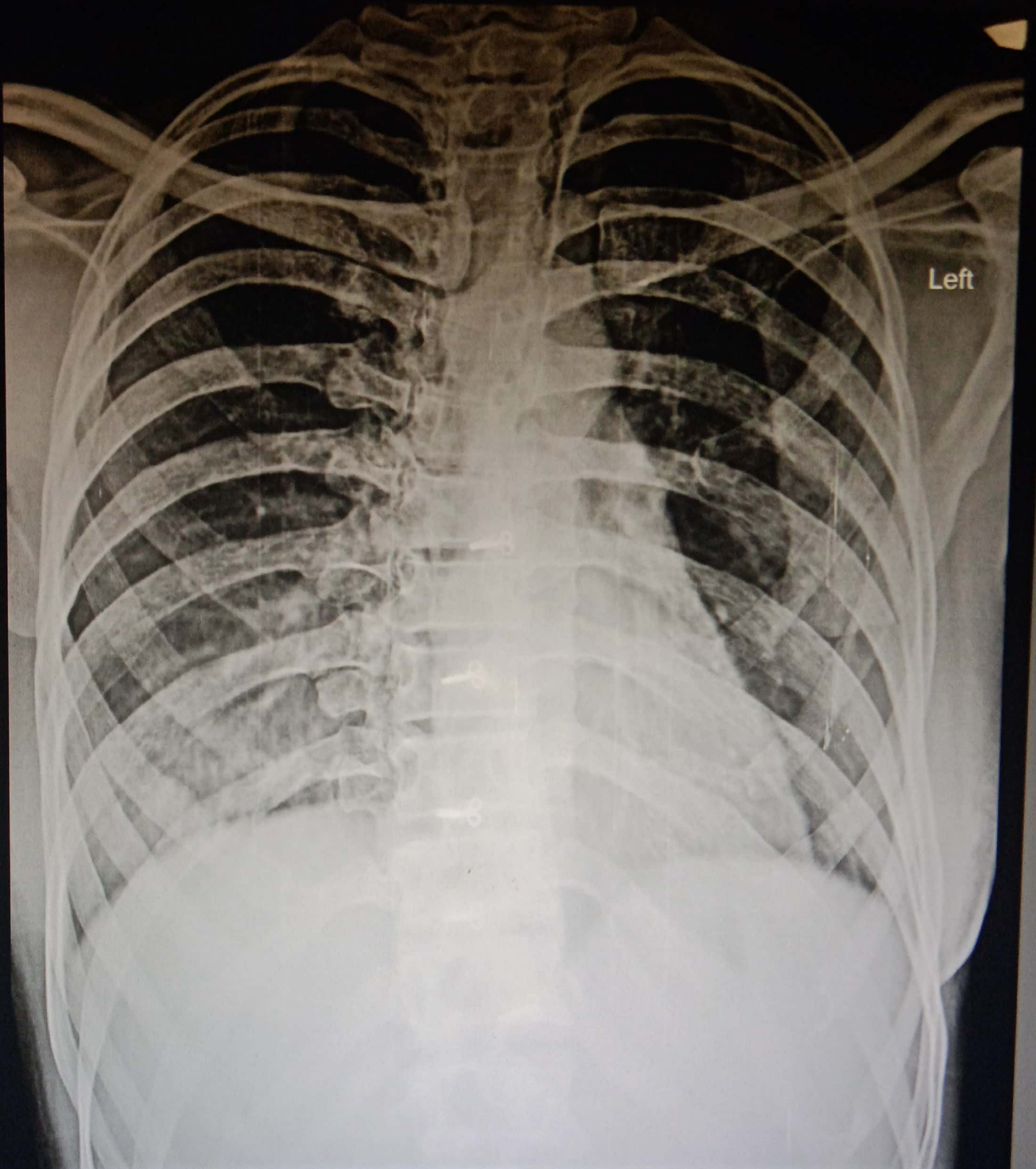
AT-1 G2 (1070.006301). 1.2.1

SCHILLER Part No.2.157044M CE 0123 N.BB

SCHILLER Part No.2.157044M CE 0123

SCHILLER Part No.2.157044M CE 0123 N.BB

SCHILLER Part No.2.157044M CE 0123



Left

MRS G RAJITHA 26Y 01 CHEST PA 06/04/2023 MED WHEEL

AMRUTHA SAI DIAGNOSTIC CENTRE, OPP. BALAJI KALYANAMANDAPAM, SRINIVASA NAGAR, ANANTAPUR, 8688984900

