

HEALTH CHECKUP REPORT

Patient Name: BIPIN PATEL

DATE: 23/07/2022

Age/Gender: 48/M

Reg. No: 376710

Package: MEDIWHEEL

COMPLAINTS (IF ANY):

- Right shoulder pain since 5 months

HISTORY OF HEALTH STATUS: No

PRESENT MEDICATIONS: No

HYPERSENSITIVITY TO ANY DRUG: No

PERSONAL HISTORY:

- | | | | | | |
|---------------|---|----------|-----------------------------|----|-----|
| - Bowel | : | Regular | Diet | : | Veg |
| - Micturition | : | Normal | Habits | : | No |
| - Sleep | : | Adequate | Physical Activity/Exercise: | NO | |
| - Appetite | : | Adequate | | | |

HISTORY OF ILLNESS (WITH PAST MEDICATIONS): No

FAMILY HISTORY:

- Father :- IHD

VITAL SIGNS:

- | | | | |
|------------|----------|---------|------------|
| - Height : | 156 cms | Pulse : | 68/min. |
| - Weight : | 77.7 Kgs | B.P: | 130/80mmHg |

FOR OFFICE USE ONLY

FOR OFFICE USE ONLY

PHYSICIAN CONSULTATION:

1) Clinical Impression

- Type 2 Dm
- Dyslipidemia

2) Recommendations

- 40 min walk daily
- Diet modification
- FBS/PP2BS monthly
- HBA1C after 3 month
- Healthy life style

(Dr. Rashmi Chovatia)

OPHTHALMO CONSULTATION:

	RE	LE
Best corrected visual acuity	6/6	6/6

DENTAL CONSULTATION:

Adv:

- Cleaning, filling

(Dr. Parvin Chandarana)

Please take regular medicine as prescribed by the Doctor. (If given)

FOR OFFICE USE ONLY

Patient ID 314476
 Patient Name Mr. BIPINKUMAR B PATEL
 Gender/Age Male/47
 Ref Doctor

Dt : 23/07/2022

Rx

	Drug Name	Generic Name		Morning	Afternoon	Evening	Night	Duration
Tab.	SITAVEL-M after brek fast ORAL	SITAVEL-M (50+500 mg)		1	0	0	0	3 Month(s)
Tab.	ROSUVAS ORAL	ROSUVASTATIN (20 MG)		0	0	0	1	3 Month(s)

Dr. Rashmi Chovatia

Reg. No : CIMS/A/2022/376710	VisitNo : HC/210722/7 [HCV]
Patient Name : MR. BIPINKUMAR B PATEL	Age(Y-M-D)/Sex : 47 Y 9 M 11 D. / Male
Referring Doctor : Dr. CIMS DOCTOR	Doctor :
Ward/Room :	Bed :

ORD/210722/1792 Lab No : 2022112341 LSN : 902942 (Whole Blood) Sample Quality : Normal
 Collection Time : 23/07/2022 9:22:10 Arrival : 23/07/2022 10:03:10 Validation Time : 23/07/2022 12:25:25PM

	<u>Result</u>	<u>Unit</u>	<u>Reference Range</u>
CBC With ESR			
TOTAL COUNT			
Hemoglobin (SLS Hemoglobin Detection method)	14.0	g/dl	13.5 - 18.0 g/dl
Total RBC Count (Hydro Dynamic Focusing Method)	4.78	mill/Cmm	4.7 - 6.0 mill/Cmm
HCT (Hydro Dynamic Focusing Method)	42.0	%	42 - 52 %
Total WBC Count (Flow Cytometry)	5570	/Cmm	4000 - 10500 /Cmm
Platelet Count (Hydro Dynamic Focusing Method)	318000	/Cmm	150000 - 450000 /Cmm

DIFFERENTIAL COUNT (by Flow Cytometry)


Polymorphs	56	%	40 - 70 %
Lymphocytes	34	%	22 - 45 %
Eosinophils	05	%	01 - 04 %
Monocytes	05	%	01 - 06 %
Basophils	00	%	00 - 01 %
Immature Granulocytes	00	%	0 - 2 %
Smear Study			

RBCs are Normochromic & Normocytic.
 Platelets are adequate in number.
 Malarial Parasites are not seen.
 No Premature cells are seen.

BLOOD INDICES (by Calculated Method)

M.C.V	87.9	fl	78 - 100 fl
M.C.H	29.3	pg	27 - 31 pg
M.C.H.C.	33.3	gm/dl	32 - 36 gm/dl
RDW-CV	12.7	%	11.5 - 14.0 %

ESR (Red Cell Aggregation)



Dr. Shreya Patel
 MD(Path)
 Consultant Pathologist

Dr. Manisha Shah
 MD (Path & Bact)
 Consultant Pathologist
 Reg. No. : G-15496

Dr. Jitendra Nayak
 MD (Path)
 Consultant Pathologist
 Reg. No. : G-14786

Print By : ankita.rajput

Print Date/Time : 23/07/2022 13:26:24



Reg. No : CIMS/A/2022/376710	VisitNo : HC/210722/7 [HCV]
Patient Name : MR. BIPINKUMAR B PATEL	Age(Y-M-D)/Sex : 47 Y 9 M 11 D. / Male
Referring Doctor : Dr. CIMS DOCTOR	Doctor :
Ward/Room :	Bed :

ORD/210722/1792 Lab No : 2022112341 LSN : 902942 (Whole Blood) Sample Quality : Normal
 Collection Time : 23/07/2022 9:22:10 Arrival : 23/07/2022 10:03:10 Validation Time : 23/07/2022 12:25:25PM

After One Hour 03 mm 0 - 10 mm

Blood Group Rh
 ABO "AB"
 Rh POSITIVE

HbA1c (Glycosylated Haemoglobin)

TEST


HbA1c (Glyco Hb)
 (Immuno Turbidimetric)

7.05

% 4.8-5.9% Normal
 5.9-7.0% Good diabetic control
 7.0-10.0% Fair diabetic control
 >10.0% Poor diabetic control

Mean Plasma Glucose 173.5 mg/dL 80 - 140 mg/dL

*** END OF REPORT ***



Dr. Shreya Patel
 MD(Path)
 Consultant Pathologist

Dr. Manisha Shah
 MD (Path & Bact)
 Consultant Pathologist
 Reg. No. : G-15496

Dr. Jitendra Nayak
 MD (Path)
 Consultant Pathologist
 Reg. No. : G-14786

Print By : ankita.rajput




Reg. No : CIMS/A/2022/376710	VisitNo : HC/210722/7 [HCV]
Patient Name : MR. BIPINKUMAR B PATEL	Age(Y-M-D)/Sex : 47 Y 9 M 11 D. / Male
Referring Doctor : Dr. CIMS DOCTOR	Doctor :
Ward/Room :	Bed :

ORD/210722/1792 Lab No : 2022112342 LSN :902942 (SERUM) Sample Quality : Normal
 Collection Time :23/07/2022 9:22:10 Arrival : 23/07/2022 10:03:10 Validation Time : 23/07/2022 12:21:56PM

Liver Function Test

	<u>Result</u>	<u>Unit</u>	<u>Reference Range</u>
Alkaline Phosphatase (PNPP, AMP Buffer Method, Colorimetric)	68.3	U/L	40 - 129 U/L
Billirubin			
Total Billirubin (Diazospecial Iazonium Iron with Blank)	1.15	mg/dL	0.0 - 1.0 mg/dL
Direct Billirubin (Diazo, (Evelyn Malloy) with Blank)	0.28	mg/dL	0.0 - 0.2 mg/dL
Indirect Billirubin (Calculated from Total and Direct Billirubin)	0.87	mg/dL	0.0 - 0.8 mg/dL
SGPT (ALT) (IFCC without pyridoxal phosphate)	14.4	U/L	0 - 41 U/L
SGOT (AST) (IFCC without pyridoxal 5 phosphate)	16.5	U/L	0 - 40 U/L
Total Protein			
Total Proteins (Biuret Method)	7.64	gm/dl	6.4 - 8.3 gm/dl
Albumin (Bromocresol Green Colorimetric)	4.85	gm/dl	3.97 - 4.95 gm/dl
Globulin	2.79	gm/dl	2.2 - 3.5 gm/dl
A/G Ratio	1.74		0.9 - 2.1



Dr. Shreya Patel
MD(Path)
Consultant Pathologist

Dr. Manisha Shah
MD (Path & Bact)
Consultant Pathologist
Reg. No. : G-15496

Dr. Jitendra Nayak
MD (Path)
Consultant Pathologist
Reg. No. : G-14786

Print By : ankita.rajpur

Print Date/Time: 23/07/2022 13:26:55




Reg. No : CIMS/A/2022/376710	VisitNo : HC/210722/7 [HCV]
Patient Name : MR. BIPINKUMAR B PATEL	Age(Y-M-D)/Sex : 47 Y 9 M 11 D. / Male
Referring Doctor : Dr. CIMS DOCTOR	Doctor :
Ward/Room :	Bed :

ORD/210722/1792 Lab No : 2022112342 LSN : 902942 (SERUM) Sample Quality : Normal
 Collection Time : 23/07/2022 9:22:10 Arrival : 23/07/2022 10:03:10 Validation Time : 23/07/2022 12:21:55PM

	Result	Unit	Reference Range
Creatinine (Buffered Jaffe Reaction Kinetic Compensated)	1.01	mg/dL	0.7 - 1.2 mg/dL
Estimated GFR	-	mL/min/1.73m2	76 - 120 mL/min/1.73m2
Fasting Glucose (Hexokinase)	113.6	mg/dL	70 - 100 mg/dL
PSA (ECLIA)	1.27	ng/ml	0 - 4 ng/ml
Thyroid Function Test			
TOTAL T3 (T3) * (Electrochemiluminescence Assay)	1.01	ng/ml	0.846 - 2.02 ng/ml
TOTAL T4 (T4) * (Electrochemiluminescence Assay)	8.51	µgm/dl	5.13 - 14.06 µgm/dl
TSH (Electrochemiluminescence Assay)	3.95	µIU/ml	0.27- 4.20 µIU/ml
Uric Acid (Uricase Colorimetric Enzymatic)	6.94	mg/dL	3.4 - 7.0 mg/dL

*** END OF REPORT ***



Dr. Shreya Patel
MD(Path)
Consultant Pathologist

Dr. Manisha Shah
MD (Path & Bact)
Consultant Pathologist
Reg. No. : G-15496

Dr. Jitendra Nayak
MD (Path)
Consultant Pathologist
Reg. No. : G-14786

Print By : ankita.rajput

Print Date/Time : 23/07/2022 13:26:55



Page 2 of 2 MC-3049

Reg. No : CIMS/A/2022/376710	VisitNo : HC/210722/7 [HCV]
Patient Name : MR. BIPINKUMAR B PATEL	Age(Y-M-D)/Sex : 47 Y 9 M 11 D. / Male
Referring Doctor : Dr. CIMS DOCTOR	Doctor :
Ward/Room :	Bed :

ORD/210722/1792 Lab No : 2022112342 LSN : 902942 (SERUM) Sample Quality : Normal
 Collection : 23/07/2022 9:22:10AM Arrival: 23/07/2022 10:03:39 Validation Time 23/07/2022 12:16:41

Lipid Profile (With Direct LDL)

Type of Sample	Result	Unit	Reference Range
Type of Sample	: Fasting		
Cholesterol (Enzymatic/Colorimetric, Cholesterol Oxidas, Esterase, Peroxidase Gen.2)	: 306.4	mg/dL	Less than 160 mg/dl Excellent Less than 200 mg/dl Desirable 200-239 mg/dl Borderline High 240 mg/dl & over High
Triglyceride (Enzymetic Colorimetric without Glycerol Blank without Serum Blank)	: 223.5	mg/dL	Less than 150 mg/dl Normal 150 - 199 mg/dl Borderline High 200-499 mg/dl High 500 mg/dl or greater Very High
H D L Cholesterol (Direct Mearuse Homogenous Technique Modified Enzymatic Colorimetric Gen. 3)	: 39.1	mg/dL	Less than 40 mg/dl Low 60 mg/dl or above Excellent
L D L Cholesterol (DIRECT) (Homogenous Enzymatic colorimetric Assay)	: 238.6	mg/dL	Less than 80 mg/dl Excellent Less than 100 mg/dl Optimal 100 - 129 mg/dl Near or above optimal 130 - 159 mg/dl Borderline High 160 - 189 mg/dl High 190 mg/dl & above Very High
VLDL Cholesterol (Calculated)	: 44.7	mg/dL	15 - 30 mg%
Cholesterol/HDL Ratio (Calculated)	: 7.84		Normal upto 4.5



Dr. Shreya Patel
MD(Path)
Consultant Pathologist

Dr. Manisha Shah
MD (Path & Bact)
Consultant Pathologist
Reg. No. : G-15496

Dr. Jitendra Nayak
MD (Path)
Consultant Pathologist
ankita.rajpoot
Reg. No. : G-14786

Print Date/Time: 23/07/2022

1:27:43PM

Page 1 of 2



Reg. No : CIMS/A/2022/376710	VisitNo : HC/210722/7 [HCV]
Patient Name : MR. BIPINKUMAR B PATEL	Age(Y-M-D)/Sex : 47 Y 9 M 11 D. / Male
Referring Doctor : Dr. CIMS DOCTOR	Doctor :
Ward/Room :	Bed :

ORD/210722/1792 Lab No : 2022112342 LSN : 902942 (SERUM) Sample Quality : Normal
Collection : 23/07/2022 9:22:10AM Arrival: 23/07/2022 10:03:39 Validation Time 23/07/2022 12:16:41

LDL/HDL Ratio : 6.1 Less than 3.5
(Calculated)

Remarks :

*** END OF REPORT ***



Dr. Shreya Patel
MD(Path)
Consultant Pathologist

Dr. Manisha Shah
MD (Path & Bact)
Consultant Pathologist
Reg. No. : G-15496

Dr. Jitendra Nayak
MD (Path)
Print By: **ankita.rajput**
Consultant Pathologist
Reg. No. : G-14786

Print Date/Time: 23/07/2022

1:27:43PM

Page 2 of 2




Reg. No : CIMS/A/2022/376710	VisitNo : HC/210722/7 [HCV]
Patient Name : MR. BIPINKUMAR B PATEL	Age(Y-M-D)/Sex : 47 Y 9 M 11 D. / Male
Referring Doctor : Dr. CIMS DOCTOR	Doctor :
Ward/Room :	Bed :

ORD/210722/1792 Lab No : 2022112429 LSN : 902942 (Urine) Sample Quality : Normal
 Collection Time : 23/07/2022 11:30:25 Arrival : 23/07/2022 11:43:25 Validation Time : 23/07/2022 12:24:12PM

	<u>Result</u>	<u>Unit</u>	<u>Reference Range</u>
Urine R & M			
PHYSICAL EXAMINATION			
Quantity	20 cc		
Colour	Pale Yellow		
Transparency	Clear		
Reaction (QDS-10 Strip)	6.0		
Sp. Gravity (QDS-10 Strip)	1.015		1.005 - 1.035
CHEMICAL EXAMINATION			
U. Albumin (QDS-10 Strip/Manual)	Nil		
U. Glucose (QDS-10 Strip/Manual)	Nil		
U. Acetone (QDS-10 Strip/Manual)	Absent		
BS/BP (QDS-10 Strip/Manual)	Absent		
MICROSCOPIC EXAMINATION			
Pus Cell	Occasional	/H.P.F.	/H.P.F.
Red Blood Cell	Nil	/H.P.F.	/H.P.F.
Epithelial Cell	1-2	/H.P.F.	/H.P.F.
Cast	Not Seen		
Crystals	Not Seen		
Amorphous	Absent		
Monilia	Absent		

*** END OF REPORT ***



Dr. Shreya Patel
MD(Path)
Consultant Pathologist

Dr. Manisha Shah
MD (Path & Bact)
Consultant Pathologist
Reg. No. : G-15496

Dr. Jitendra Nayak
MD (Path)
Consultant Pathologist
Reg. No. : G-14786

Print By : ankita.rajput

Print Date/Time : 23/07/2022 12:24:12PM





MARENGO ASIA NETWORK HOSPITAL



JCI (USA)



NABH



NABL
Certificate No. MC-3649



www.cims.org



CIMS Hospital

Name : MR. BIPINKUMAR B PATEL
Reg No : CIMS/A/2022/376710
DoB / Sex : 10/10/1974 / Male

ECHO Report

Dt : 23/07/2022

Patient Details

Patient ID 314476
Name Mr. BIPINKUMAR B PATEL
Age 47 Years
Gender Male
Blood Group
Referral Doctor

ECHO Identification Detail

Doctor Incharge Dr. VIPUL KAPOOR
Clinical Status Of Patient
ECHO Code TJ
Finding Description

1. Normal sized LA, LV, RA, RV.
2. Normal LV systolic function, LVEF: 60%.
3. No RWMA.
4. Normal LV diastolic function.
5. All cardiac valves are structurally normal.
6. Trivial MR, Trivial TR, Trivial PR, No AR.
7. No PAH.
8. IAS/IVS: Intact.
9. Normal RV systolic function.
10. No clot/vegetation/pericardial effusion.

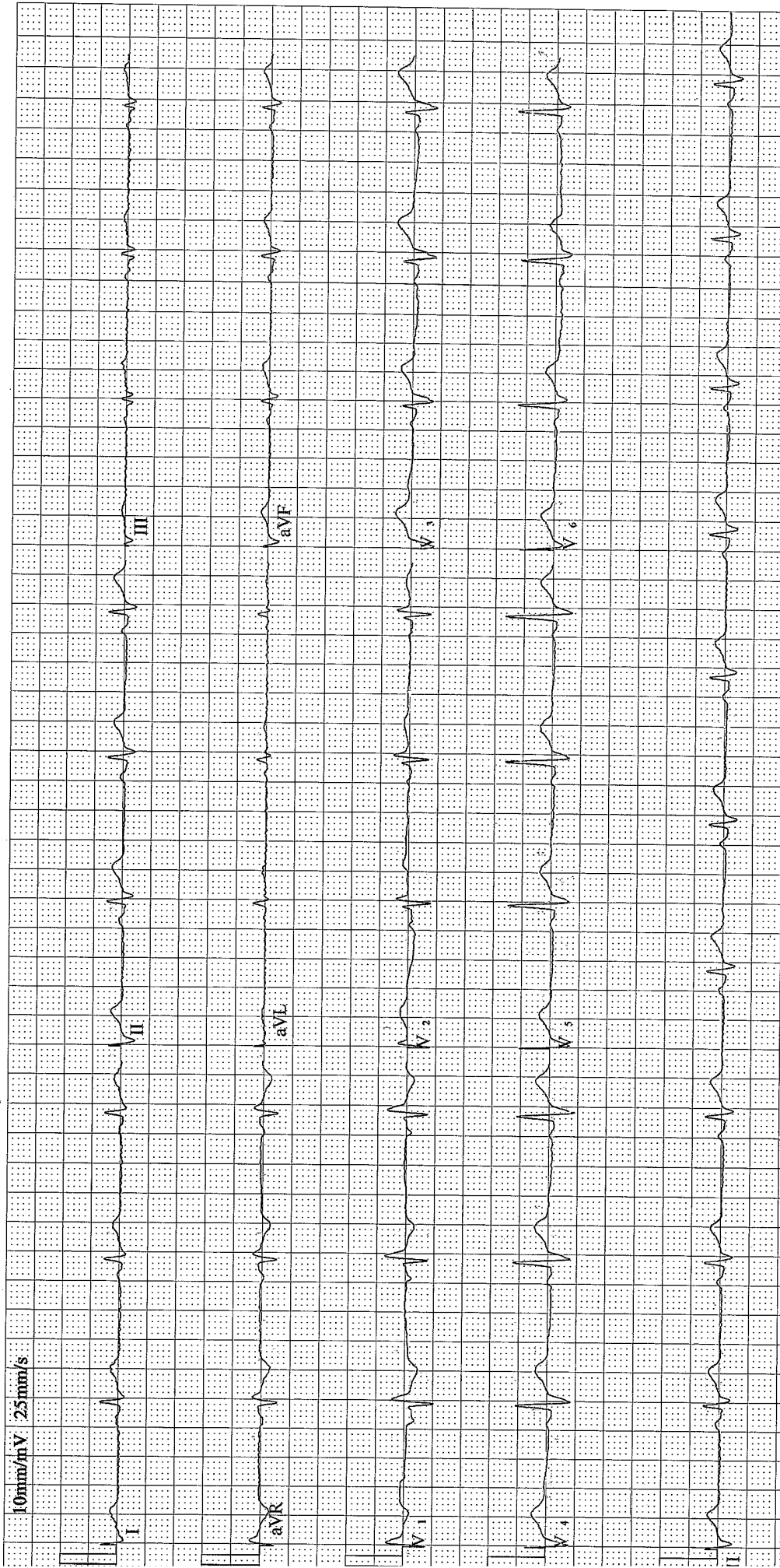
Dr. VIPUL KAPOOR

FOR ECHO / TMT REPORTS ONLY

Name : BIPINKUMAR PADEL

Sex : Male

Age : Date : 7-23-2022



Frequency :	1000 Hz	PR Interval :	103 ms
Sample Time :	14 s	QT Interval :	383 ms
Heart Rate :	60 bpm	QTc Interval :	383 ms
P Duration :	78 ms	P Axis :	59.3°
QRS Duration :	121 ms	QRS Axis :	14.4°
T Duration :	232 ms	T Axis :	53.1°

Name : MR. BIPINKUMAR B PATEL

Reg No : CIMS/A/2022/376740
DoB / Sex : 10/10/1974 / Male

MS R (W)

in Signature:



**Marengo CIMS
Hospital**



JCI (USA)

NABH

NABL
Certificate No. 111C-0849

www.cims.org

CIMS Hospital

Patient's Name : BIPINKUMAR PATEL
Reg. No. (IP/OP): HC-376710
Referred By Dr. : CIMS

Age, Sex : 48Y/M
Date : 23/07/2022

Plain Skiagram of Chest PA standing view:
(Serial No-3523)

Both lung fields appear normal.

No evidence of pleural effusion or pneumothorax is seen on either side.

Mediastinal shadow appears normal.

Heart and aorta appear normal.

Domes of diaphragm appear normal.

Bones under view appears normal.

Kindly correlate clinically

DR KIRTAN SHAH DR DEEPA SHAH DR UMA MEHTA DR NIMISH SHARMA DR VRUSHTI GANDHI DR RAVINA CHAUHAN
M.D. RADIODIAG. M.D., D.M.R.E D.M.R.D. F.R.C.R D.M.R.D. (D.N.B.) M.D. RADIODIAG. M.D. RADIODIAG.
CONS. RADIOLOGIST CONS. RADIOLOGIST CONS. RADIOLOGIST CONS. RADIOLOGIST CONS. RADIOLOGIST CONS. RADIOLOGIST

Note: This is only a radiological impression and not the final diagnosis. All diagnostic modalities have their own limitations. Therefore radiological modality report should be interpreted in correlation with clinical and pathological findings.

FOR RADIOLOGY REPORTS ONLY

Patient's Name : BIPINKUMAR PATEL
Reg. No. (IP/OP): HC-376710
Referred By Dr. : CIMS

Age, Sex : 48Y/M
Date : 23/07/2022

USG OF ABDOMEN & PELVIS

LIVER: Liver is normal in size and echotexture. No evidence of focal SOL or dilatation of IHBR seen. Porta hepatis appear normal.

GALLBLADDER: Gallbladder appeared normal. No calculus or mass lesion seen.

PANCREAS: Visualised pancreas appeared normal in size and echotexture. No focal lesion, mass or pancreatitis.

SPLEEN: Spleen appears normal in size and echotexture.

PARAAORTIC REGION: Aorta grossly appeared normal. No paraaortic lymphnodes seen.

KIDNEYS: Both kidneys appear normal in size, shape and in position. Cortex and collecting system of both kidneys appeared normal. No evidence of calculus or obstructive uropathy on either side. Right kidney: 96x40mm. Left kidney: 107x48mm.

URINARY BLADDER: Bladder appeared normal. No calculus or mass lesion is seen.

PROSTATE: Prostate appears normal in size and echotexture. Size of prostate: 26x33x30mm. Volume: 14cc.

No evidence of free fluid or collection is seen in peritoneal spaces. Normal small bowel peristalsis noted.

COMMENTS: Appearance suggests

- No significant abnormality detected.

Kindly correlate clinically.

DR KIRTAN SHAH DR DEEPA SHAH DR UMA MEHTA DR NIMISH SHARMA DR VRUSHTI GANDHI DR RAVINA CHAUHAN
M.D., RADIODIAG. M.D., D.M.R.E D.M.R.D. F.R.C.R D.M.R.D. (D.N.B.) M.D. RADIODIAG. M.D. RADIODIAG.
CONS. RADIOLOGIST CONS. RADIOLOGIST CONS. RADIOLOGIST CONS. RADIOLOGIST CONS. RADIOLOGIST CONS. RADIOLOGIST

Note: This is only a radiological impression and not the final diagnosis. All diagnostic modalities have their own limitations. Therefore radiological modality report should be interpreted in correlation with clinical and pathological findings.

FOR RADIOLOGY REPORTS ONLY