

CONSULTATION SUMMARY

Patient MRN : 17540000307498
Patient Name : Bina Mondal
Gender/Age/Dob : Female , 39 Years , 20/02/83
Patient Phone No : 9007785409
Patient Address : Mahavir park machewa,ahavir,
Mahasamund,Mahasamund,
Chhattisgarh,India,-493445

Consultation Date: 27/08/2022 01:58 PM
Consultant : Dr. Veronica Irene Yuel
(OBSTETRICS & GYNAECOLOGY)
Consultation Type : OP , NEW VISIT



CHIEF COMPLAINTS & HISTORY OF PRESENT ILLNESS

- Came for routine health checkup c/o pain lower abdomen off and on Regular cycles LMP - 6/8 /22
- Also c/o discharge from breast

VITALS

Blood Pressure: 99/63 mmHg Heart Rate: 79 /bpm Temperature: 98.4 F
Respiratory Rate: 20 /min Weight: 53 kg Fall Score: Low
Pain Score: 0

GENERAL EXAMINATION

- Pallor : nil
- Edema : nil
- Icterus : nil
- Local Examination : Both breasts active

SYSTEMIC EXAMINATION

- Per Abdomen : NAD
- Per Speculum : cervix and vagina healthy, papsmear taken
- Per Vaginal Examination : Uterus a/v, NS, mobile, NT, adnexae normal

INVESTIGATION ORDER

PROLACTIN

MEDICATION ORDER

DRUG NAME

PATIENT INSTRUCTION

NH MMI Narayana Superspeciality Hospital

(A unit of Narayana Hrudayalaya Limited) CIN: L85110KA2000PLC027497

Registered Office: 258/A, Bommasandra Industrial Area, Anekal Taluk, Bangalore 560099

Hospital Address: New Dhantari Road, Lalpur, Raipur 492001

Tel +91 771 4210901 / 902 | Fax +91 771 408 1106 | Email: info.rpr@narayanahealth.org | www.narayanahealth.org



Appointments
1800-309-0309

Page 1 of 2

Emergencies
8821-818181

DRUG NAME

- 1) CABERGOLINE-TABLET-0.5MG-
CABGOLIN

PATIENT INSTRUCTION

Once a week (1 - 0 - 0 - 0) Tablet After Food for 6 WEEKS,
Qty: 6 , Start Date: Aug 27, 2022 , End Date: Oct 07,
2022

NOTES

Review with reports.

CONSULTANT DETAILS



Dr. Veronica Irene Yuel , CONSULTANT , OBSTETRICS & GYNAECOLOGY
Registration No : 3447/2011


One free consultation with the same doctor within next 6 days.

Printed By: Dr. Veronica Irene Yuel | Printed On: 27.08.2022 14:35

CONSULTATION SUMMARY

Patient MRN : 17540000307498
Patient Name : Bina Mondal
Gender/Age/Dob : Female , 39 Years , 20/02/83
Patient Phone No : 9007785409
Patient Address : Mahavir park machewa, ahavir,
Mahasamund, Mahasamund,
Chhattisgarh, India, -493445

Consultation Date: 27/08/2022 02:00 PM
Consultant : Dr. Renuka Sharma
(OPHTHALMOLOGY)
Consultation Type : OP , NEW VISIT



VITALS

Blood Pressure: 99/63 mmHg

Heart Rate: 79 /bpm

Temperature: 98.4 F

Respiratory Rate: 20 /min

Weight: 53 kg

Fall Score: Low

Pain Score: 0

CONSULTANT DETAILS



Dr. Renuka Sharma , VISITING CONSULTANT , OPTHALMOLOGY
Registration No : 2434/2009

One free consultation with the same doctor within next 6 days.

Printed By: Dr. Renuka Sharma | Printed On: 27.08.2022 14:14

DEPARTMENT OF LABORATORY MEDICINE

MRN	: 17540000307498	Department	: OBSTETRICS & GYNAECOLOGY
Name	: Bina Mondal	Specimen	: WHOLE BLOOD
Age / Sex	: 39 Year(s) / Female	Visit Type	: OP
Sample No	: 22208270161	Collected On	: 27/08/2022 12:08 PM
Consulting DR	: Dr. Veronica Irene Yuel	Referred DR	: Dr. Veronica Irene Yuel
Patient Address	: Mahavir park machewa ahavir Mahasamund Mahasamund Chhattisgarh,India	Received On	: 27/08/2022 12:59 PM
		Reported On	: 27/08/2022 02:10 PM
		Report Type	: Final

HAEMATOLOGY LAB

Test	Result	Unit	Biological Reference Interval
EHP MEDIWHEEL FULL BODY HEALTH CHECK PACKAGE FEMALE BELOW 40 YRS			
ERYTHROCYTE SEDIMENTATION RATE (ESR)	15.00	mm/hr	0-19



Dr. SMOYI RATH GREMBBS MD
PATHOLOGIST



DEPARTMENT OF LABORATORY MEDICINE

MRN	: 17540000307498	Department	: OBSTETRICS & GYNAECOLOGY
Name	: Bina Mondal	Specimen	: PLASMA
Age / Sex	: 39 Year(s) / Female	Visit Type	: OP
Sample No	: 1R2208270286	Collected On	: 27/08/2022 12:08 PM
Consulting DR	: Dr. Veronica Irene Yuel	Referred DR	: Dr. Veronica Irene Yuel
Patient Address	: Mahavir park machewa ahavir Mahasamund Mahasamund Chhattisgarh,India	Received On	: 27/08/2022 12:59 PM
		Reported On	: 27/08/2022 04:12 PM
		Report Type	: Final

BIOCHEMISTRY

Test	Result	Unit	Biological Reference Interval
POST PRANDIAL BLOOD SUGAR (PPBS)	91.00		



Dr. N. S. RAJAN, M.B.B.S D.C.P
CONSULTANT PATHOLOGIST



DEPARTMENT OF LABORATORY MEDICINE

MRN : 17540000307498
Name : Bina Mondal
Age / Sex : 39 Year(s) / Female
Sample No : 22208270162
Consulting DR : Dr. Veronica Irene Yuel
Patient Address : Mahavir park machewa abavir Mahasamund
Mahasamund Chhattisgarh,India

Department : OBSTETRICS & GYNAECOLOGY
Specimen : WHOLE BLOOD
Visit Type : OP
Collected On : 27/08/2022 12:08 PM
Referred DR : Dr. Veronica Irene Yuel
Received On : 27/08/2022 12:59 PM
Reported On : 27/08/2022 01:36 PM
Report Type : Final

Test	Result	Unit	Biological Reference Interval
COMPLETE BLOOD COUNT (CBC)			
HAEMOGLOBIN (HB%)	12.00 L	g/dl	13-18
RED BLOOD CELL COUNT	4.08	Million/ul	3.8-5.8
PCV (PACKED CELL VOLUME) / HEMATOCRIT	34.8 L	%	36-46
MCV (MEAN CORPUSCULAR VOLUME)	85.3	fl	76-96
MCH (MEAN CORPUSCULAR HAEMOGLOBIN)	29.30	pg	27-32
MCHC (MEAN CORPUSCULAR HAEMOGLOBIN CONCENTRATION)	34.40	%	30-35
RED CELL DISTRIBUTION WIDTH (RDW)	14.60 H	%	11.6-14.0
PLATELET COUNT	167.00	Thous/ μ l	150-400
TOTAL LEUKOCYTE COUNT (TLC)	5.1	Thousand/cu.mm	4.0-10.0
DIFFERENTIAL COUNT (DC)			
Neutrophils	68	%	40-75
Lymphocytes	25	%	20-45
Monocytes	05	%	2-10
Eosinophils	02	%	1-6
Basophils	00	%	0-1
NRBC	0.0		



Dr. SMRITI K. SATHYANARAYAN
PATHOLOGY M.B.B.S MD



DEPARTMENT OF LABORATORY MEDICINE

MRN	: 17540000307498	Department	: OBSTETRICS & GYNAECOLOGY
Name	: Bina Mondal	Specimen	: SERUM
Age / Sex	: 39 Year(s) / Female	Visit Type	: OP
Sample No	: 1R2208270288	Collected On	: 27/08/2022 12:08 PM
Consulting DR	: Dr. Veronica Irene Yuel	Referred DR	: Dr. Veronica Irene Yuel
Patient Address	: Mahavir park machewa ahavir Mahasamund Mahasamund Chhattisgarh,India	Received On	: 27/08/2022 12:59 PM
		Reported On	: 27/08/2022 02:05 PM
		Report Type	: Final

Test	Result	Unit	Biological Reference Interval
FASTING BLOOD SUGAR (FBS)	83.00	mg/dl	70-99
LIPID PROFILE (CHOL,TRIG,HDL,LDL,VLDL)			
CHOLESTEROL TOTAL	167.00		50-200
TRIGLYCERIDES	81.00	mg/dl	0-150
HDL CHOLESTROL (HDLC)	46.00	mg/dl	35-70
LDL CHOLESTEROL	105.00 H	mg/dl	0-100
VLDL CHOLESTEROL	16.20	mg/dl	0-40
CHOLESTEROL /HDL RATIO	3.63		0-5



Dr. SUNITA RATHORE MBBS MD
PATHOLOGIST



DEPARTMENT OF LABORATORY MEDICINE

MRN : 17540000307498
 Name : Bina Mondal
 Age / Sex : 39 Year(s) / Female
 Sample No : IR2208270288
 Consulting DR : Dr. Veronica Irene Yuel
 Patient Address : Mahavir park machewa ahavir Mahasamund
 Mahasamund Chhattisgarh,India

Department : OBSTETRICS & GYNAECOLOGY
 Specimen : SERUM
 Visit Type : OP
 Collected On : 27/08/2022 12:08 PM
 Referred DR : Dr. Veronica Irene Yuel
 Received On : 27/08/2022 12:59 PM
 Reported On : 27/08/2022 03:05 PM
 Report Type : Final

Test	Result	Unit	Biological Reference Interval
THYROID PROFILE (T3, T4, TSH)			
TRI IODO THYRONINE (T3)	1.16	ng/dL	0.6-1.81
THYROXINE (T4)	8.63	ug/dl	3.2-12.6
TSH (THYROID STIMULATING HORMONE)	1.90	mIU/mL	0.35-5.50



Dr. SMRITI RATHORE MBBS MD
PATHOLOGY



DEPARTMENT OF LABORATORY MEDICINE

MRN	: 17540000307498	Department	: OBSTETRICS & GYNAECOLOGY
Name	: Bina Mondal	Specimen	: Stool
Age / Sex	: 39 Year(s) / Female	Visit Type	: OP
Sample No	: 7R2208270083	Collected On	: 27/08/2022 12:08 PM
Consulting DR	: Dr. Veronica Irene Yuel	Referred DR	: Dr. Veronica Irene Yuel
Patient Address	: Mahavir park machewa ahavir Mahasamund Mahasamund Chhattisgarh,India	Received On	: 27/08/2022 12:59 PM
		Reported On	: 27/08/2022 02:01 PM
		Report Type	: Final

CLINICAL PATHOLOGY

Test	Result	Unit	Biological Reference Interval
FAT	NOT SEEN		
STARCH	NOT SEEN		
MUSCLE CELLS	NOT SEEN		
VEG CELLS	NOT SEEN		
BLOOD STOOL	NOT SEEN		
PUS CELLS	2-3		



Dr. **SHRUTI RATHOR** EMBBS MD
PATHOLOGY



DEPARTMENT OF LABORATORY MEDICINE

MRN : 17540000307498	Department : OBSTETRICS & GYNAECOLOGY
Name : Bina Mondal	Specimen : URINE
Age / Sex : 39 Year(s) / Female	Visit Type : OP
Sample No : 7R2208270084	Collected On : 27/08/2022 12:08 PM
Consulting DR : Dr. Veronica Irene Yuel	Referred DR : Dr. Veronica Irene Yuel
Patient Address : Mahavir park machewa ahavir Mahasamund Mahasamund Chhattisgarh,India	Received On : 27/08/2022 12:59 PM
	Reported On : 27/08/2022 01:55 PM
	Report Type : Final

Test	Result	Unit	Biological Reference Interval
URINE ROUTINE & MICROSCOPY			
PHYSICAL EXAMINATION			
VOLUME	20	ml	
COLOUR	PALE YELLOW		
APPEARANCE	CLEAR		
SP. GRAVITY	1.015		1.002-1.03
CHEMICAL EXAMINATION			
pH(REACTION)	6.0		4.8-7.5
PROTEIN	Negative		Negative
URINE GLUCOSE	Negative		Negative
KETONE BODIES	Negative		Negative
BILE SALTS	Negative		Negative
BILE PIGMENT (BILIRUBIN)	Negative		Negative
UROBILINOGEN	Negative		
BLOOD URINE	Negative		Negative
URINE LEUCOCYTE ESTERASE	Negative		Negative
MICROSCOPIC EXAMINATION			
NITRITE	Negative		Negative
PUS CELLS	2-3	hpf	0-2


 Dr. SM. L. BATHORE MBBS MD
 PATHOLOGIST


DEPARTMENT OF LABORATORY MEDICINE

MRN : 17540000307498	Department : OBSTETRICS & GYNAECOLOGY
Name : Bina Mondal	Specimen : SERUM
Age / Sex : 39 Year(s) / Female	Visit Type : OP
Sample No : 1R2208270287	Collected On : 27/08/2022 12:08 PM
Consulting DR : Dr. Veronica Irene Yuel	Referred DR : Dr. Veronica Irene Yuel
Patient Address : Mahavir park machewa ahavir Mahasamund Mahasamund Chhattisgarh,India	Received On : 27/08/2022 12:59 PM
	Reported On : 27/08/2022 02:05 PM
	Report Type : Final

Test	Result	Unit	Biological Reference Interval
RENAL PACKAGE - 2 (RFT FASTING)			
SERUM CREATININE			
SERUM CREATININE	0.6	mg/dl	0.6-1.2
eGFR	108.5	mL/min/1.73m2	
BLOOD UREA NITROGEN (BUN)	11.00	mg/dl	7-20
SODIUM, SERUM	139.00	mmol/L	135-150
POTASSIUM, SERUM	4.20	mmol/L	3.5-5
CHLORIDE	101.00	mmol/L	95-106
CALCIUM	9.10	mg/dl	8.5-10.1
MAGNESIUM	1.90	mg/dL	1.8-2.4
URIC ACID	3.30	mg/dl	2.6-6
PHOSPHORUS	4.50	mg/dl	2.6-4.7
FASTING BLOOD SUGAR (FBS)	83.00	mg/dl	70-99

Note:
Abnormal results are highlighted.
Results relate to the sample only.
Kindly correlate clinically.



Dr. SMRITI RATHORE MBBS MD
PATHOLOGY



DEPARTMENT OF PATHOLOGY LAB

MRN : 17540000307498
Name : Bina Mondal
Age / Sex : 39 Year(s) / Female
Sample No : 0,1R2208270286,1R2208270287,1R2208270288,1R2208270289,22208270161,22208270162,7R2208270083,7R2208270084,92208290003
Consulting DR : Dr. Veronica Irene Yuel
Patient Address : Mahavir park machewa ahavir Mahasamund Mahasamund Chhattisgarh,India

Department : OBSTETRICS & GYNAECOLOGY
Specimen : PLASMA,SERUM,Stool,SWAB,URINE,WHOLE BLOOD
Visit Type : OP
Collected On : 27/08/2022 12:08 PM
Referred DR : Dr. Veronica Irene Yuel
Received On : 27/08/2022 12:59 PM
Reported On : 29/08/2022 10:33 AM
Report Type : Final

HISTOPATHOLOGY

EHP MEDIWHEEL FULL BODY HEALTH CHECK PACKAGE FEMALE BELOW 40 YRS

PAP SMEAR

GENERAL CATEGORIZATION	Smear show superficial & intermediate squamous epithelial cells in the background of inflammatory cells.
MATERIAL RECEIVED	Received one unstained smear.
SPECIMEN TYPE	Pap Smear
IMPRESSION	NILM (Negative for Intraepithelial Lesion or malignancy)
Lab No	2022/C/603

-- End of Report --

Result Entered by


Dr. SMRITI RATHORE MBBS MD
PATHOLOGIST RAIPUR (C.G.)

DEPARTMENT OF LABORATORY MEDICINE

MRN	: 17540000307498	Department	: OBSTETRICS & GYNAECOLOGY
Name	: Bina Mondal	Specimen	: SERUM
Age / Sex	: 39 Year(s) / Female	Visit Type	: OP
Sample No	: 1R2208270390	Collected On	: 27/08/2022 04:33 PM
Consulting DR	: Dr. Veronica Irene Yuel	Referred DR	: Dr. Veronica Irene Yuel
Patient Address	: Mahavir park machewa ahavir Mahasamund Mahasamund Chhattisgarh,India	Received On	: 27/08/2022 04:55 PM
		Reported On	: 27/08/2022 06:43 PM
		Report Type	: Final

BIOCHEMISTRY

Test	Result	Unit	Biological Reference Interval
PROLACTIN	1620.00	mIU/L	NORMAL FEMALE 64-395 mIU/L NON-PREGNANT 3.0-18.6 ng/mL MALES 78-380 mIU/L

Note:
Abnormal results are highlighted.
Results relate to the sample only.
Kindly correlate clinically.

– End of Report –


Dr. NEERAJ NAIR, M.B.B.S D.C.P
CONSULTANT PATHOLOGIST

NH MMI Narayana Superspeciality Hospital

(A unit of Narayana Hrudayalaya Limited) CIN: L85110KA2000PLC027497

Registered Office: 258/A, Bommasandra Industrial Area, Anekal Taluk, Bangalore 560099

Hospital Address: New Dhamtari Road, Lalpur, Raipur 492001

Tel +91 771 4210901 / 902 | Fax +91 771 408 1106 | Email: info.rpr@narayanahealth.org | www.narayanahealth.org



Page 1 / 1

Appointments
1800-309-0309

Emergencies
8821-818181

NAME: MRS: BINA MONDAL

AGE: 39YRS/F MRN: 307498

REF. BY: DR. VERONICA

DATE: 27.08.2022

SONOGRAPHY OF ABDOMEN AND PELVIS

The Real time, B mode, gray scale sonography was performed.

LIVER : The liver is normal in size 12.5cm & reveals normal echotexture with smooth outlines.

PORTAL VEIN : The portal vein is normal in calibre.

GALL BLADDER : The gall bladder is partially distended. Visualized lumen appear clear.

Visualized proximal CBD is normal in calibre.

SPLEEN : The spleen is normal in size and shape. No evidence of focal lesion is noted.

PANCREAS :The visualized pancreas is normal in size, shape, contours and echotexture.

B/L KIDNEYS :

The right kidney measures - 10.2 x 4.5cm and left kidney measures - 9.8 x 5.2cm in size. Both kidneys reveal normal cortical echotexture and have smooth margins. Cortico-medullary differentiation is maintained. No calculus or hydronephrosis is seen.

URINARY BLADDER : The urinary bladder is well distended.

UTERUS:The uterus is anteverted and normal in size 7.5 x 4.9 x 4.5cm.The endometrial thickness is 9.3mm.

Both ovaries are normal in size and echotexture. No adnexal mass is seen.

Right ovary measures 3.2 x 1.8cm. Left ovary measures 3.1 x 1.4cm.

No free fluid is seen in the peritoneal & pelvic cavity.

Excessive intrabowel gases are noted.

IMPRESSION :

- **THE SONOGRAPHY OF THE ABDOMEN AND PELVIS IS WITHIN NORMAL LIMITS.**

ADVISED: Clinical correlation & appropriate further evaluation.


DR. BANJANA KEDIA
MBBS, CHET
CONSULTANT SONOLOGIST

Patient Name	Bina Mondal	Requested By	DR V LRENE YUEL
MRN	17540000307498	Procedure DateTime	27-08-2022 15:31
Age/Sex	39Y 6M/Female	Hospital	NH-RAIPUR

CHEST RADIOGRAPH (PA VIEW)

CLINICAL DETAILS: Routine checkup.

FINDINGS:

- The lung fields and bronchovascular markings appear normal.
- The cardiac size is within normal limits.
- Mediastinum and great vessels are within normal limits.
- Trachea is normal and is central. The hilar shadows are unremarkable.
- The costo-phrenic angles are clear. No evidence of pleural effusion or pneumothorax.
- The visualized bones and soft tissue structures appear normal.
- Both the diaphragmatic domes appear normal.

IMPRESSION:

- **No significant abnormality detected.**



MBBS, DNB
Associate Consultant.

This report has been generated from NH Teleradiology 24/7, a service of Narayana Health

-- End of Report --

Page 1 of 1

NH MMI Narayana Superspeciality Hospital

(A unit of Narayana Hrudayalaya Limited) CIN: LB5110KA2000PLC027497

Registered Office: 258/A, Bommasandra Industrial Area, Anekal Taluk, Bangalore 560099

Hospital Address: New Dhamtari Road, Lalpur, Raipur 492001

Tel +91 771 4210901 / 902 | Fax +91 771 408 1106 | Email: info.rpr@narayanahealth.org | www.narayanahealth.org



Appointments

1800-309-0309

Emergencies

8821-818181

ID: 307498
Name: MS BINA MONDAL
Age: 39 Years
Gender: Female

2022-08-27 13:11:01

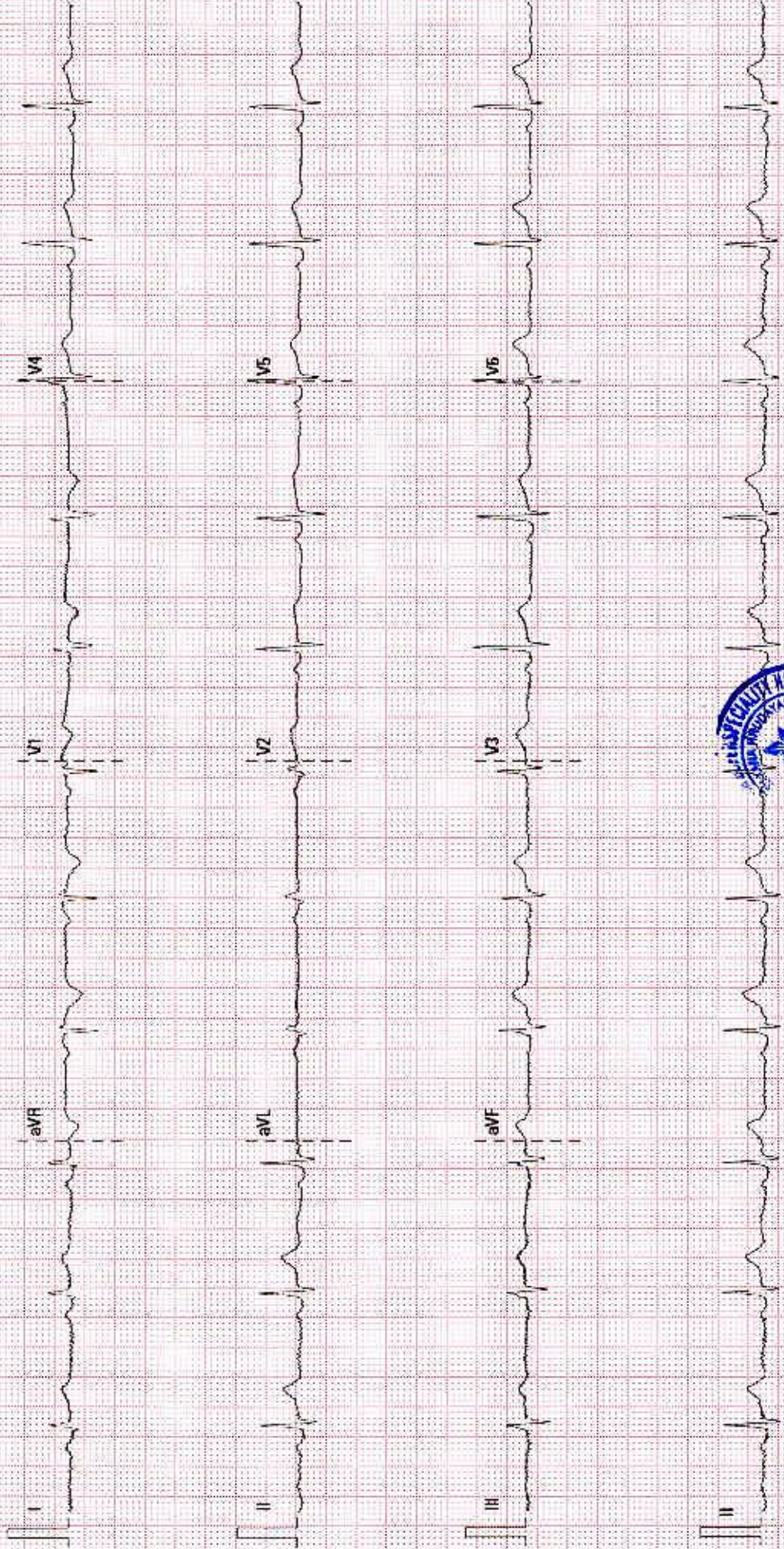
Heart Rate
PR Interval
QRS Duration
QT/QTc Interval
P/QRS/T Axis
QTc Hodges

68 bpm
150 ms
78 ms
374/388 ms
8/39/56 deg

Sinus rhythm
Normal ECG

Unconfirmed Diagnosis

“Please Xerox This Copy”



ECHOCARDIOGRAPHY REPORT

Patient ID	: 17540000307498	Report Date	: 27/08/2022
Patient Name:	: Mrs.Bina Mondal		
Age / Gender	: 39 Years/ Female		

MEASUREMENT

AO : 28 (20 - 35)mm LVID(d) : 47 (36 - 52)mm IVS: 09 (06 -11)mm
LA : 31 (19 - 40)mm LVID s : 28 (23 - 39)mm PW: 08 (06 - 11)mm
EF : 60%

VALVES

Mitral Valve : Normal
Aortic valve : Normal
Tricuspid Valve : Normal
Pulmonary Valve : Normal

CHAMBERS

Left Atrium : Normal
Right Atrium : Normal
Left Ventricle : Normal
Right Ventricle : Normal

SEPTAE

IVS : Intact
IAS : Intact

GREAT ARTERIES

Aorta : Normal
Pulmonary Artery : Normal



Patient ID : 17540000307498 **Report Date** : 27/08/2022
Patient Name : **Mrs.Bina Mondal**
Age / Gender : 39 Years/ Female

WALL MOTION ABNORMALITIES

No RWMA at rest

FINAL DIAGNOSIS

No RWMA at rest
Normal LV systolic function. LVEF-60%.
Normal cardiac chambers dimension
IVC normal & collapsing >50% with respiratory variation.
No I/C clot, vegetation or pericardial effusion

S.Gouniyal

Dr. S.Gouniyal
MD, DM
Senior interventional Cardiologist

Dr. JINESH JAIN
MD, DM
Consultant, interventional Cardiology



DR. PRASHAMI MADHARIA
MD, PGCC
Consultant Non-Invasive Cardiology