



Dr. NITIN AGARWAL
MBBS, MD
Regn. No. DMC-R-1436

ONEPLUS ULTRASOUND LAB
47 Harsh Vihar, Pitam Pura,
Delhi 110034
Ph. 011-42480101, 9599913051
E-mail: oneplusul@gmail.com



Synthesis

[Signature]
Dr. NITIN AGARWAL
MBBS, MD
Regn. No. DMC-R-1436



ONEPLUS ULTRASOUND LAB
47 Harsh Vihar, Pitam Pura,
Delhi-110034
Ph. 011-42480101, 9599913051
E-mail onepusul@gmail.com

Name	: Mr. SUSHIL KUMAR	Age/Sex	: 44 YRS/Male
Ref. By	: Dr. MEDIWHEEL	Lab No	: 012402240004
Date	: 24-Feb-2024	Patient ID	: LSHHI130584

ULTRASOUND EXAMINATION---WHOLE ABDOMEN

Liver is normal in size (12.6 cm) and outline with normal altered echopattern. **Diffuse increase in echogenicity of liver parenchyma is noted, suggestive of fatty infiltration (grade I).** No abscess or mass lesion seen. Hepatic veins, portal vein, IVC and aorta are normal. Intrahepatic biliary radicles are not dilated. CBD is normal in caliber.

Gall bladder is well distended with anechoic lumen. Wall thickness is normal.

Both kidneys are normal in size, shape, position, outline and echopattern. Corticomedullary differentiation is maintained. No pelvicalyceal dilation or calculus or mass lesion is seen.

Renal measurements are --

Rt. kidney – 9.3 x 4.1 cm.

Lt. kidney – 10.6 x 4.5 cm.

Spleen is normal in size (9.8 cm) and echotexture. No mass lesion seen.

Pancreas is normal in size, outline and echotexture.

Urinary bladder is normal in shape and position. No evidence of intravesical stone or mass seen.


Prostate is normal in size, shape and echopattern.

Prostate measures 4.2 x 3.5 x 3.2 cm. **Weight of prostate is 24.6 grams.**

No abnormal bowel wall thickening seen in right iliac fossa.

No free fluid seen anywhere in abdomen.

IMPRESSION: Fatty infiltration of liver (grade I) with no hepatomegaly.


DR. RASHMI BANSAL
RADIOLOGIST
REG. NO. DMC/R/10067

Dr. RASHMI BANSAL
Radiologist
Reg. No. DMC/R/10067

Type By : sangeeta

47, Harsh Vihar, Pitampura, Delhi-34 ☎ 011-4248 0101, 9599913051

✉ Email: oneplusul@gmail.com 🌐 www.oneplusul.in

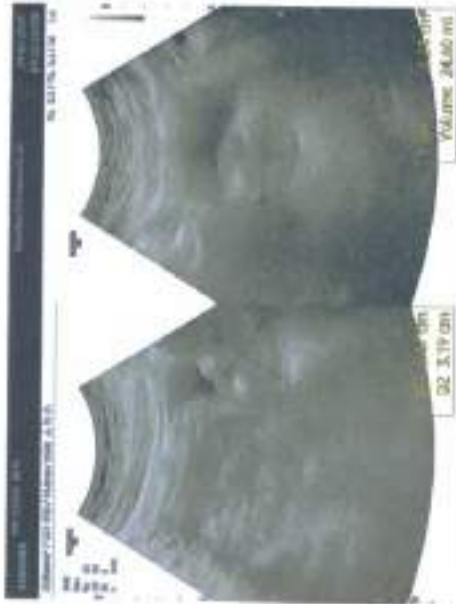




TABLE I. Properties of the Polymers



Fig. 1. Infrared spectrum of the polymer.



Fig. 2. Infrared spectrum of the polymer.



TABLE II. Properties of the Polymers



Fig. 3. Infrared spectrum of the polymer.



Fig. 4. Infrared spectrum of the polymer.



TABLE III. Properties of the Polymers



Fig. 5. Infrared spectrum of the polymer.



Fig. 6. Infrared spectrum of the polymer.





OnePLUS
Ultrasound Lab
— QUALITY FIRST... ALWAYS! —

Dr. Nitin Agarwal

Pathologist & Director
MBBS, MD, FAGE
Ex. Chief of Lab
Dr. Lal Path labs.

Dr. Pooja (Garg) Agarwal

Radiologist & Director
MBBS (MAMC) DMRD (MAMC)
Imaging Expert in Fetal And Maternal Medicine,
University of Barcelona, Spain
Fetal Medicine Foundation (UK) Accreditation

दिनांक

24/02/24

सेवा में

ONEPLUS ULTRASOUND में प्रेषित हुआ

PP Blood Sugar को STOLE का टेस्ट रीपोर्ट का

2एट है।

Sugar

DR. NITIN AGARWAL
MBBS, MD
Regn. No. DMC-R-1436

47, Harsh Vihar, Pitampura, Delhi-34 ☎ 011-4248 0101, 9599913051

✉ Email: oneplusul@gmail.com 🌐 www.oneplusul.in

- Clinical correlation is essential for final diagnosis. • If test results are unsatisfactory please contact personally or on phone.
- This report is for perusal of doctors only. • All disputes are subject to Delhi jurisdiction only. • Not for medico legal case.
- All congenital anomalies in a foetus may not be diagnosed in routine obstetric ultrasound.

Name	: Mr. SUSHIL KUMAR	Age/Sex	: 44 YRS/Male
Ref. By	: Dr. MEDIWHEEL	Lab No	: 012402240005
Date	: 24-Feb-2024	Patient ID	: LSHHI130585

X-ray-Chest PA view

Bony cage and soft tissues are normal.

Cardiothoracic ratio is normal.

Mediastinum is normal.


Both hila are normal.

Both costophrenic angles are clear.

Both domes of diaphragm are normal.

Lung fields are clear. No parenchymal lesion seen.

IMPRESSION: Normal Study.


DR. RASHMI BANSAL
RADIOLOGIST
REG. NO. DMC/R/10067

Dr. RASHMI BANSAL
Radiologist
Reg. No. DMC/R/10067

Type By : sangeeta

47, Harsh Vihar, Pitampura, Delhi-34 ☎ 011-4248 0101, 9599913051

✉ Email: oneplusul@gmail.com 🌐 www.oneplusul.in



NAME	:Mr. SUSHIL KUMAR	Barcode No	:10165511
AGE/GENDER	:44 YRS/Male	SPECIMEN DATE	:24/Feb/2024 08:25AM
PATIENT ID	:130585	SPECIMEN RECEIVED	:24/Feb/2024 08:41AM
REFERRED BY	:Dr. MEDIWHEEL	REPORT DATE	:24/Feb/2024 03:06PM
CENTRE NAME	:ONEPLUS ULTRASOUND LAB	LAB NO.	:012402240005

Test Name	Result	Unit	Ref. Range
-----------	--------	------	------------

HAEMATOLOGY

MediWheel Health Checkup >40 Male

Sample Type: EDTA Blood

Glycosylated Hemoglobin (HbA1c)
HPLC

5.8

%

Non Diabetic adults <5.7
Prediabetic (at risk) 5.7-6.4
Diabetes >6.4

Estimated average blood glucose (eag)
CALCULATED

120

Reference range (mg/dl):

90 - 120:Excellent control, 121 - 150:Good Control, 151 - 180:Average Control, 181 - 210:Action Suggested

>211:Panic value

Dr. NITIN AGARWAL
MBBS, MD
Regn. No. DMC-R-1436



DR. NITIN AGARWAL
MBBS,MD(PATHOLOGIST)

Checked By.

47, Harsh Vihar, Pitampura, Delhi-34 ☎ 011-4248 0101, 9599913051

✉ Email: oneplusul@gmail.com 🌐 www.oneplusul.in

Page 1 of 9



OnePLUS
Ultrasound Lab
— QUALITY FIRST... ALWAYS! —

Dr. Nitin Agarwal

Pathologist & Director
MBBS, MD, FAGE
Ex. Chief of Lab
Dr. Lal Path labs.

Dr. Pooja (Garg) Agarwal

Radiologist & Director
MBBS (MAMC) DMRD (MAMC)
Imaging Expert in Fetal And Maternal Medicine,
University of Barcelona, Spain
Fetal Medicine Foundation (UK) Accreditation



NAME	:Mr. SUSHIL KUMAR	Barcode No	:10165511
AGE/GENDER	:44 YRS/Male	SPECIMEN DATE	:24/Feb/2024 08:25AM
PATIENT ID	:130585	SPECIMEN RECEIVED	:24/Feb/2024 08:41AM
REFERRED BY	:Dr. MEDIWHEEL	REPORT DATE	:24/Feb/2024 03:06PM
CENTRE NAME	:ONEPLUS ULTRASOUND LAB	LAB NO.	:012402240005

Test Name	Result	Unit	Ref. Range
-----------	--------	------	------------

HAEMATOLOGY

BLOOD GROUP (ABO)

Forward and Reverse grouping (Slide & Tube)

B

Rh typing

POSITIVE

NOTE :

- * Apart from major A,B,H antigens which are used for ABO grouping and Rh typing, many minor blood group antigens exist. Agglutination may also vary according to titre of antigen and antibody.
- * So before transfusion, reconfirmation of blood group as well as cross-matching is needed.
- * Presence of maternal antibodies in newborns, may interfere with blood grouping.
- * Auto agglutination (due to cold antibody, falciparum malaria, sepsis, internal malignancy etc.) may also cause erroneous result.

Checked By.

Dr. NITIN AGARWAL
MBBS, MD
Reg. No. BPC-A-1436

DR. NITIN AGARWAL
MBBS, MD (PATHOLOGIST)

47, Harsh Vihar, Pitampura, Delhi-34 ☎ 011-4248 0101, 9599913051

✉ Email: oneplusul@gmail.com 🌐 www.oneplusul.in

Page 2 of 9

- Clinical correlation is essential for final diagnosis. • If test results are unsatisfactory please contact personally or on phone.
- This report is for perusal of doctors only. • All disputes are subject to Delhi jurisdiction only. • Not for medico legal case.
- All congenital anomalies in a foetus may not be diagnosed in routine obstetric ultrasound.



NAME	:Mr. SUSHIL KUMAR	Barcode No	:10165511
AGE/GENDER	:44 YRS/Male	SPECIMEN DATE	:24/Feb/2024 08:25AM
PATIENT ID	:130585	SPECIMEN RECEIVED	:24/Feb/2024 08:41AM
REFERRED BY	:Dr. MEDIWHEEL	REPORT DATE	:24/Feb/2024 03:06PM
CENTRE NAME	:ONEPLUS ULTRASOUND LAB	LAB NO.	:012402240005

Test Name	Result	Unit	Ref. Range
-----------	--------	------	------------

HAEMATOLOGY

CBC

Haemoglobin Non cyanide Hb analysis	14.3	g/dl	13.0-17.0
Total Leucocyte Count Electrical Impedance	5700	/cumm	4000-10000
Differential leucocyte count			
Neutrophils Electrical Impedance & Microscopic	64.4	%	40-80
Lymphocyte Electrical Impedance & Microscopic	30.80	%	20-40
Monocytes Electrical Impedance & Microscopic	2.00	%	2-10
Eosinophils Electrical Impedance & Microscopic	2.0	%	1-6
Basophils Electrical Impedance & Microscopic	0.8	%	0-2
RBC Count Electrical Impedance	5.00	million/cumm	4.5 - 5.5
Hematocrit(PCV) Flow Cytometry	44.2	%	40-50
MCV Calculated	88	fL	83-101
MCH Calculated	28.6	pg	27-32
MCHC Calculated	32.5	g/dL	31.5-34.5
RDW-CV Calculated	14.8	%	11.4-14.0
Platelet count Electrical Impedance	152000	/cumm	150000-410000

BIOCHEMISTRY

Sample Type:Fluoride F			
Blood sugar fasting GOD-POD	109	mg/dl	70-100 mg/dl

Checked By.

Dr. NITIN AGARWAL
MBBS, MD
Regn. No. DMC-R-1436
DR. NITIN AGARWAL
MBBS,MD(PATHOLOGIST)

47, Harsh Vihar, Pitampura, Delhi-34 ☎ 011-4248 0101, 9599913051

✉ Email: oneplusul@gmail.com 🌐 www.oneplusul.in

Page 3 of 9

• Clinical correlation is essential for final diagnosis. • If test results are unsatisfactory please contact personally or on phone.
• This report is for perusal of doctors only. • All disputes are subject to Delhi jurisdiction only. • Not for medico legal case.
• All congenital anomalies in a foetus may not be diagnosed in routine obstetric ultrasound.



NAME	:Mr. SUSHIL KUMAR	Barcode No	:10165511
AGE/GENDER	:44 YRS/Male	SPECIMEN DATE	:24/Feb/2024 08:25AM
PATIENT ID	:130585	SPECIMEN RECEIVED	:24/Feb/2024 08:41AM
REFERRED BY	:Dr. MEDIWHEEL	REPORT DATE	:24/Feb/2024 03:06PM
CENTRE NAME	:ONEPLUS ULTRASOUND LAB	LAB NO.	:012402240005

Test Name	Result	Unit	Ref. Range
Sample Type: Serum			
Bun (blood urea nitrogen) Calculated	12.10	mg/dl	8.9-21.6
Uric Acid, serum Uricase- PAP	4.6	mg/dl	3.5-7.2
Creatinine, serum Enzymatic	0.7	mg/dl	0.71-1.16
LFT(LIVER FUNCTION TEST)			
Bilirubin Total Modified lab	0.42	mg/dl	0.2-1.1
Bilirubin Conjugated Diazotized sulfanilic acid	0.24	mg/dL	0.11-0.42
Bilirubin Unconjugated Calculated	0.18	mg/dl	up to 0.7
SGOT (AST) Tris buffer	54	U/L	0-46
SGPT (ALT) Tris buffer	77	U/L	0-49
Alkaline phosphatase Amp buffer	95	U/L	40-129
GAMMA GT Szasz Method	27	U/L	10-45
Total Protein Biuret	6.8	gm/dl	6.60 - 8.70
Albumin serum BCG	3.9	g/dL	3.0-5.2
Globulin Calculated	2.90	gm/dl	1.8-3.4
Albumin/Globulin Ratio Calculated	1.34		1.10 - 2.50
LIPID PROFILE			
Cholesterol CHOD-PAP	238	mg/dl	50-200
Triglycerides GPO-PAP	134	mg/dL	25-150
HDL Cholesterol Selective Inhibition	46	mg/dL	40 - 60

Checked By.

Dr. NITIN AGARWAL
MBBS, MD
Regn. No. DMC-R-1436

DR. NITIN AGARWAL
MBBS, MD (PATHOLOGIST)

47, Harsh Vihar, Pitampura, Delhi-34 ☎ 011-4248 0101, 9599913051

✉ Email: oneplusul@gmail.com 🌐 www.oneplusul.in

Page 4 of 9

- Clinical correlation is essential for final diagnosis. • If test results are unsatisfactory please contact personally or on phone.
- This report is for perusal of doctors only. • All disputes are subject to Delhi jurisdiction only. • Not for medico legal case.
- All congenital anomalies in a foetus may not be diagnosed in routine obstetric ultrasound.



NABL
MC - 6036



NAME	:Mr. SUSHIL KUMAR	Barcode No	:10165511
AGE/GENDER	:44 YRS/Male	SPECIMEN DATE	:24/Feb/2024 08:25AM
PATIENT ID	:130585	SPECIMEN RECEIVED	:24/Feb/2024 08:41AM
REFERRED BY	:Dr. MEDIWHEEL	REPORT DATE	:24/Feb/2024 03:06PM
CENTRE NAME	:ONEPLUS ULTRASOUND LAB	LAB NO.	:012402240005

Test Name	Result	Unit	Ref. Range
LDL cholesterol Calculated	165	mg/dL	<100
VLDL cholesterol Calculated	28.8	mg/dL	5-40
Cholesterol/HDL Ratio Calculated	5.2		Low Risk 3.3-4.97 Average Risk 4.4-7.1 Moderate Risk 7.1-11.0 High Risk >11.0
LDL/HDL Ratio Calculated	3.6		0 - 3.55

LDL Cholesterol	Total Cholesterol	HDL Cholesterol
<100 Optimal	<200 Desirable	<40 Low
100-129 Near optimal	200-239 Borderline high	>60 High
130-159 Borderline high	>240 High	
160-189 High		
>190 Very high		

According to NCEP, ATP-III Guidelines

	BUN/Creatinine ratio		
UREA	26.00	mg/dl	15-45
UREASE-GLDH	12.15	mg/dl	8.9-21.6
Bun (blood urea nitrogen) Calculated	0.70	mg/dl	0.30-1.10
CREATININE ENZYMATIC	17.36		10.0 - 20.0
Bun/Creatinine Ratio Calculated			

Checked By.

Dr. NITIN AGARWAL
MBBS, MD
DMC-R-1436
[Signature]
DR. NITIN AGARWAL
MBBS, MD (PATHOLOGIST)

47, Harsh Vihar, Pitampura, Delhi-34 ☎ 011-4248 0101, 9599913051

✉ Email: oneplusul@gmail.com 🌐 www.oneplusul.in

Page 5 of 9



OnePLUS

Ultrasound Lab

— QUALITY FIRST... ALWAYS! —

Dr. Nitin Agarwal

Pathologist & Director
MBBS, MD, FAGE
Ex. Chief of Lab
Dr. Lal Path labs.

Dr. Pooja (Garg) Agarwal

Radiologist & Director
MBBS (MAMC) DMRD (MAMC)
Imaging Expert In Fetal And Maternal Medicine
University of Barcelona, Spain
Fetal Medicine Foundation (UK) Accreditation



NAME	:Mr. SUSHIL KUMAR	Barcode No	:10165511
AGE/GENDER	:44 YRS/Male	SPECIMEN DATE	:24/Feb/2024 08:25AM
PATIENT ID	:130585	SPECIMEN RECEIVED	:24/Feb/2024 08:41AM
REFERRED BY	:Dr. MEDIWHEEL	REPORT DATE	:24/Feb/2024 03:06PM
CENTRE NAME	:ONEPLUS ULTRASOUND LAB	LAB NO.	:012402240005

Test Name	Result	Unit	Ref. Range
<p>1. Primary hypothyroidism is accompanied by depressed serum T3 and T4 values and elevated serum TSH level. 2. Primary hyperthyroidism is accompanied by elevated serum T3 and T4 levels along with depressed TSH values. 3. Slightly elevated T3 levels may be found in pregnancy and estrogen therapy, while depressed levels may be encountered in severe illness, renal failure and during therapy with drugs like propranolol and propyl thiouracil. 4. Although elevated TSH levels are nearly always indicative of primary hypothyroidism, and may be seen in secondary thyrotoxicosis</p>			

Checked By.

DR. NITIN AGARWAL
MBBS, MD (PATHOLOGIST)

Dr. Nitin Agarwal
Regn. No. DMC-R-1436

47, Harsh Vihar, Pitampura, Delhi-34 ☎ 011-4248 0101, 9599913051

✉ Email: oneplusul@gmail.com 🌐 www.oneplusul.in

Page 7 of 9

• Clinical correlation is essential for final diagnosis. • If test results are unsatisfactory please contact personally or on phone.
 • This report is for perusal of doctors only. • All disputes are subject to Delhi jurisdiction only. • Not for medico legal case.
 • All congenital anomalies in a foetus may not be diagnosed in routine obstetric ultrasound.



NAME	:Mr. SUSHIL KUMAR	Barcode No	:10165511
AGE/GENDER	:44 YRS/Male	SPECIMEN DATE	:24/Feb/2024 08:25AM
PATIENT ID	:130585	SPECIMEN RECEIVED	:24/Feb/2024 08:41AM
REFERRED BY	:Dr. MEDIWHEEL	REPORT DATE	:24/Feb/2024 03:06PM
CENTRE NAME	:ONEPLUS ULTRASOUND LAB	LAB NO.	:012402240005

Test Name	Result	Unit	Ref. Range
-----------	--------	------	------------

CLINICAL PATHOLOGY

URINE ROUTINE (Strip/microscopy)

Sample Type:Urine

Physical examination

Colour	PALE YELLOW	PALE YELLOW
Transparency	CLEAR	CLEAR
Sp.gravity	1.015	1.005-1.030
BROMOTHYMOL BLUE		
pH	6.00	5.0-8.0
Double indicators Test		
Reaction	ACIDIC	ACIDIC

Chemical examination

Urine protein	NIL	NIL
Protein Ionization		
Urine sugar	NIL	NIL
Oxidation Reaction		
Bilirubin, urine	NEGATIVE	NEGATIVE
Urobilinogen	NORMAL	NORMAL
P-Aminobenzoic Acid and Phenazopyridine Reaction		
Ketones	NEGATIVE	NEGATIVE
Acetoacetate and Dichlorobenzene Reaction		

Microscopic examination

Pus cells.	2-3	/HPF	0-2
Microscopy			
Epithelial cells	1-2	/HPF	NIL
Microscopy			
R.B.C.	NIL	/HPF	NIL
Microscopy			
Casts	NIL	/HPF	NIL
Microscopy			
Crystals	NIL	/HPF	NIL
Microscopy			
Bacteria	NIL	/HPF	NIL
Microscopy			

Checked By.

DR. NITIN AGARWAL
MBBS, MD
No. DMC-R-1436
MBBS,MD(FATHOLOGIST)

47, Harsh Vihar, Pitampura, Delhi-34 ☎ 011-4248 0101, 9599913051

✉ Email: oneplusul@gmail.com 🌐 www.oneplusul.in

Page 8 of 9




NAME	:Mr. SUSHIL KUMAR	Barcode No	:10165511
AGE/GENDER	:44 YRS/Male	SPECIMEN DATE	:24/Feb/2024 08:25AM
PATIENT ID	:130585	SPECIMEN RECEIVED	:24/Feb/2024 08:41AM
REFERRED BY	:Dr. MEDIWHEEL	REPORT DATE	:24/Feb/2024 03:06PM
CENTRE NAME	:ONEPLUS ULTRASOUND LAB	LAB NO.	:012402240005

Test Name	Result	Unit	Ref. Range
Others.	NIL	NIL	NIL

*** End Of Report ***

Checked By.


Dr. NITIN AGARWAL
MBBS, MD
Regn. No. DMC-R-1436
DR. NITIN AGARWAL
MBBS, MD (PATHOLOGIST)

47, Harsh Vihar, Pitampura, Delhi-34 ☎ 011-4248 0101, 9599913051

✉ Email: oneplusul@gmail.com 🌐 www.oneplusul.in

Page 0 of 0

ONEPLUS ULTRASOUND LAB

47, HARSH VIHAR, PITAMPURA, DELHI- 110034

Mr. SUSHIL KUMAR
Age : 44M
Ref. by MEDWHEEL
Indication1 :
Indication2 :
Indication3 :
COMMENTS : Normal ECG.

ID : 2472
HMM : 163/71
Recorded : 24-2-2024 9:02
Medication1 :
Medication2 :
Medication3 :

BPM : 72
BP : 138/98
P Axis : 86 deg
QRS Axis : 71 deg
T Axis : 62 deg

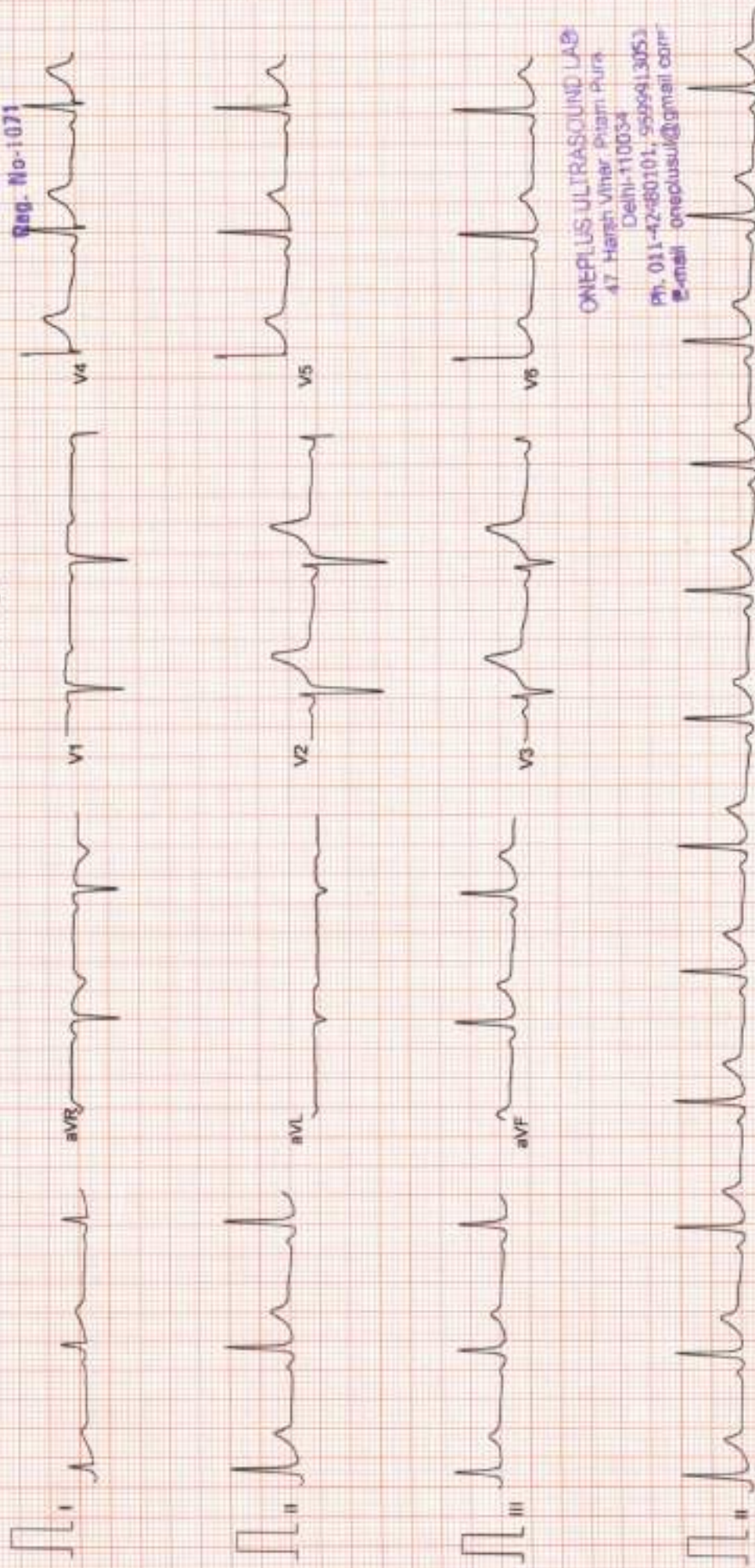
P duration : 80 msec
PR duration : 130 msec
QRS duration : 103 msec
QT interval : 326 msec
QTc interval : 347 msec

Raw E.C.G.(Seq)

Sushil Kumar
Dr. P. A. GUPTA
MBBS, MD
Reg. No-1071

Unconfirmed Report Reviewed By:

Cardiologist



ONEPLUS ULTRASOUND LAB
47, Harsh Vihar Pitam Pura
Delhi-110034
Ph. 011-42-880101, 9999413053
E-mail: oneplusul@gmail.com

ONEPLUS ULTRASOUND LAB

47, H.O. H.V. S.P.T.A. V. Jb. - 110034

Mr. SUSHIL KUMAR
Age/Sex : 44/M
Ref. by : MEDIWHEEL
Indication1 :
Indication2 :
Indication3 :

ID : 973
HMM : 153/71
Recorded : 24-2-2024 9:04

TREADMILL TEST SUMMARY REPORT
Protocol: BRUCE
History :
Medication1 :
Medication2 :
Medication3 :

PHASE	PHASE TIME	STAGE TIME	SPEED (Km./Hr.)	GRADE (%)	H.R. (BPM)	B.P. (mmHg)	RPP X100	II	ST LEVEL (mm) V2	V5	METS
SUPINE STANDING					71 70	138/86 138/86	97 96	0.7 0.7	2.2 2.1	0.9 0.9	
STAGE 1	2:59	2:59	2.70	10.00	98	138/86	135	0.4	1.7	0.7	4.80
STAGE 2	5:09	2:59	4.00	12.00	116	150/90	174	0.6	2.2	0.5	7.10
STAGE 3	8:14	2:14	5.40	14.00	153	160/92	244	-0.1	3.5	0.5	9.27
PEAK EXER	8:16	2:16			155	160/92	248	-0.2	3.4	0.6	9.30
RECOVERY	2:59	2:59	0.00	0.00	86	150/90	129	-0.2	1.1	-0.4	
RECOVERY	4:29	4:29	0.00	0.00	79	238/88	188	0.0	1.2	0.0	
RECOVERY	5:15	5:15	0.00	0.00	80	238/88	190	0.3	1.3	0.1	

RESULTS

Exercise Duration : 8:16 Minutes
Max Heart Rate : 155 bpm 86 % of target heart rate 176 bpm
Max Blood Pressure : 238/88 mmHg
Max Work Load : 9.30 METS
Reason of Termination :

Negative for ischaemic aetiology

IMPRESSIONS

Dr. P.K. GUPTA
MBBS, MD
Reg. No-1071
Cardiologist

Syultra
ONEPLUS ULTRASOUND LAB
47 Harsh Vihar, Ghum. Pura,
Delhi-110034
Ph. 011-47480101, 9999913051
E-mail oneplusul@gmail.com

ONEPLUS ULTRASOUND LAB

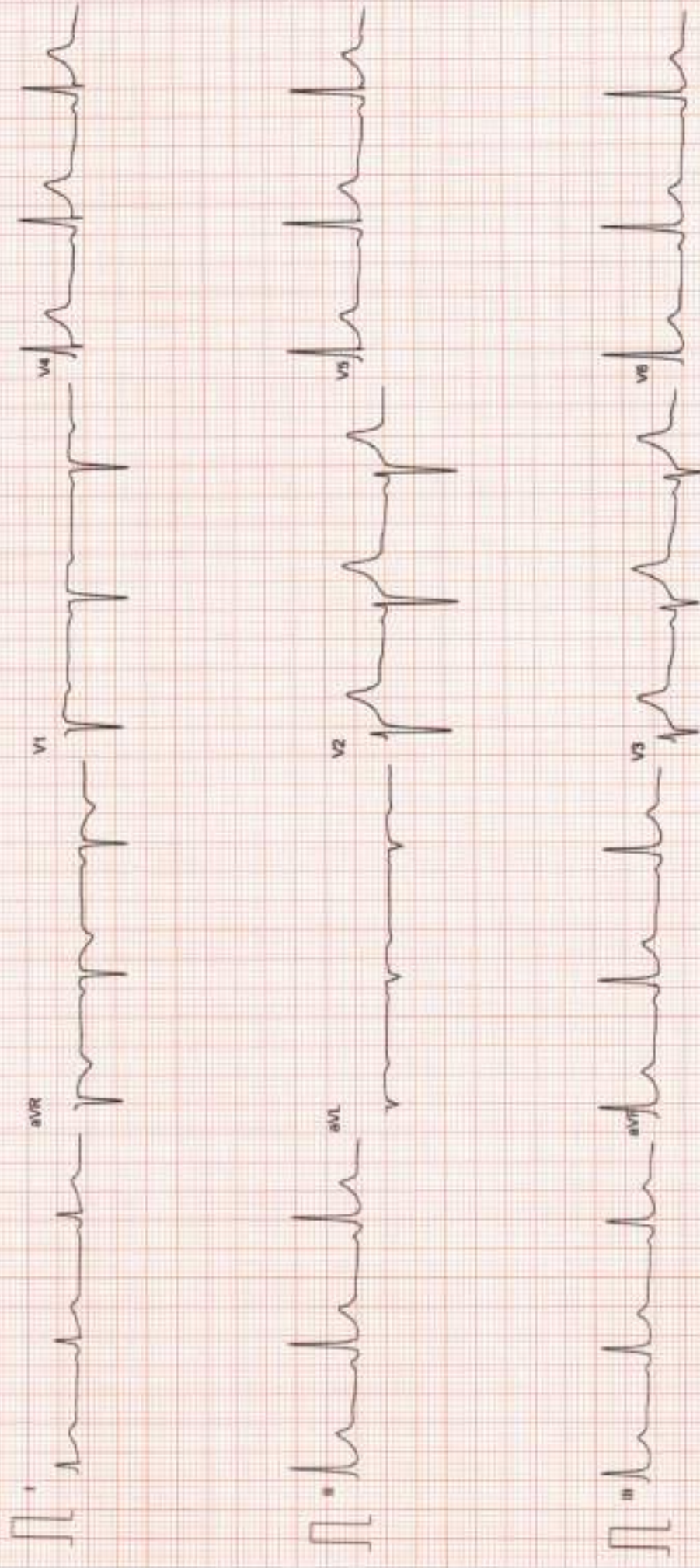
Mr. SUSHIL KUMAR
I.D. : 973
AGE/SEX : 44/M
RECORDED : 24-2-2024 9:04

RATE : 71 BPM
B.P. : 138/86 mmHg

ST @ 10mm/mV
80ms PostJ

SUPINE
PRETEST

RAW ECG.



ONEPLUS ULTRASOUND LAB
47 Harsh Vihar, Pkara Pura,
Delhi-110034
Ph. 011-47480101, 5599913051
E-mail: oneplusultrasound@gmail.com

ONEPLUS ULTRASOUND LAB

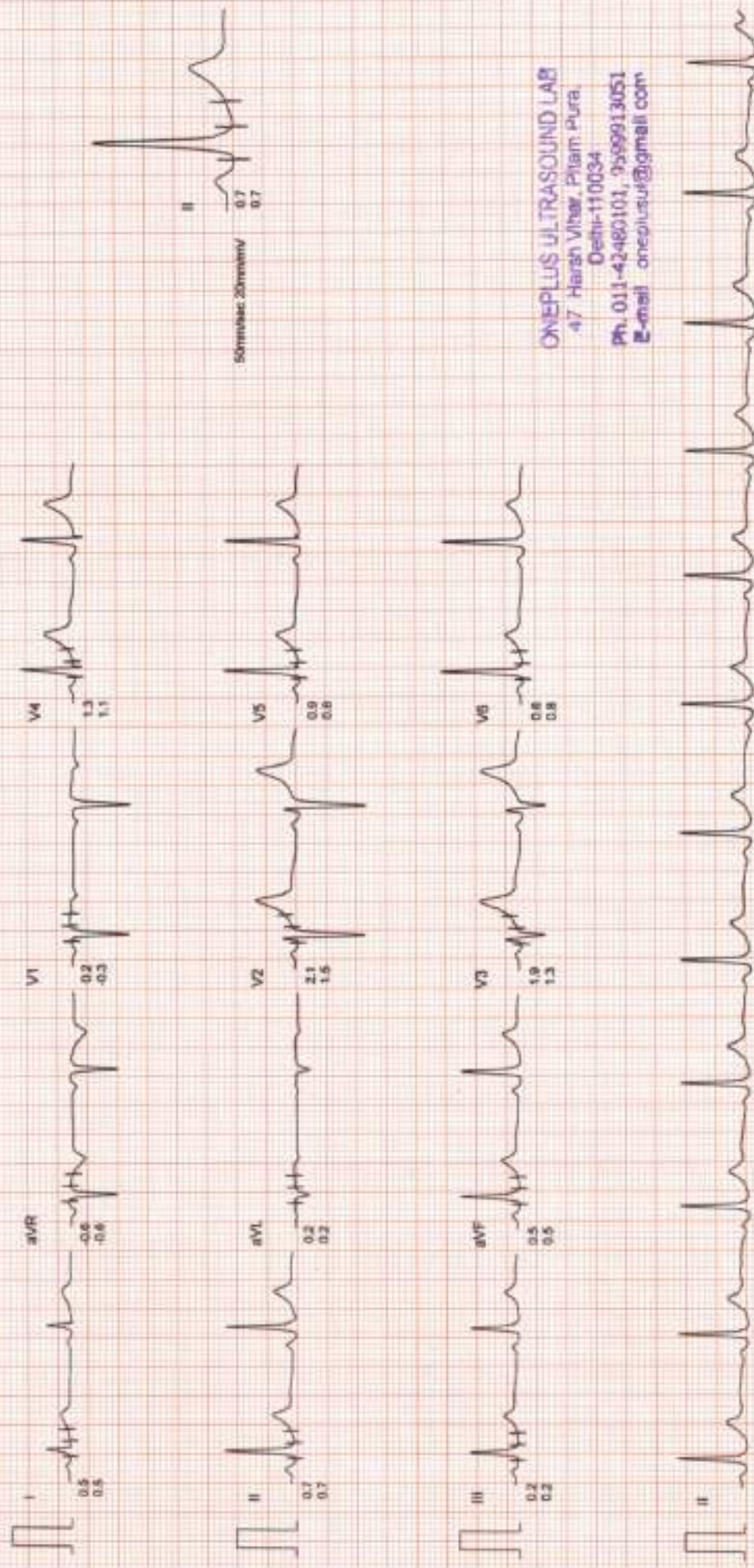
Mr. SUSHIL KUMAR
I.D. : 973
AGE/SEX : 44/M
RECORDED : 24-2-2024 9:04

RATE : 70 BPM
B.P. : 138/65 mmHg

ST 10mm/mV
60ms PostJ

STANDING
PRETEST

LINKED MEDIAN



ONEPLUS ULTRASOUND LAB
47 Harsh Vibhar, Pham Pura,
Delhi-110034
Ph. 011-42480101, 9999913051
E-mail: oneplusul@gmail.com

ONEPLUS ULTRASOUND LAB

Mr. SUSHIL KUMAR

I.D. : 973

AGE/SEX : 41/M

RECORDED : 24-2-2024 9:04

RATE : 98 BPM

B.P. : 138/86 mmHg

BRUCE

EXERCISE 1

PHASE TIME : 2:59

STAGE TIME : 2:59

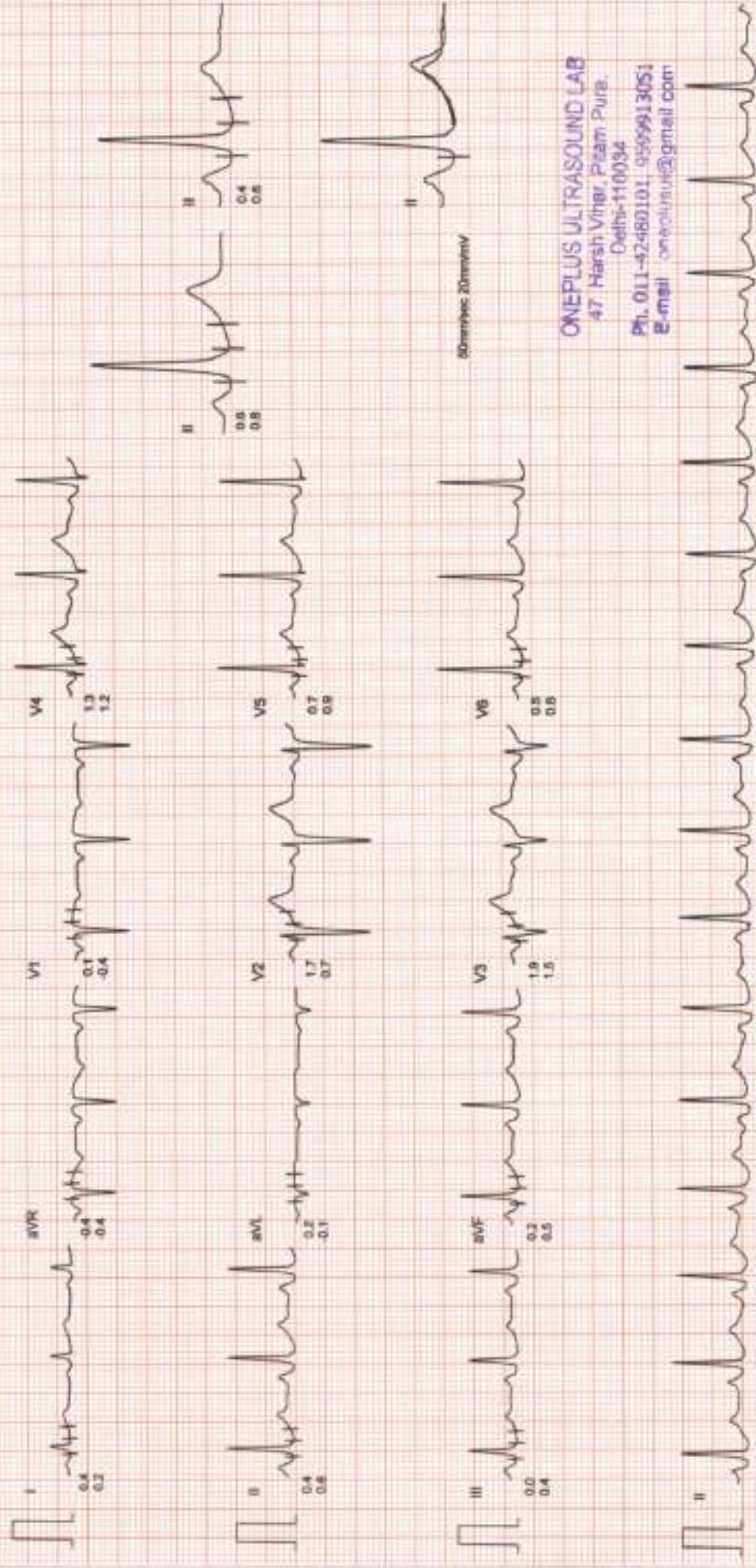
ST @ 10mm/mV

50ms PostJ

SPEED : 2.7 Km/HR.

GRADE : 10.0 %

LINKED MEDIUM



ONEPLUS ULTRASOUND LAB
47 Harsh Vihar, Pitam Pura,
Delhi-110034

Ph. 011-42480101, 9559913051
E-mail: oneplusul@oneplusul@gmail.com

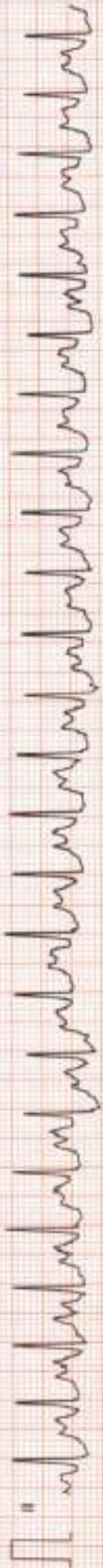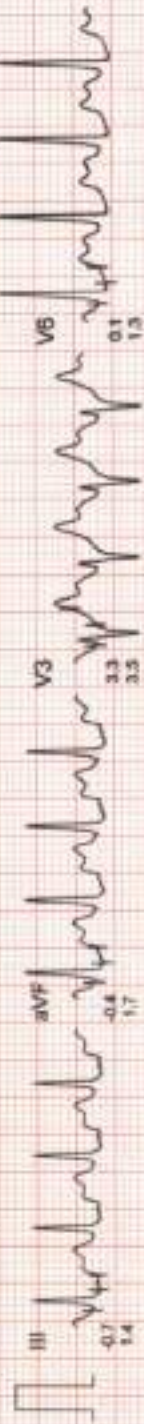
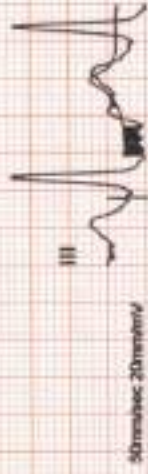

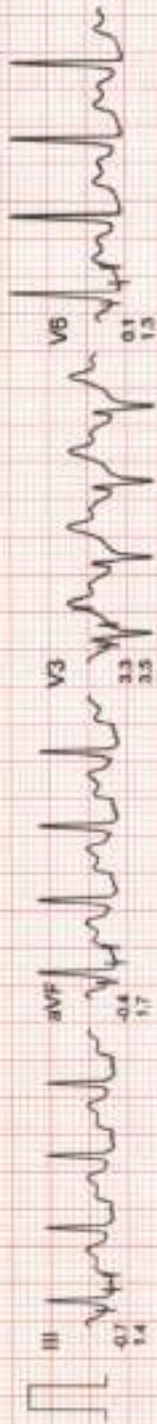
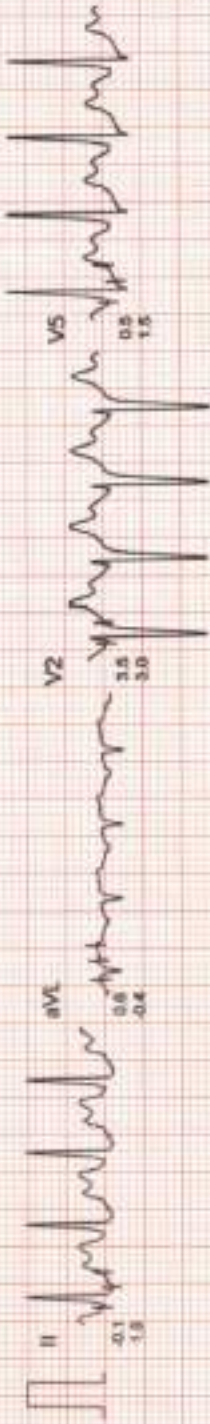
ONEPLUS ULTRASOUND

RECORDED: 24-2-2024 9:04
RATE: 13
B.P.: 160/95 mmHg

STAGE TIME: 2:14

GRADE: 1-3 %

LINKED MEDIUM



ONEPLUS ULTRASOUND LAB
47 Margh Vihar, Pitam Pura,
Delhi-110034
Ph: 011-42480101, 9599913051
E-mail: oneplusul@gmail.com

ONEPLUS ULTRASOUND LAB

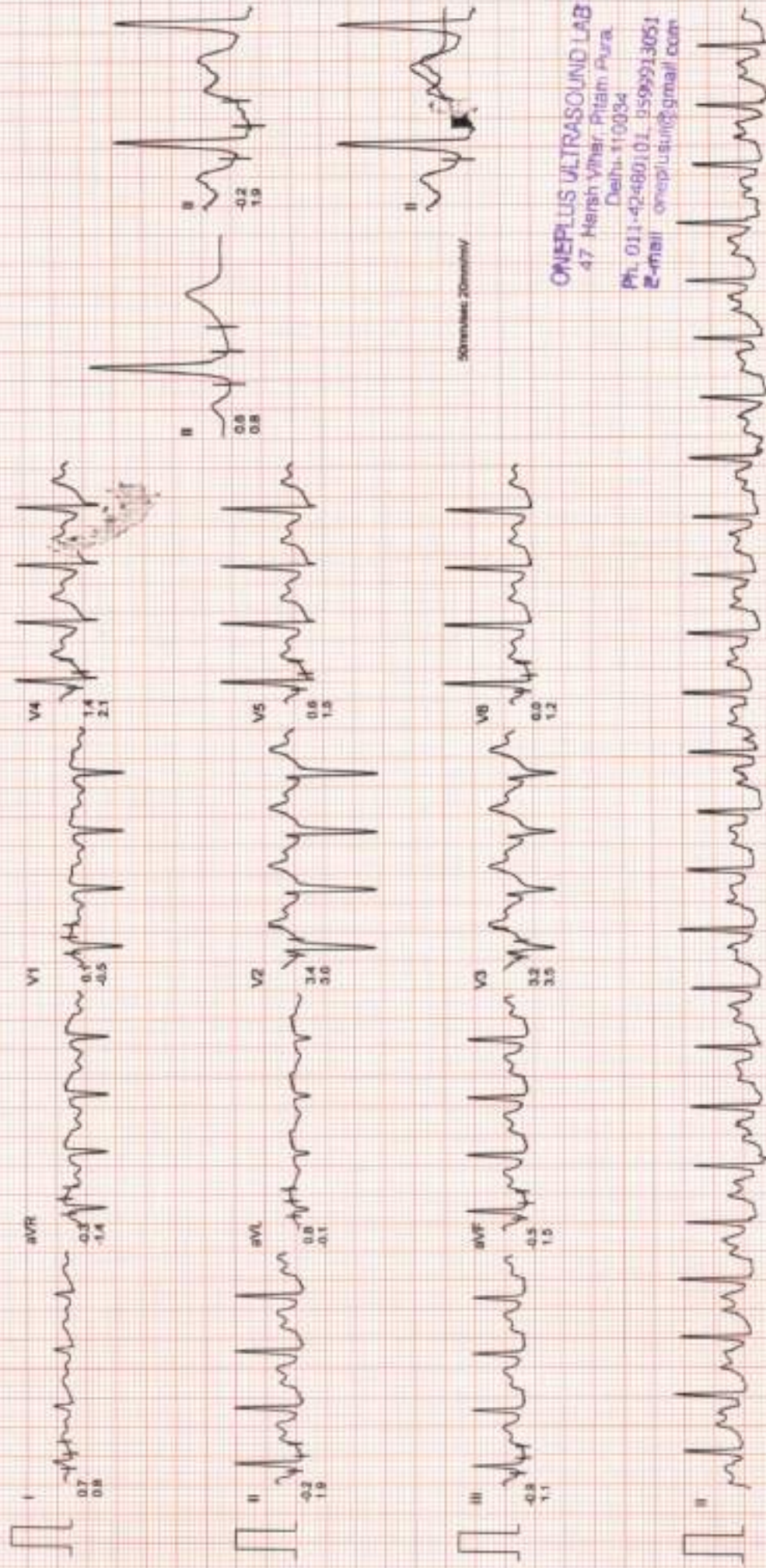
Mr. SUSHIL KU
I.D. : 973
AGE/SEX : 44/M
RECORDED : 24-2-2024 9:04

RATE : 155 BPM
B.P. : 160/92 mmHg

BRUCE
PEAK EXER
PHASE TIME : 8:16
STAGE TIME : 2:16

S. @ 10mm/mV
80ms PostJ
SPEED : 5.4 Km./Hr.
GRADE : 14.0 %

LINKED MEDIAN



ONEPLUS ULTRASOUND LAB
47 Hersh Vihar, Pitam Pura
Delhi-110034
Ph. 011-42460101, 9999913051
E-mail: oneplusultrasound@gmail.com

ONEPLUS ULTRASOUND LAB

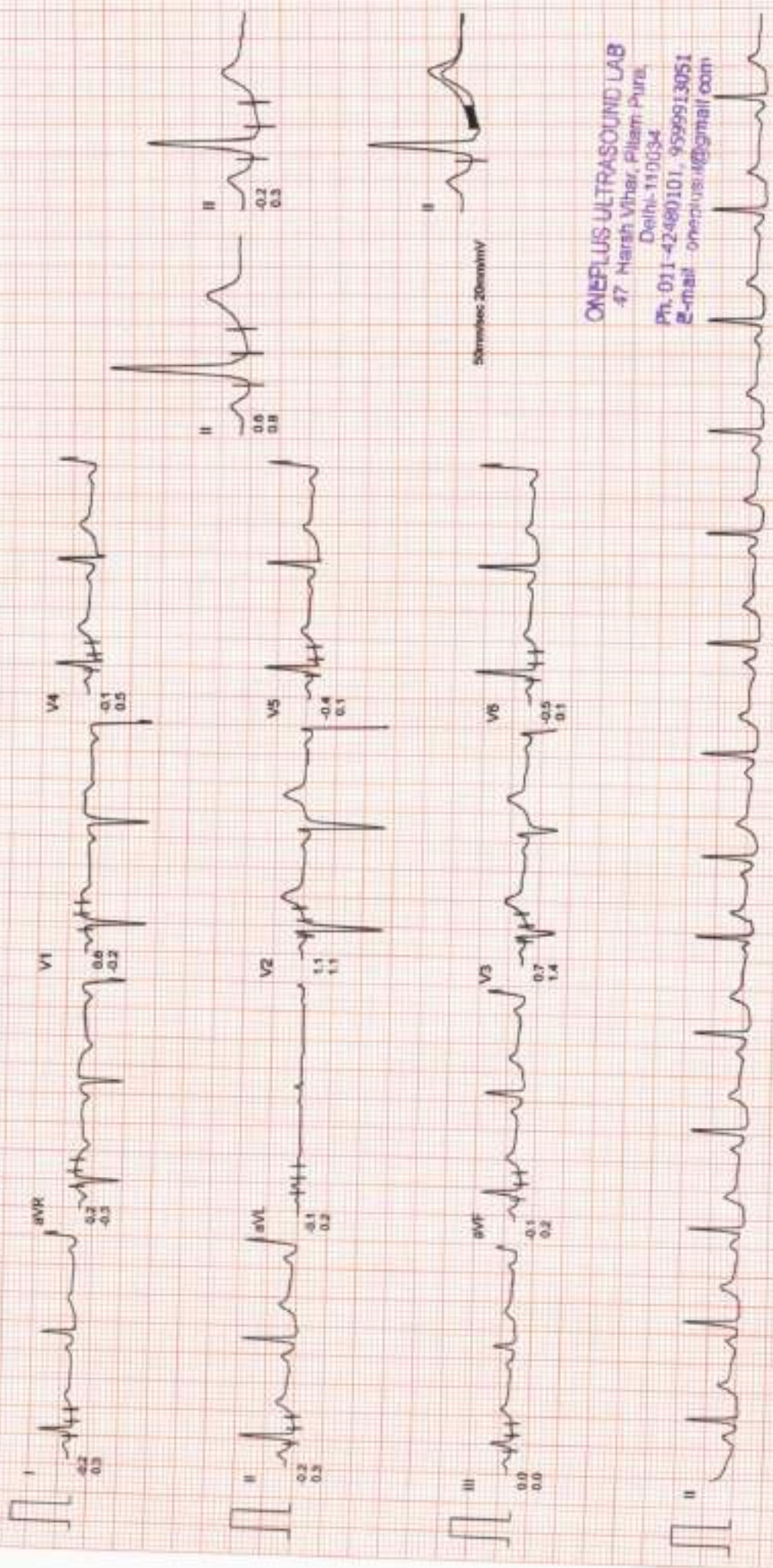
Mr. SUSHIL KUMAR
I.D. : 973
AGE/SEX : 44/M
RECORDED : 24-2-2024 9:04

BRUCE
RECOVERY
PHASE TIME : 2:59

RATE : 86 BPM
B.P. : 150/90 mmHg

ST : 0mm/mV
80ms PostJ
SPEED : 0.0 Km./Hr.
GRADE : 0.0 %

LINKED MEDIUM



ONEPLUS ULTRASOUND LAB
47 Harsh Vihar, Pitambara,
Delhi-110034
Ph. 011-42480101, 9599913051
E-mail: onepplus@gmail.com

Filtered

Computer Corrected Baseline

25mm/sec 10mm/mV

CardiCom, INDIA Ph. 091-731-2820740, TeleFax:091-731-2431214

ONEPLUS ULTRASOUND LAB

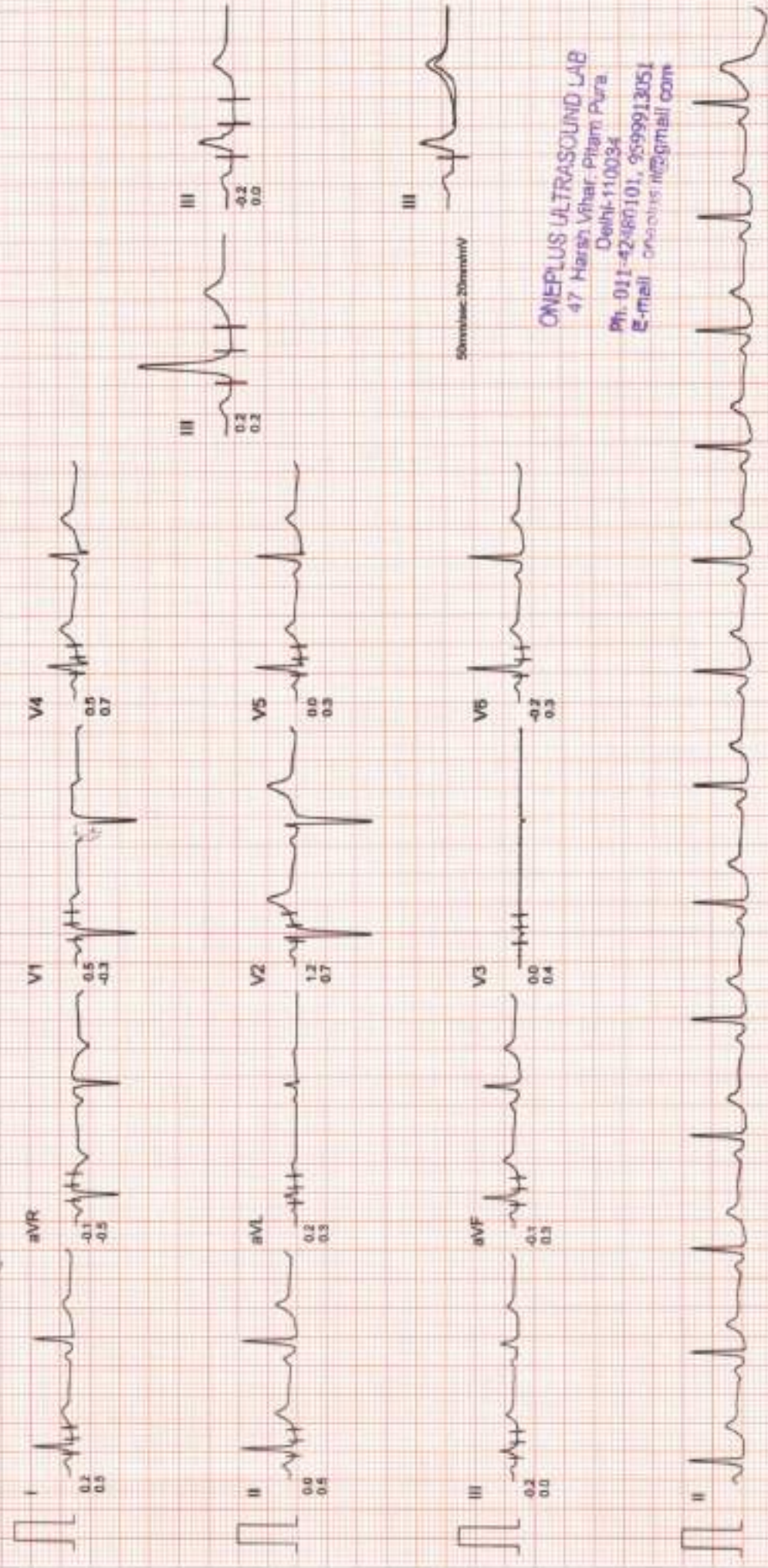
AGE/SEX: 44/M
RECORDED: 24-2-2024 9:04

RATE: 79 Bf
B.P.: 238/88 mmHg

P: AS - ME: 4.23

SpO2: 97.0 %
GR: 0.0 %

LINKED MEDIAN



ONEPLUS ULTRASOUND LAB
47 Hareh Vihar Pitam Pura
Delhi-110034
Ph: 011-42460101, 9599913051
E-mail: onepplus11@gmail.com

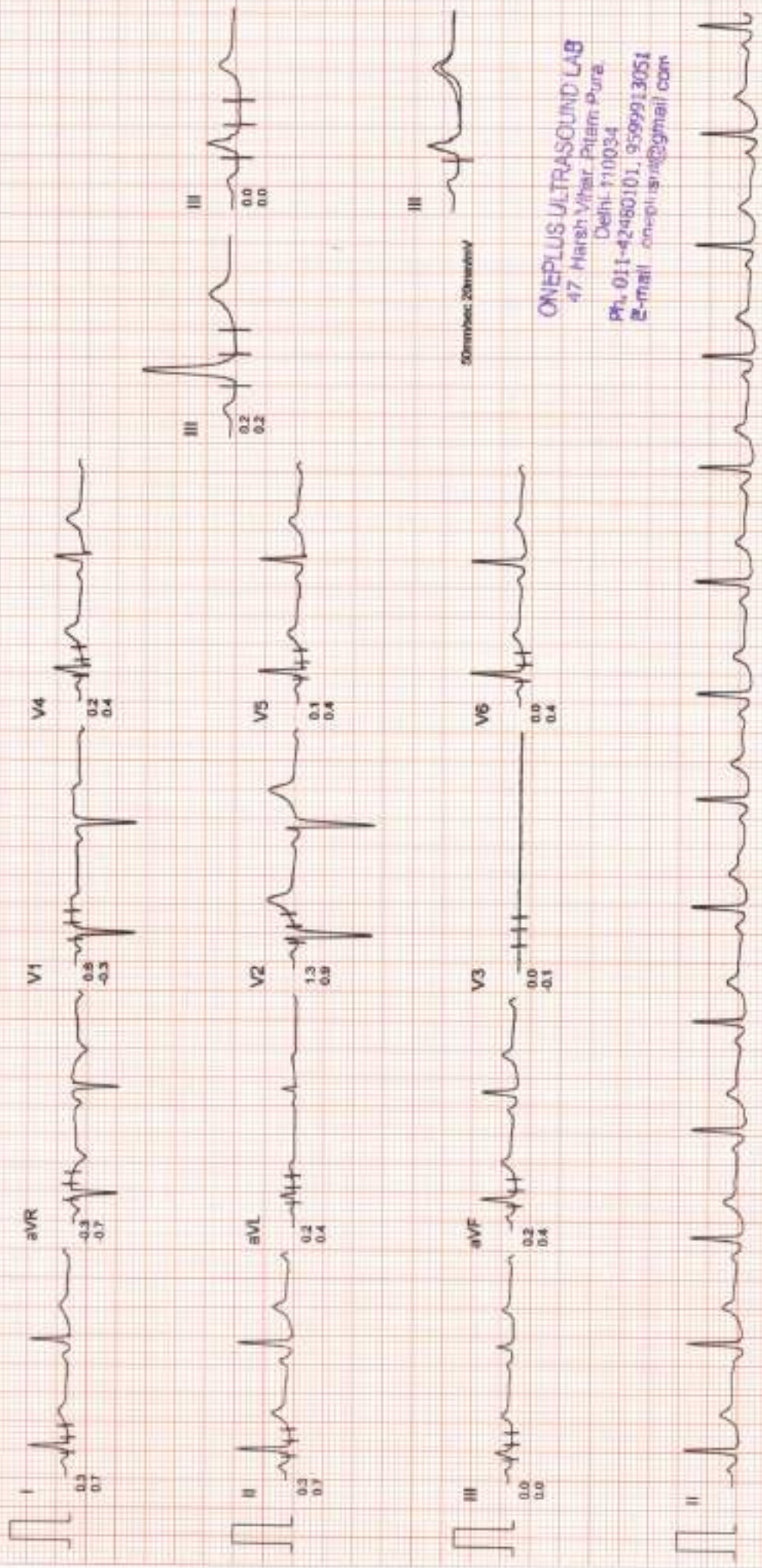
ONEPLUS ULTRASCIND AB

AGE/SEX : 44/M
RECORDED : 24-2-2024 9:04

PHASE TIME : 3:15

SPEED : 0.3 Kt./Hr.
GRADE : 0.0 %

LINKED MEDIAN



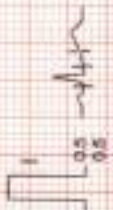



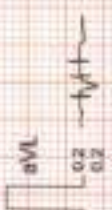
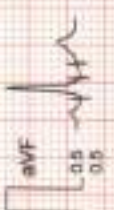
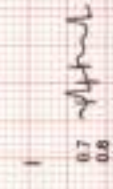


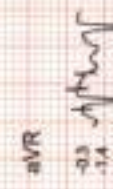
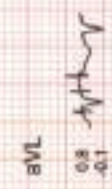
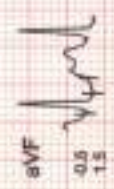



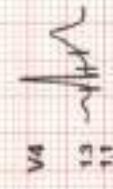
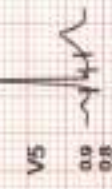
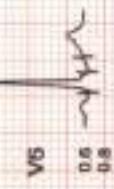
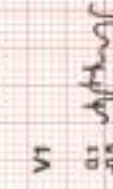


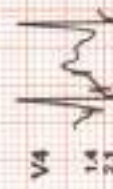
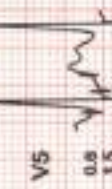
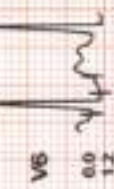
ONEPLUS ULTRASOUND LAB
47, Marsh Vihar, Pitam Pura,
Delhi-110034
Ph: 011-42460101, 9599913051
E-mail: oneplusul@gmail.com

Filtered

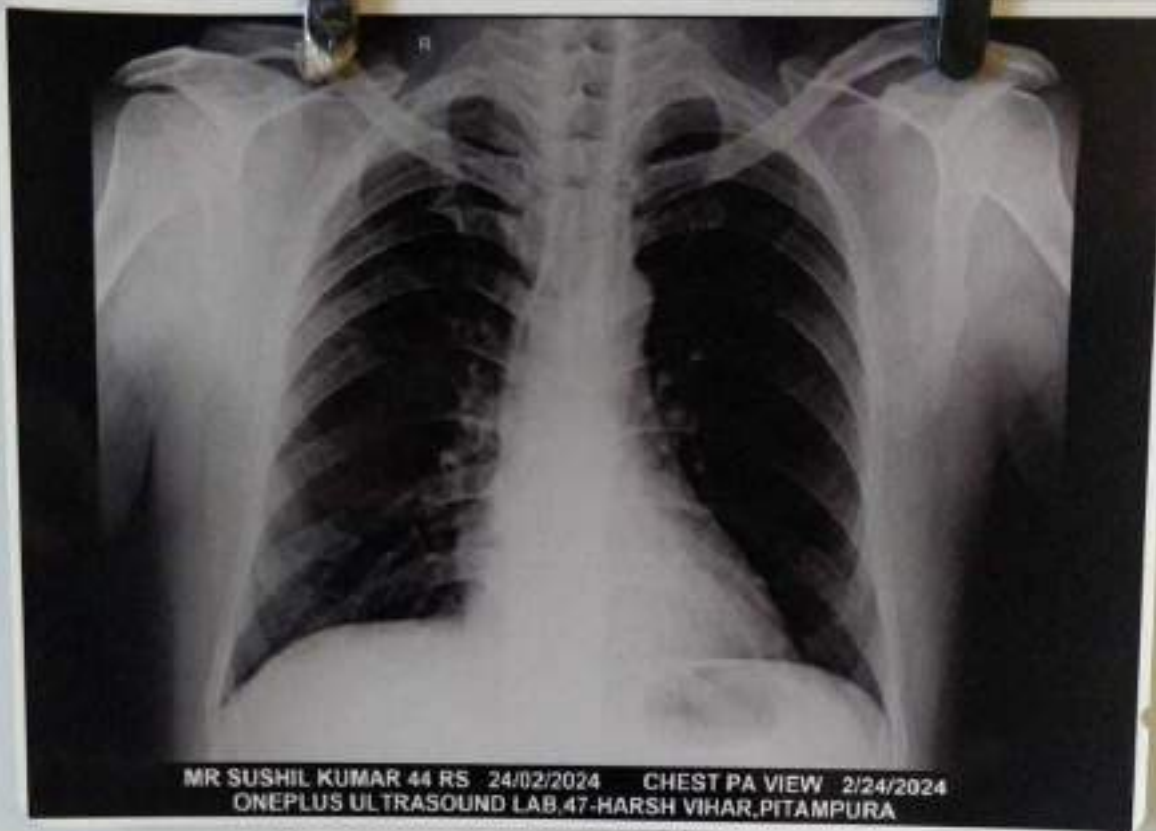Computer Corrected Baseline

25mm/sec 10mm/mV

CardiCentr. INDIA. Ph: 091-731-2620740, TeleFax: 091-731-2431214

STANDING	PEAK EXERCISE	STANDING	PEAK EXERCISE
<p>0.00mph 0.0% 70 bpm B.P. 130/85 80mm PostU</p>  <p>I 0.5 0.5</p>  <p>II 0.7 0.7</p>  <p>III 0.2 0.2</p>  <p>aVR 0.6 0.6</p>  <p>aVL 0.2 0.2</p>  <p>aVF 0.5 0.5</p>	<p>8.16 2.16 5.46 mph 14.0% 155 bpm B.P. 160/92 80mm PostU</p>  <p>I 0.7 0.6</p>  <p>II 0.2 1.8</p>  <p>III 0.9 1.1</p>  <p>aVR 0.3 0.4</p>  <p>aVL 0.8 0.1</p>  <p>aVF 0.5 1.5</p>	<p>0.00mph 0.0% 70 bpm B.P. 130/85 80mm PostU</p>  <p>V1 0.2 0.3</p>  <p>V2 2.1 1.5</p>  <p>V3 1.9 1.5</p>  <p>V4 1.3 1.1</p>  <p>V5 0.9 0.8</p>  <p>V6 0.6 0.8</p>	<p>8.16 2.16 5.46 mph 14.0% 155 bpm B.P. 160/92 80mm PostU</p>  <p>V1 0.1 0.5</p>  <p>V2 3.4 3.0</p>  <p>V3 3.2 3.5</p>  <p>V4 1.4 2.1</p>  <p>V5 0.8 1.5</p>  <p>V6 0.6 1.2</p>

ONEPLUS ULTRASOUND LAB
 47 Mergh Vihar, Pitara, Pura,
 Delhi-110034
 Ph. 011-42468710, 9599913051
 Email: oneplusultrasound@gmail.com



MR SUSHIL KUMAR 44 RS 24/02/2024 CHEST PA VIEW 2/24/2024
ONEPLUS ULTRASOUND LAB, 47-HARSH VIHAR, PITAMPURA