



ભારત સરકાર  
Government of India

ભારતીય વિશિષ્ટ ઓળખ પ્રાધિકરણ  
Unique Identification Authority of India


નોંધણીની ઓળખ / Enrollment No. : 0000/00813/74800

To  
RATHVA VIPULKUMAR RAMESHBHAI  
રાઠવા વિપુલકુમાર રમેશભાઈ  
S/O RATHVA RAMESHBHAI,  
A 13 DARSHNAM ANTILIA 2,  
DABHOI ROAD,  
SOMATALAV,  
OPP M M VORA SHOWROOM,  
VTC: Vadodara, PO: Soma Talav,  
District: Vadodara,  
State: Gujarat, PIN Code: 390025,  
Mobile: 9033370049

75013823



KF750138235FI



આપનો આધાર નંબર / Your Aadhaar No. :

**4434 7481 9338**

મારો આધાર, મારી ઓળખ



ભારત સરકાર  
Government of India



Issue Date: 06/12/2013



રાઠવા વિપુલકુમાર રમેશભાઈ  
RATHVA VIPULKUMAR RAMESHBHAI  
જન્મ તારીખ / DOB: 02/04/1987  
પુરુષ / Male

**4434 7481 9338**

મારો આધાર, મારી ઓળખ



LETTER OF APPROVAL / RECOMMENDATION

To,

The Coordinator,  
Mediwheel (Arcofemi Healthcare Limited)  
Helpline number: 011- 41195959

Dear Sir / Madam,

**Sub: Annual Health Checkup for the employees of Bank of Baroda**

This is to inform you that the following employee wishes to avail the facility of Cashless Annual Health Checkup provided by you in terms of our agreement.

PARTICULARS	EMPLOYEE DETAILS
NAME	MR. RATHVA VIPULKUMAR RAMESHBHAI
EC NO.	105283
DESIGNATION	SINGLE WINDOW OPERATOR A
PLACE OF WORK	VADODARA,SERVICE BRANCH
BIRTHDATE	02-04-1987
PROPOSED DATE OF HEALTH CHECKUP	02-12-2022
BOOKING REFERENCE NO.	22D105283100032084E

This letter of approval / recommendation is valid if submitted along with copy of the Bank of Baroda employee id card. This approval is valid from **29-11-2022** till **31-03-2023** The list of medical tests to be conducted is provided in the annexure to this letter. Please note that the said health checkup is a **cashless facility** as per our tie up arrangement. We request you to attend to the health checkup requirement of our employee and accord your top priority and best resources in this regard. The EC Number and the booking reference number as given in the above table shall be mentioned in the invoice, invariably.

We solicit your co-operation in this regard.

Yours faithfully,

Sd/-

**Chief General Manager**  
**HRM Department**  
**Bank of Baroda**

(Note: This is a computer generated letter. No Signature required. For any clarification, please contact Mediwheel (Arcofemi Healthcare Limited))

**SUGGESTIVE LIST OF MEDICAL TESTS**

<b>FOR MALE</b>	<b>FOR FEMALE</b>
CBC	CBC
ESR	ESR
Blood Group & RH Factor	Blood Group & RH Factor
Blood and Urine Sugar Fasting	Blood and Urine Sugar Fasting
Blood and Urine Sugar PP	Blood and Urine Sugar PP
Stool Routine	Stool Routine
<b>Lipid Profile</b>	<b>Lipid Profile</b>
Total Cholesterol	Total Cholesterol
HDL	HDL
LDL	LDL
VLDL	VLDL
Triglycerides	Triglycerides
HDL / LDL ratio	HDL / LDL ratio
<b>Liver Profile</b>	<b>Liver Profile</b>
AST	AST
ALT	ALT
GGT	GGT
Bilirubin (total, direct, indirect)	Bilirubin (total, direct, indirect)
ALP	ALP
Proteins (T, Albumin, Globulin)	Proteins (T, Albumin, Globulin)
<b>Kidney Profile</b>	<b>Kidney Profile</b>
Serum creatinine	Serum creatinine
Blood Urea Nitrogen	Blood Urea Nitrogen
Uric Acid	Uric Acid
HBA1C	HBA1C
Routine urine analysis	Routine urine analysis
USG Whole Abdomen	USG Whole Abdomen
<b>General Tests</b>	<b>General Tests</b>
X Ray Chest	X Ray Chest
ECG	ECG
2D/3D ECHO / TMT	2D/3D ECHO / TMT
Stress Test	Thyroid Profile (T3, T4, TSH)
PSA Male (above 40 years)	Mammography (above 40 years) and Pap Smear (above 30 years).
Thyroid Profile (T3, T4, TSH)	Dental Check-up consultation
Dental Check-up consultation	Physician Consultation
Physician Consultation	Eye Check-up consultation
Eye Check-up consultation	Skin/ENT consultation
Skin/ENT consultation	Gynaec Consultation



बैंक ऑफ बड़ौदा  
Bank of Baroda

नाम  
Name  
विपुलकुमार राठवा  
VIPULKUMAR RATHVA  
कर्मचारी कूट क्र.  
E.C. No. 105283



जारीकर्ता प्राधिकारी  
Issuing Authority

V. R. Rathva

धारक के हस्ताक्षर  
Signature of Holder



# Savita

**Superspeciality Hospital**  
(A Unit of Solace Healthcare Pvt. Ltd.)

Parivar Char Rasta, Waghodia-Dabhoi Ring Road, Vadodara-390019

☎ 0265-2578844 / 2578849 ✉ mh@savitahospital.com 🌐 savitahospital.com

## Examination By Ophthalmologist

**NAME:- VIPULKUMAR RATHVA**

**Age:35/MALE**

**Reg.No: 20221206683**

**DOE: 02/12/2022**

**Present Complaints: NAD**

**Medical History: NAD**

**Examination Of Eye: Right Left**

**External Examination : WNL WNL**

**Anti Seg Examination: RRRL RRRL**

**Schiotz Tonometry IOP: RRL RRRL**

**Fundus: NIL**

**Without Glass Distant Vision: WNL\_\_\_\_\_ WNL**

**Near Vision: \_\_\_\_\_**

**With Glass Distant Vision: 6/6 -1.75 DSPH \_\_\_\_\_ 6/6 -1.75 DSPH**

**Near VISION : \_\_\_\_\_ N6 \_\_\_\_\_**

**Colour Vision (With Ishihara Chart): WNL**

**Advice: NAD**

**DR CHETAN CHAUHAN**



CANON RK-F2  
02/DEC/2022 11:56  
No. : 003284  
NAME : \_\_\_\_\_ M/F

<RIGHT>  
[REF] VD: 13.5  
SPH CYL AX  
-1.75 -0.25 139

<LEFT >  
[REF]  
-1.75 0.00 180  
-2.00 0.00 180  
-2.25 0.00 180  
[-2.00 0.00 180]

PD : 62 mm

SOLACE HEALTH CARE  
WAGHODIA ROAD,  
VADODARA.



# Savita

**Superspeciality Hospital**  
(A Unit of Solace Healthcare Pvt. Ltd.)

Parivar Char Rasta, Waghodia-Dabhoi Ring Road, Vadodara-390019

☎ 0265-2578844 / 2578849 ✉ mh@savitahospital.com 🌐 savitahospital.com

## PHYSICIAN EXAMINATION

**Name:-VIPULKUMAR RATHVA**

**Age: 35/MALE**

**Reg.No: 20221206683**

**DOE: 02/12/2022**

### **Physical Examination:**

**Height: 167 CM    Weight: 66KG**  
**BP:132/90        SPO2- 99%**

**PULSE: 88    TEMPERATURE:NORMAL**  
**BMI:23.66**

**Chief Complaint: NAD**

**Past History: NAD**

**General Examination:NAD**

**Systemic Examination: NAD**

**INVESTIGATION: NAD**


**ADVICE:-**

**\*TAB:- ROSUVAS 20MG (HS)**

**DR HIREN PATEL**





<b>Patient Name :</b>	Vipulkumar Rameshbhai Rathva	<b>Sample No. :</b>	20221211345 
<b>Patient ID :</b>	20221206683	<b>Visit No. :</b>	OPD20221219299
<b>Age / Sex :</b>	35y/Male	<b>Coll. Date :</b>	02/12/2022 08:46
<b>Consultant :</b>	DR HIREN PATEL	<b>S. Coll. Date :</b>	02/12/2022 09:14
<b>Ward :</b>	-	<b>Report Date :</b>	02/12/2022 12:16

### CBC, ESR

Investigation	Result	Normal Value
Hemoglobin :	13.2 gm/dl [L]	13.5 to 18.0 gm/dl
P.C.V. :	40 % [L]	42.0 to 52.0 %
M.C.V. :	80.2 fL	78 to 100 fL
M.C.H. :	26.5 pg [L]	27 to 31 pg
M.C.H.C. :	33 g/dl	32 to 36 g/dl
RDW :	12.4 %	11.5 to 14.0 %
RBC Count :	4.99 X 10 <sup>6</sup> / cumm	4.7 to 6.0 X 10 <sup>6</sup> / cumm
Polymorphs :	51 %	38 to 70 %
Lymphocytes :	42 %	15 to 48 %
Eosinophils :	4 %	0 to 6 %
Monocytes :	3 %	3 to 11 %
Basophils :	0 %	0.0 to 1.0 %
Total :	100	< 100 > 100
WBC Count :	6000 /cmm	4000 to 10000 /cmm
Platelets Count :	272000 / cmm	1,50,000 to 4,50,000 /cmm
ESR - After One Hour :	15 mm/hr [H]	1 to 13 mm/hr



**Dr. Mehul Desai**  
**M.B.D.C.P**  
**Reg.No.G-9521**



**Patient Name :** Vipulkumar Rameshbhai Rathva

**Sample No. :** 20221211345



**Patient ID :** 20221206683

**Visit No. :** OPD20221219299

**Age / Sex :** 35y/Male

**Coll. Date :** 02/12/2022 08:46

**Consultant :** DR HIREN PATEL

**S. Coll. Date :** 02/12/2022 09:14

**Ward :** -

**Report Date :** 02/12/2022 12:16

### Blood Group

Investigation	Result	Normal Value
<b>BLOOD GROUP :</b>		
<b>ABO</b>	O	
<b>Rh</b>	Positive	

**Dr. Mehul Desai**  
**M.B.D.C.P**  
**Reg.No.G-9521**





<b>Patient Name :</b> Vipulkumar Rameshbhai Rathva	<b>Sample No. :</b> 20221211345
<b>Patient ID :</b> 20221206683	
<b>Age / Sex :</b> 35y/Male	<b>Visit No. :</b> OPD20221219299
<b>Consultant :</b> DR HIREN PATEL	<b>Coll. Date :</b> 02/12/2022 08:46
<b>Ward :</b> -	<b>S. Coll. Date :</b> 02/12/2022 09:14
	<b>Report Date :</b> 02/12/2022 12:16

**Lipid Profile**

Investigation	Result	Normal Value
Sample :	Fasting	
Sample Type :	Normal	
Cholesterol (Chol) :	<u>273 mg/dl [H]</u>	Low risk : < 200 Moderate risk : 200 - 239 High risk : > or = 240
Triglyceride :	175 mg/dl	Normal : < 200.0 High : 200 - 499 Very High : > or = 500
HDL Cholesterol :	48 mg/dl	Low risk: >or = 60 mg/dL High risk : Up to 35 mg/dL
LDL :	<u>190 mg/dl [H]</u>	131.0 to 159.0(N) < 130.0(L) > 159.0(H)
VLDL :	35 mg/dl [H]	Up to 0 to 34 mg/dl
LDL/HDL Ratio :	3.96	Low risk : 0.5 to 3.0 Moderate risk : 3.0 to 6.0 Elevted level high > 6.0
Total Chol / HDL Ratio :	5.69	Low Risk : 3.3 to 4.4 Average Risk : 4.4 to 7.1 Moderate Risk : 7.1 to 11.0 High Risk : > 11.0
Total Lipids :	796 mg/dl [H]	400 to 700 mg/dl

**Note :-** Lipemic samples give high triglyceride value and falsely low LDL value.

**Dr. Mehul Desai**  
**M.B.D.C.P**  
**Reg.No.G-9521**



<b>Patient Name :</b>	Vipulkumar Rameshbhai Rathva	<b>Sample No. :</b>	20221211345 
<b>Patient ID :</b>	20221206683	<b>Visit No. :</b>	OPD20221219299
<b>Age / Sex :</b>	35y/Male	<b>Coll. Date :</b>	02/12/2022 08:46
<b>Consultant :</b>	DR HIREN PATEL	<b>S. Coll. Date :</b>	02/12/2022 09:14
<b>Ward :</b>	-	<b>Report Date :</b>	02/12/2022 12:16


### RENAL FUNCTION TEST

Investigation	Result	Normal Value
Creatinine :	0.7 mg/dl	0.6 - 1.4 mg/dl
Urea :	20 mg/ dl	13 - 45 mg/dl
Uric Acid :	5.7 mg/dl	3.5 - 7.2 mg/dl
Calcium :	9 mg/dl	8.5 - 10.5
Phosphorus :	4.4 mg/dl	1.5 - 6.8



**Dr.Mehul Desai**  
**M.B.D.C.P**  
**Reg.No.G-9521**



<b>Patient Name :</b>	Vipulkumar Rameshbhai Rathva	<b>Sample No. :</b>	20221211345 
<b>Patient ID :</b>	20221206683	<b>Visit No. :</b>	OPD20221219299
<b>Age / Sex :</b>	35y/Male	<b>Coll. Date :</b>	02/12/2022 08:46
<b>Consultant :</b>	DR HIREN PATEL	<b>S. Coll. Date :</b>	02/12/2022 09:14
<b>Ward :</b>	-	<b>Report Date :</b>	02/12/2022 12:16

**LFT (Liver Function Test)**

Investigation	Result	Normal Value
Total Bilirubin :	0.4 mg/dl	0.2 to 1.0 mg/dl
Direct Bilirubin :	0.1 mg/dl	0.0 to 0.2 mg/dl
Indirect Bilirubin :	0.3 mg/dl	0.0 to 0.8 mg/dl
AST (SGOT) :	21 U/L	5 to 34 U/L
ALT (SGPT) :	23 U/L	0 to 55 U/L
Total Protein (TP) :	6.8 g/dL	6.4 to 8.3, g/dl
Albumin (ALB) :	4.2 g/dl	3.5 to 5.2 g/dl
Globulin :	2.6 g/dl	2.3 to 3.5 g/dl
A/G Ratio :	1.62	
Alkaline Phosphatase (ALP) :	124 U/L	40 to 150 U/L
GAMMA GT. :	18 U/L	7 to 35 U/L



**Dr. Mehul Desai**  
**M.B.D.C.P**  
**Reg.No.G-9521**



<b>Patient Name :</b>	Vipulkumar Rameshbhai Rathva	<b>Sample No. :</b>	20221211345 
<b>Patient ID :</b>	20221206683	<b>Visit No. :</b>	OPD20221219299
<b>Age / Sex :</b>	35y/Male	<b>Coll. Date :</b>	02/12/2022 08:46
<b>Consultant :</b>	DR HIREN PATEL	<b>S. Coll. Date :</b>	02/12/2022 09:14
<b>Ward :</b>	-	<b>Report Date :</b>	02/12/2022 12:16

### Urine R/M

Investigation	Result	Normal Value
Quantity - :	20 ml	
Colour - :	Pale Yellow	
Reaction (pH) :	6.0	4.6-8.0
Turbidity :	Clear	
Deposit :	Absent	Absent
Sp.Gravity :	1.010	1.005-1.010
Protein :	Absent	Absent
Glucose :	Absent	Absent
Bile Salts :	Absent	Absent
Bile pigments :	Absent	Absent
Ketones :	Absent	Absent
Urobilinogen :	Absent	
Blood :	Absent	Absent
Pus Cells :	0-1 /hpf	0-5/hpf
Red Blood Cells :	Absent /hpf	Absent
Epithelial Cells :	0-1 /hpf	



**Dr. Mehul Desai**  
**M.B.D.C.P**  
**Reg.No.G-9521**



**2D-ECHOCARDIOGRAPHY AND COLOR DOPPLER REPORT**

**NAME: VIPULKUMAR R RATHVA**

**AGE/SEX: 35 YRS/MALE**

**DATE : 02/12/2022**



**REF BY: DR. HIREN PATEL**

**OBSERVATION:**

- NORMAL LV SIZE WITH NORMAL LV SYSTOLIC FUNCTION. LVEF = 60% (VISUAL).
- NO RWMA
- TRIVIAL MR. NO MS.
- NO AR. NO AS.
- TRIVIAL TR. NO PAH.
- NORMAL SIZED LA, RA & RV WITH NORMAL RV SYSTOLIC FUNCTION.
- NORMAL SIZED MPA, RPA & LPA.
- INTACT IAS & IVS.
- NO E/O INTRACARDIAC CLOT/VEGETATION/PE.
- NORMAL IVC.
- NORMAL PERICARDIUM.

**CONCLUSION:**

- NORMAL LV SYSTOLIC FUNCTION
- NO RWMA
- LVEF = 60% (VISUAL).

  
**DR. NIRAV BHALANI**  
**[CARDIOLOGIST]**  


**DR. ARVIND SHARMA**  
**[CARDIOLOGIST]**

**DR. CHIRAG SHETH**  
**[CARDIOLOGIST]**

35 Years

SHARDA, VIJOL DEAI  
Male

02-Dec-22 8:35:03 AM

Rate 80

PR 144

QRSD 84

QT 340

QTc 393

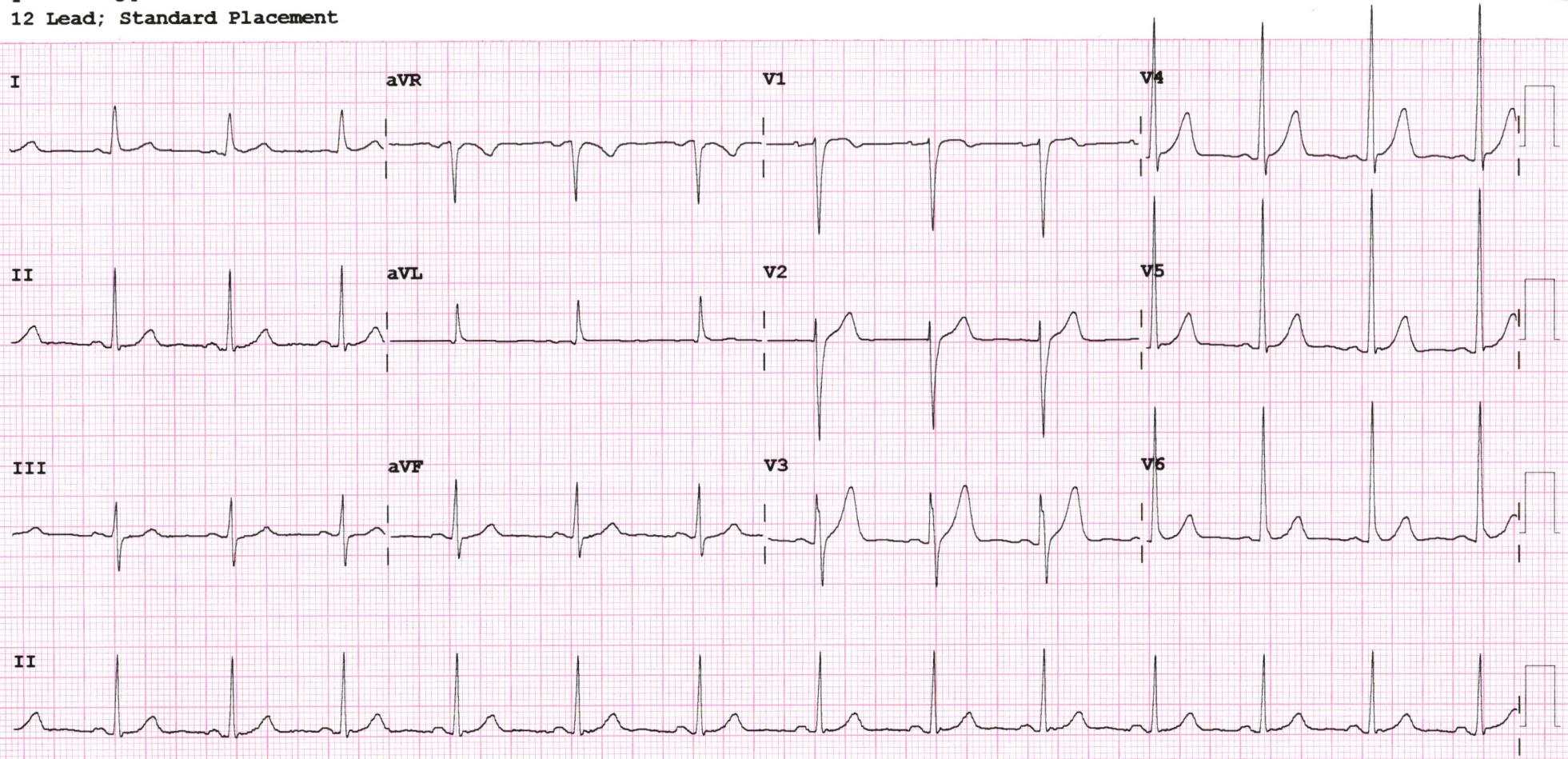
--AXIS--

P 67

QRS 32

T 54

12 Lead; Standard Placement



Device:

Speed: 25 mm/sec

Limb: 10 mm/mV

Chest: 10.0 mm/mV

F 50~ 0.50-150 Hz W

PH09

P?



Friday, December 02, 2022

VIPULKUMAR RATHVA

35 YEARS/MALE

Clinical profile: H/O LEFT SIDED NEPHRECTOMY.

**ULTRASONOGRAPHY OF ABDOMEN AND PELVIS**

Liver shows normal size and echogenicity. No mass lesion detected.  
PV, CBD and intrahepatic biliary radicals shows no dilatation.

The gall bladder is distended and show normal gall bladder. There is no evidence of gallstones.

Spleen appears normal in size and echotexture. No evidence of focal lesion.

Pancreas appears normal in size and echotexture. No focal lesion.

Right kidney shows normal size, position and cortical echogenicity.

Right kidney measures 9.9 cm .

Left kidney absent, consistent with h/o left sided nephrectomy.

Corticomedullary differentiation is preserved bilaterally.

No calculus or hydronephrosis on either side.

The urinary bladder is distended and appears normal..

Prostate appears normal. (17 cc) No focal lesion.

  
DR. CHETNA DUHAN, M.D

CONSULTANT RADIOLOGIST



**02/12/2022**

**VIPULKUMAR RATHVA**

**36 YEARS/MALE**

**CHEST X RAY PA VIEW**

Both the lung fields appear normal.

Both costophrenic angles appear clear.

Cardiac silhouette appear normal.

Both hila appears normal.

Mediastinum and aorta appear normal.

Bony thorax appears normal.

No evidence of free gas seen under dome of diaphragm.

**COMMENTS:**

- **NORMAL BOTH LUNG FIELDS.**
- **NORMAL CARDIAC SIZE.**



**DR. CHETNA DUHAN, M.D**  
**CONSULTANT RADIOLOGIST**