



PARKLINE DIAGNOSTICS PVT. LTD.

L.G. 3, 4 & 5, Bhuvana Towers, S.D. Road, Secunderabad - 500 003.
Tel : +91 40-2784 5852, 6649 1787, 7995421787, 7093445852, Fax : +91 40 2784 7864
Email parklinediagnostics@gmail.com www.parklinediagnostics.com




NABL Accredited
Certificate No.MC-2566

MEDICAL EXAMINATION REPORT

Name	MS. M. N. Chandrakala		Date	12/03/2022		
Company	Clo: Mediwheel		Reg. No. :	1868575		
Contact No.	9492407672		Sex	<input type="checkbox"/> M <input checked="" type="checkbox"/> F	Age	<input type="checkbox"/> 40 <input checked="" type="checkbox"/> 50
Type	Pre-Emp		Emp. No.:	Spouse		
	Overseas		Height	152		
	Annual	<input checked="" type="checkbox"/>	Weight	75		
Remarks	<p>TMT : Positive for Inducible Ischemia ⊕. Advice Coronary Angiography for further evaluation.</p> <p>USG : Cholelithiasis ⊖ 1.3cm Calculus in G. bladder Advice follow up.</p> <p>- ↑ red ESR count, ? Infection. Advice follow up.</p> <p>- Hb - 10.9 gm%. Advised to improve Hb. levels.</p>					
Fitness Status	Medically Fit / Unfit		<p>DR. PRIYANKA SANNIDHI</p> <p>Physician's Signature</p> <p>Regn. No. 11351</p>			

COMPREHENSIVE MEDICAL EXAMINATION REPORT

NAME 45 M. N. Chandra Kala
 AGE 50 yr / Female
 MARITAL STATUS Married CHILDREN: M F
 IDENTIFICATION (IF ANY) A mole on the (R) cheek



PAST HISTORY

Any family H/o : High Blood Pressure, Heart Disease, Tuberculosis, Diabetes, Asthma, Cancer
 Both parents Both parents

Any personal H/o Major illness like : Typhoid.....NIL.....Jaundice.....NIL.....Etc.

Any H/o STD.....Skin infection.....NIL

H/o Blood Transfusion.....NIL.....Recent Vaccination.....COUGLISHED 2 doses ✓

H/o Epilepsy.....Giddiness.....NIL

H/o Surgery.....2 LSCS.....Fracture in the past.....NIL

Any Personal H/O.

High Blood Pressure, Heart Disease Tuberculosis, Diabetes, Asthma, Cancer

Drug Abuse, Drug Allergy, Micturition, Bowels, Alcohol, Smoking, Sleep, MC, Wt. Loss/Wt. Gain

Present illness / Medication

GENERAL EXAMINATION

Conjunctiva :
 Skin :
 Ears :
 Nose :
 Throat & Oral Cavity :

NAD

Bone, Joints : (N)
 Nutritional Status : well Nourished
 Lymph Nodes : NPD
 Edema Feet : NIL
 Varicose Veins : NIL

Distant Vision : Near Vision :

Right Eye: 6/6

Right Eye: NB + 2.0 Sph NB

With glasses / Without glasses

With glasses / Without glasses

left Eye : 6/6

left Eye : NB + 2.0 sph NB

with glasses / without glasses

with glasses / without glasses

Colour Vision : BE normal

DR. KATTA
M.B.B.S., D.O., F.R.F.
Regd. (AMCI)
Ophthalmologist's Signature

Right Ear

Left Ear

Hearing :

Rinee's Test ;

Weber Test :

Discharge :

SYSTEMIC EXAMINATION

Pulse :

B.P. : 110/70

Lungs :
A. Shape of Chest
B. Breath Sounds
C. Adventitious Sounds

B/C symmetrical
B/C clear ⊕
No

Heart :
A. Sounds
B. Murmurs

S₁ S₂ ⊕
No

Nervous System

Abdomen :
A. Liver NPD
B. Spleen NPD
C. Piles NIL
D. Any Lump NIL

A. Higher Function :
B. Cranial Nerves :
C. Sensory System :
D. Motor System :
E. Jerks :

(N)

General :
A. Hernia
B. Hydrocele
C. Varicocele

(NAD)

Breast : Rt (N) Lt. (N)

CANDIDATE'S DECLARATION

I hereby solemnly declare that I am not suffering from Asthma, Hypertension, Diabetes, Occult Psychological disorders or any other ailment which can be suppressed without my voluntary declaration.

Date :

M.N. Chandra Kala
Signature

Place :

Note : General Physical Examination and Investigation included in the health check-up

· Have certain limitations and may not be able to detect all latent and asymptomatic diseases.

Any new symptoms developing after the health check-up or persisting thereafter should be

· brought to the attention of the treating physician.



SECUNDERABAD DENTAL HOSPITAL

CENTRE FOR ADVANCED DENTAL CARE

12/3/2022

ORAL & MAXILLOFACIAL SURGEONS

Dr. Kazim Himathi M.D.S.

Dr. Gautam Dendukuri

FDSRCS (Eng), FFDRCS (Ire),
FFCS (OMFS), (Ire)

PROSTHODONTIST

Dr. Chandrakanth Reddy M.D.S.

ENDODONTIST

Dr. Ram Narayan Reddy M.D.S.

ORTHODONTIST

Dr. Rajesh Reddy M.D.S., M.Orth RCS.

Dr. Sudeep Bhalerao M.D.S.

PERIODONTIST

Dr. Veerendranath Reddy M.D.S.

PEDODONTIST

Dr. Soumya M.D.S.

Dr. Mounika M.D.S.

DENTAL SURGEONS

Dr. N. Jagadish Rao B.D.S.

Dr. Baisakhi Saha B.D.S.

Mrs. Chandrakala . M.N

O/C - Patient came for a regular
dental checkup

O/E - old ceramic bridge $\frac{27449}{27454} / \frac{45578}{45578}$

- sinus opening $\frac{78}{78}$ region.

ADN Mr. Jay





PARKLINE DIAGNOSTICS PVT. LTD.



NABL Accredited
Certificate No. MC-2566

Mrs. Chandrakala
50 yrs

12-3-22

2 MP. 19.2-22)

- resided once in hospital

(W) H/O.

Bowel - constipation

urine - (W) & Regular

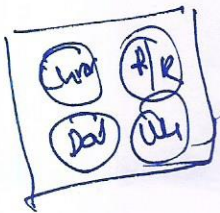
Breast - NAD

P/A - obesity

Exercise - $\left\{ \begin{array}{l} \text{walking} \\ \text{weights} \end{array} \right.$

X traced - M.D

→ - 6 months



Dr. JAMUNA DEVI. G
 MBBS, DGO, LL.B, (LL.M)
 Regd.No. 9207, A.P. Medical Council
 Obstetrician & Gynaecologist



PARKLINE DIAGNOSTICS PVT. LTD.

L.G. 3, 4 & 5, Bhuvana Towers, Sarojini Devi Road, Secunderabad - 500 003 Tel. +91 40-2784 5852
6649 1787 Fax : +91 40 2784 7864 Email : parklinediagnostics@gmail.com www.parklinediagnostics.com



NABL Accredited
Certificate No. MC-2566

TEST REPORT

Name : Ms . M N CHANDRAKALA [SPOUSE]
Age / Gender : 50 Years / Female
Ref.By : Medi Wheel
Req. No : BIL1868575

TID : UMR0739362
Registered on : 12-Mar-2022 08:56 AM
Reported On : 12-Mar-2022 02:22 PM

ABDOMINO-PELVIC ULTRASONOGRAPHY

LIVER is normal shape, size (12.6 cms) and has uniform echopattern.
No evidence of focal lesion or intrahepatic biliary ductal dilatation.
Hepatic and portal vein radicals are normal.

GALL BLADDER shows calculus of 1.3 cms is noted .
Gall bladder wall is of normal thickness.
CBD is of normal calibre.

PANCREAS has normal shape, size and uniform echopattern.
No evidence of ductal dilatation or calcification.

SPLEEN shows normal shape, size (8.2 cms) and echopattern.

KIDNEYS move well with respiration and have normal shape, size and echopattern.
Cortico- medullary differentiations are well made out.
No evidence of calculus or hydronephrosis.
Right kidney measures: 9.5 x 4.1 cms, Left kidney measures: 9.8 x 4.5 cms.

URINARY BLADDER Empty

UTERUS & OVARIES are not visualized due to empty urinary bladder.

No evidence of free fluid in the abdomen and pelvis.

IMPRESSION:

* Cholelithiasis.

Suggested clinical correlation and follow up

FLB

Dr. Abid Yazden
Consultant Radiologist

The Test marked with* are not accredited by NABL

Lab Timings (Weekdays) : 7.00 am to 8.30 pm

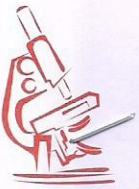Sundays & Holidays : 7.00 am to 1.00 pm

Radiologists Timings (Weekdays) : 9.00 am to 1.30 pm
& 5.30 pm to 7.45 pm

Sundays & Holidays : 7.30 am to 9.30 am

Free Home Visit for Sample Collection.

Call : 7995421787, 7093445852, 8121147282, 9885202212



PARKLINE DIAGNOSTICS PVT. LTD.

L.G. 3, 4 & 5, Bhuvana Towers, Sarojini Devi Road, Secunderabad - 500 003 Tel. +91 40-2784 5852
6649 1787 Fax : +91 40 2784 7864 Email : parklinediagnostics@gmail.com www.parklinediagnostics.com



NABL Accredited
Certificate No. MC-2566

TEST REPORT

Name : Ms. M N CHANDRAKALA [SPOUSE]

Age / Gender : 50 Years / Female

Ref. By : Medi Wheel

Req. No : BIL1868575

TID : UMR0739362

Registered on : 12-Mar-2022 08:56 AM

Reported On : 14-Mar-2022 12:15 PM

DEPARTMENT OF ULTRASOUND Mammography

Bilateral CC and MLO views done.

Both breasts show normal fibro-glandular parenchyma.

No dominant mass / pleomorphic micro calcifications / skin thickening /
Nipple retraction on either side.

No architectural distortion.


No evidence of duct dilatation.

No axillary lymphadenopathy.

IMPRESSION : No breast abnormality noted - BIRADS- I

Advised clinical correlation.

Note: Please bring previous reports on next visit.


Dr. PRAJAKTA SUKHADEVE
DNB RADIOLOGY
Reg. No. 68493

The Test marked with*are not accredited by NABL

Lab Timings (Weekdays) : 7.00 am to 8.30 pm

Sundays & Holidays : 7.00 am to 1.00 pm

Radiologists Timings (Weekdays) : 7.30 am to 1.30 pm

Sundays & Holidays

Page 1 of 2
& 5.30 pm to 7.45 pm

: 7.30 am to 9.30 am



TEST REPORT

Name	: Ms . M N CHANDRAKALA [SPOUSE]	TID	: UMR0739362
Age / Gender	: 50 Years / Female	Registered on	: 12-Mar-2022 08:56 AM
Ref.By	: Medi Wheel	Reported On	: 14-Mar-2022 12:15 PM
Req. No	: BIL1868575		

BIRADS ASSESSMENT CATEGORIES

- 0 - Needs additional imaging.
- 1 - Negative - There is nothing the comment on.
- 2 - Benign finding.
- 3 - Probably benign finding - followup after 3 months suggested.
- 4 - Suspicious abnormality. Biopsy should be considered
[4A - Low suspicion ,4B - Intermediate suspicion, 4C- Moderate concern]
- 5 - Highly suggestive of malignancy.
- 6 - Known biopsy proven malignancy.

The Test marked with*are not accredited by NABL

Lab Timings (Weekdays) : 7.00 am to 8.30 pm

Sundays & Holidays : 7.00 am to 1.00 pm

Radiologists Timings (Weekdays) : 7.30 am to 1.30 pm
& 5.30 pm to 7.45 pm

Sundays & Holidays : 7.30 am to 9.30 am

Free Home Visit for Sample Collection.

Call : 7995421787, 7093445852, 8121147282, 9885202212

Call : 7995421787, 7093445852, 8121147282, 9885202212



PARKLINE DIAGNOSTICS PVT. LTD.

L.G. 3, 4 & 5, Bhuvana Towers, Sarojini Devi Road, Secunderabad - 500 003 Tel. +91 40-2784 5852
6649 1787 Fax :+91 40 2784 7864 Email : parklinediagnostics@gmail.com www.parklinediagnostics.com



NABL Accredited
Certificate No. MC-2566

TEST REPORT

Name : Ms . M N CHANDRAKALA [SPOUSE]
Age / Gender : 50 Years / Female
Ref.By : Medi Wheel
Req. No : BIL1868575

TID : UMR0739362
Registered on : 12-Mar-2022 08:56 AM
Reported On : 12-Mar-2022 10:45 AM

X-RAY CHEST PA VIEW

Lung fields are clear.

Cardia is normal.


Hila are normal.

C P angles are free.

Bony cage is normal.

Soft tissues are normal.

IMPRESSION : NORMAL CHEST X-RAY


Dr. D.J. MOHAN
MD DMRD
(Reg No. 8995)
Consultant Radiologist

The Test marked with*are not accredited by NABL

Lab Timings (Weekdays) : 7.00 am to 8.30 pm
Sundays & Holidays : 7.00 am to 1.00 pm

Radiologists Timings (Weekdays) 7.30 am to 1.30 pm
& 5.30 pm to 7.45 pm
Sundays & Holidays : 7.30 am to 9.30 am

Free Home Visit for Sample Collection.

Call : 7995421787, 7093445852, 8121147282, 9885202212

NE DIAGNOSTICS PVT.LTD
: 1868575
: MS M.S.CHANDRAKALA
EX : 50 / FEMALE

HEIGHT (cm) : 152
WEIGHT (kg) : 75
PROTOCOL : BRUCE

REF. BY : MED
DONE BY : DR NAVEEN KUMAR C
TECHNICIAN : G.M.SURESH

2-03-2022, 16:17:
RAC

HISTORY :
PREPARATION :
OBJECT OF TEST : Routine Check Up.
TEST FACTOR : None.
ACTIVITY : Very Active.
OTHER INVESTIGATION : ECG
REASON FOR TERMINATION : THR ACHIEVED
EXERCISE TOLERANCE : Moderate (< 10 METS).
EXERCISE INDUCED ARRHYTHMIAS : No.
HEMO RESPONSE : Normal.
CHRONO RESPONSE : Normal.

FINAL IMPRESSION :

positive for inducible ischemia
Ado
CAG

Dr. NAVEEN KUMAR .C
M.D., D.M.
Consultant Cardiologist
Reg. No. 52294
Signature

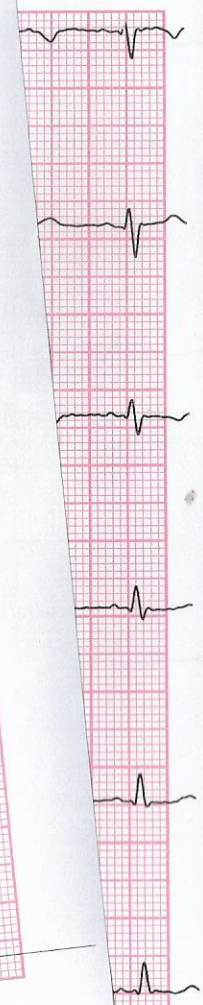
Page No.: 1

BPL DYNATRAC

No Filter

10mm/mV, 25mm/Sec

830 Tested On 12-03-2022, 16:17:32



ID: 1808573

12-05-2022 09:42:57 AM

MS.M N CHANDRAKALA
Female 50Years

CARDIART

HR : 72 bpm
P : 92 ms
PR : 151 ms
QRS : 71 ms
QT/QTc : 372/407 ms
P/QRST : 13/44/19 °
RV5/SV1 : 0.911/0.541 mV

Diagnosis Information:
Sinus Rhythm
Normal ECG

Report Confirmed by:

NSR

WNL
Dr. NAVIER PUNJIC
M.D., D.M.
Consultant Cardiologist
Reg. No. 52291