



Diagnostic/Hospital

Address of Diagnostic/Hospital- : Baramuri, P.O. - Bishunpur Polytechnic

Appointment Date : 20-11-2021

Preferred Time : 09:30:AM

Member Information			
Booked Member Name	Age	Gender	Cost(In INR)
MR. GUPTA HEMANT	41	Male	Cashless
Total amount to be paid			Cashless

We will get back to you with confirmation update shortly. Please find the package details as attached for your reference.

Package Name : Bob Full Body Health Checkup Male Above 40 - Includes (40)Tests

Tests included in this Package : Ecg, TSH, X-ray Chest, Stress Test (tmt)/ 2d Echo, Blood Sugar Postprandial, Psa(for Male), Dental Consultation, Creatinine, Serum, A:g Ratio, Blood Group, Total Cholesterol, Triglycerides, Fasting Blood Sugar, Ultrasound Whole Abdomen , Glycosylated Haemoglobin (hba1c), Hdl, Vldl, Urine Analysis, LDL, Total Protine, General Consultation, HDL/ LDL ratio, GGT(Gamma-glutamyl Transferase), Eye Check-up consultation, ALP (ALKALINE PHOSPHATASE), Uric Acid, AST/ALT Ratio, Serum Protein, CBC with ESR, Stool Analysis, Urine Sugar Fasting, Urine Sugar PP, T3, T4, Cholesterol Total / HDL Ratio, BUN, BUN/Creatinine Ratio, Bilirubin Total & Direct and Indirect, Albumin, Globulin



भारत सरकार
Unique Identification Authority of India
Government of India

नामांकन क्रम / Enrollment No 1171/21094/08635

To,
हेमंत गुप्ता
Hemant Gupta
S/O: Rajendra Prasad Gupta
House No. -118
Near hari Bol Mandir Manaiand Basti
Dhanbad
Dhanbad Nirsa-cum-chirkunda Dhanbad
Jharkhand 826001
9708616409

11/01/2013

Ref: 189 / 26B / 239529 / 240117 / P



SH218983225DF



आपका आधार क्रमांक / Your Aadhaar No. :

7284 7780 0467


आधार – आम आदमी का अधिकार



भारत सरकार
GOVERNMENT OF INDIA



हेमंत गुप्ता
Hemant Gupta
जन्म वर्ष / Year of Birth : 1980
पुरुष / Male



7284 7780 0467

आधार – आम आदमी का अधिकार



बैंक ऑफ बड़ौदा
Bank of Baroda



नाम : हेमन्त गुप्ता
Name : HEMANT GUPTA

कमन्सिटी ए.सी. नं. : 160232
E.C. No. : 160232

[Signature]
HEMANT GUPTA



Asarfi Hospital Limited.
 Baramuri, P.O.-Bishunpur Polytechnic, Dhanbad(Jharkhand)
 Phone : 03262295147 Fax : 08817844529
 Email: asarfihospital@hotmail.com

Medi Wheel Full Body Health Checkup

Bill Date : 19.11.2021

Bill No: AHL/Medi Wheel/2021/17
 TIN NO.20861605701

Patient Details

Registration no : NOV21-28454
 Patient Name : MR.HEMANT GUPTA
 Age : 41 Yrs
 Address : NEAR HARI BOL MANDIR MANITAND- JHARKHAND, INDIA

Gende : MALE
 Phone No.
 Mobile No : 8372090313

Sl.No.	Service(s) Name	Rate	Quantity	Discount	Total.
1	Medi Wheel Full Body Health Checkup Male Above 40 Years (PACKAGE)	2100.00	1	0.00	2100.00
				Total Rs.	2100.00
				Net Amount.	2100.00

(Rupees Two Thousand One Hundred Only)
 Prepared By :

Mr. Anikesh paul





OUT PATIENT DEPARTMENT

Type : Mediwheel

DEPARTMENT OF GENERAL MEDICINE

Regd. No.	: NOV21-28454	Visit	: OPD/191121/100
Patient Name	: MR. HEMANT GUPTA	Mobile	: 8372090313
Age/Sex	: 41 Yrs / MALE	Date	: 19-Nov-2021
Address	: NEAR HARI BOL MANDIR MANITAND- Jharkhand, INDIA		
Doctor	: Dr. PANKAJ KUMAR (M.B.B.S, DNB-GENERAL MEDICINE)		
OPD Timing	:		

BP - 142/82 mmHg
B - 84/120

full body health checkup

Inf

- blood glucose fasting

- blood grouping

- blood urea nitrogen

- ECG, BLS

- X-ray, KFT

- cold profile

- LFT, PSA

- Urine, stool routine

- Thyroid hormones T3, T4, TSH

- chest PA view

- BLS, 2 Echo, usg Abd., BLS

Adv

- no need of med.

Dr. PANKAJ
DNB (Medicine)
Asarfi Hospital
Dhanbad, Jharkhand





असर्फी हॉस्पिटल
सबके लिए स्वास्थ्य

Baramuri, P.O. - Bishunpur Polytechnic, Dhanbad (Jharkhand) - 828130
Mob.: 9234302735, 9234651512, 9234681514
CIN : U85110JH2005PTC011673



DEPARTMENT OF PATHOLOGY

Name	MR. HEMANT GUPTA	Lab No:	1,249
Age	41 Yrs Sex: Male	Collection Date	20/11/2021
Doctor	SELF WALK-IN	Collection Time	12:28 pm
Reg.No.	NOV21-28454	Reporting Date	20/11/2021
		Reporting Time	5:21 pm

KFT PANEL

Blood Urea	14.5 mg/dl	10-40 mg/dl
Uric Acid	3.5 mg/dl	3.0 - 7.0 mg/dl
Calcium	9.1 mg/dl	8.7 - 11 mg/dl
Sodium	143.3 mmol/L	133 - 155 mmol/L
Potassium	4.2 mmol/L	3.5 - 5.5 mmol/L
Chlorides	105.9 mmol/L	96 - 108 mmol/L
S. Creatinine	0.6 mg/dl	0.7-1.4 mg/dl
Phosphorus	3.6 mg/dl	2.5 - 5.5 mg/dl

Serum Potassium(K), Sodium (Na)

Serum Chloride (Cl)

Serum Creatinine

Serum Phosphorus

Dr.N.N.SINGH MD(PATH)
PATHOLOGIST

24 HOUR EMERGENCY

Checked by:

© AHL/D/0066

Typed by



"KEEP THE REPORTS CAREFULLY AND BRING THEM ALONG DURING YOUR NEXT VISIT TO OUR HOSPITAL"

DEPARTMENT OF PATHOLOGY

Name : MR. HEMANT GUPTA
Age : 41 Yrs Sex : Male
Doctor : SELF WALK-IN
Reg. No. : NOV21-28454
Sub Dept. : Biochemistry

Lab No: : 1,249
Collection Date: 20-Nov-2021
Collection Time: 12:28:18PM
Reporting Date : 20-Nov-2021
Reporting Time : 5:19:55PM

Test Result Reference Range

Test	Result	Reference Range
Lipid Profile		
Serum Cholesterol	183.0 mg/dl	150 - 250 mg/dl
Serum Triglyceride	120.0 mg/dl	50-190 mg/dl
HDL Cholesterol	47.0 mg/dl	35 - 55 mg/dl
LDL Cholesterol	112.0 mg/dl	Upto 160 mg/dl
VLDL Cholesterol	24.0 mg/dl	Upto 60 mg/dl

Dhanbad's 1st NABH & NABL Certified Hospital & Lab

PATHOLOGIST

Typed by:

Checked by:

24 HOUR EMERGENCY

© AHL/D/0066



"KEEP THE REPORTS CAREFULLY AND BRING THEM ALONG DURING YOUR NEXT VISIT TO OUR HOSPITAL"

DEPARTMENT OF PATHOLOGY

Name	: MR. HEMANT GUPTA	Lab No.	: 1,243
Age	: 41 Yrs Sex : Male	Collection Date:	20-Nov-2021
Doctor	: SELF WALK-IN	Collection Time:	12:27:44PM
Reg. No.	: NOV21-28454	Reporting Date :	20-Nov-2021
Sub Dept.	: Haematology	Reporting Time :	6:26:55PM

Test	Result	Reference Range
	<u>ESR</u>	
E.S.R (Westergren)	27 mm/hr	0 - 20 mm/hr
	<u>CBC</u>	
Haemoglobin	13.3 g/dl	13 - 18 g/dl
Red Blood Cells Count	4.22 / cumm	4.0 - 6.0 / cumm
TOTAL COUNT OF PLATELET	1.34 lakhs/cumm	1 - 4 lakhs/cumm
Total WBC Count	6,500 /cumm	4000 - 11000 /cumm
Neutrophils	51 %	55 - 75 %
Lymphocytes	32 %	15 - 30 %
Eosinophils	14 %	1 - 6 %
Monocytes	03 %	2 - 10 %
Basophils	00 %	0 - 1 %
PCV	38.9 %	40 - 54 %
MCV	92.2 cu-microns	80 - 99 cu-microns
MCHC	34.2 %	32 - 38 %
	<u>Blood Grouping</u>	
ABO Group	"B"	
Rh (Factor)	POSATIVE	
	<u>Blood Urea Nitrogen</u>	
Blood Urea Nitrogen	5.2 mg/dl	5 - 20 mg/dl

DEPARTMENT OF PATHOLOGY

Name : MR. HEMANT GUPTA
Age : 41 Yrs Sex : Male
Doctor : SELF WALK-IN
Reg. No. : NOV21-28454
Sub Dept. : Biochemistry

Lab No: : 1,249
Collection Date: 20-Nov-2021
Collection Time: 12:28:18PM
Reporting Date : 20-Nov-2021
Reporting Time : 5:19:55PM

Test	Result	Reference Range
------	--------	-----------------

LIVER FUNCTION TEST (LFT)

Bilirubin (Total)	0.4 mg/dl	0.2 - 1.0 mg/dl
Bilirubin (Direct)	0.2 mg/dl	0 - 0.2 mg/dl
Bilirubin (Indirect)	0.2 mg/dl	0.2 - 0.8 mg/dl
Total Proteins	7.7 g/dl	6.5 - 8.5 g/dl
Albumin	4.5 g/dl	3.5 - 5.5 g/dl
Globulin	3.2 g/dl	1.5 - 3.5 g/dl
SGOT	32.9 IU/L	< 40 IU/L
SGPT	40.4 IU/L	< 49 IU/L
Alkaline Phosphatase	217.5 IU/L	70-306 IU/L
Gamma-GT	21.6 U/L	0-55 U/L

Blood glucose-fasting, postprandial

Blood Glucose Fasting	91.0 mg/dl	60 - 110 mg/dl
Blood Glucose Postprandial	102.9 mg/dl	70-140 mg/dl

DEPARTMENT OF PATHOLOGY

Name : MR. HEMANT GUPTA
Age : 41 Yrs Sex : Male
Doctor : SELF WALK-IN
Reg. No. : NOV21-28454
Sub Dept. : Clinical Pathology

Lab No: : 1,250
Collection Date: 20-Nov-2021
Collection Time: 12:28:23PM
Reporting Date: 20-Nov-2021
Reporting Time: 5:19:55PM

Test	Result	Reference Range
Routine Examination of Urine		
Quantity	20 ml (Approx)	
Colour	STRAW	
Appearance	CLEAR	
Specific Gravity	1.030	
Reaction (pH)	ACIDIC	
Albumin.	NIL	
Sugar	NIL	
Ketone Bodies	XX	
Bile Salts	XX	
Bile Pigments	XX	
RBC	NIL /hpf	
Pus Cells	0-1 /hpf	/hpf
Epithelial Cells	1-2	
Casts	NOT SEEN /hpf.	/hpf.
Crystals	NOT SEEN /hpf.	/hpf.
Bacteria	NOT SEEN /hpf.	/hpf.

DEPARTMENT OF PATHOLOGY

Name	: MR. HEMANT GUPTA	Lab No:	: 1,248
Age	: 41 Yrs Sex : Male	Collection Date:	: 20-Nov-2021
Doctor	: SELF WALK-IN	Collection Time:	: 12:28:10PM
Reg. No.	: NOV21-28454	Reporting Date:	: 20-Nov-2021
Sub Dept.	: Clinical Pathology	Reporting Time:	: 5:19:55PM

Test	Result	Reference Range
------	--------	-----------------

Stool - Routine

Colour	BROWN	
Reaction (pH)	ALKALINE	
Occult Blood	NEGATIVE	
Protozoa	NOT FOUND	
Ova of Parasites	NOT FOUND	
Epithelial Cells	1-2 /hpf.	/hpf.
Pus Cells (Stool)	1-2	
Red Blood Cells (Stool)	NIL	
Vegetable Cells	NOT SEEN	
Yeast Cells	NOT SEEN	
Cyst (stool)	NOT SEEN	

Thyroid hormones T3 T4 TSH (Enzyme Immunoassay)

T3, Total, Serum	0.98 ng/ml	0.74-1.79 ng/ml
T4, Total, Serum	7.73 ng/dl	4.7-12.8 ng/dl
TSH, SERUM (Enzyme Immunoas)	2.11 μ IU/ml	0.25-5.00 μ IU/ml

PSA (PROSTATIC SPECIFIC ANTIGEN TEST TOTAL)

P.S.A.	0.62 ng/ml.	0.0 - 4.0 Border line 4.0 - 10.0 ng/ml.
--------	-------------	---

HbA1c (glycosylated Hb)

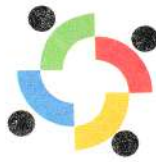glycosylated Hb	3.7 %	4.6-6.2 %
-----------------	-------	-----------

24 HOUR EMERGENCY

© AHL/D/0066

"KEEP THE REPORTS CAREFULLY AND BRING THEM ALONG DURING YOUR NEXT VISIT TO OUR HOSPITAL"





ECHOCARDIOGRAPHY REPORT

Name: **MR HEMANT GUPTA**

Age: **41**

Sex: **Male**

Date: **19/11/2021**

2D & M-MODE MEASUREMENTS

IVSd	1.1 cm
LVIDd	4.5 cm
LVPWd	1.2 cm
IVSs	1.4 cm
LVIDs	3.0 cm
Ao Diam	3.2 cm
LA Diam	3.9 cm

2D & M-MODE CALCULATIONS

EDV(Teich)	92 ml
ESV(Teich)	34 ml
EF(Teich)	63 %
%FS	34 %
SV(Teich)	58 ml
LVd Mass	230.66 g
RWT	0.55
LA/Ao	1.22

MITRAL VALVE

MV E Vel	0.99 m/s
MV DecT	161 ms
MV Dec Slope	6.1 m/s ²
MV A Vel	0.86 m/s
MV E/A Ratio	1.15

AORTIC VALVE

AV Vmax	1.20 m/s
AV maxPG	5.74 mmHg

TRICUSPID VALVE

PV Vmax	1.39 m/s
PV maxPG	7.73 mmHg

COMMENTS:

- NORMAL SIZE CARDIAC CHAMBERS
- NO LVRWMA
- GOOD LV SYSTOLIC FUNCTION (EF-64%)
- NO MS/MR, NO AS/AR
- IAS, IVS INTACT
- NO CLOT, PE
- IVC NORMAL

IMPRESSION:

- NORMAL SIZE CARDIAC CHAMBERS
- NO LVRWMA
- GOOD LV SYSTOLIC FUNCTION (EF-64%)

DR. S.H CHAVAN
(CONSULTANT CARDIOLOGIST)

TECH. SIG

1167



RADIOLOGY REPORT

Patient Information		Patient ID	28454
Patient Name	MR HEMANT GUPTA	Scan Date	NOV 19 2021
Age Gender	41Y M	Report Date	NOV 19 2021
Referring Doctor	DR SELF		

X-RAY CHEST

FINDINGS

Lungs

- Prominent broncho-vascular markings are noted bilaterally.
- Both para hilar shadow in patch fibrotic consolidation and tiny nodular calcification seen.

Airways

- Trachea is central. Tracheo-bronchial tree is normal.

Heart

- Cardiac silhouette is normal.

Others

- Bilateral CP angles are clear.
- Both domes of diaphragm are normally placed.
- Bony thoracic cage is normal.
- No soft tissue abnormality seen.

IMPRESSION

- Both para hilar shadow in patch fibrotic consolidation and tiny nodular calcification seen.
- Bronchitis

RECOMMENDATION

Suggested clinical correlation



Dr. Kajal Agarwal

MD Radiology(MPMC-18472)

Consultant Radiologist

Disclaimer

It is an online interpretation of medical imaging based on the available clinical data. Patient's identification in online reporting is not established, so this report cannot be utilized for any medico legal purpose/ certifications. All modern machines/procedures have their own limitations. If there is any clinical discrepancy, this investigation may be repeated or reassessed by other tests.

MR HEMANT GUPTA 41Y/M DR SELF | 1

24 HOUR EMERGENCY

© AHL/D/0070



"KEEP THE REPORTS CAREFULLY AND BRING THEM ALONG DURING YOUR NEXT VISIT TO OUR HOSPITAL"




RADIOLOGY REPORT

Reg.No.	28454	Ref.Dr.	SELF
Name	MR. HEMANT GUPTA	Study	USG WHOLE ABDOMEN
Age & Sex	41Y/M	Reporting Date	19.11.2021

USG WHOLE ABDOMEN

- LIVER** : Liver is normal in size & shape. It appears bright in echotexture. No obvious focal lesion is seen. IHBR are not dilated.
- GALL BLADDER** : GB is well distended. No obvious calculus or mass lesion is seen. The wall thickness is normal.
- CBD** : CBD is normal in course & caliber.
- PV** : PV is normal in course & caliber.
- PANCREAS** : Pancreas is normal in size, shape & echotexture. Peripancreatic soft tissues appear normal. MPD is not dilated.
- SPLEEN** : Spleen is normal in shape, size & echotexture. It measures 9.8 cm in size.
- KIDNEYS** : The right kidney measures 9.8 x 4.6 cm. The left kidney measures 9 x 4.2 cm. Both kidneys are normal in shape, size & position. The pelvicalyceal system is normal. Corticomedullary differentiation is maintained. A simple cyst measuring 6.9 x 5.2cm is seen at the upper pole of right kidney. A calculus measuring 3.1mm is seen at the lower pole of right kidney. A calculus measuring 2.6mm is seen at the mid pole of left kidney.
- URINARY BLADDER** : Urinary bladder is partially distended. No obvious calculus or mass lesion is seen.
- PROSTATE** : Prostate is normal in size, shape & echotexture. It measures 3.5 x 3.1 x 3.5cm in size (volume – 20gram).
- OTHERS** : No ascites or retroperitoneal lymphadenopathy is seen.
- IMPRESSION** :
- **Bilateral renal calculi.**
 - **A right renal simple cyst.**
 - **Grade II diffuse fatty infiltration of liver.**


Dr. VAISHALI PATEL
MBBS, DNB (Radio-diagnosis)
Consultant Radiologist

19-Nov-21 14:43:27
MEDICA DHANBAD

MR HEMANT GUPTA
Male

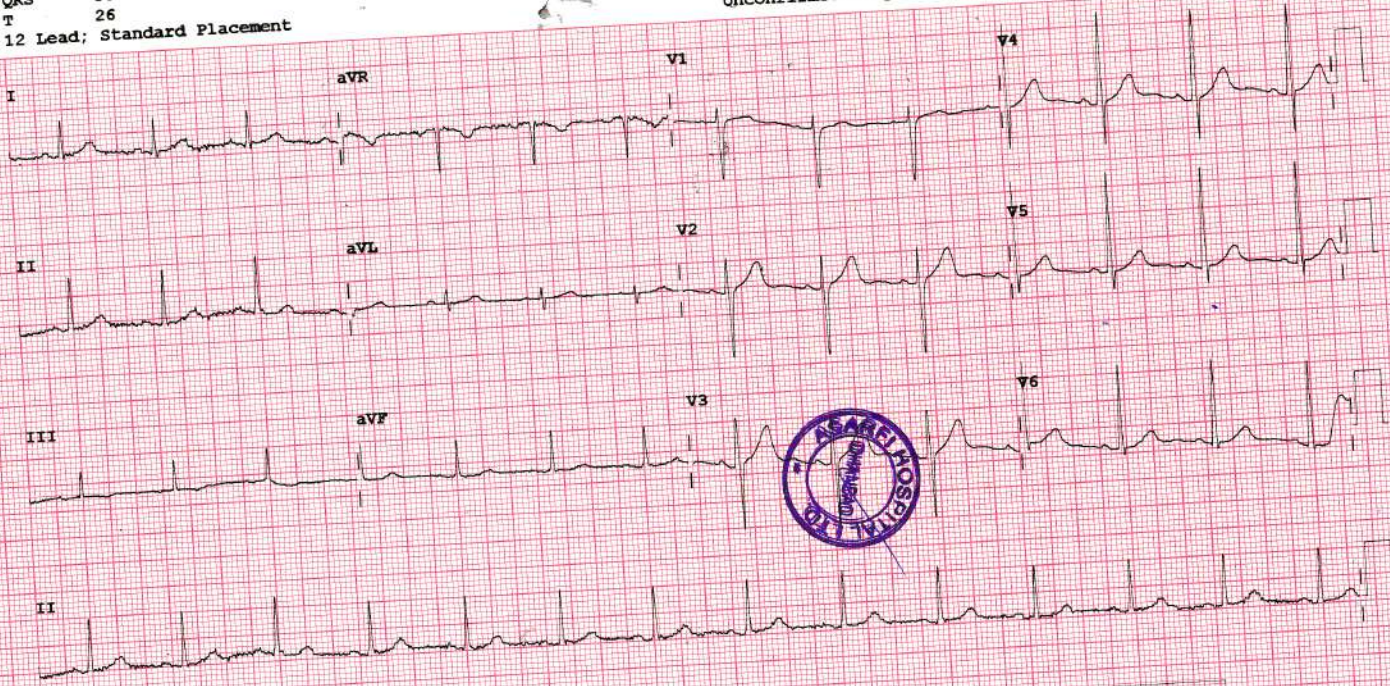
41 Years

Rate 84 Sinus rhythm.....normal P axis, V-rate 50-99
PR 137 Minimal ST depression.....ST <-0.05mV in 2 leads
QRSD 74 Baseline wander in lead(s) V1,V3,V5
QT 358
QTc 424

- OTHERWISE NORMAL ECG -

Unconfirmed Diagnosis

--AXIS--
P 22
QRS 58
T 26
12 Lead; Standard Placement



Speed: 25 mm/sec Limb: 10 mm/mV Chest: 10.0 mm/mV

F 50~ 0.50-100 Hz W PH100B CL P?

1111112130