

Unique Identification Authority of India

மேலே உள்ள
விலக்கு
பெற்றுள்ள
பொருள்கள்
பற்றி
தகவல்
பெற
விரும்பு
பின்னர்
இந்த
பெட்டி
பிரதான
அலுவலகம்
பற்றி
தகவல்
பெற
விரும்பு

Address:
F BLOCK H NO 303, DECCAN
ALL SEASONS APARTMENT,
CHURCH ROAD, OLYMBUS,
Coimbatore South, Coimbatore,
Ramanathapuram Coimbatore,
Tamil Nadu, 641045

5492 1234 8440



சர்க்கார் அடையாளம்

Government of India



Manoj Aravindakshan
பேரண்முகம் / மண் : 27/03/1976
ஆண் / Male



5492 1234 8440

எனது ஆதார், எனது அடையாளம்

Handwritten signature



बैंक ऑफ बड़ौदा
Bank of Baroda

नाम : मनोज .ए. नायर
Name: **MANOJ .A. NAIR**

क.कू.सं : **103438**
E.c. No. :



जारीकर्ता प्राधिकारी
Issuing Authority

धारक का हस्ताक्षर
Signature of the Holder



ABI SCANS & LABS

A unit of Aarthi Scans and Labs

Name	MR.NAIR MANOJ ARAVINDAKSHAN	Patient ID	84676
Accession No	88009	Age/Gender	45Y / Male
Referred By	Dr.MEDIWHEEL	Date	12-Feb-2022

USG REPORT - ABDOMEN AND PELVIS

LIVER:

Liver is normal in size (measures ~ 13.3 cm) and shows increased echotexture.

No focal liver lesion. No intra hepatic biliary radical dilatation seen.

GALL BLADDER:

Is adequately distended. No calculus or cholecystitis seen.

PANCREAS:

Appears normal in size and shows uniform echo texture. The pancreatic duct is normal. No calcifications are seen.

SPLEEN:

Appears normal in size and it shows uniform echo texture. It measures ~ 10.6 cm in long axis.

RIGHT KIDNEY:

Right kidney measures ~ 9.9 x 3.9 cm.

The shape, size and contour of the right kidney appear normal.

Cortico medullary differentiation is within normal. No evidence of pelvicalyceal dilatation.

No calculi seen.

LEFT KIDNEY:

Left kidney measures ~ 10.8 x 4.9 cm.

The shape, size and contour of the left kidney appear normal.

Cortico medullary differentiation is within normal. No evidence of pelvicalyceal dilatation.

No calculi seen.



ABI SCANS & LABS

A unit of Aarthi Scans and Labs

Name	MR.NAIR MANOJ ARAVINDAKSHAN	Patient ID	84676
Accession No	88009	Age/Gender	45Y / Male
Referred By	Dr.MEDIWHEEL	Date	12-Feb-2022

USG REPORT - ABDOMEN AND PELVIS

URINARY BLADDER:

Is normal contour. No intra luminal echoes are seen.

PROSTATE:

Prostate appears normal, Measures ~ 3.1 x 3.5 x 2.5 cms (Vol - 15 cc).

RIGHT ILIAC FOSSA:

No focal fluid collections seen.

No evidence of hernia seen in anterior abdominal wall.

IMPRESSION:

❖ Grade I fatty liver.

- Suggested clinical correlation.


Dr. Abinaya Rajasekaran., MDRD.,
Radiologist

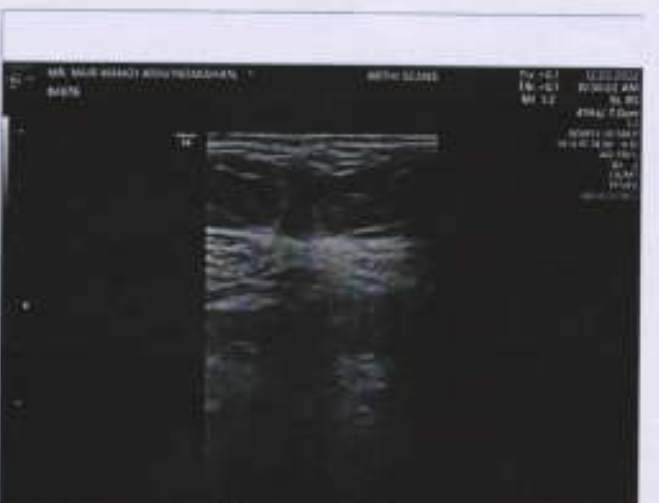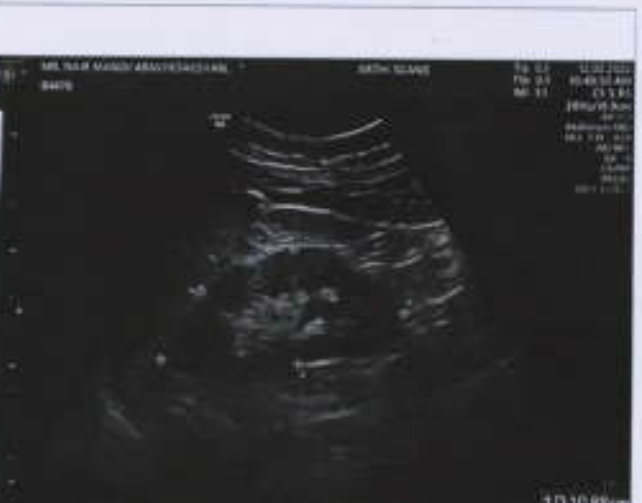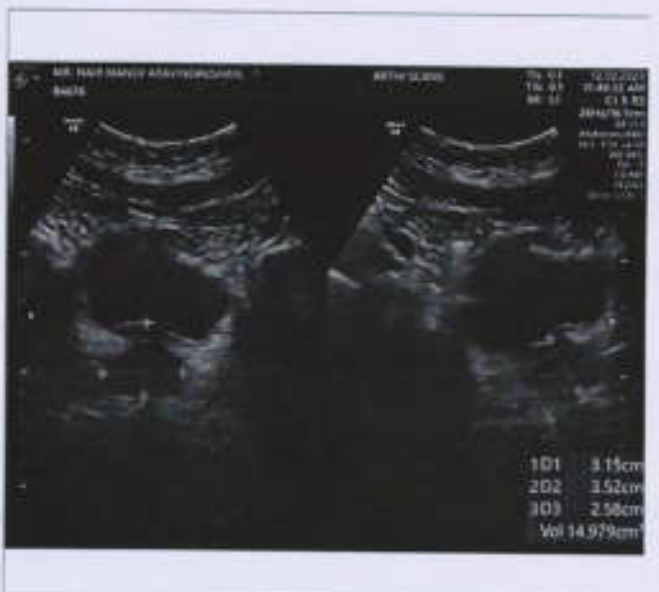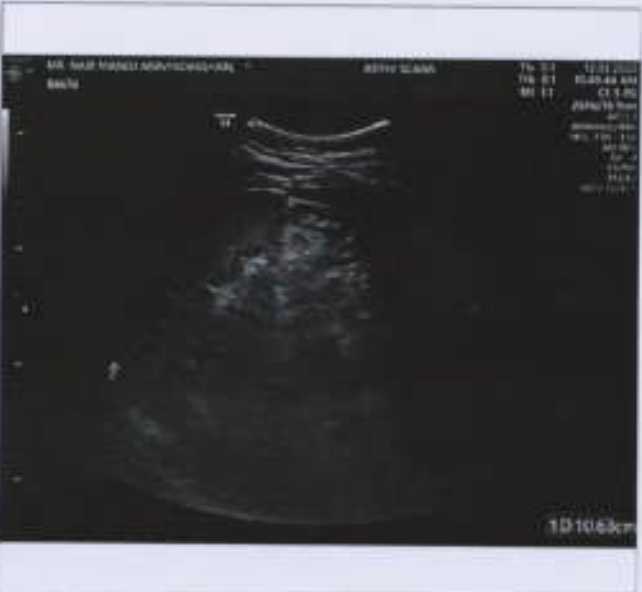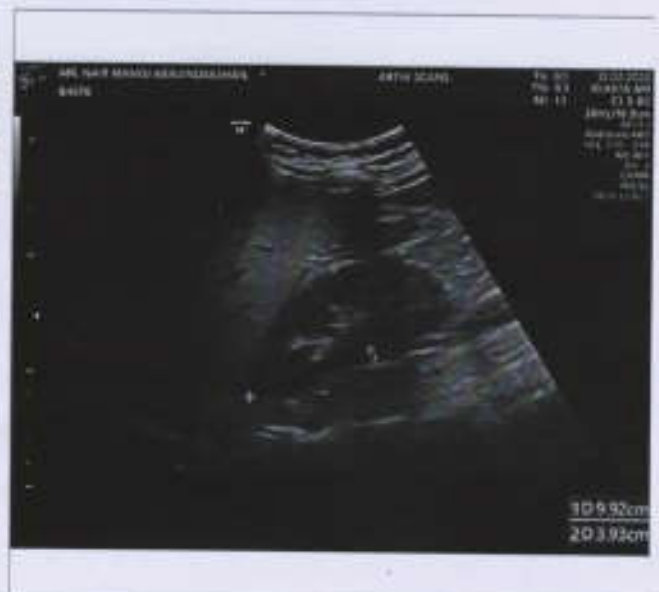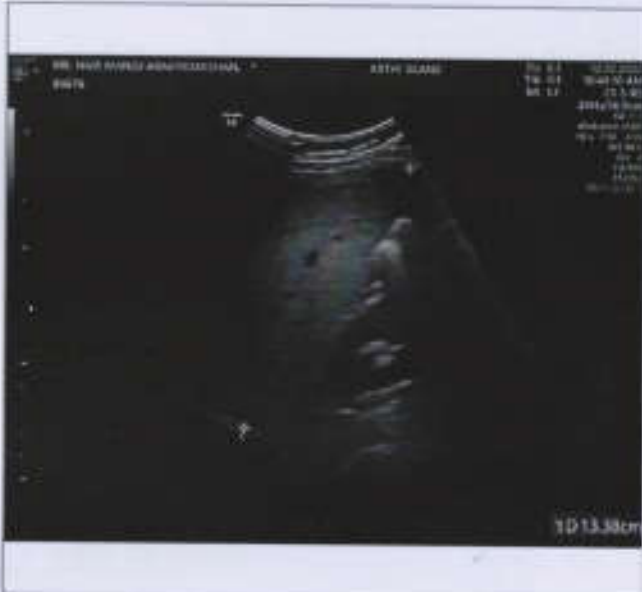Thank you for the courtesy of this referral

Foot Note: Patient's identity is not verified. Report is not valid for medico legal purpose.

Dr. Abinaya Rajasekaran, MD, RD,
Reg. No: 119338.

ABI SCANS AND LABS

MR. NAIR MANOJ ARAVINDAKSHAN /M 84676 12-Feb-2022 09:33:23 AM





ABI SCANS & LABS

A unit of Aarthi Scans and Labs

Name	MR.NAIR MANOJ ARAVINDAKSHAN	Patient ID	88009
Accession No	84676	Age/Gender	45Y / Female
Referred By	Dr.MEDIWHEEL	Date	12-Feb-2022

X-RAY - CHEST PA VIEW

OBSERVATION:

The trachea is central.

The mediastinal and cardiac silhouette are normal.

Cardiothoracic ratio is normal.

Cardiophrenic and costophrenic angles are normal.

Both hila are normal.

Lung zones are clear.

Bones of the thoracic cage are normal.

Soft tissues of the chest wall are normal.

IMPRESSION:

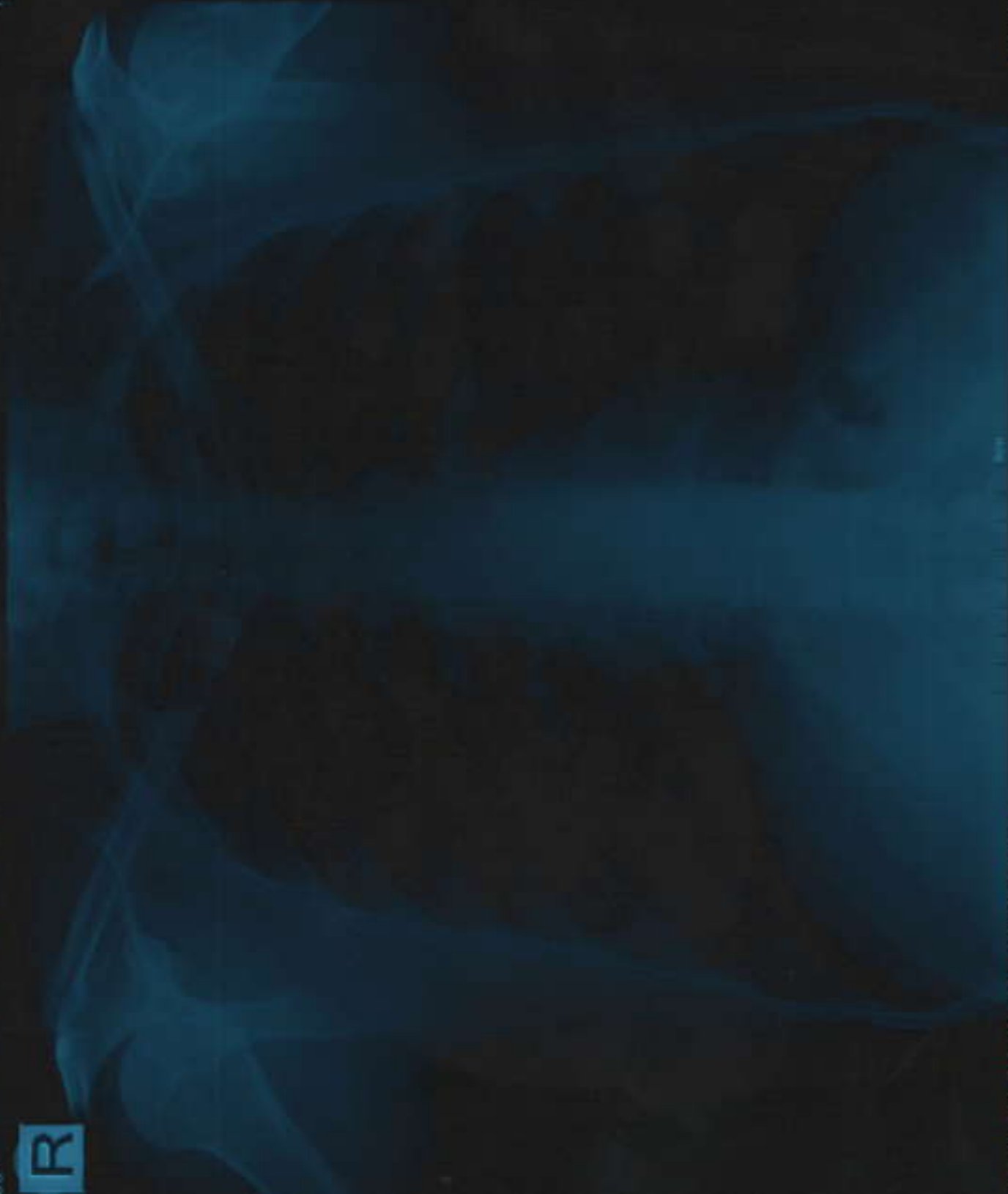
> No significant abnormality seen.

Dr. Abinaya R MDRD.,
Consultant Radiologist

NAIR MANOJ ARAVINDAKSHAN 45Y

12/02/2022
10:12:00

R



PHI CT AND MRI SCAN COIMBATORE

MEDIWHEEL



ABI SCANS & LABS

A unit of Aarhi Scans and Labs

NAME	MR. NAIR MANOJ ARAVINDKSHAN	PATIENT ID	84676
ACCESSION NO	88009	AGE/GENDER	45Y/MALE
REFERRED BY	MEDIWHEEL	DATE	12.02.2022

ECHOCARDIOGRAPHIC EVALUATION

MEASUREMENTS: ACOUSTIC WINDOW: OPTIMAL

2D/ M MODE PARAMETERS:

Parameters	Patient Values	Normal Adult Value
LA	2.58	(2.0 - 4.0 cm)
AO	2.54	(2.0 - 4.0 cm)
LVIDD	4.43	(3.5 - 5.5 cm)
LVIDS	2.22	(2.5 - 4.3 cm)
IVSd	0.77	(0.6 - 1.2 cm)
LVPWd	0.80	(0.6 - 1.2 cm)
EF	81	(50% - 70%)

IMPRESSION:

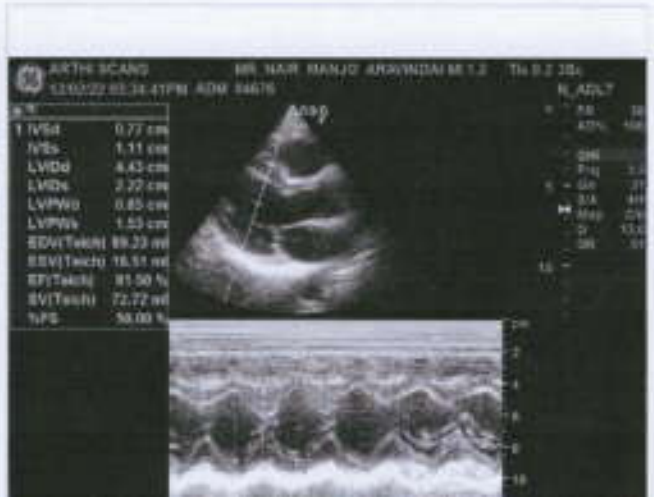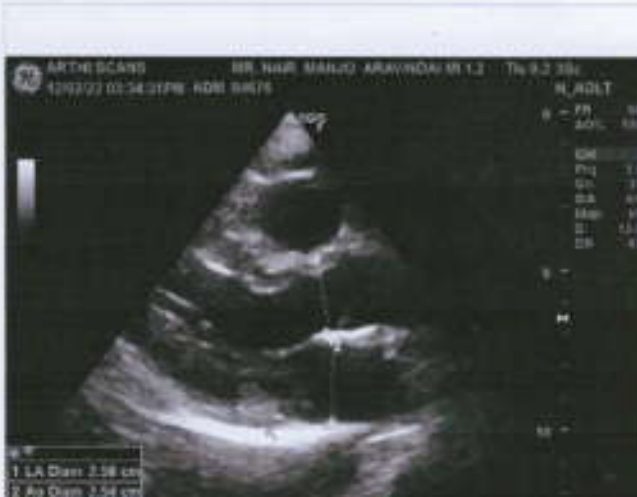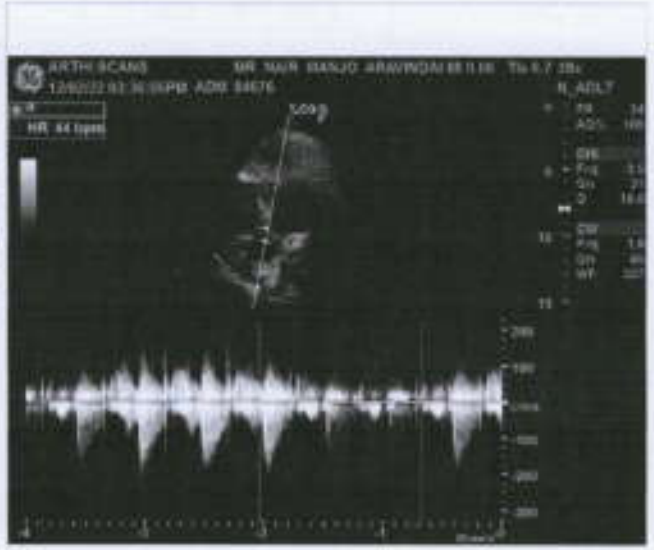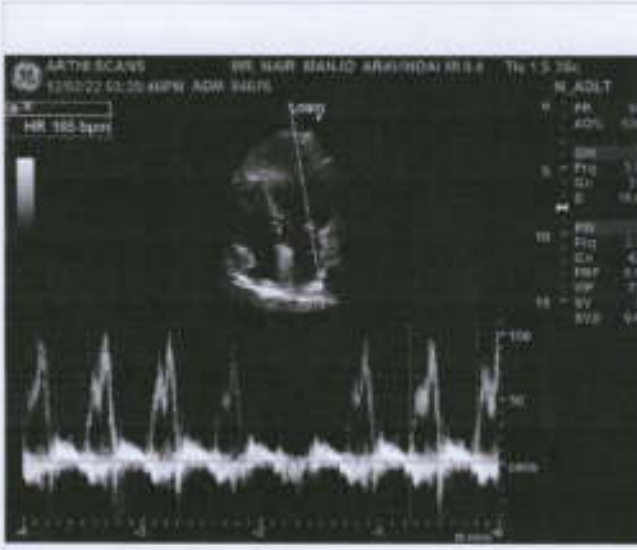
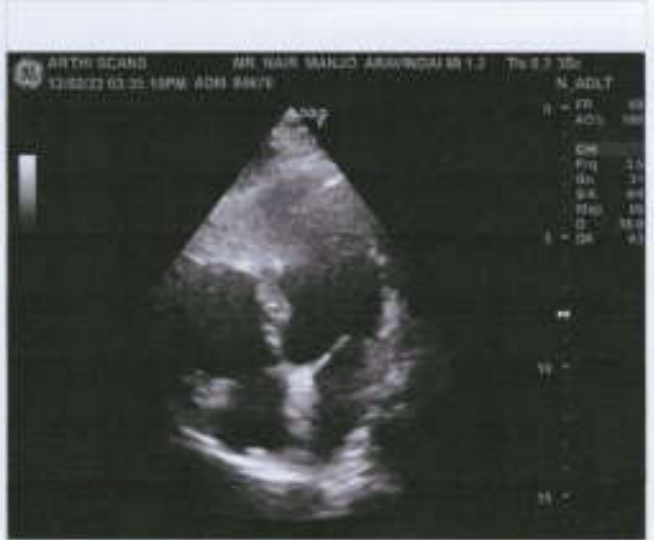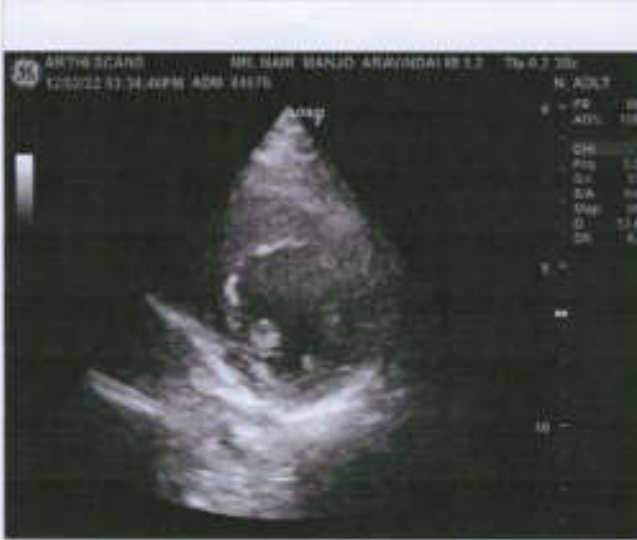- ✚ No regional wall motion abnormality at rest.
- ✚ Normal valves and chambers.
- ✚ Tachycardia during study.
- ✚ No pulmonary hypertension.
- ✚ No pericardial effusion.
- ✚ Normal LV systolic function.

Dr. KARTHIK C.S.MD.,PGD(CARDIOLOGY,UKR)

CONSULTANT CARDIOLOGIST

ABI SCANS

MR. NAIR MANJO ARAVINDAKSHAN 45Y/M 84676 12-Feb-2022 02:34:05 PM
Physician Name





ABI SCANS & LABS

A unit of Aarthi Scans and Labs

NAME	MR. NAIR MANOJ ARAVINDAKSHAN	PATIENT ID	84676
ACCESSION NO	88009	AGE/GENDER	45Y /MALE
REFERRED BY	MEDIWHEEL	DATE	12-FEB-2022

VISION TEST

VISUAL ACUITY (VA)

If The Acuity Can Be Measures, Complete This Box Using Snellen acuities or snellen equivalents or NLP,LP,HM, or distance at which the patient sees the 20/100 letter.

WITH BEST CORRECTION

DISTANCE VISION	
Right	10/11
Left	10/11
Both	10/11

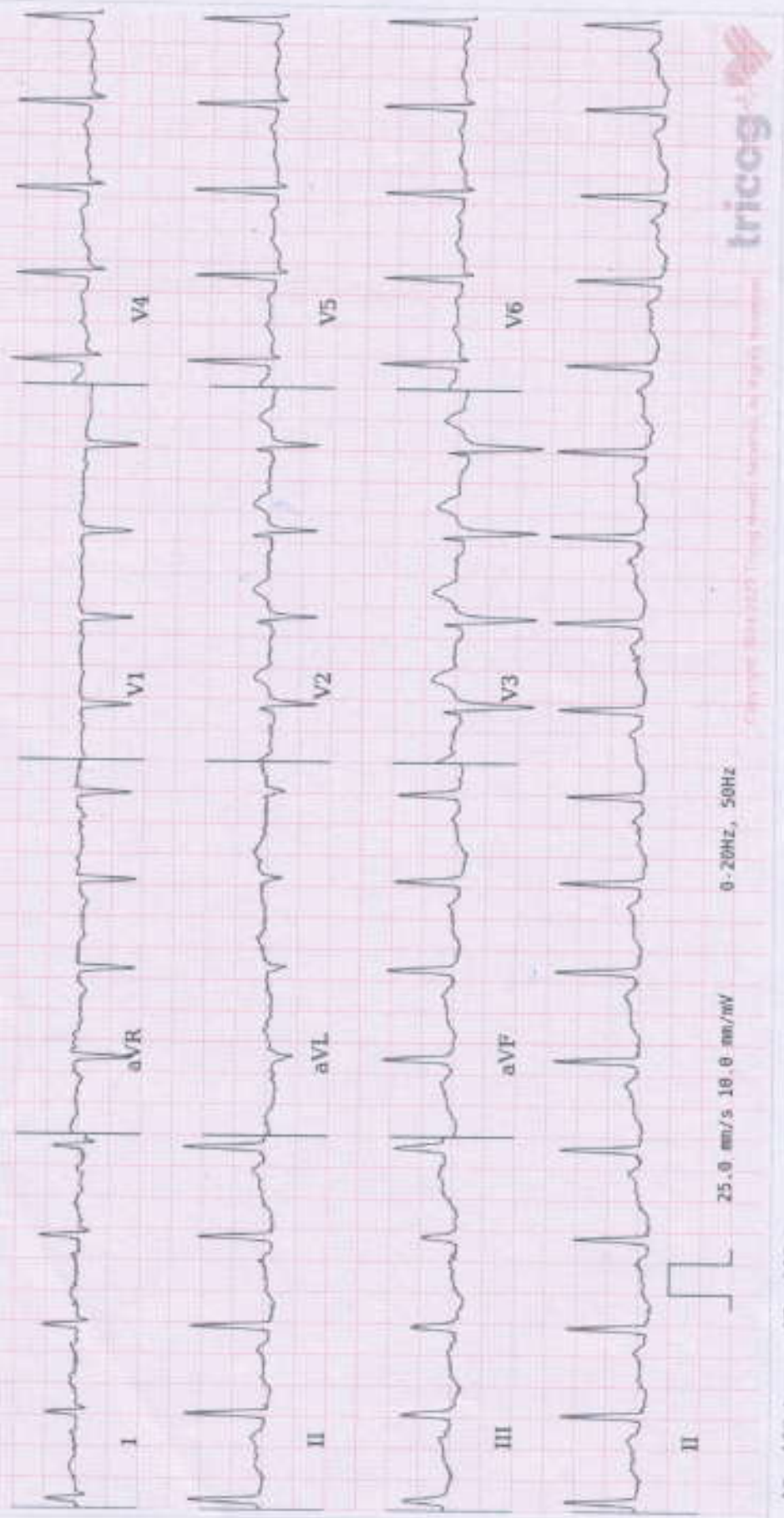
NEAR VISION	
Right	N6
Left	N6
Both	N6

COLOUR VISION	
BOTH	Normal

Age / Gender: 45/Male
Patient ID: 0000084676
Patient Name: MR. NAIR MANOJ ARAVINDAKSHAN

Date and Time: 12th Feb 22 12:08 PM

Bp: - 150/90mmHg



Tachycardia, Abnormal T waves suggestive of Inferior Wall Ischemia. Please correlate clinically.

