



भारतीय विशिष्ट पहचान प्राधिकरण
UNIQUE IDENTIFICATION AUTHORITY OF INDIA

पता:

S/O भूमि सिंह, विकास कॉलोनी,
वेस्ट सीडीए कॉलोनी, शास्त्री नगर,
राजवंशी नगर, पटना,
बिहार - 800023

Address:

S/O Bhim Singh, vikas colony,
west CDA colony, shastri nagar,
Rajvanshi Nagar, Patna,
Bihar - 800023

4920 3111 6070

MEERA AADHAAR, MERI PEHACHAN



GPS Map Camera

वाराणसी, उत्तर प्रदेश, भारत

B36/44B-3, पदमपुरी कॉलोनी, दुर्गाकुंड, नगवा, वाराणसी, उत्तर प्रदेश
221005, भारत

Lat 25.289201°

Long 82.993409°

26/08/23 09:59 AM GMT +05:30

Google



भारत सरकार
GOVERNMENT OF INDIA



यशवंत कुमार सिंह

Yashwant Kumar Singh

ਜਨਮ ਮਿਤੀ/ DOB: 31/07/1979

ਮਰਦ / MALE



4920 3111 6070

ਮੇਰਾ ਆਧਾਰ, ਮੇਰੀ ਪਛਾਣ



GPS Map Camera

वाराणसी, उत्तर प्रदेश, भारत

B36/44B-3, पदमपुरी कॉलोनी, दुर्गाकुंड, नगवा, वाराणसी, उत्तर प्रदेश

221005, भारत

Lat 25.289201°

Long 82.993409°

26/08/23 09:59 AM GMT +05:30

Google



PANACEA HOSPITAL

B 36/44 F.K KABIR NAGAR, DURGAKUND
TOLLFREE NO-18001233070, Whatsapp No - 8795832852
www.paire.org
panaceaquery@gmail.com|panaceahospitalit@gmail.com



OP Slip

Print Date : 26-Aug-2023 09:57AM



UHID No :- UD-23240002273 OP No :- OP-23240007803 OP Date :- 26 Aug 2023 9:57AM

Patient Name :- Mr YASHWANT KUMAR SINGH Age/Sex :- 44 Y/Male Mobile No :- 8427102166

Father :- BHIM SINGH Department :- DIABETES, ENDOCRINOLOGY & METABOLIC PHYSICIAN

Pay Type :- Cash Consultant :- Dr ASHUTOSH MISHRA (MD(MEDICINE), IMS, BHU)

Token No :- NOR - 4 Paid/Bal :- 0.00 /600.00

Patient Type :- Normal

Address :- VIKAN COLONY, WEST CDA COLONY, SHASTRI NAGAR, PATNA, BIHAR

BP :- 110/70 **Rx**

height :- 168

Weight (kg) :- 71.9 (68)

BMI

SpO₂ - 97

PR - 96

NC - 35 (34)

WC - 92 (90)

PEFR - 200

Rx

Influenza. 2M SHI ✓

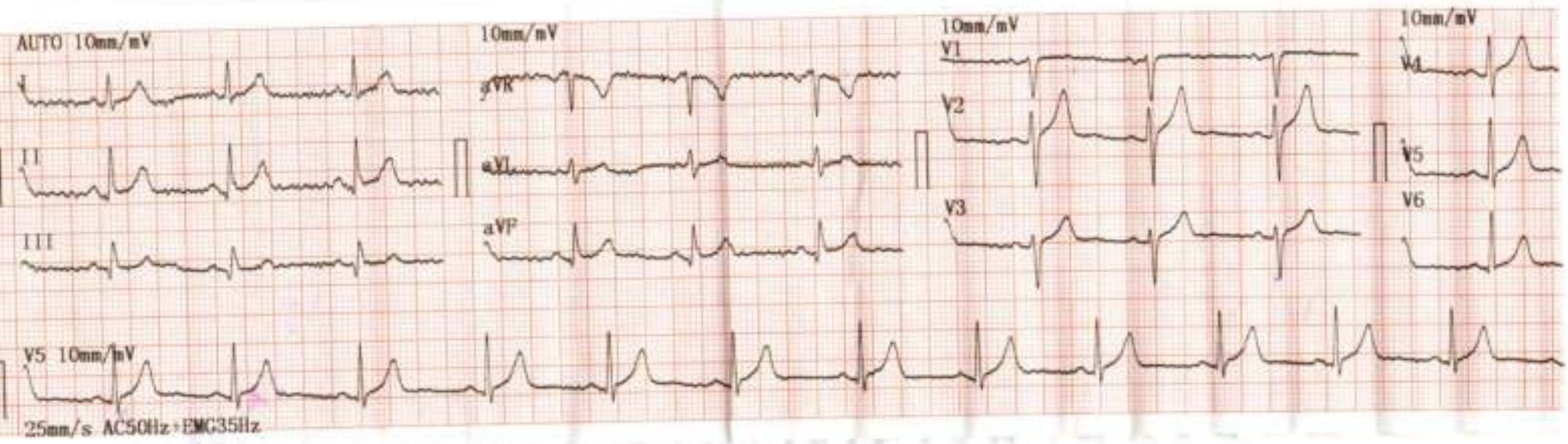
RHZ vaccine. (0.1ml)

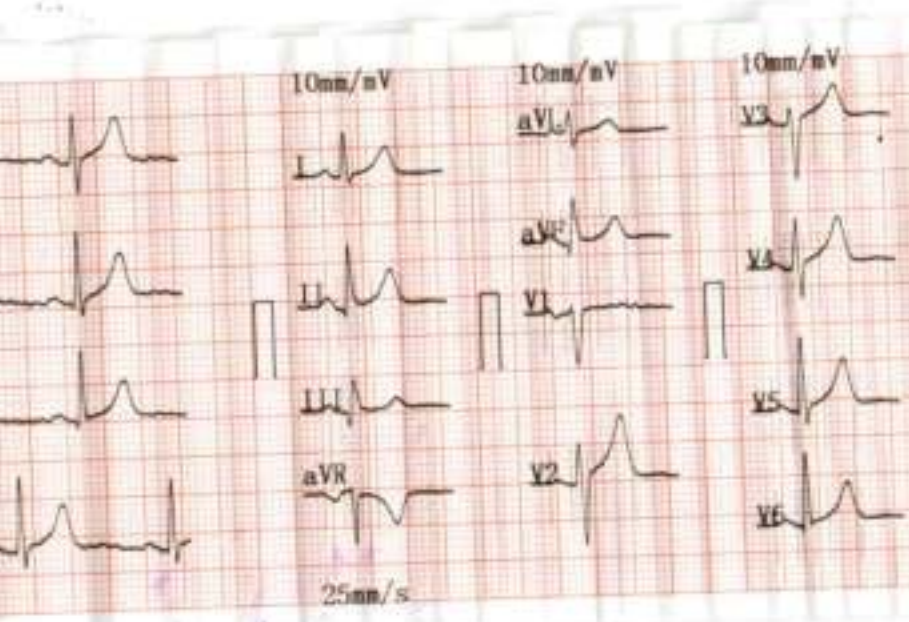
o.e. Bafylson

RA 1 month

Printed By : Ms. RENUKA

Created By : Ms. RENUKA





2023-08-26 10:44

<< Conclusion >>

ID :
 Name : *Yashvard Km. Singh*
 Sex : *MALE*
 Age : *44*
 Height :
 SYS :
 DIA :

Normal Sinus rhythm
 Cardiac electric ax normal.

Weight: *kg* *Report analysis on firm*

Egg is Within Medical Limit

HR : 69 bpm
 PR Interval : 146 ms
 P Duration : 112 ms
 QRS Duration : 72 ms
 T Duration : 178 ms
 QT/QTc : 334/358 ms
 P/QRS/T Axis : 62.3/58.1/46.2 deg
 R(V5)/S(V1) : 0.98/0.68 mV
 R(V5)+S(V1) : 1.66 mV

DR. ASHUTOSH
 MBBS, MD GENERAL MEDICINE
 MCI Reg. No. 45699

Physical



Call Now - 1800-123-3070

PANACEA HOSPITAL

A shelter for many hearts A Home for many lives

(An ISO 9001:2008 Certified Organisation)

Lab Attached with CMC Vellore Under EQAS Scheme

PATIENT'S NAME : Mr. YASHWANT KUMAR SINGH

AGE/SEX: 44 Y/M

REF. BY : Dr. ASHUTOSH MISHRA (MD)

Saturday, August 26, 2023

Echo - Cardiography

MITRAL VALVE Doppler	AML - normal morphology MV Flow - E - 0.7 A-0.4 E/A=1.89	PML - normal morphology MVA - 3.0 cm ² Mitral Regurgitation - No
TRICUSPID VALVE Doppler	Normal TV Flow -No	Tricuspid Regurgitation -No
PULMONARY VALVE Doppler	Normal PV Flow -No	Pulmonary Regurgitation - No
AORTIC VALVE Doppler	Trileaflet-No AV Flow - no	Aortic Regurgitation - no
MEASUREMENT	Aorta - 31.4 (20-38) mm IVS ed - 10.9 (6 -12) mm LVID ed - 50.8 (35 - 55) mm LVPW ed - 10.9 (6 -12) mm OA - 7 (> 5) mm	LA - 28.0 (24-32) mm IVS es -10.9 (6 - 12) mm LVID es - 36.6 (24 - 40) mm LVPW es - 14.8 (6 -12) mm EPSS - 6 (< 9) mm

CONCLUSION

All cardiac chamber dimensions are WNL
No valvular abnormalities
Good LV systolic function present Modified Simpson's method (4C, 2C) (LVEF-54%)
No diastolic dysfunction present (E/A = 1.89)
No RWMA
No pericardial effusion
Intact IAS / IV
No PAH
No intra cardiac mass /thrombus /vegetation

IMPRESSION

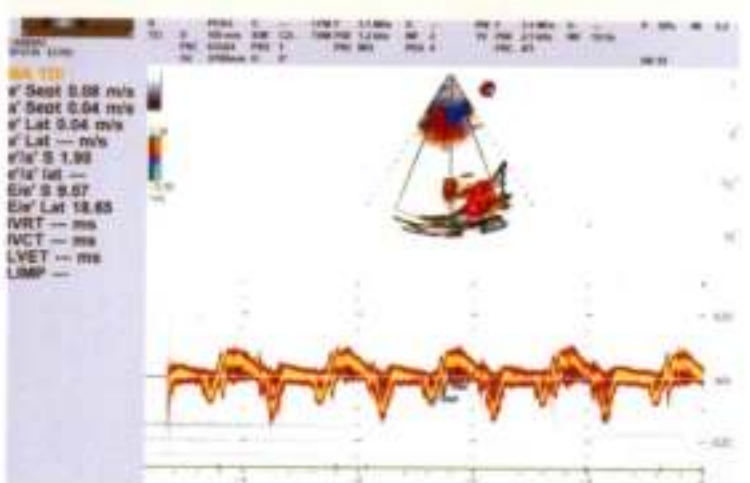
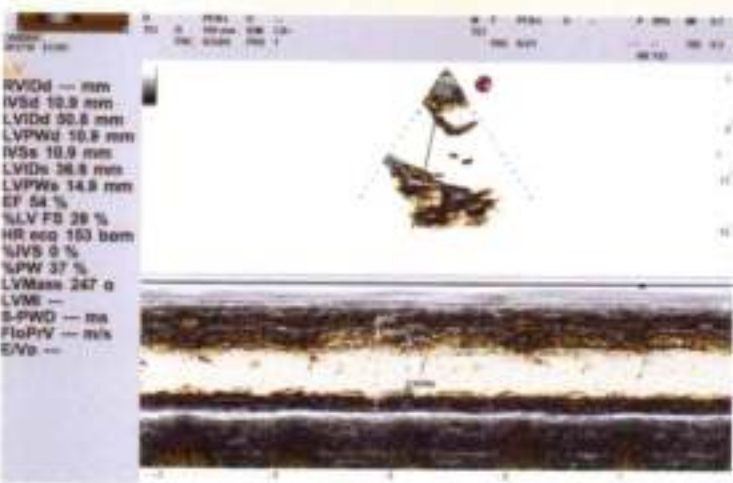
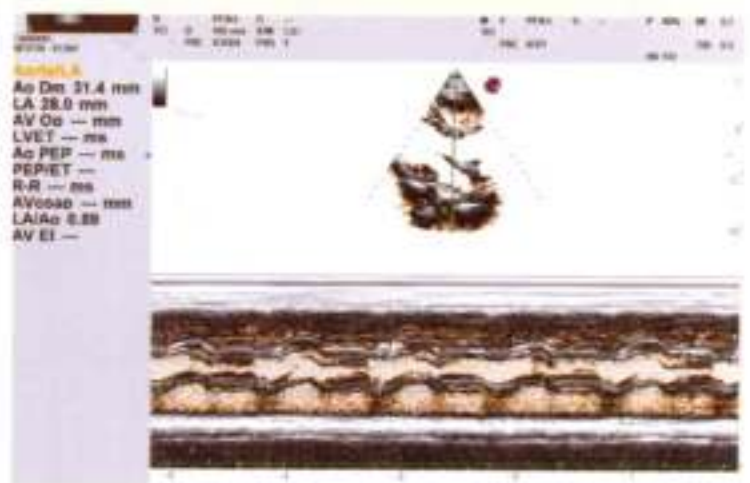
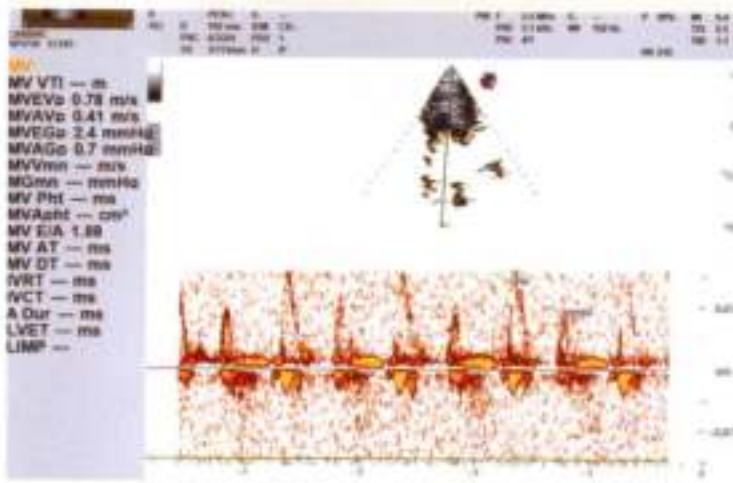
Normal Echocardiogram


Dr. Pallavi Mishra
Special Assistant
(PARE)


Dr. Pallavi Mishra
MBBS, MD (MED) Lucknow
Echocardiography Specialist, MAZ
Non-invasive cardiologist
Women Cardiologist
Diabetocardiologist

Address : Kabir Nagar (Near Sanjay Shiksha Niketan), Durgakund, Varanasi

Mobile : 9554572100 / 9452827505 / Email : 0290004234





PANACEA HOSPITAL

B 36/44 F.K KABIR NAGAR, DURGAKUND
TOLLFREE NO-18001233070. Whatsapp No - 8795832852
www.paire.org
panaceaquery@gmail.com|panaceahospital@gmail.com



OP Slip

Print Date : 26-Aug-2023 01:57PM



UHID No	:- UD-23240002273	OP No	:- OP-23240007828	OP Date	:- 26 Aug 2023 12:06PM
Patient Name	:- Mr YASHWANT KUMAR SINGH	Age/Sex	:- 44 Y/Male	Mobile No	:- 8427102166
Father	:- BHIM SINGH	Department	:- OPHTHALMOLOGY		
Pay Type	:- Cash	Consultant	:- Dr ANKIT SONI (MBBS,MS)		
Token No	:- NOR. - 2	Paid	:- 0.00		
Patient Type	:- Normal				
Address	:- VIKAN COLONY, WEST CDA COLONY, SHASTRI NAGAR, PATNA, BIHAR				

BP :-
height :-
Weight (kg) :-
BMI :-

Rx

VA 6/6x
6/6x

Add
NV +1.00 DS
+1.00 DS

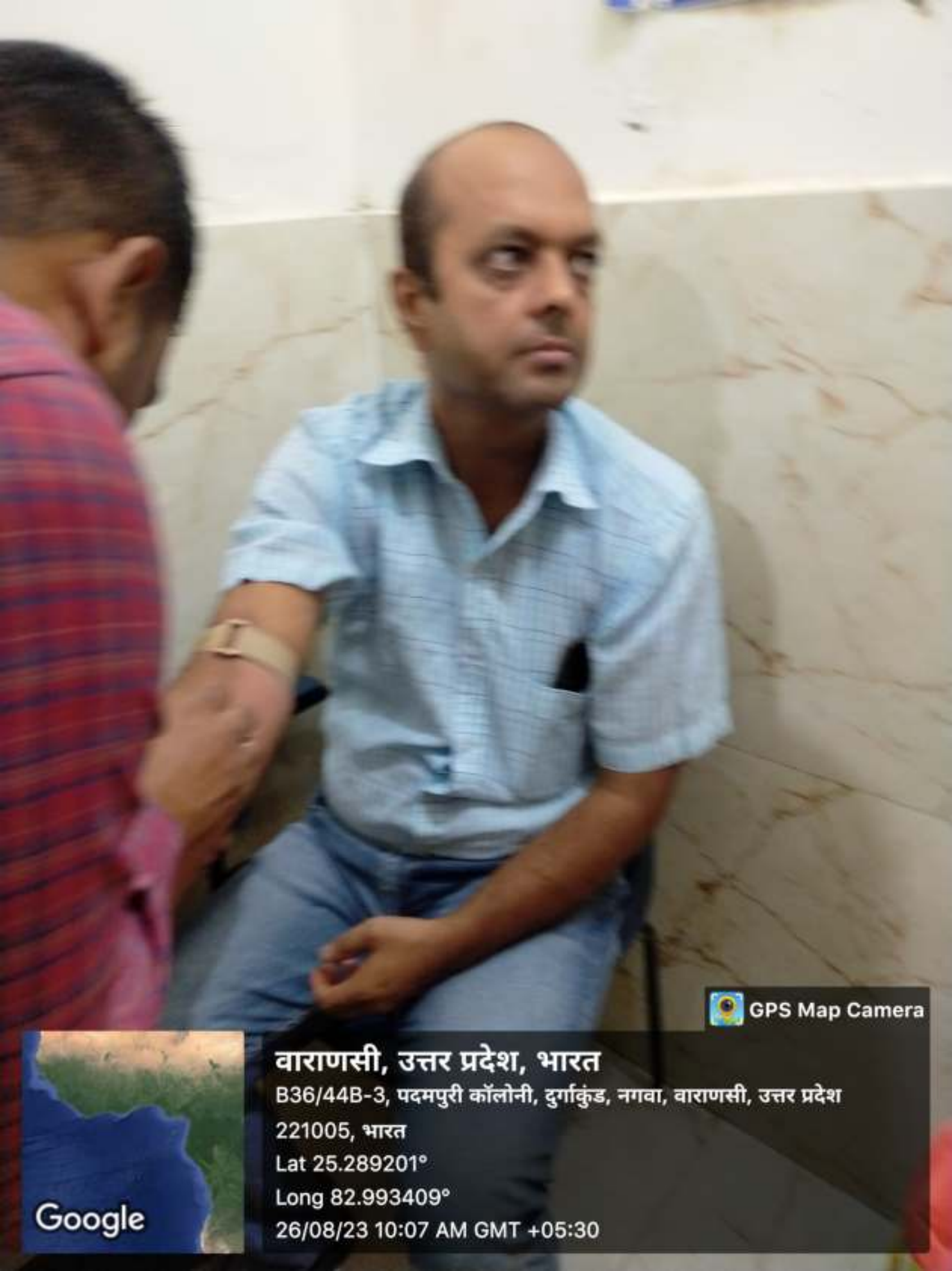Acules clear
clear

~ Leukocoria

0000

Printed By : Mr NITIN YADAV

Created By : Ms. RENUKA



GPS Map Camera

वाराणसी, उत्तर प्रदेश, भारत

B36/44B-3, पदमपुरी कॉलोनी, दुर्गाकुंड, नगवा, वाराणसी, उत्तर प्रदेश

221005, भारत

Lat 25.289201°

Long 82.993409°

26/08/23 10:07 AM GMT +05:30



Google

nacea Hospital

A Shelter For Many Hearts

Home For Many

Member Care Organisation

RD BILLING

(I HELP



GPS Map Camera

वाराणसी, उत्तर प्रदेश, भारत

B36/44B-3, पदमपुरी कॉलोनी, दुर्गाकुंड, नगवा, वाराणसी, उत्तर प्रदेश

221005, भारत

Lat 25.289201°

Long 82.993409°

26/08/23 09:56 AM GMT +05:30

Google



Call Now - 1800-123-3070

PANACEA HOSPITAL

A shelter for many hearts A Home for many lives

(An ISO 9001:2008 Certified Organisation)

Lab Attached with CMC Vellore Under EQAS Scheme

PATIENT'S NAME : YASHWANT KUMAR

AGE/SEX: 44 Y/M

REF. BY : Dr. ASHUTOSH MISHRA


DATE:26/08/2023

X-RAY CHEST (PA VIEW)

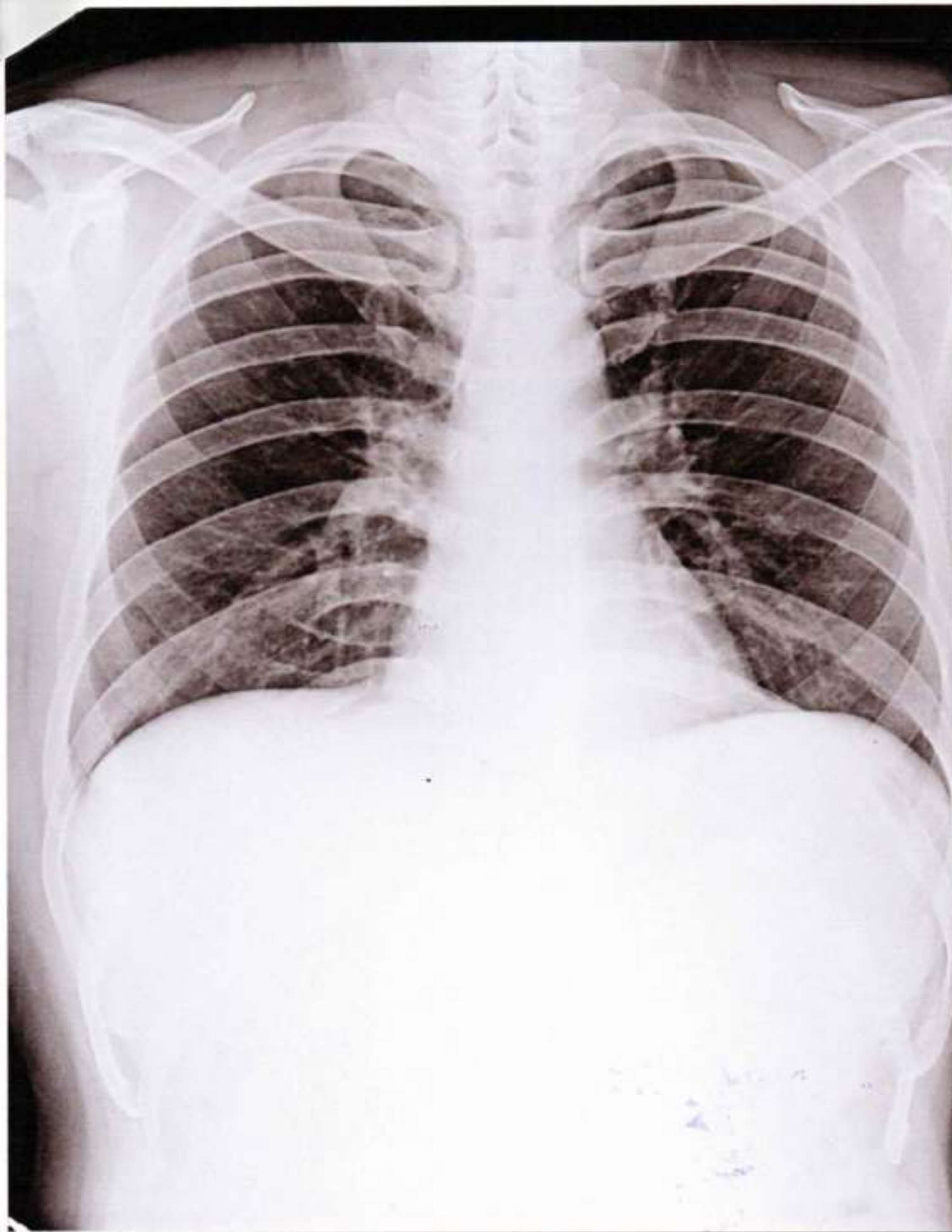
- Bilateral visualized lung fields appear normal.
- Trachea appears normal in position.
- Both hila appear normal in size and are symmetrical.
- Cardiac shadow within normal limits.
- Both CP angles appear clear.
- Bony rib cage and soft tissue shadows appear normal.

IMPRESSION

- **No obvious abnormality noted in the chest radiograph.**


DR. R. K. TIWARI
MD RADIODIAGNOSIS (GOLD MEDALIST)
KGMU, LUCKNOW
EX-RESIDENT (IMS BHU)

Thanks for reference.



YASHWANT KUMAR SINGH 44Y/M 2273 O CHEST P.A. 26-Aug-23 10:49 AM