




भारतीय विशिष्ट पहचान प्राधिकरण

Unique Identification Authority of India



पता: S/O: मेवालाल साहू, लक्ष्मनपुरी, चित्रकूट,
चक गौरा, चित्रकूट, उत्तर प्रदेश, 210205

Address: S/O: Mevalal Sahu, laxmanpuri,
chitrakoot, Chak Gaura, Chitrakoot, Uttar
Pradesh, 210205



5081 2433 9136



1947



help@uidai.gov.in



www.uidai.gov.in



भारत सरकार

Government of India



Issue Date: 16/09/2014



शिव शंकर प्रसाद साहू

Shiv Shankar Prasad Sahu

जन्म तिथि / DOB : 03/05/1992

पुरुष / Male

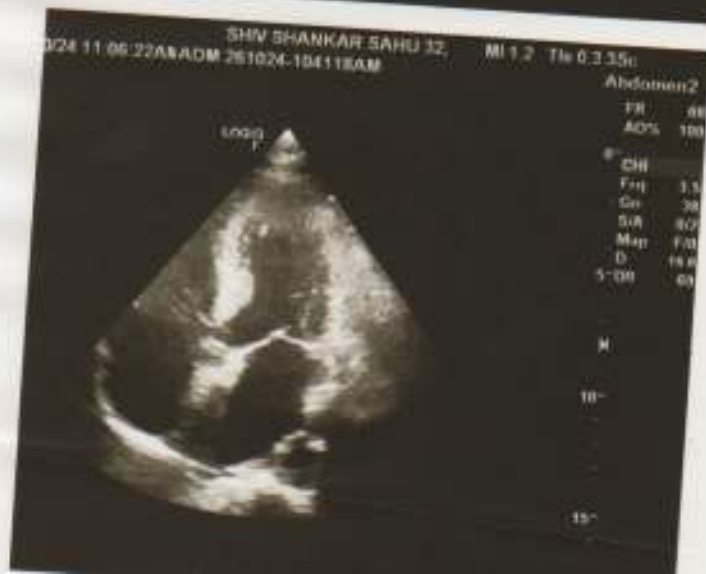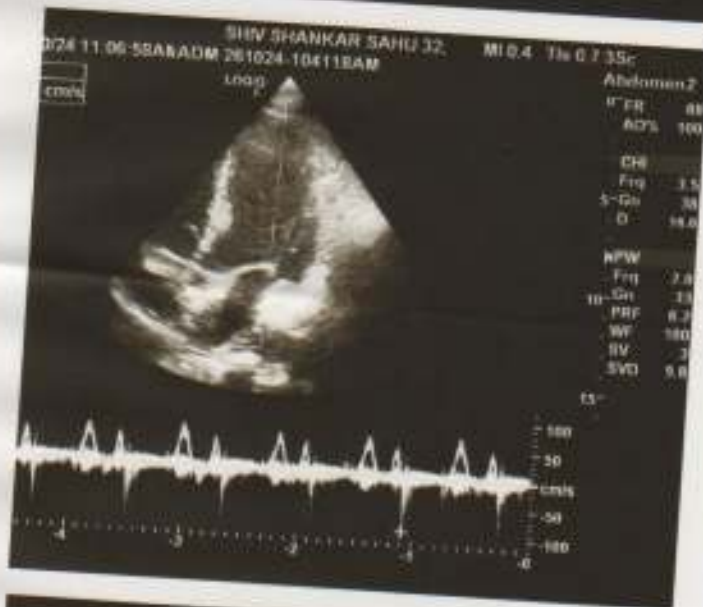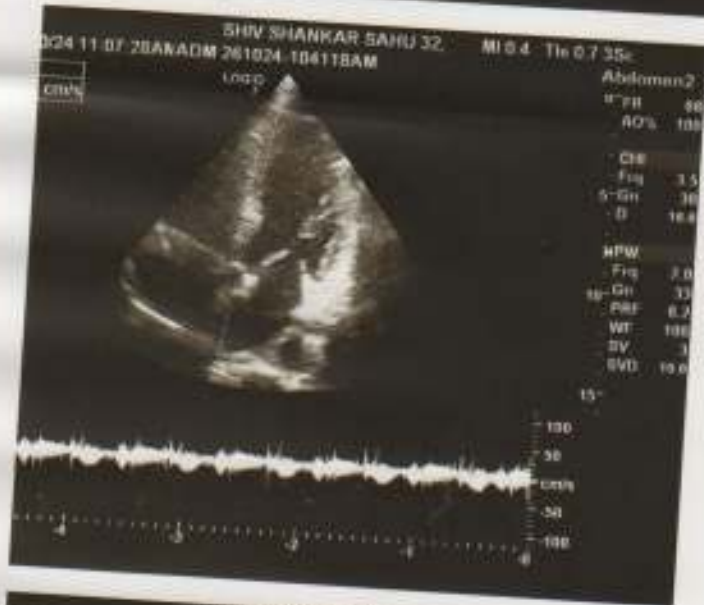
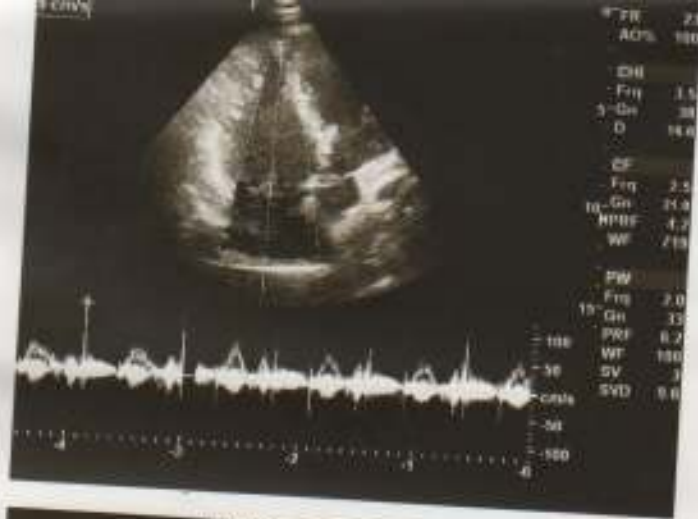


5081 2433 9136



5081 2433 9136

मेरा आधार मेरी पहचान



ADHAAR CARD OF CLIENT SHIV SHANKAR SAHU

DATE: 26 OCTOBER 2024

भारत सरकार
Government of India

शिव शंकर प्रसाद साह
Shiv Shankar Prasad Sahu
जन्म तिथि / DOB : 03/05/1992
पुरुष / Male

Issue Date: 16/08/2014

5081 2433 9136

सेवा भाषाज सेवा गदनास

ORIGINAL SEEN AND VERIFIED

भारतीय विशिष्ट पहचान प्राधिकरण
Unique Identification Authority of India

पता: S/O: मेवालाल साह, लक्ष्मणपुरी, चित्रकूट,
चक गौरा, चित्रकूट, उत्तर प्रदेश, 210205
Address: S/O: Mevalal Sahu, laxmanpuri,
chitrakoot, Chak Gaura, Chitrakoot, Uttar
Pradesh, 210205

Print Date: 04/10/2024

5081 2433 9136

1947

help@uidai.gov.in

www.uidai.gov.in

Shiv Shankar Sahu

CLIENT SIGNATURE



HOSPITAL AUTHORITY SIGNATURE

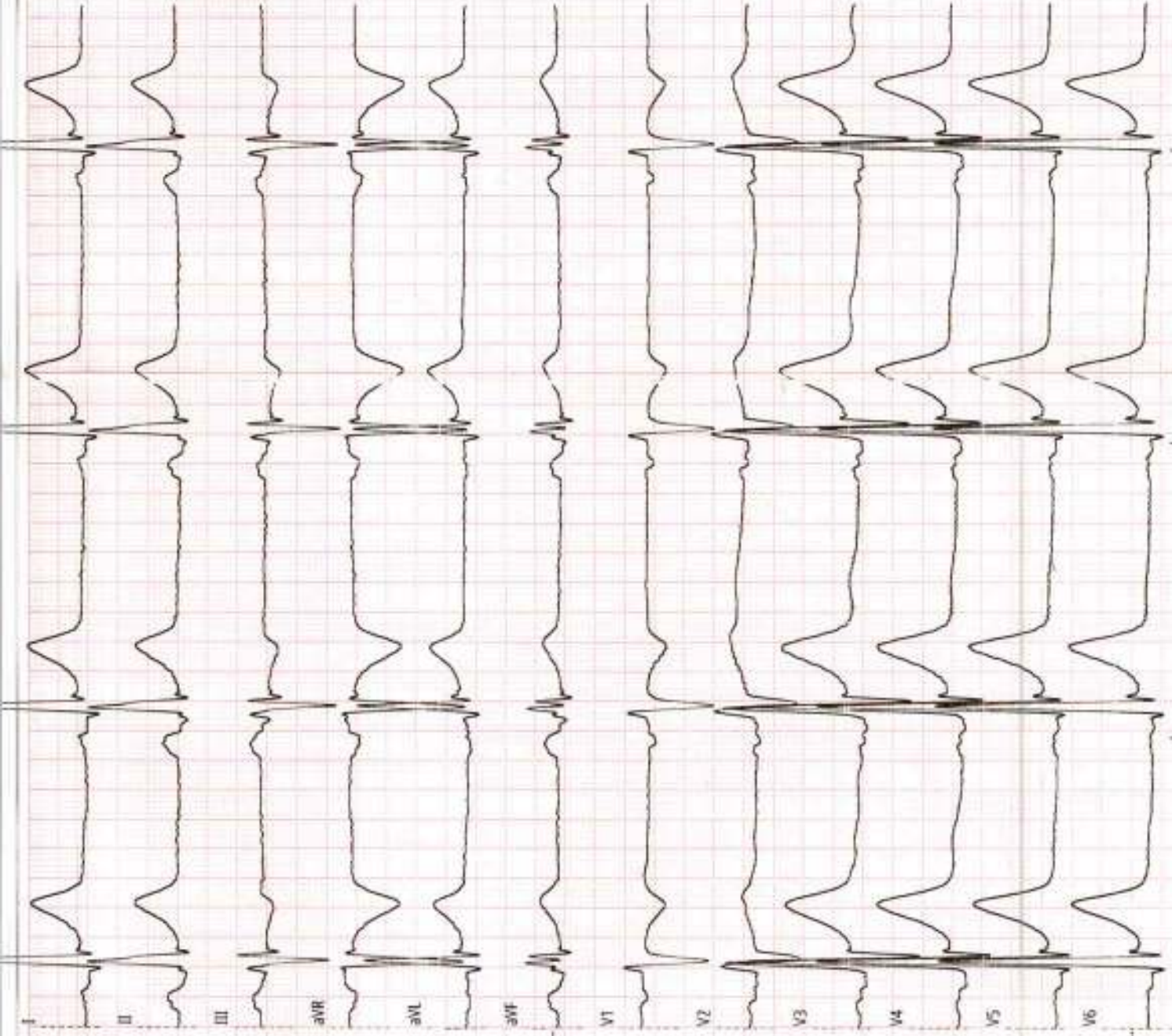
ECG report

ID : 20241026110015
Name : Shiv Shankar Sahu
Gender: M
Age : 32 Years
Dept :
Bed No:

HR : 64 bpm
PR : 134 ms
QRS : 82 ms
QT/QTc : 342/349 ms
P/QRS/T : 67/13/18 °
RV5/SV1 : 1.885/0.527 mV
RV5+SV1 : 2.412 mV

<<Interpretations >>

Sinus rhythm
— Interpretation made without knowing patient's gender/age —
Short QT interval
Lateral ST elevation
— - possible early repolarization
Borderline ECG



0.3Hz - 35Hz - AC 50Hz 50mm/s 20mm/mv 1.0.25 Simultaneous



Affiliated with CGHS / CAPF

TOURUS HOSPITAL

(A Unit of Taurus Medicare Pvt. Ltd.)

208, Safipur 1st Ramadevi, G. T. Road, Kanpur-208 007

Ph.: 0512-2400779, 2400774, 2400737, 8601955058 • E-mail: tourushospital@gmail.com



<i>Patient Name</i>	SHIV SHANKAR SAHU	<i>Patient ID</i>	261024-2
<i>Age/D.O.B</i>	32 YRS	<i>Gender</i>	M
<i>Ref Doctor</i>	SELF	<i>Date</i>	26 Oct 24

XRAY RADIOGRAPH CHEST - PA

Observations

Cardiophrenic and costophrenic angles are normal.
Both hila are normal.
Cardiothoracic ratio is normal.
Soft tissues of the chest wall are normal.
The mediastinal and diaphragmatic outlines appear normal.
Bones of the thoracic cage are normal.
The tracheal lucency is centrally placed.
Both lung fields are clear.

Impression

The study is within normal limits.

Reported By,

M. Farid Khan

Dr. Farid Khan
MBBS, MD

Consultant Radiologist

MPMC - 23324



RAJNI HOSPITAL



A Unit of Shrimati Rajani Dwivedi Charitable Society
1518/5, Daheli Sujapur, By Pass Road, Kanpur-208013
(Near Koyla Nagar Police Chowki)
GST N0:- 09AARTS9188A1ZR



Helpline No.:

+91 -8004991414

+91 -8004991515

+91 -8004991616

+91 -8933048215

Web : www.rajnihospitalin

Email : rajnihospitalknp@gmail.com

Patient Name : Mr. SHIV SHANKAR SAHU

Age : 32years/M

Referred By : Dr. SELF

Date : 26/10/2024

Investigation : USG Whole Abdomen

Liver:

- Liver is enlarged in size mea(153mm). with hyper echoic Echogenicity fatty change. No focal or diffuse lesion seen. Hepatic veins appear normal. No dilation of intrahepatic biliary ducts is seen.

Gall bladder:

- Gall bladder is normal in size and show echo free lumen. Wall thickness is within normal limit. No calculus & mass lesion seen in GB.

Portal vein:

- Normal in size (mm) and shows normal appearance.

C.B.D.:

- Normal in size (mm) and shows normal caliber.

Pancreas:

- Pancreas is normal in size. No calcification or mass lesion seen.

Spleen:

- Spleen is normal in size. Splenic vein appears normal. No mass seen.

Right kidney:

- Normal in size (104x47mm) seen in respective renal areas.

- Cortico - medullary differentiation appears to be normal.

- No calculus or mass lesion seen. No hydronephrosis is seen.

P.T.O



RAJNI HOSPITAL

A Unit of Shrimati Rajani Dwivedi Charitable Society
1518/5, Daheli Sujapur, By Pass Road, Kanpur-208013
(Near Koyla Nagar Police Chowki)
GST NO:- 09AARTS9188A1ZR



Helpline No.:

+91 -8004991414

+91 -8004991515

+91 -8004991616

+91 -8933048215

Web : www.rajnihospitalin

Email : rajnihospitalknp@gmail.com

Left kidney:

- Normal in size (103x51mm) seen in respective renal areas.
- Cortico - medullary differentiation appears to be normal.
- No calculus or mass lesion seen. No hydronephrosis is seen.

Ureter:

- Both ureters are normal.

Urinary bladder:

- Normal in shape and size. Wall thickness is within normal limit.
- No calculus & mass lesion seen.

Prostate:

- Prostate is normal in shape and size. No calculus or mass lesion noted.

Peritoneum/Retroperitoneum:

- Dilated bowel loops with gas shadow seen in whole abdomen.
- No ascitis or fluid is seen. No lymphadenopathis seen.

Impression:

- HEPATOMEGALY WITH FATTY
- DILATED BOWEL LOOPS WITH GAS

ADV: CT- Scan, LFT Please correlate clinically.



Affiliated with CGHS/CAPF/TPA



TAURUS HOSPITAL

(A Unit of Taurus Medicare Pvt. Ltd.)

208. Safipur 1st Ramadevi G. T. Road, Kanpur-208 007

Phone

0512 -2400779

0512 -2400774

0512 -2400737

8601955058




Pathology Report

Lab. No. : 1292	Date : 2024-10-26 10:10:12
Patient Name : Mr. SHIV SHANKAR SAHU	Guardian Name :
Age/Sex : 32 Years/Male	Address : CHITRAKOOT,
Referred By : SELF	
0	

Test Name	Observed Values	Unit	Normal Values
Haematology			
HbA1C	6.3	g/dl	< 5.6 % Normal 5.7-6.4% Pre-Diabetes >6.5 % Diabetes 6.5-7.0% Good control 7.0-8.0% Poor control >8.0% Bad control
CBC (Complete Blood Counts)			
HB	15.30	mg/dl	11.50 - 17.50 mg/dl
TLC	6900	/CU MM	4000-11000
DLC		%	
NEUTROPHILL	63	%	40.0-80.0
LYMPHOCYTE	28	%	20.0-40.0
MONOCYTE	04	%	2.0-10.0
EOSINOPHILL	05	%	1.0-6.0
BASOPHILL		%	2.00 - 2.00 %
RBC	5.12	U/L	4.7-7.1
PCV	43.8	%	36.0-46.0
MCV	85.5	FL	83.0-101.0
MCH	29.9	%	11-20
MCHC	34.9	g/dl	31.5-34.5
PLatelet count	2.50	lakh/cum	1.50-4.0
RDW-CV	13.6	%	11.6-14.0

Dr. Vishakha Pal
MBBS, DCP (PATH)



Affiliated with CGHS/CAPF/TPA



TAURUS HOSPITAL

(A Unit of Taurus Medicare Pvt. Ltd.)

208. Safipur 1st Ramadevi G. T. Road, Kanpur-208 007



Phone
0512 -2400779
0512 -2400774
0512 -2400737
8601955058

Pathology Report

Lab. No. : 1292	Date : 2024-10-26 10:10:12
Patient Name : Mr. SHIV SHANKAR SAHU	Guardian Name :
Age/Sex : 32 Years/Male	Address : CHITRAKOOT,
Referred By : SELF	
0	

Test Name	Observed Values	Unit	Normal Values
Biochemistry			
Serum Bilirubin (Total)	0.87	mg/dl.	0.2 - 1.0
Serum Bilirubin (Direct)	0.19	mg/dl.	Up to 0.4
Serum Cholesterol	173.06	mg/dl.	<_200 to >239 mg/dl
Total Protein	6.71	.	
BLOOD SF	77.16	mg/dl	70-100
Blood Chemistry			
Serum Albumin	3.63	1	
Uric Acid	5.68	mg/dl.	2.6-7.5


Dr. Vishakha Pal
MBBS, DCP (PATH)
Ramadevi, Kanpur



TAURUS HOSPITAL

(A Unit of Taurus Medicare Pvt. Ltd.)

208. Safipur 1st Ramadevi G. T. Road, Kanpur-208 007



Phone
0512 -2400779
0512 -2400774
0512 -2400737
8601955058

Pathology Report

Lab. No. : 1292	Date : 2024-10-26 10:10:12
Patient Name : Mr. SHIV SHANKAR SAHU	Guardian Name :
Age/Sex : 32 Years/Male	Address : CHITRAKOOT,
Referred By : SELF	
0	

Test Name	Observed Values	Unit	Normal Values
-----------	-----------------	------	---------------

Biochemistry

Lipid Profile (With Direct - HDL & L)

Cholestrol	173.06	mg/dl	0.00 - 200.00 mg/dl
triglycerides	88.29	mg/dl	0.00 - 150.00 mg/dl
HDL	48.21	mg/dl	30.00 - 65.00 mg/dl
LDL	76.31	mg/dl	0.00 - 130.00 mg/dl
VLDL	27.31	mg/dl	2.00-30.00
Cholesterol/HDL Ratio	3.58	-	<4.00
LDL/HDL cholesterol Ratio	1.58	-	<3.50
HDL/LDL Cholestrol Ratio	0.63	-	<3.50

Blood Chemistry

L.F.T.

BILI TOTAL	0.87	mg/dl	0-2.0 mg/dl
BILI DIRECT	0.19	mg/dl	0-0.20 mg/dl
BILI (IND)	0.68	mg/dl	0.20-0.60mg/dl
SGPT(ALT)	32.31	IU/L	up-45 U/L
SGOT	26.24	IU/L	up-35 IU/L
ALP(ALKALINE PHOSPHATASE)	81.64	IU/L	54-119 IU/L
TOTAL PROTEIN	6.71	g/dl	6.4-8.3 g/dl
ALBUMIN(ALB)	3.63	g/dl	3.5-4.6 g/dl

Dr. Vishakha Pal
MBBS,DCP(PATH)

Affiliated with CGHS/CAPF/TPA



TAURUS HOSPITAL

(A Unit of Taurus Medicare Pvt. Ltd.)

208. Safipur 1st Ramadevi G. T. Road, Kanpur-208 007



Phone
0512 -2400779
0512 -2400774
0512 -2400737
8601955058

Pathology Report

Lab. No. : 1292	Date : 2024-10-26 10:10:12
Patient Name : Mr. SHIV SHANKAR SAHU	Guardian Name :
Age/Sex : 32 Years/Male	Address : CHITRAKOOT,
Referred By : SELF	
0	

Test Name	Observed Values	Unit	Normal Values
-----------	-----------------	------	---------------

Biochemistry

Alkaline Phosphatase	81.64		
Blood Urea Nitrogen (BUN)	14.08	mg/dl.	5.0 - 20.0
Blood Urea	30.18	mg/dl.	7-20 mg/dl
Serum Creatinine	0.78	mg/dl.	0.8 - 1.4

Haematology

ESR-Wintrobe (Erythrocyte Sedimentation)	06	mm/hr.	
--	----	--------	--

Serology

Blood Group ABO+ Rh	"AB" POSITIVE		gh
---------------------	---------------	--	----



Dr. Vishakha Pal
MBBS, DCP (PATH)

Affiliated with CGHS/CAPF/TPA



TAURUS HOSPITAL

(A Unit of Taurus Medicare Pvt. Ltd.)

208. Safipur 1st Ramadevi G. T. Road, Kanpur-208 007



Phone
0512 -2400779
0512 -2400774
0512 -2400737
8601955058

Pathology Report

Lab. No. : 1292	Date : 2024-10-26 10:10:12
Patient Name : Mr. SHIV SHANKAR SAHU	Guardian Name :
Age/Sex : 32 Years/Male	Address : CHITRAKOOT,
Referred By : SELF	
0	

Test Name	Observed Values	Unit	Normal Values
-----------	-----------------	------	---------------

Hormones & Related Test

T3, T4 (Total) & TSH 3rd Generation

T3	1.98	-	1.30-3.10nmol/L
T4	88.62	-	66.00-181.00nmol/L
TSH	4.12	-	0.45-4.50MIU/L



Affiliated with CGHS/CAPF/TPA



TAURUS HOSPITAL

(A Unit of Taurus Medicare Pvt. Ltd.)

208. Safipur 1st Ramadevi G. T. Road, Kanpur-208 007



Phone

0512 -2400779

0512 -2400774

0512 -2400737

8601955058

Pathology Report

Lab. No. : 1292	Date : 2024-10-26 10:10:12
Patient Name : Mr. SHIV SHANKAR SAHU	Guardian Name :
Age/Sex : 32 Years/Male	Address : CHITRAKOOT,
Referred By : SELF	
0	

Test Name	Observed Values	Unit	Normal Values
-----------	-----------------	------	---------------

Clinical

URINE R/M

Colour	STRAW	-	
Appearance	CLEAR	-	
Specific Gravity	1.020	-	1.005-1.030
Ph	6.0	-	4.5-8.0
Protein	Nil	-	Nil
Glucose	Nil	-	Nil
Pus Cells	1-2	/hpf	0-5
Epithelial Cells	1-2	/hpf	0-5
RBC	Nil	/hpf	Nil
Casts	Not Seen	-	Not Seen
Crystals	Not Seen	-	Not Seen


Dr. Vishakha Pal
MBBS, DCP (PATH)



Affiliated with CGHS / CAPF
TOURUS HOSPITAL

(A Unit of Taurus Medicare Pvt. Ltd.)

208, Safipur 1st Ramadevi, G. T. Road, Kanpur-208 007

Ph.: 0512-2400779, 2400774, 2400737, 8601955058 • E-mail: tourushospital@gmail.com



2DECHO

Normal size LA LV, RA RV

• NO RWMA

• NO MRITRIAR

• NO MBIAS

• NO PE IAPICAL clot

• IVC ~ 12mm
collapse 70% keep

• LVCF - 60%





GPS Map Camera


Kanpur, Uttar Pradesh, India

208, SAFIPUR 2, RAMA DEVI, Ramadevi, Ayodhya Market, Near Mallik Complex, Lal Bungalow, Jajmau Sub Metro City, Kanpur, Uttar Pradesh 208007, India

Lat 26.413899°

Long 80.384243°

26/10/24 10:34 AM GMT +05:30



Google