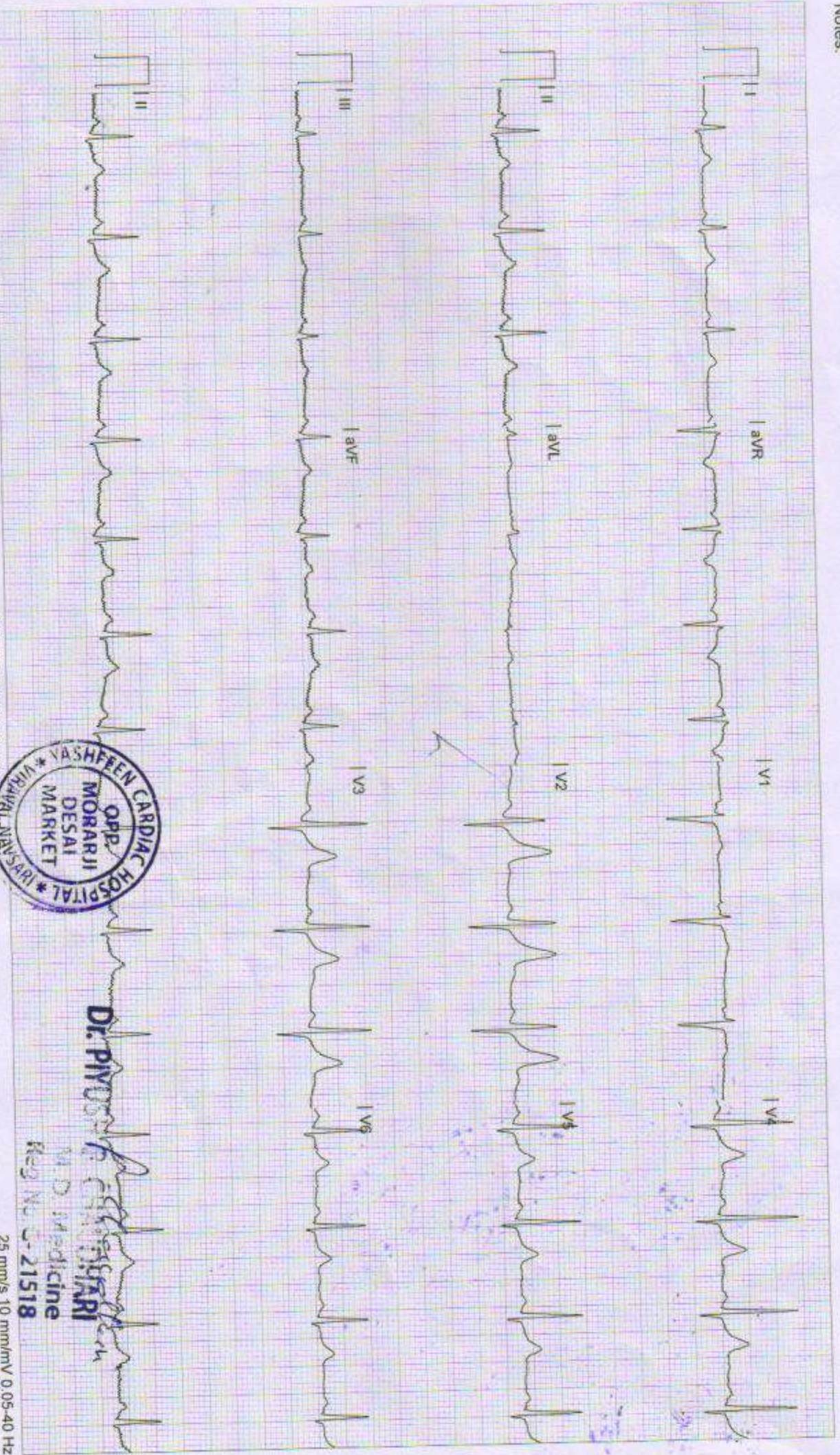


NAITIK  
 ID:  
 DOB:  
 Med: Unknown Unknown  
 Location:  
 Referring Physician:  
 Notes:

14-04-2022 11:56:52  
 Vent Rate: 82 BPM  
 PR int: 127 ms  
 QRS dur: 86 ms  
 QT/QTc: 349/388 ms  
 P-R-T axes: 61 57 50  
 Avg. RR: 727 ms  
 QTcB: 409 ms  
 QTcF: 388 ms

SINUS RHYTHM  
 NORMAL ECG  
 INTERPRETATION BASED ON A DEFAULT AGE OF 40 YEARS  
 UNCONFIRMED REPORT  
 Reviewed by:

Signed by:  
 Date:



**Dr. P. V. Desai**  
 M.D. Medicine  
 Reg. No. 21518



# YASHFEEN CARDIAC HOSPITAL

## EYE DEPARTMENT

Chief Complaint :

Routine Checkup

Medical History : DM / HT / Asthama / Allergy / Heart / Thyroid / .....

Ocular History :

Distance vision      Colour Vision

Visual Acuity :

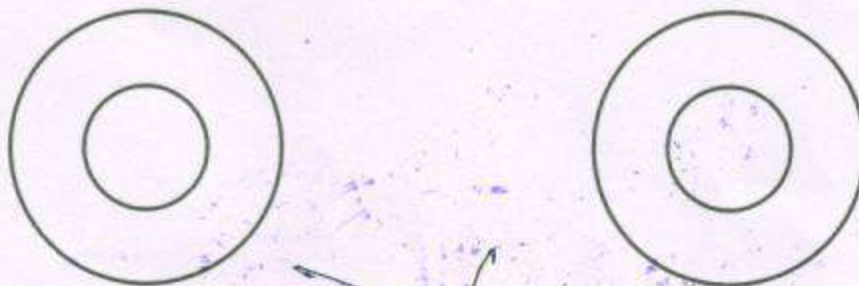$V_n < \frac{6}{6}$  | NB | Normal  
 $\frac{6}{6}$  | NB | Normal

IOP :

	RIGHT EYE (PH.....)				LEFT EYE (PH.....)			
	Sph.	Cyl.	Axis	V/A	Sph.	Cyl.	Axis	V/A
Distance	Plano	—	—	6/6	Plano	—	—	6/6
Near	—	—	—	NB	—	—	—	NB

Distance/Reading/Bi-Focal/Progressive/Separate Glasses

Slit :



NAD

Order  
 - Reg. Plinop  
 After 1 year



Dr. PIYUSH CHAUDHARI  
 M.D. Medicine  
 Reg. No. C-21518



(Regd. No. E / 1390 / Navsari)

# YASHFEEN CARDIAC HOSPITAL™

MANAGED BY :- YASHFEEN FOUNDATION

VIRAVAL, NAVSARI. 396 445. PHONE : (H) (02637) 235725

Website : www.yashfeenhospital.in E-mail : info@yashfeenhospital.in

(Stationary For Report Only)

## 2D ECHO CARDIOGRAPHY COLOUR DOPPLER REPORT

Patient Name & No	: NAITIK DHIRUBHAI PATEL CH22001720	Age/Sex	UHID :	: 225
Doctor	: Mohil Nagad	33/ M	No :	: 214
Referred By	:		Date :	: 14/04/2022

### M-Mode findings

LVIDd : 35mm  
 LVIDs : 24mm  
 IVSd : 10mm  
 PWd : 09mm  
 EF : 55%  
 Aorta : 20mm  
 LA : 27mm

### 2D Imaging

Aortic Valve : Trileaflet, Normal  
 Mitral Valve : Thin, Pliable, Normal Mobility, Normal function  
 Tricuspid Valve : Trace TR, RVSP: 20+ RAP  
 Pulmonary Valve : Normal

=> : All cardiac chambers are normal sized.  
 => : All cardiac valves are normal.  
 => : No regional wall motion abnormality.  
 => : Normal LV systolic function.  
 => : Normal LV diastolic function.  
 => : IAS/IVS intact.  
 => : No obvious clots/ vegetations/ or effusion.  
 => : IVC Normal size.

### Doppler Findings

=> : No MS/MR, No TS/Trace TR, No AS/AR & No PS/PR  
 Mitral inflow Pattern : E > A  
 Tissue Doppler Findings : E' > A'

Impression : Normal LVEF:55%, No RWMA.

Report Prepared By



Report Checked By

Mobin Sheikh

M.D. (Phy.) Dip. Cardiology

**DR. MOHIL NAGAD**

M.D. Medicine, D.M. Cardiology

Senior Consultant- Interventional Cardiology

Reg. No. G- 22893

YASHFEEN HOSPITAL, NAVSARI

Designed By : Sarita Infotech Pvt. Ltd., Navsari

# YASHFEEN IMAGING & RADIOLOGY DEPARTMENT

MANAGED BY :- YASHFEEN FOUNDATION

VIRAVAL, NAVSARI. 396 445. PHONE : (H) (02637) 235725

Website : [www.yashfeenhospital.in](http://www.yashfeenhospital.in) E-mail : [info@yashfeenhospital.in](mailto:info@yashfeenhospital.in)

Name	NAITIK DHIRUBHAI PATEL	Age	33 Y/M
Ref by Dr	SELF	Date	14/04/2022

## USG ABDOMEN (SCREENING)

**Liver** appears normal in size & shape with normal echopattern.  
No e/o focal or diffuse lesion. IHBR appear normal.  
PV and CBD appear normal.

**Gall bladder** appears distended & normal in shape & size. No e/o calculus or mass seen.  
Walls appear normal.

**Pancreas** appears normal in size and echogenicity. No e/o focal or diffuse lesion.

**Spleen** appears normal in size and shows normal echopattern. No e/o focal lesion.

**Both Kidneys** appear normal in size and echopattern. CM Differentiation is preserved.  
No e/o calculus or hydronephrosis on either side.  
Perirenal spaces appear normal on either side.  
Suprarenal regions appear normal on either side. No e/o mass lesion.

**Bladder** is physiologically distended. No e/o calculus or mass. Walls appear normal.


**Prostate** appears normal in size & normal echopattern.  
No e/o calcification.

RIF region appears normal.


No e/o ascites.

### IMPRESSION:

**No significant abnormality detected.**

  
Dr. Dharmesh Desai  
MD



  
Dr. PIYUSH B. CHAUDHARI  
M.D. Medicine  
Reg. No. C-21518



# YASHFEEN CARDIAC HOSPITAL™

At. & Po. Viraval, Navsari. 396 445. Phone (H) (02637) 235725  
Website : www.yashfeenhospital.in E-mail : info@yashfeenhospital.in  
(For Laboratory Reports Only)



Patient Name : NAITIK DHIRUBHAI PATEL  
Ref By Dr. : -  
Sample Time : 14/04/2022 11:34 No : 46

Age : 33 Years Sex : M  
Area : Vansda Date : 14/04/2022  
Time : 4:08PM

## HAEMOGRAM REPORT

Test	Findings	UOM	Normal Range
HAEMOGLOBIN	<b>13.1</b>	gm/dl	M-13.5-17.0 F-11.5-15.5
TOTAL LEUCOCYTE COUNT	<b>26900</b>	cells/cumm	4,000-11,000
<b>Differential Count</b>			
Neutrophil	<b>33</b>	%	40-75
Lymphocytes	<b>11</b>	%	20-40
Eosinophil	<b>48</b>	%	1-6
Monocytes	9	%	2-10
Basophils	0	%	0
PLATELET COUNT	267000	lacs/cumm	1.5-5.5 Lacs
<b>RBC INDICES</b>			
P.C.V.	41.6	%	M-40-56% F-37-47%
M.C.V.	<b>75.2</b>	cu/microns	76-94
M.C.H.	<b>23.7</b>	pg	27-30
M.C.H.C.	31.4	-	30-35
BLOOD GROUP	" B "	-	-
RH FACTOR	POSITIVE	-	-



*P. Chaudhary*  
**Dr. PIYUSH B. CHAUDHARI**  
M.D. Medicine  
Reg. No. C-21518

### Remarks

Designed By : Sarita Infotech Pvt. Ltd., Navsari

*Thanks for Reference*

Yashfeen Cardiac Hospital

*P. Chaudhary*  
**Signature**  
Technician



# YASHFEEN CARDIAC HOSPITAL™

At. & Po. Viraval, Navsari. 396 445. Phone (H) (02637) 235725

Website : www.yashfeenhospital.in E-mail : info@yashfeenhospital.in  
(For Laboratory Reports Only)



Patient Name : NAITIK DHIRUBHAI PATEL

Age : 33 Years Sex : M

Ref By Dr. : -

Area : Vansda Date : 14/04/2022

Sample Time : 14/04/2022 11:34 No : 46

Time : 4:08PM

## HAEMOGRAM

Test	Findings	UOM	Normal Range
<b>HAEMOGRAM</b>			
RED BLOOD CELL	5.53	10 <sup>6</sup> /μL	3.76 - 5.70
E.S.R.(1 hour)	<b>18</b>	mm/hr.	M-5-10, F-5-20



Dr. PIYUSH B CHAUDHARI  
M.D. Medicine  
Reg. No. C-21518

### Remarks

Designed By : Sarita Infotech Pvt. Ltd., Navsari

Yashfeen Cardiac Hospital

*M. H. Tejani*  
Technician  
Signature



# YASHFEEN CARDIAC HOSPITAL™

At. & Po. Viraval, Navsari. 396 445. Phone (H) (02637) 235725  
Website : www.yashfeenhospital.in E-mail : info@yashfeenhospital.in  
(For Laboratory Reports Only)



Patient Name : NAITIK DHIRUBHAI PATEL  
Ref By Dr. : -  
Sample Time : 14/04/2022 11:34 No : 46

Age : 33 Years Sex : M  
Area : Vansda Date : 14/04/2022  
Time : 4:08PM

## HAEMOGLOBIN A1 C ESTIMATION

Test	Findings	UOM	Normal Range
Hb A1C	5.9	%	>8 :Action Suggested, 7-8 :Good Control, <7 :Goal, 6-7 :Near Normal Glycemia, <6 :Non-diabetic Level
<b>Technique</b> METHOD - HPLC			
Mean Blood Glucose	121.3	mg/dL	



Dr. PIYUSH B. CHAUDHARI  
M.D. Medicine  
Reg. No. G-21518

### Remarks

Designed By : Sarita Infotech Pvt. Ltd., Navsari

*Thanks for Reference*

Yashfeen Cardiac Hospital

*[Signature]*  
Technician  
Signature



# YASHFEEN CARDIAC HOSPITAL™

At. & Po. Viraval, Navsari. 396 445. Phone (H) (02637) 235725

Website : [www.yashfeenhospital.in](http://www.yashfeenhospital.in) E-mail : [info@yashfeenhospital.in](mailto:info@yashfeenhospital.in)  
(For Laboratory Reports Only)



Patient Name : NAITIK DHIRUBHAI PATEL

Ref By Dr. : -

Sample Time : 14/04/2022 11:34 No : 46

Age : 33 Years Sex : M

Area : Vansda

Date : 14/04/2022

Time : 4:09PM

## BLOOD SUGAR TEST REPORT

Test	Findings	UOM	Normal Range
FASTING BLOOD SUGAR	100.7	mg/dL	70-110
FASTING URINE SUGAR	NIL	-	NIL
POSTPANDRIAL BLOOD SUGAR	102.0	mg/dL	70-140
POSTPANDRIAL URINE SUGAR	NIL	-	NIL



*P. Chaudhari*  
**Dr. PIYUSH B. CHAUDHARI**  
M.D. Medicine  
Reg. No. G-21518

### Remarks

Designed By : Sarita Infotech Pvt. Ltd., Navsari

*Thanks for Reference*

Yashfeen Cardiac Hospital

*M. Heitejee*  
Technician  
Signature





# YASHFEEN CARDIAC HOSPITAL™

At. & Po. Viraval, Navsari. 396 445. Phone (H) (02637) 235725

Website : www.yashfeenhospital.in E-mail : info@yashfeenhospital.in  
(For Laboratory Reports Only)



Patient Name : NAITIK DHIRUBHAI PATEL

Ref By Dr. : -

Sample Time : 14/04/2022 11:35 No : 46

Age : 33 Years Sex : M

Area : Vansda

Date : 14/04/2022

Time : 4:09PM

## BIOCHEMICAL TEST REPORT

Test	Findings	UOM	Normal Range
S.CREATININE	1.0	mg/dL	M .0.9-1.4 , F. 0.8-1.2
S.URIC ACID	4.3	mg/dL	Male:3.5-7.2, Female:2.6-6.0
BLOOD UREA NITROGEN	13.3	mg/dL	4.7-23.0



*P. Chaudhari*  
**Dr. PIYUSH B CHAUDHARI**  
M.D. Medicine  
Reg.No.C-21518

### Remarks

Designed By : Sarita Infotech Pvt. Ltd., Navsari

*Thanks for Reference*

Yashfeen Cardiac Hospital

*P. Chaudhari*  
Technician  
Signature



# YASHFEEN CARDIAC HOSPITAL™

At. & Po. Viraval, Navsari. 396 445. Phone (H) (02637) 235725

Website : [www.yashfeenhospital.in](http://www.yashfeenhospital.in) E-mail : [info@yashfeenhospital.in](mailto:info@yashfeenhospital.in)  
(For Laboratory Reports Only)



Patient Name : NAITIK DHIRUBHAI PATEL

Ref By Dr. : -

Sample Time : 14/04/2022 11:35 No : 46

Age : 33 Years Sex : M

Area : Vansda Date : 14/04/2022

Time : 4:09PM

## LIPID PROFILE TEST REPORT

Test	Findings	UOM	Normal Range
S.CHOLESTEROL	166.3	mg/dL	<200:Desirable, 200-239:Borderline High, >=240:High
HDL CHOLESTEROL	34.3	mg/dL	<40:Low(High Risk), >=60:High(Low Risk)
LDL CHOLESTEROL	<b>126.7</b>	mg/dL	<100: Optimal, 100-129: Nearoptimal/ Aboveoptimal, 130-159:BorderlineHigh,16 0-189:High,>=190:Very
VLDL CHOLESTEROL	22.9	mg/dL	UPTO 40
S.TRIGLYCERIDES	114.2	mg/dL	<150:Normal, 150-199:Borderline High,200-499:High, >=500:Very Hi
CHOL/ HDL RATIO	4.8	mg/dL	LESS THAN 5
LDL/ HDL RATIO	3.7	mg/dL	LESS THAN 5
REMARK	-	-	-



Dr. PIYUSH B CHAUDHARI  
M.D. Medicine  
Reg No. C-21518

### Remarks

Designed By : Sarita Infotech Pvt. Ltd., Navsari  
*Thanks for Reference*

Yashfeen Cardiac Hospital

*Signature*  
Technician  
Signature



# YASHFEEN CARDIAC HOSPITAL™

At. & Po. Viraval, Navsari. 396 445. Phone (H) (02637) 235725

Website : www.yashfeenhospital.in E-mail : info@yashfeenhospital.in

(For Laboratory Reports Only)



Patient Name : NAITIK DHIRUBHAI PATEL

Ref By Dr. : -

Sample Time : 14/04/2022 11:35 No : 46

Age : 33 Years Sex : M

Area : Vansda Date : 14/04/2022

Time : 4:09PM

## LIVER FUNCTION TEST REPORT

Test	Findings	UOM	Normal Range
<b>Serum Bilirubin</b>			
TOTAL	0.4	mg/dL	0-1.0
DIRECT	0.2	mg/dL	0-0.8
INDIRECT	0.2	mg/dL	0-0.2
SGPT	11.9	IU/L	Below 40.0
S.ALKALINE PHOSPHATASE	126.6	IU/L	CH . 170.0-515.0 A. 37.0-147.0
TOTAL PROTEIN	8.2	g/dl	6.0-8.0
ALBUMIN	4.5	g/dl	3.0-5.0
GLOBULIN	3.6	g/dl	3.0-3.5
A/G	1.3	g/dl	
SGOT	14.7	IU/L	Below 40.0



Dr. PIYUSH B CHAUDHARI  
M.D. Medicine  
Reg. No. G-21518

### Remarks

Designed By : Sarita Infotech Pvt. Ltd., Navsari

Yashfeen Cardiac Hospital

*Piyush B Chaudhari*  
Technician  
Signature

Test reports are subject to technical limitations and should be clinically co-related. Laboratory may be contacted whenever required.



# YASHFEEN CARDIAC HOSPITAL™

At. & Po. Viraval, Navsari. 396 445. Phone (H) (02637) 235725

Website : [www.yashfeenhospital.in](http://www.yashfeenhospital.in) E-mail : [info@yashfeenhospital.in](mailto:info@yashfeenhospital.in)  
(For Laboratory Reports Only)



Patient Name : NAITIK DHIRUBHAI PATEL

Ref By Dr. : -

Sample Time : 14/04/2022 11:35 No : 46

Age : 33 Years Sex : M

Area : Vandsa Date : 14/04/2022

Time : 4:09PM

## THYROID FUNCTION TEST REPORT

Test	Findings	UOM	Normal Range
T3 (TRIODOXYRONINE)	1.73	ng/ml	NEWBORNS:0.73-2.88 6DAYS-3MONTHS:0.80-2.75 4-12MONTHS:0.86-2.65 1-6YEARS:0.92-2.48 7-11YEARS:0.93-2.31 12-20YEARS:0.91-2.18 ADULT:0.80-2.00
T4 (THYROXINE)	8.94	µg/dl	NEWBORNS:5.04-18.5, 6DAYS-3MONTHS:5.41-17.0, 4-12 MONTHS:5.67-16.0, 1-6YEARS:5.95-14.7, 7-11 YEARS:5.99-13.8, 12-20 YEARS:5.91-13.2, ADULTS:5.10-14.1
TSH	3.05	µIU/ml	NEWBORNS:0.70-15.2, 6DAYS-3MONTHS:0.72-11.0, 4-12MONTHS:0.73-8.35, 1-6YEARS:0.70-5.97, 7-11YEARS:0.60-4.84, 12-20YEARS:0.51-4.30, ADULTS:0.27-4.20

### TECHNIQUE

ELECTROCHEMILUMINESCENCE



Dr. PIYUSH B CHAUDHARI  
M.D. Medicine  
Reg No. G-21518

### Remarks

Designed By : Sarita Infotech Pvt. Ltd., Navsari

Yashfeen Cardiac Hospital

Technician Signature



# YASHFEEN CARDIAC HOSPITAL™

At. & Po. Viraval, Navsari. 396 445. Phone (H) (02637) 235725  
Website : [www.yashfeenhospital.in](http://www.yashfeenhospital.in) E-mail : [info@yashfeenhospital.in](mailto:info@yashfeenhospital.in)  
(For Laboratory Reports Only)



Patient Name : NAITIK DHIRUBHAI PATEL

Ref By Dr. : -

Sample Time : 14/04/2022 11:38 No : 46

Age : 33 Years Sex : M

Area : Vansda

Date : 14/04/2022

Time : 4:09PM

## GGT TEST REPORT

Test	Findings	UOM	Normal Range
SERUM GGT	30	U/L	10-71 U/L



Dr. PIYUSH B CHAUDHARI  
M.D. Medicine  
Reg. No. G-21518

### Remarks

Designed By : Sarita Infotech Pvt. Ltd., Navsari

Yashfeen Cardiac Hospital

*P. Chaudhari*  
Technician  
Signature



# YASHFEEN CARDIAC HOSPITAL™

At. & Po. Viraval, Navsari. 396 445. Phone (H) (02637) 235725  
Website : www.yashfeenhospital.in E-mail : info@yashfeenhospital.in  
(For Laboratory Reports Only)



Patient Name : NAITIK DHIRUBHAI PATEL  
Ref By Dr. : -  
Sample Time : 14/04/2022 11:35 No : 46

Age : 33 Years Sex : M  
Area : Vansda Date : 14/04/2022  
Time : 4:09PM

## ROUTINE URINE ANALYSIS

Test	Findings	UOM	Normal Range
<b>PHYSICAL EXAMINATION</b>			
Quantity	-	-	-
Colour	YELLOW	-	-
Appearance	CLEAR	-	-
Reaction	ACIDIC	-	-
Sp. Gravity	QNS	-	-
<b>CHEMICAL EXAMINATION</b>			
U.Albumin	NIL	-	-
Sugar	NIL	-	-
Acetone	NIL	-	-
Bile Salt	NIL	-	-
Bile Pigment	NIL	-	-
Occult Blood	NIL	-	-
<b>MICROSCOPIC EXAMINATION</b>			
Pus Cells	1-2	/hpf	-
Epithelial cells	1-2	/hpf	-
Red cells	ABSENT	/hpf	-
Casts	-	/hpf	-
Crystals	<b>AMORPHOUS SEEN</b>	/hpf	-
Others	-	/hpf	-



Dr. PIYUSH B CHAUDHARI  
M.D. Medicine  
Reg. No. C-21518

### Remarks

Designed By : Sarita Infotech Pvt. Ltd., Navsari  
*Thanks for Reference*

Yashfeen Cardiac Hospital

*M. Heitees*  
Technician  
Signature

# YASHFEEN IMAGING & RADIOLOGY DEPARTMENT

MANAGED BY :- YASHFEEN FOUNDATION

VIRAVAL, NAVSARI. 396 445. PHONE : (H) (02637) 235725

Website : [www.yashfeenhospital.in](http://www.yashfeenhospital.in) E-mail : [info@yashfeenhospital.in](mailto:info@yashfeenhospital.in)

Patient's Name:	NAITIK D. PATEL	Age & Sex:	33Yrs/M
Ref. by Dr.	SELF	Date:	14-04-2022

## X RAY CHEST (PA VIEW)

Prominent bronchovascular markings seen. Otherwise both lung fields appear normal.

Both hila appear normal.

Both CP angles appear clear.


Cardiac size appears within normal limit.

Both domes of diaphragm appear normal.


Bony thoracic cage appears normal.

### IMPRESSION:

Prominent bronchovascular markings seen. Otherwise both lung fields appear normal.

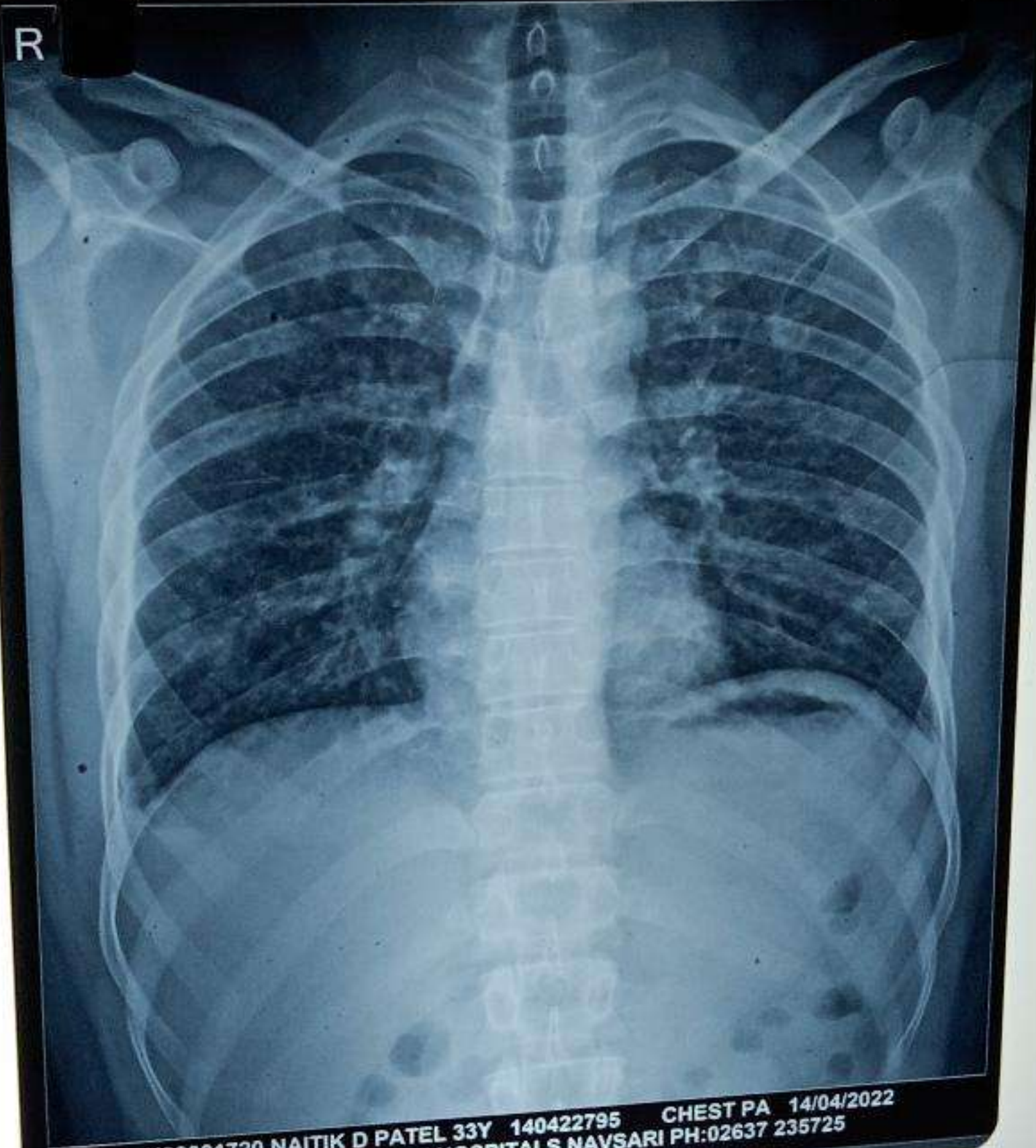
  
Dr. Dharmesh Desai  
MD



  
Dr. PIYUSH B. CHAUDHARI  
M.D. Medicine  
Reg No. C-21518

Please contact immediately for any typographical error.  
This is only professional opinion, not a final diagnosis. Kindly correlate clinically. Not valid for medicolegal purpose.

R



CH22001720 NAITIK D PATEL 33Y 140422795 CHEST PA 14/04/2022  
YASHFEEN GROUP OF HOSPITALS NAVSARI PH:02637 235725