



LETTER OF APPROVAL / RECOMMENDATION

To,

The Coordinator,  
Mediwheel (Arcofemi Healthcare Limited)  
Helpline number: 011- 41195959

Dear Sir / Madam,

**Sub: Annual Health Checkup for the employees of Bank of Baroda**

This is to inform you that the following employee wishes to avail the facility of Cashless Annual Health Checkup provided by you in terms of our agreement.

PARTICULARS	EMPLOYEE DETAILS
NAME	MR. BISOI SUKANT KUMAR
EC NO.	97591
DESIGNATION	CREDIT
PLACE OF WORK	BERHAMPUR, BRAJANAGAR
BIRTHDATE	20-04-1988
PROPOSED DATE OF HEALTH CHECKUP	24-07-2021
BOOKING REFERENCE NO.	21S97591100001382E

This letter of approval / recommendation is valid if submitted along with copy of the Bank of Baroda employee id card. This approval is valid from **22-07-2021** till **31-03-2022** The list of medical tests to be conducted is provided in the annexure to this letter. Please note that the said health checkup is a **cashless facility** as per our tie up arrangement. We request you to attend to the health checkup requirement of our employee and accord your top priority and best resources in this regard. The EC Number and the booking reference number as given in the above table shall be mentioned in the invoice, invariably.

We solicit your co-operation in this regard.

Yours faithfully,

Sd/-

**Chief General Manager**  
**HRM Department**  
**Bank of Baroda**

(Note: This is a computer generated letter. No Signature required. For any clarification, please contact Mediwheel (Arcofemi Healthcare Limited))



बैंक ऑफ बड़ौदा  
Bank of Baroda



नाम

Name

**Sukant Kumar Bisoi**

स.स. नं.

S.C. No.

**97591**

अधिकारी

Issuing Authority

C.M. (Co-ord/Security)

N & G Zone

Signature of Holder



# BHABANI DIAGNOSTIC CENTRE

Goilundi-Kamapalli Road,  
Infront of Nandighos Apartment, Brahmapur  
Mob. : 9078214639, 7008833151

PATIENT NAME : MR.SUKANT KUMAR BISHOYI

AGE :33 Yrs SEX: M

REFERRED BY : NEELANCHAL HOSPITAL

DATE: 24-Jul-21

## ULTRASOUND EXAMINATION OF WHOLE ABDOMEN

### LIVER:

Normal in size. Measures 13.1 cm

**parenchymal echotexture is increased mildly.**

No focal lesion or IHBR Dilatation is seen. P.V—normal.

### GALL BLADDER:

Normal in shape and size with anechoic lumen.

Wall thickness is normal. CBD-normal.

### PANCREAS:

Normal in size & outline. Parenchymal echo is normal. Pancreatic duct is not dilated.

### KIDNEYS:

Rt. Kidney: Normal in shape and size-9.5 x4.2 cm.

Parenchymal echogenicity is normal. Cortical thickness is normal.

Cortico medullary differentiation is well maintained.

Collecting system appears normal.

No evidence of calculus or any pathological abnormalities is seen.

Lt. Kidney: Normal in shape and size-9.7x4.5cm..

Parenchymal echogenicity is normal. Cortical thickness is normal.

Cortico medullary differentiation is well maintained.

Collecting system appears normal.

No evidence of calculus or any pathological abnormalities is seen.

### SPLEEN:

Normal in size & measures 11.3 cm

Parenchymal echogenicity appears normal.

### URINARY BLADDER:

Normal in outline. Wall thickness is normal. .

### PROSTATE:

Normal in size. Vol-13.0cc

Parenchymal echotexture is normal

No free fluid is seen in peritoneal cavity.

### IMPRESSION

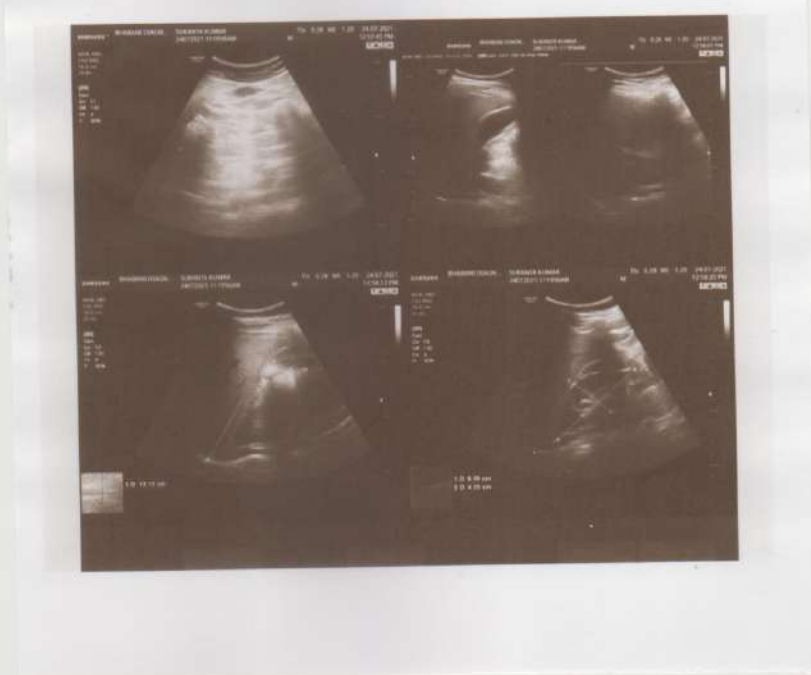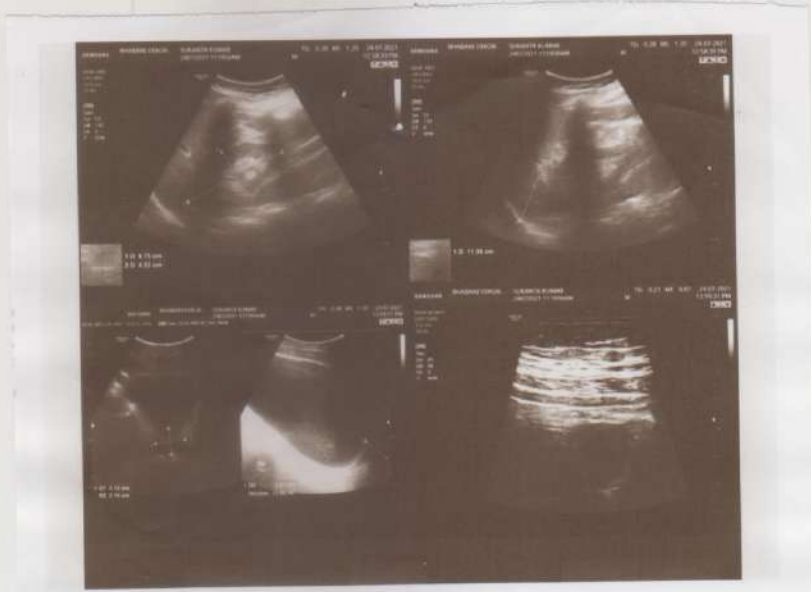
- NO SIGNIFICANT ABNORMALITY IS NOTED IN ABDOMEN & PELVIS.

  
DR. B. A. SUBUDHI, M.D  
RADIOLOGIST

Clinical correlation of this report is a must.

NB. : This report is not valid for medico legal purpose

ULTRA SOUND, DIGITAL X-RAY, VIDEO ENDOSCOPY, ECG, ALL PATHOLOGICAL INVESTIGATION DONE HERE



**BHABANI DIAGNOSTIC CENTRE**

Goilundi-Kamapalli Road,  
Infront of Nandighos Apartment, Brahmapur  
Mob. : 9078214639, 7008833151

**PATIENTS NAME: SUKANT KUMAR BISIO****AGE:33 YRS SEX:M****REFERRED BY : NEELANCHAL HOSPITAL****DATE:24-Jul-2021****X-RAY CHEST PA / VIEW**

- Tracheas is centre.
- Mediastium is central and normal.
- Both lung fields are clear.
- Pulmonary vasculatures are normal.
- Both hila are normal.
- Both cp angels are normal.
- Cardiac shape size are normal .
- Both domes of diaphragm are normal is position.
- Thoracic cage and soft tissue are normal.

**IMPRESSION :NORMAL STUDY.**

P. NO: S.N. 2021

CONSULTANT RADILOGIST

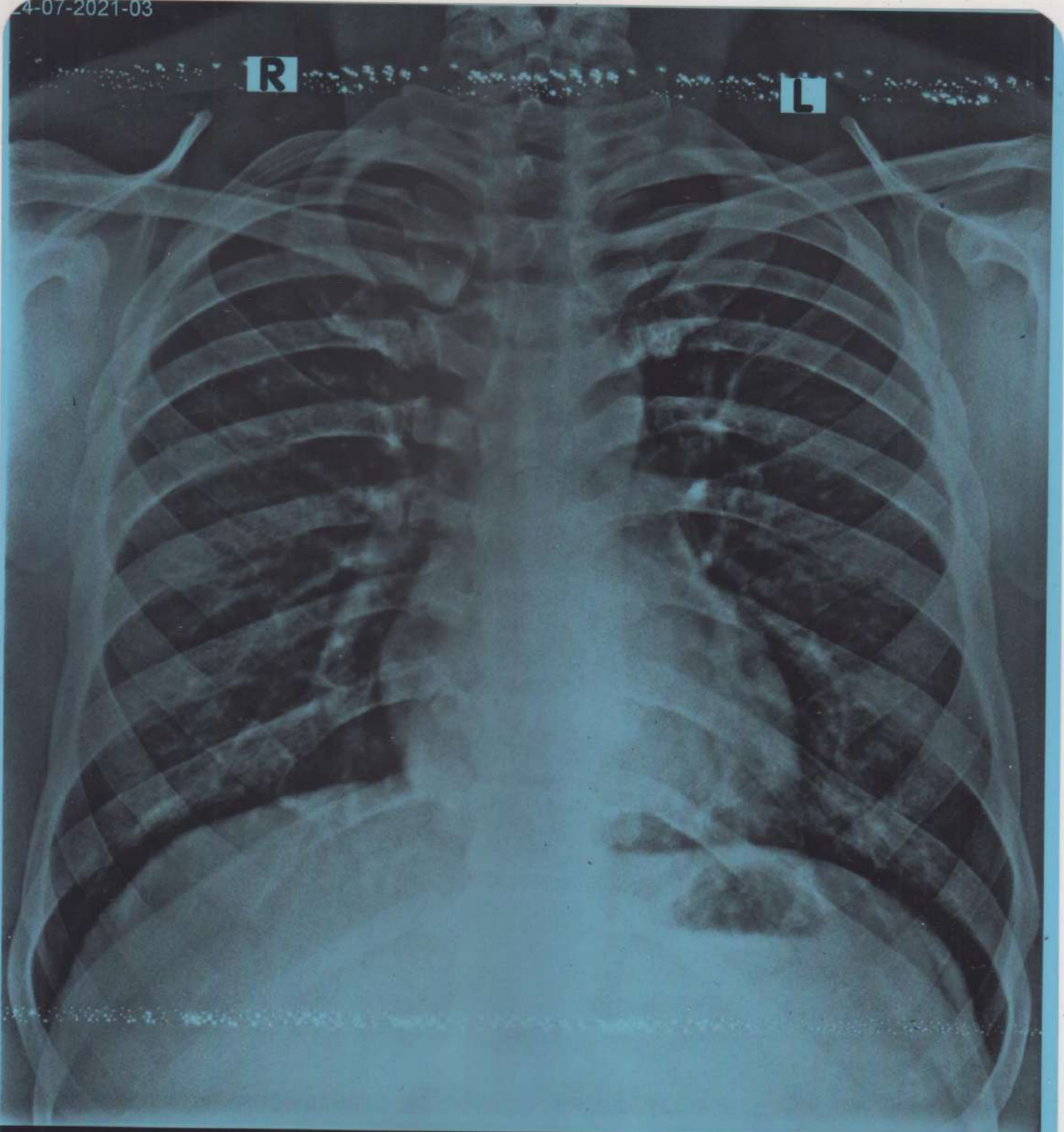
NB. : This report is not valid for medico legal purpose

**ULTRA SOUND, DIGITAL X-RAY, VIDEO ENDOSCOPY, ECG, ALL PATHOLOGICAL INVESTIGATION DONE HERE**

24-07-2021-03

R

L



SC: 62 %

24-07-2021-03 SUKANT KU BISOI, (M) AGE-33 YRS (NEELANCHAL HOSPITAL)  
2021.JUL.24 X -RAY CHEST- PA VIEW  
BHABANI DIAGNOSTIC CENTER, BERHAMPUR



New  
**NEELACHALA HOSPITAL**

*A Promise for Life...*

(AN ISO 9001 : 2008 CERTIFIED HOSPITAL)

<b>NAME</b>	SUKANT KUMAR BISOI	<b>Age/Sex</b>	33Yrs/M
<b>Ref. By.</b>	New Neelachala Hospital	<b>EC No.</b>	97591
<b>Sample.Dt.</b>	24-07-2021	<b>Reporting Dt</b>	26-07-2021

**HAEMOGRAM REPORT**

<u>INVESTIGATION</u>	<u>RESULT</u>	<u>UNIT</u>	<u>NORMAL VALUE</u>
Hb%	: 13.9	gm%	(11.0 - 15.0 gm%)
TWBC	: 9100	Cumm	(4500-11000/ Cumm)
TRBC	: 4.7	Mill	(4.0- 5.5 Mill/ Cumm)
TPC	: 2.8	Lacs / Cumm	(1.5 - 4.0 Lacs / Cumm)
PCV	: 44	%	(35- 50%)
MCV	: 85	fl	(76 - 96 fl)
MCH	: 30.8	pg	(28 - 32 pg)
MCHC	: 35.0	%	(28 - 43%)
RDW (CV)	: 14.9	%	(13 - 16%)
MPV	: 8.9	fl	(8.0 - 10. 5 fl)
PDW	: 9.2	fl	(8.2 - 10.0 fl)

**DIFFERENTIAL COUNT**

<u>INVESTIGATION</u>	<u>RESULT</u>	<u>UNIT</u>	<u>NORMAL VALUE</u>
Neutrophil	68	%	40 - 70
Eosinophil	04	%	01 - 06
Basophil	00	%	00 - 01
Lymphocyte	23	%	15 - 40
Monocyte	05	%	02 - 10

<u>INVESTIGATION</u>	<u>RESULT</u>	<u>UNIT</u>	<u>NORMAL VALUE</u>
ESR	: 14	/mm in 1 <sup>st</sup> hour	05 - 20

**Grouping**

ABO Group & Rh Typing

"AB" & Positive.

("AB"+ve.)

Swayam Prava Pradhan  
Signature  
MD Pathologist  
Regd. No.9431

**N. B. : THIS REPORT IS NOT MEANT FOR MEDICO LEGAL PURPOSE**

KAMAPALI - GOILUNDI LINK ROAD, NEAR NANDIGHOSH APARTMENT, BERHAMPUR - 760 004 (ODISHA)  
CELL : 9438251721, 9337859729



New  
**NEELACHALA HOSPITAL**

*A Promise for Life...*

(AN ISO 9001 : 2008 CERTIFIED HOSPITAL)

<b>NAME</b>	<b>SUKANT KUMAR BISOI</b>	<b>Age/Sex</b>	<b>33Yrs/M</b>
<b>Ref. By.</b>	<b>New Neelachala Hospital</b>	<b>EC No.</b>	<b>97591</b>
<b>Sample.Dt.</b>	<b>24-07-2021</b>	<b>Reporting Dt</b>	<b>26-07-2021</b>

**STOOL ANALYSIS REPORT**

COLOUR :- Yellow  
CONSISTENCY :- Pesty  
REACTION :- Acidic  
MUCUS :- Absent  
BLOOD :- Absent  
PARASITS :- Aduquate  
R.B.C. :- Not Seen  
VEG. CELLS :- Present  
STARCH :- Not Seen  
MICROPHAGES :- Not Seen  
FAT GLOBULES :- Not Seen  
BACTERIAL FLORA :- Reduced.  
YEAST/MOULDS :- Not Seen  
SUGAR :- Not Seen  
OVA/LARVA OF HELMINTUS:- Not Seen  
CYST. VEG FORMS PROTOZOA:- Not Seen  
OCCULT BLOOD :- Not Seen  
PROTOZOA (Cysts/Trohozoites) :- Not Seen  
HELMINTHES (Ova/Larva) :- Not Seen

**Swayam Prava Pradhan**  
Signature  
Microbiologist  
Regd. No. 9431

**N. B. : THIS REPORT IS NOT MEANT FOR MEDICO LEGAL PURPOSE**

KAMAPALI - GOILUNDI LINK ROAD, NEAR NANDIGHOSH APARTMENT, BERHAMPUR - 760 004 (ODISHA)  
CELL : 9438251721, 9337859729





New  
**NEELACHALA HOSPITAL**

*A Promise for Life...*

(AN ISO 9001 : 2008 CERTIFIED HOSPITAL)

<b>NAME</b>	<b>SUKANT KUMAR BISOI</b>	<b>Age/Sex</b>	<b>33Yrs/M</b>
<b>Ref. By.</b>	<b>New Neelachala Hospital</b>	<b>EC No.</b>	<b>97591</b>
<b>Sample.Dt.</b>	<b>24-07-2021</b>	<b>Reporting Dt</b>	<b>26-07-2021</b>

**URINE ANALYSIS REPORT**

**PHYSICAL EXAMINATION**


VOLUME : 10 ML.  
SPECIFIC GRAVITY : 1.018  
COLOUR : PALE YELLOW.  
APPEARANCE : CLEAR.  
TURBIDITY : ABSENT.  
SEDIMENT : ABSENT.  
REACTION : ACIDIC.

**CHEMICAL EXAMINATION**

ALBUMIN : ABSENT.  
SUGAR : NIL.  
PHOSPHATE : ABSENT.  
ACETONE : ABSENT.  
BILE SALT : ABSENT.  
BILE PIGMENT : NEGATIVE.  
UROBILINOGEN : ABSENT.  
CHYLE : ABSENT.  
HAEMATURIA : ABSENT.

**MICROSCOPIC EXAMINATION**

EPITHELIAL CELL : 1 - 4 / H.P.F  
PUS CELL : 2 - 3 / H.P.F  
R.B.C : NIL.  
CAST : NIL.  
CRYSTAL : NIL.  
YEAST : ABSENT.  
OTHERS : ABSENT

  
Swyam Prwva Pradhan  
Signature  
Regd. No.9431

**N. B. : THIS REPORT IS NOT MEANT FOR MEDICO LEGAL PURPOSE**

KAMAPALI - GOILUNDI LINK ROAD, NEAR NANDIGHOSH APARTMENT, BERHAMPUR - 760 004 (ODISHA)

CELL : 9438251721, 9337859729



New

# NEELACHALA HOSPITAL

*A Promise for Life...*

(AN ISO 9001 : 2008 CERTIFIED HOSPITAL)


NAME	SUKANT KUMAR BISOI	Age/Sex	33Yrs/M
Ref. By.	New Neelachala Hospital	EC No.	97591
Sample.Dt.	24-07-2021	Reporting Dt	26-07-2021

## BIOCHEMICAL TEST

<u>TEST</u>	<u>OBSERVED VALUE</u>	<u>UNIT</u>	<u>NORMAL VALUE</u>
Fasting Blood Sugar	84.0	mg/dl	70 - 110
Fasting Urine Sugar	0.3	mmol/L	0 - 0.8
2H PPBS	91	mg/dl	> 140
PP Urine Sugar	06	mg/dl	0 - 15
Serum Uric Acid	4.8	mg/dl	3.4 - 7.0
Serum Creatinine	0.8	mg/dl	0.0 - 1.2
Blood Urea Nitrogen	13.4	mg/dl	07 - 20
BUN Ratio	16.8		

## LIPID PROFILE

<u>TEST</u>	<u>OBSERVED VALUE</u>	<u>UNIT</u>	<u>NORMAL VALUE</u>
Cholesterol	165	mg/dl	130 - 220
Triglycerides	116.5	mg/dl	50 - 160
HDL Cholesterol	51.5	mg/dl	35 - 70
LDL Cholesterol	90.2	mg/dl	60 - 130
VLDL	31	mg/dl	25 - 50
Cholesterol/HDL Ratio	3.20	mg/dl	< 4.5
LDL/HDL Ratio	1.75		

  
Swayan Prava Pradhan  
MD Pathologist  
Regd. No. 9431

**N. B. : THIS REPORT IS NOT MEANT FOR MEDICO LEGAL PURPOSE**

KAMAPALI - GOILUNDI LINK ROAD, NEAR NANDIGHOSH APARTMENT, BERHAMPUR - 760 004 (ODISHA)

CELL : 9438251721, 9337859729



New  
**NEELACHALA HOSPITAL**

*A Promise for Life...*

(AN ISO 9001 : 2008 CERTIFIED HOSPITAL)

<b>NAME</b>	<b>SUKANT KUMAR BISOI</b>	<b>Age/Sex</b>	<b>33Yrs/M</b>
<b>Ref. By.</b>	<b>New Neelachala Hospital</b>	<b>EC No.</b>	<b>97591</b>
<b>Sample.Dt.</b>	<b>24-07-2021</b>	<b>Reporting Dt</b>	<b>26-07-2021</b>


**LIVER FUNCTION TEST (L.F.T)**

<b>TEST</b>	<b>OBSERVED VALUE</b>	<b>UNIT</b>	<b>NORMAL VALUE</b>
Total Protein	6.8	g/dl	5.5 - 8.0
Albumin	4.5	g/dl	3.5 - 5.0
Globulin	2.3	g/dl	2.0 - 3.0
A/G Ratio	1.96		
S.G.O.T	29	IU/L	5 - 40
S.G.P.T	34	IU/L	5 - 50
G.G.T.P	27	mg/dl	15 - 40
Serum Bilirubin (Total)	0.8	mg/dl	0.3 - 1.0
(Direct)	0.2	mg/dl	0.0 - 0.3
(Indirect)	0.6	mg/dl	0.2 - 0.8
Alkaline Phosphate	133	IU/ML	60 - 170

**Thyroid Test**

<b>TEST</b>	<b>OBSERVED VALUE</b>	<b>UNIT</b>	<b>NORMAL VALUE</b>
T3	0.90	ng/mL	0.6 - 1.81
T4	7.48	ug/dl	4.61 - 14.94
TSH	2.32	IU/ml	0.35 - 5.5

<b>TEST</b>	<b>OBSERVED VALUE</b>	<b>UNIT</b>	<b>NORMAL VALUE</b>
HBA1C	5.3	%	below 6.0%-Normal Value 6.0%-7.0%-Good control 7.0%-8.0%-Fair Control 8.0%-10%-Unsatisfactory Control Above 10%-Poor Control

  
Swayam Prava Pradhan  
MD Pathologist  
Regd. No.9431

**N. B. : THIS REPORT IS NOT MEANT FOR MEDICO LEGAL PURPOSE**

KAMAPALI - GOILUNDI LINK ROAD, NEAR NANDIGHOSH APARTMENT, BERHAMPUR - 760 004 (ODISHA)  
CELL : 9438251721, 9337859729

Resting ECG Report

Patient Name Mr-SUKANT KUMAR BISOI 33/M

July 24, 2021

Time: 13:41:09

QT / QTc: 0.148 / 0.169 Sec

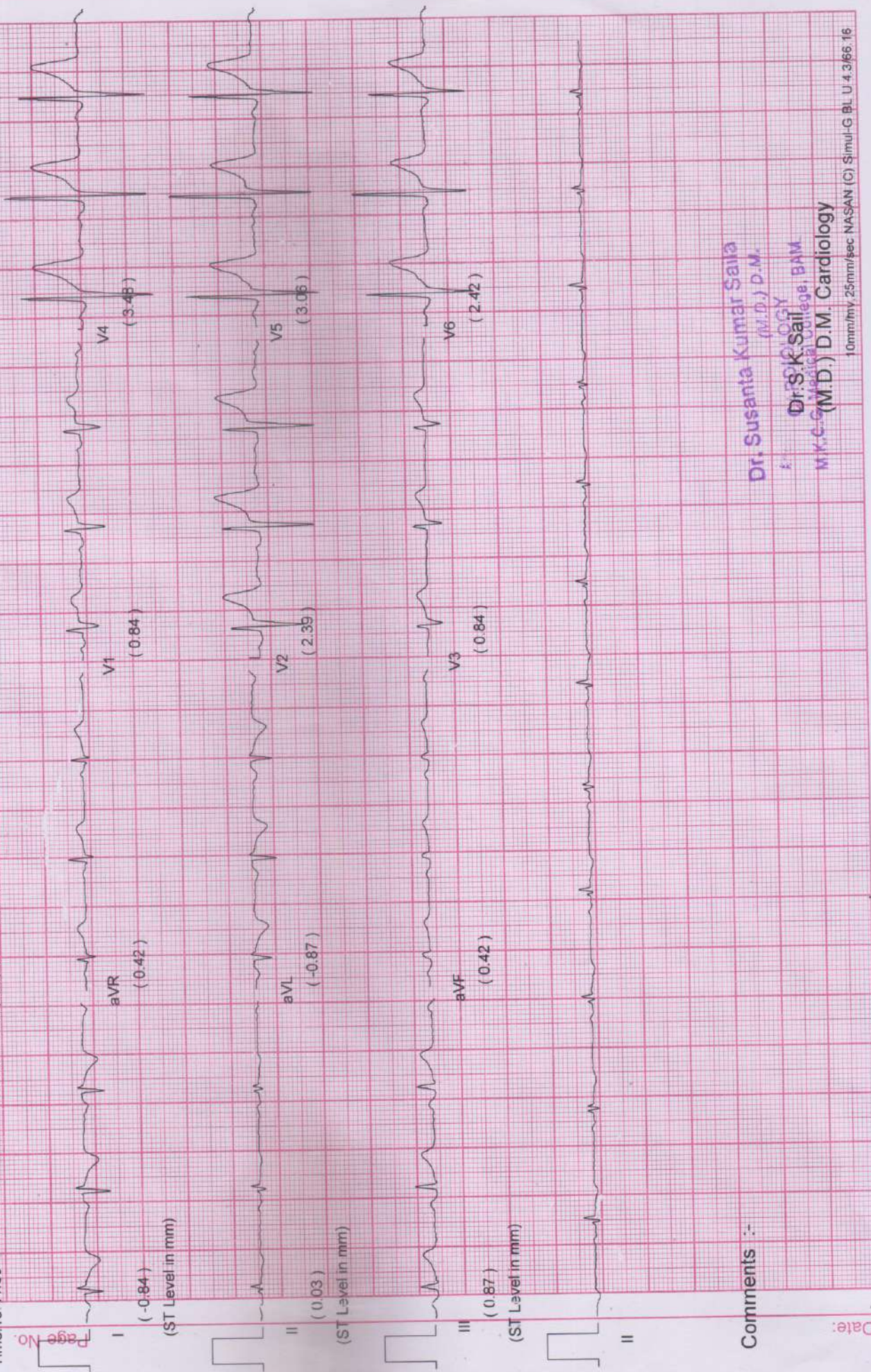
P-QRS-T Axis (138)-(174)-(106) deg

PR Interval: 0.14 sec

QRS Duration: 0.108 Sec

HR: 80 bpm

BP: 0 / 0 mmHg



Comments :-

Dr. Susanta Kumar Saia (M.D.) D.M.

Dr. S. K. Saini (M.D.) D.M. Cardiology  
M.K.C.G. Medical College, BAM

Date:

10mm/mv, 25mm/sec NASAN (C) Simul-G BL U 4.3.66.16