

- COMPU. PATHOLOGY • ALLERGY TESTING
- DIGITAL WHOLE BODY X-RAYS
- DIGITAL 3D SONOGRAPHY
- DIGITAL WHOLE BODY COLOUR DOPPLER
- DIGITAL 2-D ECHO WITH COLOUR DOPPLER
- E.C.G. • LUNG FUNCTION TEST
- MAMMOGRAPHY & BONE MINERAL DENSITOMETRY

- COMPUTERISED STRESS TEST
- DENTAL
- ADVANCED DENTISTRY
- PHYSIOTHERAPY
- AUDIOMETRY & SPEECH THERAPY
- FULL BODY HEALTH CHECK-UPS
- CORPORATE HEALTH CHECKUPS



# HEALTHCARE

MEDICAL CENTRE & DIAGNOSTICS

NAME	MR MAHESH K JADHAV	DATE	26.03.2022
		AGE	33 YRS
REF. BY DR	MEDIWHEEL	SEX	MALE

## X-RAY CHEST (PAVIEW).

The lungs on the either side show equal translucency.

The pleural spaces are normal.

The cardiac size is normal.

The domes of the diaphragms are normal in position, and show smooth outline.

Ribs appear normal.

### **IMPRESSION :**

**NO EVIDENCE OF PLEURAL OR PARENCHYMAL PATHOLOGY IS NOTED.**  
Correlate clinically .

*for Das*  
**DR. SHRIKANT BODKE**  
(Consultant Radiologist)

Investigations have their limitation. Solitary pathological/Radiological & other investigations never confirm the final diagnosis. They only help in diagnosing the disease in correlation to clinical symptoms & other related tests. Please interpret accordingly.  
Clinical correlation and further evaluation is required, if indicated.

- BORIVALI CENTRE** 1ST FLR., YOGI AVENUE, YOGI NAGAR, BORIVALI (W), MUMBAI - 400092. • TEL.: 2899 6565 / 2899 1376 • MOB.: 90222 39301
- KANDIVALI CENTRE** MAHAVIR SURYADARSHAN SOC., SATYANAGAR RD., MAHAVIR NAGAR, KANDIVALI (W), MUMBAI - 67. • TEL.: 2868 0090 / 6522 6565 / 2869 7808 • MOB.: 90220 54458
- KANDIVALI CENTRE** SHOP NO. 44/49, EMP 71, EVERSHERE MILLENNIUM PARADISE, THAKUR VILLAGE, 120 FEET ROAD, KANDIVALI (E) MUMBAI - 400101. • TEL.: 2885 7171 / 89288 41541
- DAHISAR CENTRE** NILANGI APARTMENT, KANDERPADA JUNCTION, DAHISAR (W), MUMBAI - 400068. • TEL.: 2893 3427 • MOB.: 90220 58504
- GORAI CENTRE** VICTORY HEIGHTS, GORAI MAIN ROAD, OPP. SUVIDYA SCHOOL, BORIVALI (W), MUMBAI - 400092. • TEL.: 2869 6556 • MOB.: 90224 88354 / 72080 02565
- GOREGAON CENTRE** M.G. ROAD, NEAR JAIN MANDIR, GOREGAON (W), MUMBAI - 400062. • TEL.: 2873 3030 / 2873 3131 • MOB.: 93213 83806
- GOREGAON (EAST)** SATELLITE GARDENS, FILM CITY ROAD, NEAR SATELLITE TOWER, GOREGAON (EAST), MUMBAI - 400063 • TEL.: 79773 74838 / 79773 62922
- MIRA ROAD** UNIT NO. R13, RNA LIBERTY REST, NEAR JANGID CIRCLE, VIJAY PARK, MIRA ROAD (EAST), MUMBAI - 401107. • TEL.: 70218 04221 / 70218 27389

Website : [www.healthcarediag.com](http://www.healthcarediag.com) • E-mail : [healthcare.medicals@gmail.com](mailto:healthcare.medicals@gmail.com)

"Home Visit Facility Call On 76667 66307"

- COMPU. PATHOLOGY • ALLERGY TESTING
- DIGITAL WHOLE BODY X-RAYS
- DIGITAL 3D SONOGRAPHY
- DIGITAL WHOLE BODY COLOUR DOPPLER
- DIGITAL 2-D ECHO WITH COLOUR DOPPLER
- E.C.G. • LUNG FUNCTION TEST
- MAMMOGRAPHY & BONE MINERAL DENSITOMETRY

- COMPUTERISED STRESS TEST
- DENTAL
- ADVANCED DENTISTRY
- PHYSIOTHERAPY
- AUDIOMETRY & SPEECH THERAPY
- FULL BODY HEALTH CHECK-UPS
- CORPORATE HEALTH CHECKUPS



# HEALTHCARE

MEDICAL CENTRE & DIAGNOSTICS

NAME	MR MAHESH K JADHAV	DATE	26.03.2022
REF. BY DR.	MEDIWHEEL	AGE	33 YRS
		SEX	MALE

## REAL TIME ABDOMINAL SONOGRAPHY SHOWS,

**LIVER** : Liver is normal in size showing homogenous parenchymal echotexture . There is no evidence of solid or cystic mass .The portal and the hepatic venous system appears normal.

**GALL BLADDER** : The Gall bladder is partially distended .The gall bladder wall of normal thickness . No evidence of gall stones.

**PANCREAS** : Pancreas is normal in size with smooth margin.and homogenous paranchymal echotexture.No focal lesion seen.

**KIDNEYS** : Both kidneys are normal in size and shows homogenous cortical echotexture.Central calyceal echoes appears normal. There is no evidence of hydronephrosis or renal calculus.

(a) Right kidney measures: 9.7 x 4.2 cms

(b) Left kidney measures: 10.0 x 4.5 cms.

**SPLEEN** : The spleen is normal in size with homogenous paranchymal echotexture.No focal lesion are seen.

**URINARY BLADDER** : Urinary bladder is well distended.No evidence of calculus or intraluminal mass seen in the bladder.

**PROSTATE** :Prostate is normal in size & volume is 13 cc.

**IMPRESSION :**  
**NO SIGNIFICANT ABNORMALITY DETECTED.**

*for Das*  
**DR.SHRIKANT BODKE**  
**CONS.RADIOLOGIST.**

Note : Investigations have their limitations. Solitary radiological investigations never confirm the final diagnosis. They only help in diagnosing the disease in correlation to clinical symptoms and other related tests. USG is known to have interobserver variation. Further / Follow-up imaging may be needed in some cases for confirmation of USG findings. Patient was explained in detail about the USG findings and its limitations. Please interpret accordingly.

- BORIVALI CENTRE** 1ST FLR., YOGI AVENUE, YOGI NAGAR, BORIVALI (W), MUMBAI - 400092. • TEL.: 2899 6565 / 2899 1376 • MOB.: 90222 39301
- KANDIVALI CENTRE** MAHAVIR SURYADARSHAN SOC., SATYANAGAR RD., MAHAVIR NAGAR, KANDIVALI (W), MUMBAI - 67. • TEL.: 2868 0090 / 6522 6565 / 2869 7808 • MOB.: 90220 54458
- KANDIVALI CENTRE** SHOP NO. 44/49, EMP 71, EVERSHINE MILLENNIUM PARADISE, THAKUR VILLAGE, 120 FEET ROAD, KANDIVALI (E) MUMBAI - 400101. • TE.: 2885 7171 / 89288 41541
- DAHISAR CENTRE** NILANGI APARTMENT, KANDERPADA JUNCTION, DAHISAR (W), MUMBAI - 400068. • TEL.: 2893 3427 • MOB.: 90220 58504
- GORAI CENTRE** VICTORY HEIGHTS, GORAI MAIN ROAD, OPP. SŪVIDYA SCHOOL, BORIVALI (W), MUMBAI - 400092. • TEL.: 2869 6556 • MOB.: 90224 88354 / 72080 02565
- GOREGAON CENTRE** M.G. ROAD, NEAR JAIN MANDIR, GOREGAON (W), MUMBAI - 400062. • Tel.: 2873 3030 / 2873 3131 • MOB.: 93213 83806
- GOREGAON (EAST)** SATELLITE GARDENS, FILM CITY ROAD, NEAR SATELLITE TOWER, GOREGAON (EAST), MUMBAI - 400063 • TEL.: 79773 74838 / 79773 62922
- MIRA ROAD** UNIT NO. R13, RNA LIBERTY REST, NEAR JANGID CIRCLE, VIJAY PARK, MIRA ROAD (EAST), MUMBAI - 401107. • TEL.: 70218 04221 / 70218 27389

Website : [www.healthcarediag.com](http://www.healthcarediag.com) • E-mail : [healthcare.medicals@gmail.com](mailto:healthcare.medicals@gmail.com)

"Home Visit Facility Call On 76667 66307"

- COMPU. PATHOLOGY
- DIGITAL X-RAY
- DIGITAL SONOGRAPHY
- DIGITAL COLOR DOPPLER
- 2D ECHO CARDIOGRAPHY
- MAMMOGRAPHY & BONE MINERAL DENSITOMETRY ( BMD )
- ECG ■ PFT
- COMPU. TREADMILL TEST
- PHYSIOTHERAPY
- DENTAL
- HEALTH CHECK-UP



# HEALTHCARE

MEDICAL CENTRE & DIAGNOSTICS

## ELECTROCARDIOGRAM (ECG)

MR MAHESH K JADHAV  
 2018115643  
 26-03-2022  
 ECG

PATIENT MR. MAHESH K JADHAV AGE 33 SEX M

REF. BY DR. MEDINHEEL DATE 26.03.2022

INTERPRETATION :

*Normal*



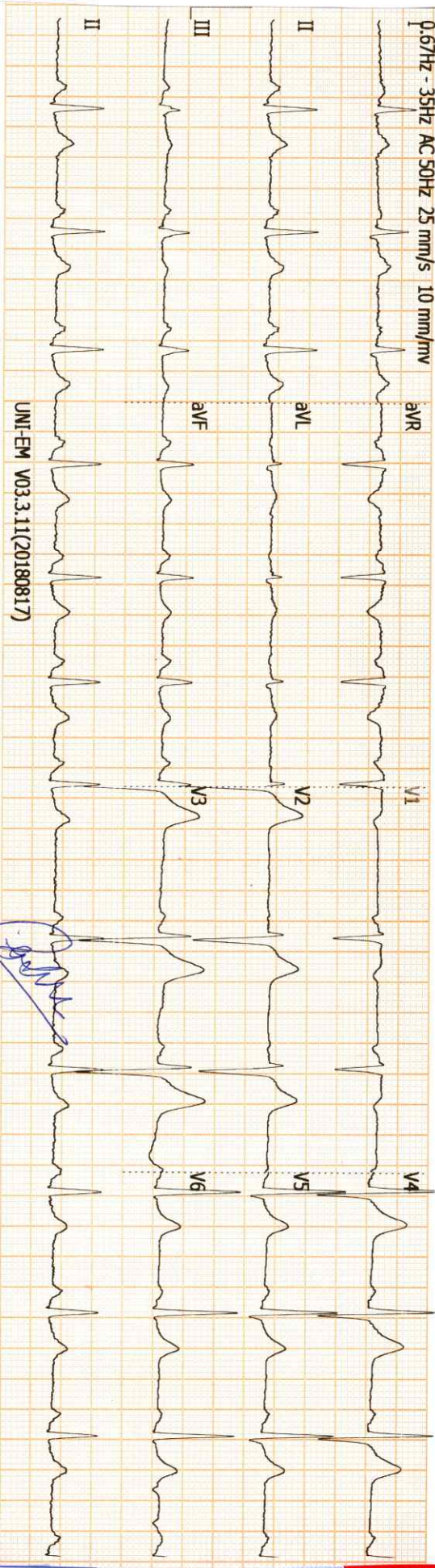
Dr.

*[Signature]*

Dr. NUPUR RAI  
 MBBS, DIPLOMA CARDIOLOGY (PGDCC)  
 Reg. No.: 2018115643

**Healthcare**  
**HEALTHCARE CENTRE & DIAGNOSTICS**  
 Salya Main No. 44/40, Shivajinagar,  
 Khandivadi, Pune - 411007, India. Phone: 91-20-26977000  
 Karimnagar (East), Mumbai - 400101.

0.67Hz - 35Hz AC 50Hz 25 mm/s 10 mm/mv



UNI-EM V03.3.11(20180817)

MP GEHEILD

MP - XI - 20



History : .....

B.P. : .....

Drugs : .....

Standard : .....

Auricular Rate : .....

Ventricular Rate : .....

Rhythm : .....

Mechanism : .....

Voltage : .....

Axis : .....

P Waves : .....

PR Interval : .....

Q. Waves : .....

QRS Interval : .....

ST Segment : .....

T. Waves : .....

QT Interval : .....

Extra Systoles : .....

REMARKS & CONCLUSIONS : .....

Normal