

**LAB REPORT**

Reg. Date	28/10/2023	Patient Id	2310280012	DOB.	
Name	MRS. ANU GUPTA	Gender	F	Perm. ID	
Age	32 Yrs.	Panel	MEDIWHEEL	Reported	29/10/2023 13:26:24
Ref. By	MEDIWHEEL				

Test Name	Result	Units	Ref. Range
MEDIWHEEL COM PLUS VIT (F)			
HB A1C	5.0	%	

Interpretation

Non Diabetic	: 4-6%
Good Diabetic Control	: 6-8%
Fair Control	: 8-10%
Poor Control	: >10%

The Glycosylated haemoglobin assay has been validated as a reliable indicator Of mean blood glucose levels for a period of 8-12 week period. ADA recommended the testing twice a year in patients with stable blood glucose and quarterly. If treatment change, or if blood glucose levels are unstable.

TO BE CORRELATED CLINICALLY.

DR. REEMA DAHIYA

M.B.B.S, MD (Path.)

Checked by: *[Signature]*

M.B.B.S, MD (Path.)

Malik Radix Healthcare Pvt. Ltd.

C-217, C-218, Nirman Vihar,

Delhi-92

DR. MEENU AGGARWAL

M.B.B.S, MD (Path.)

If test results are abnormal or unexpected, patient is advised to contact the laboratory immediately for possible remedial action.

Facilities Available

- Multispeciality Hospital - 24 Hours Emergency - X-Ray/ ECG/ Ultrasound/ CT Scan - Dental - Fully Equipped Operation Theatre
- Fully Functional Lab - Casualty/ ICU-Nursery - Labour Room - All Speciality OPD - Laproscopic Surgery - ECHO - Plastic Surgery

Patient Name : Mrs ANU GUPTA
 DOB/Age/Gender : 32 Y/Female
 Patient ID / UHID : 6011977/OF6011977
 Referred By : Dr.Self
 Sample Type : Serum
 Barcode No : ZA214431

Bill Date : Oct 28, 2023, 04:25 PM
 Sample Collected : Oct 28, 2023, 04:25 PM
 Sample Received : Oct 28, 2023, 06:41 PM
 Report Date : Oct 28, 2023, 07:55 PM
 Report Status : Final Report



Test Description	Value(s)	Unit(s)	Reference Range
------------------	----------	---------	-----------------

BIOCHEMISTRY REPORT

Vitamin B12 / Cyanocobalamin

Vitamin - B12 Method : CMIA	388	pg/mL	187 - 883
--------------------------------	-----	-------	-----------

Interpretation:

Low Values are a sign of a vitamin B12 deficiency. People with this deficiency are likely to have or develop symptoms.

Causes of vitamin B12 deficiency include: Not enough vitamin B12 in diet (rare except with a strict vegetarian diet), Diseases that cause malabsorption (for example, celiac disease and Crohn's disease), Lack of intrinsic factor, Above normal heat production (for example, with hyperthyroidism), Pregnancy. Increased vitamin B12 levels are uncommon. Usually excess vitamin B12 is removed in the urine. Conditions that can increase B12 levels include: Liver disease (such as cirrhosis or hepatitis), Myeloproliferative disorders (for example, polycythemia vera and chronic myelocytic leukemia).

Vitamin B12: Low Levels can cause malabsorption, Lack of intrinsic factor, Above normal heat production (for example, with hyperthyroidism), Pregnancy. High Level Liver disease, Myeloproliferative disorders (for example, polycythemia vera and chronic myelocytic leukemia).

1. Out of 140 healthy indian population, 91% of Vitamin B 12 concentrations was at lower level: 59.00 pg/ml and upper level: 700.00 pg/ml

"Patients on Biotin supplement may have interference in some immunoassays. Ref: Arch Pathol Lab Med—Vol 141, November 2017. With individuals taking high dose Biotin (more than 5 mg per day) supplements, at least 8-hour wait time before blood draw is recommended."

Sohini Sengupta

Dr. Sohini Sengupta
 MD (CI Biochemistry), DNB,
 FNB (Lab Medicine)
 Medical Laboratory Director
 HOD (Biochemistry & Special Assays)

Booking Centre :- Malik Radix Healthcare (Delhi), C-218, Nirman Vihar, Vikas Marg

Processing Lab :- Redcliffe Lifetech Pvt. Ltd., H-55, Sector-63, Noida, Uttar Pradesh - 201301

928-909-0609

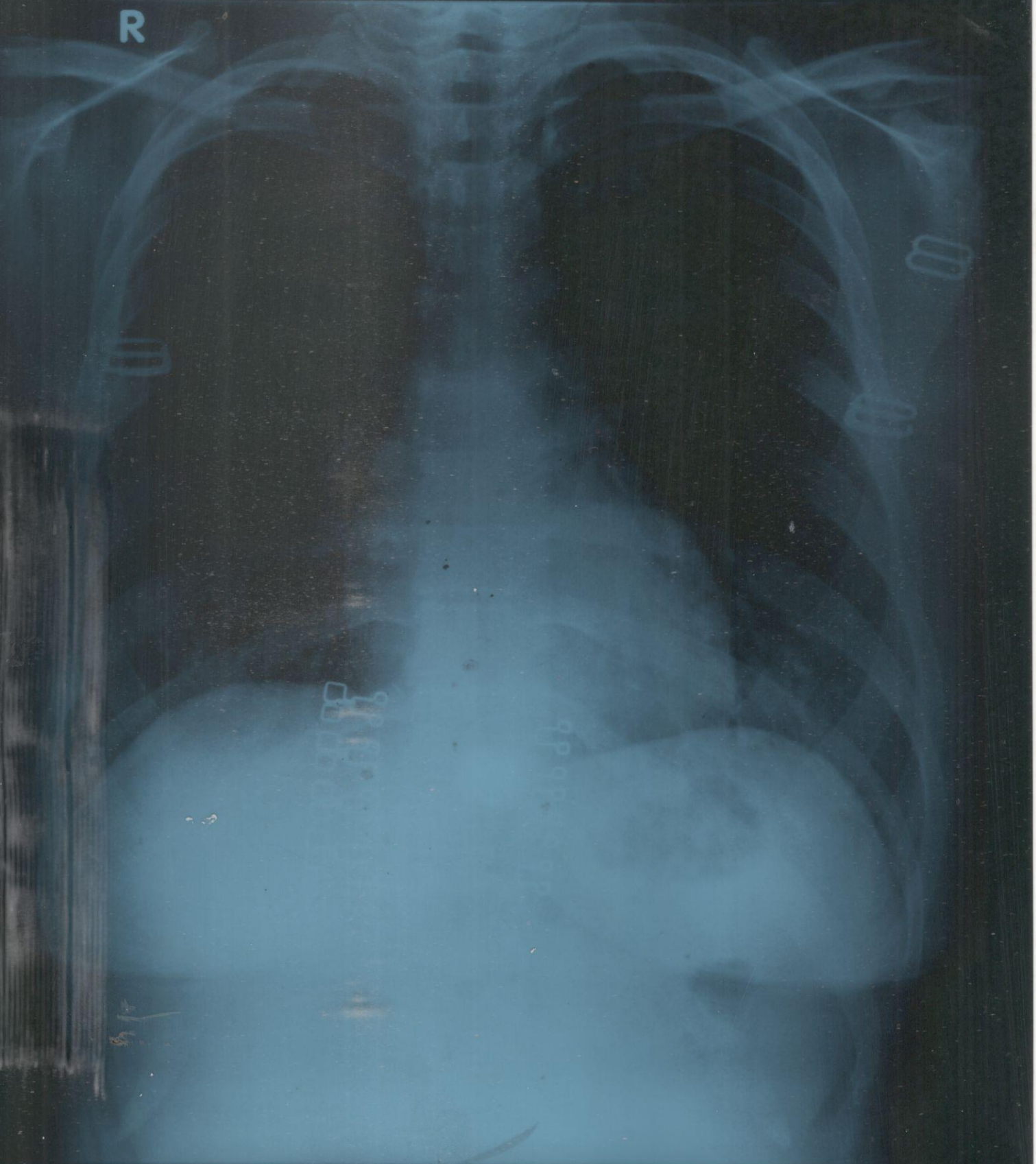
ccsupport@redcliffelabs.com

www.redcliffelabs.com


All Lab results are subject to clinical interpretation by qualified medical professional and this report is not subject to use for any medico-legal purpose.



R



ANU GUPTA 32 YRS F 199774 CHEST PA 28-10-2023 11:49 AM
RADIX HEALTH CARE 218 NIRMAN VIHAR PH-22011198



UHID	PT199774	LAB No.	XRY2306228
Name	Mrs. ANU GUPTA	Regn. No.	GEN2325968
Age / Sex	32 Yrs / F	Receiving Dt/Time	28-Oct-2023 11:49
		Reporting Dt/Time	28-Oct-2023 11:55 AM



XRAY

CHEST (PA)

Both lung fields are normal.

Cp angles are clear.

Hila are normal...

Heart size appears within normal limits.

Soft tissue shadows and bony thorax are normal.

IMP- NORMAL CHEST X-RAY

Advised....please correlate clinically.

***** END OF REPORT *****

DR. K.K. SINHA
M.B.B.S. D.M.R.D.
SENIOR CONSULTANT
Reg. No. 25437 (DMC)

DR. RAJESH MALHOTRA
MBBS, MD (RADIOLOGY)
CONSULTANT RADIOLOGY
Reg.No.DMC9299

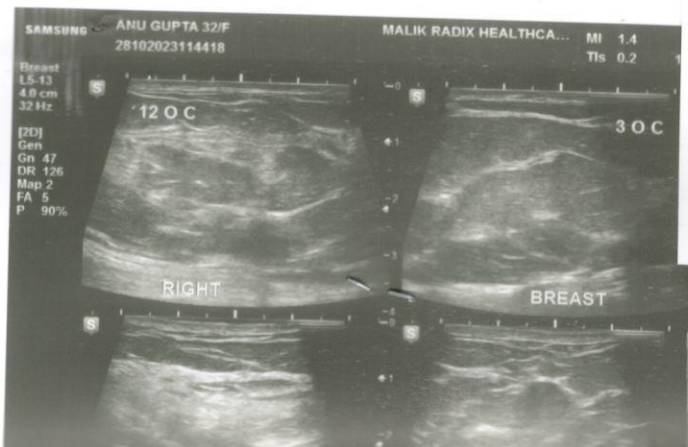
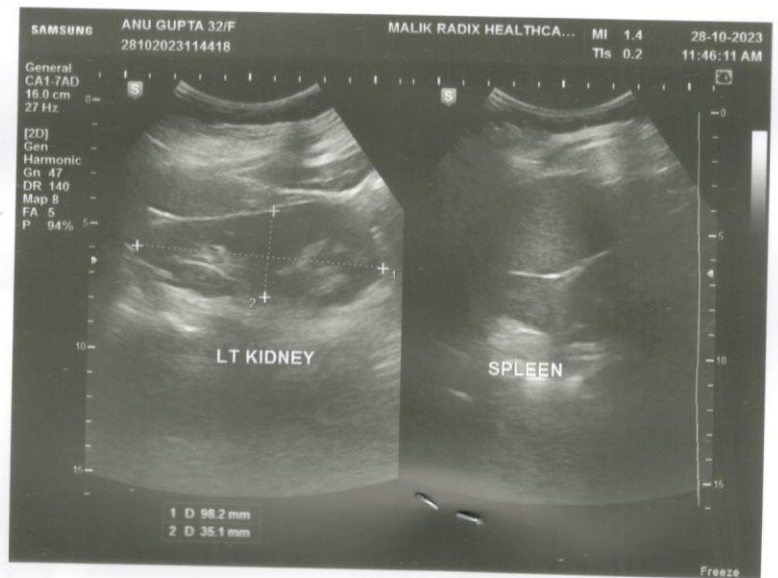
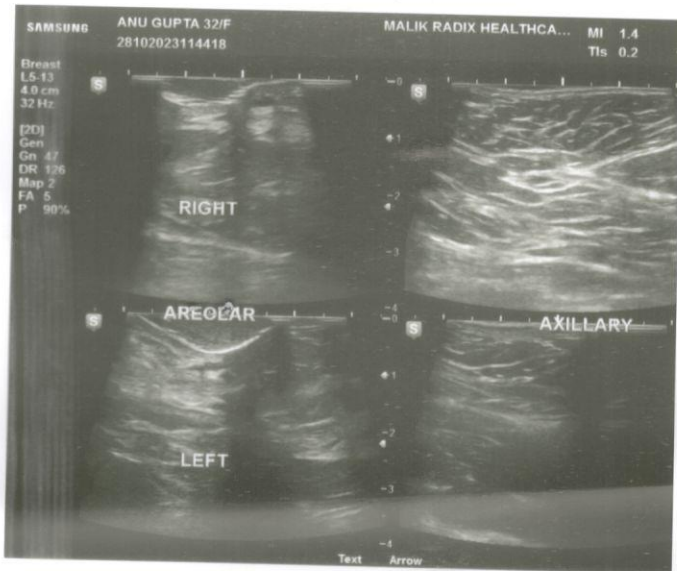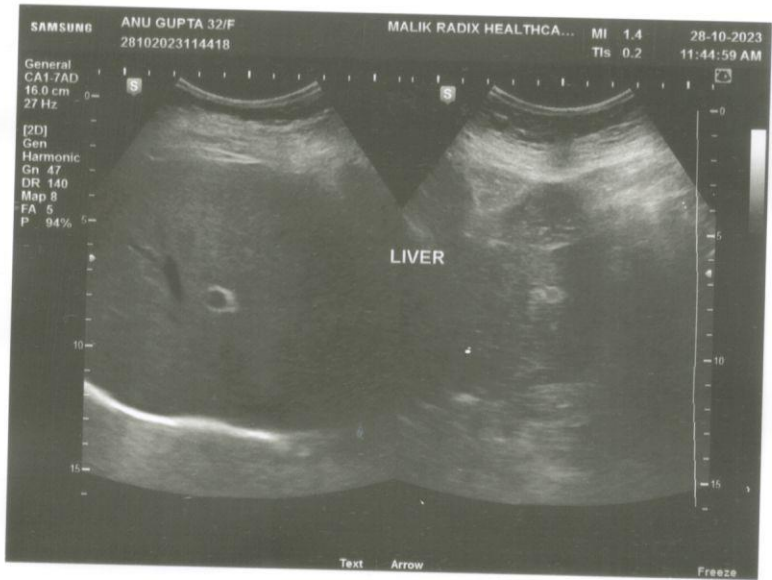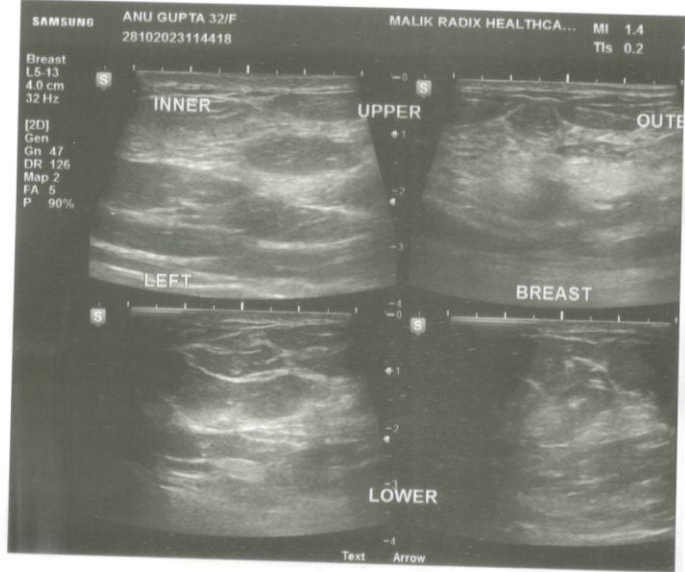
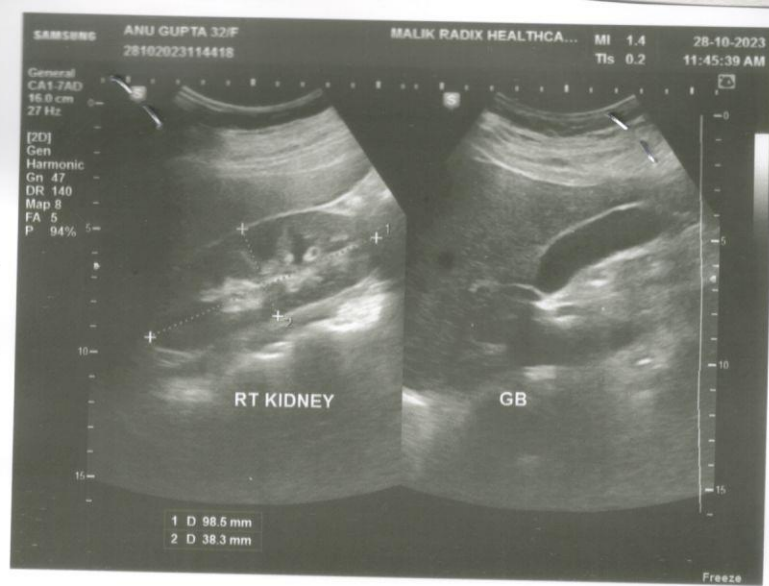
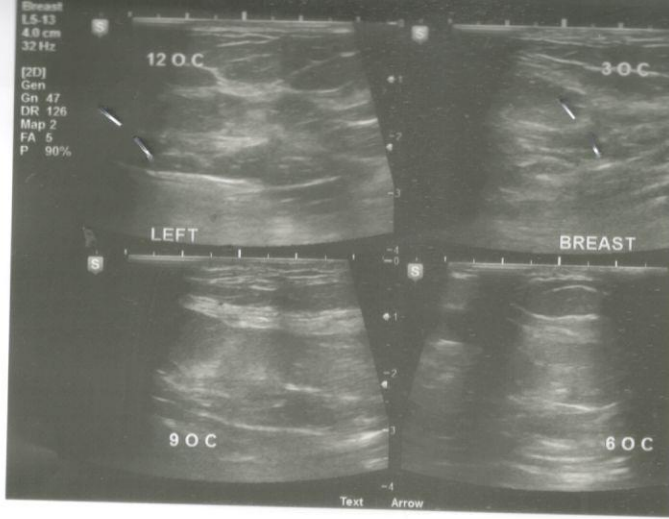
DR. T. K VOHRA
MD (RADIODIAGNOSIS)
SENIOR CONSULTANT
Reg. No. 3272 (DMC)


DR. MUKESH KOSHAL
MBBS, MD (RADIOLOGY)
CONSULTANT RADIOLOGY
Reg.No.DMC10407

DR. SHREYASH TIWARY
MBBS, MD (RADIOLOGY)
CONSULTANT RADIOLOGY
Reg.No.DMC85802

Facilities Available

- Multispeciality Hospital - 24 Hours Emergency - X-Ray/ ECG/ Ultrasound/ CT Scan - Dental - Fully Equipped Operation Theatre
- Fully Functional Lab - 24/7 Casualty/ ICU-Nursery 24/7 Pharmacy - Labour Room - All Speciality OPD - Laproscopic Surgery - ECHO - Plastic Surgery





NAME	MRS ANU GUPTA	AGE	32 Y/F
REFD. BY.	HEALTH CHECK UP	DATE	28.10.23

Ultrasound Examination of Whole Abdomen & Pelvis :

Liver: Liver shows normal parenchymal echotexture. No focal SOL is seen in liver. IHBR & portal radicles are normal.

Gallbladder: Gallbladder shows normal anechoic pattern. No evidence of cholecystitis or cholelithiasis is seen. Common bile duct is normal in course & caliber.

Pancreas: Pancreas shows normal size & echotexture.

Spleen: Spleen shows normal size, outline & echotexture.

Kidneys: Kidneys show normal size, shape, position & echotexture. No calculus, hydronephrosis or SOL is seen in kidneys. Cortico- medullary differentiation and cortical thickness is normal on both sides.

No supra- renal mass seen.

Great abdominal vessels are normal.

Domes of diaphragm are seen to move normally & synchronously in respiration. No supra- or infra diaphragmatic collection is seen.

No ascites or pericardial effusion seen.

No para aortic lymph nodes seen.

Urinary bladder: Urinary bladder shows normal anechoic pattern. No calculus, SOL or diverticulum seen.

Uterus: Uterus is anteverted and normal in size & echotexture. No intrinsic SOL is seen in uterus. Endometrial thickness is 5.6 mm.

Adnexa: Adnexal regions including the ovaries are sonographically normal.

Regards.

Dr Mukesh Koshal MD (Rad- diag)

Regn. No. DMC 10407

RADIOLOGIST :

Facilities Available

- Multispeciality Hospital - 24 Hours Emergency - X-Ray/ ECG/ Ultrasound/ CT Scan - Dental - Fully Equipped Operation Theatre
 - Fully Functional Lab - 24/7 Casualty/ ICU-Nursery 24/7 Pharmacy - Labour Room - All Speciality OPD - Laproscopic Surgery -
 ECHO - Plastic Surgery



NAME	MRS ANU GUPTA	AGE	32 Y/F
REFD. BY.	HEALTH CHECK UP	DATE	28.10.23

Ultrasound Examination of Breasts:

US examination of both breasts was performed using a high frequency probe.

On US both breasts show the normal appearances of adult breasts.
Normal echogenic adipose tissue is seen. The glandular elements are normal.
The fibrous tissue stroma is well defined.
No evidence of any SOL or abnormal calcification seen.
No evidence of any abscess seen.
Areolar and axillary regions are normal.

NORMAL STUDY.



Regards.


Dr Mukesh Koshal MD (Rad- diag)
Regn. No. DMC 10407


RADIOLOGIST :

Facilities Available

- Multispeciality Hospital - 24 Hours Emergency - X-Ray/ ECG/ Ultrasound/ CT Scan - Dental - Fully Equipped Operation Theatre
- Fully Functional Lab - 24/7 Casualty/ ICU-Nursery 24/7 Pharmacy - Labour Room - All Speciality OPD - Laproscopic Surgery -
ECHO - Plastic Surgery


भारत सरकार
Government of India


Issue Date: 01/02/2012



अनु गुप्ता
Anu Gupta
जन्म तिथि/DOB: 21/11/1990
महिला/ FEMALE



3742 4291 5833

VID : 9170 5872 4084 3548

मेरा आधार. मेरी पहचान

Anu


Malik Radix Health Care Pvt. Ltd.
C-217, C-218, Nirman Vihar,
Delhi-110092
Ph.: 011-22011196, 22011192
Regd. No. 607


भारतीय विशिष्ट पहचान प्राधिकरण
Unique Identification Authority of India


Download Date: 27/01/2022




पता:
श्री: कार्तिक रावत, हाउस नं-135, बेरसिया रोड, हिमांशु
शुभ सिटी शारदा नगर, लाम्बा खेड़ा, भोपाल,
मध्य प्रदेश - 462038

Address:
C/O: Kartik Rawat, House No-135, Berasia
Road, Himanshu Shubh City Sharda Nagar,
Lamba Kheda, Bhopal,
Madhya Pradesh - 462038



3742 4291 5833

VID : 9170 5872 4084 3548

 1947 |  help@uidai.gov.in |  www.uidai.gov.in



CONSULTANTS ON PANEL

PAEDIATRICS

Dr Ravi Malik (MBBS, MD)
Dr Pawan Verma (MBBS, MD)

GYNAECOLOGY

Dr Renu Malik (MBBS, MD)
Dr Meena Malhotra (MBBS, MD)
Dr Rajni (MBBS, MD)
Dr Manju Gupta (MBBS, MS)
Dr Vaishali Saini (MBBS, DGO)
Dr Rupam Arora (MBBS, MD)

DENTAL

Dr Shruti Malik (BDS, MDS)
Dr Shilpa Verma
Dr Pooja Makkar
Dr Rupsha Mallick

MEDICINE

Dr A S Talwar (MBBS, MD)
Dr Sunny Uppal (MBBS, MD)
Dr Surendra Rajpal (MBBS, MD)
Dr Amrit Singh Matharu (MBBS, DNB)

RESPIRATORY MEDICINE /PULMONOLOGY

Dr Abhinav Bhanot (MBBS, DNB)

LAPAROSCOPY SURGERY

Dr Ajay Jain (MBBS, MS)
Dr V.K Jain (MBBS, MS)
Dr Deepak Saran (MBBS, MS)
Dr Pradeep Saini (MBBS, MS)
Dr G. S Garg (MBBS, MS)

ORTHOPAEDICS

Dr Vikas Bhardwaj (MBBS, MS ORTHO, DNB)
Dr Prabhat Aggarwal (MBBS, MS ORTHO)
Dr KB Tiwari (MBBS, MS ORTHO)
Dr Deepak Kumar Arora (MBBS, MS ORTHO)

EYE/OPTHALMOLOGY

Dr Nidhi Gupta (MBBS, MS, DNB, PGDM)
Dr Himanshu Singh Pundir (MBBS, MS)

ENT

Dr Sharad Kumar Singhi (MBBS, MS)
Dr Prateek Sharma (MBBS, MS)
Dr Ashok Singh (MBBS, MS)
Dr A K Lahiri (MBBS, MS)

RADIOLOGY(ULTRASOUND)

Dr K K Sinha (MBBS DNRB)
Dr T K Vohra (MBBS, MD)
Dr Rajesh Malhotra (MBBS, MD)
Dr Ashish Tomar (MBBS, MD)

PATHOLOGY

Dr Reema Dahiya (MBBS, MD PATH)
Dr Meenu Aggarwal (MBBS, MD PATH)

ANAESTHESIA

Dr Rajesh Dhall (MBBS, MD)
Dr Rakesh Atrey (MBBS, MD)
Dr R K Arora (MBBS, MD)
Dr Swaraj Garg (MBBS, MD)

DERMATOLOGY

Dr Niharika Jain (MBBS, MD)
Dr Nitish Singhal (MBBS, MD)

PLASTIC & COSMETIC SURGERY

Dr Ayush Jain (MBBS, MS, MCh)

PAEDIATRIC SURGERY

Dr Dharmendra Singh (MBBS, MS, M.Ch)
Dr Satish Aggarwal (MBBS, MS, M.Ch)

PAEDIATRIC NEPHROLOGY

Dr A S Vasudev (MD, Dip.in. Paed.)

NEPHROLOGY

Dr Javed (MBBS, MD, Nephro)

CARDIOLOGY

Dr Nishant Tyagi (MBBS, MD)

NEUROLOGY

Dr Amit Batra (MBBS, MD)

GASTROENTROLOGY

Dr Deepak Lahoti (MBBS, MD)
Dr Naresh Aggarwal (MBBS, MD)

UROLOGY

Dr Nikhil Sharma (MBBS, Mch)

PSYCHIATRY

Dr Mohit Sharma (MBBS, MD)

PHYSIOTHERAPY

Dr Kirti Dwivedi
Dr Ravi Kumar

NUTRITIONIST

Dr Deepika Kohli
Dr Sakshi Rana

CLINICAL PSYCHOLOGIST

Dr. Sarika Singh

Dr. Shruti Malik

BDS, MDS (Endodontics)

(+91-9899561092)

**Timings : 9.00 am. to 1:30 pm.
6:00 pm. to 8:30 pm.**

Name : Anu Gupta
Age/Sex : 32y / F
Date : 28/10/23

**For Appointment
(+91-9999254639)**

CLINICAL EXAMINATION:-

1. TMJ:-

Routine checkup

2. DENTAL STATUS:

o/e M.H. - NOT Relevant

- a. Caries Teeth :
- b. Fracture Teeth :
- c. Root Stumps :
- d. Gingivitis :
- e. Periodontitis :
- f. Impacted Teeth :
- g. Malaligned Teeth :

o/e

Calculus +

Stains +

Caries

8	8
8	8

3. ORAL LESIONS:-

4. DIAGNOSIS:-

Adv - OPG.

5. TREATMENT PLANNING:

- P-kit

6. FOLLOW UP:-

Quality

Referral To Other Consultant: Yes/ No

If Yes, please mention the Name:

Doctor's Signature

Facilities Available :

- ★ MULTI-SPECIALITY HOSPITAL ★ MODULAR FULLY EQUIPPED OT ★ NURSERY ★ LAPROSCOPIC SURGERY
- ★ 24X7 EMERGENCY ★ OPG ★ DENTAL ★ 24X7 DIAGNOSTICS ★ LABOUR ROOM ★ ECHO ★ EEG ★ DIGITAL X-RAY
- ★ ECG ★ ULTRASOUND ★ RICU/ICU ★ ALL SPECIALITY OPD ★ PLASTIC & COSMETIC SURGERY ★ DIALYSIS ★ PHARMACY



PHYSICAL EXAMINATION REPORT

NAME: Mrs. Anu Gupta AGE/GENDER: 32yr/Female DATE 28/10/23

HEIGHT	156cm
WEIGHT	60kg
BMI	24.7
BLOOD PRESSURE	110/70mmHg
OTHER	NAD, She is 'physically Fit & Healthy

Anu Gupta

Dr. SHEIKH WAZIR AHMED
M.D. "Physician"
PGECC
DMC-46499

Malik Radix Health Care Pvt. Ltd.
C-217, C-218, Nirman Vihar,
Delhi-110092
Ph.: 011-22011196, 22011192
Regd. No. 607

Facilities Available

- Multispeciality Hospital - 24 Hours Emergency - X-Ray/ ECG/ Ultrasound/ CT Scan - Dental - Fully Equipped Operation Theatre
- Fully Functional Lab - 24/7 Casualty/ ICU-Nursery 24/7 Pharmacy - Labour Room - All Speciality OPD - Laproscopic Surgery - ECHO - Plastic Surgery

Anu Gupta

ID: 9713384497

32 years Female

Vent. rate 74 bpm
 QRS duration 78 ms
 QT/QTc 402/446 ms
 PR interval 172 ms
 P duration 90 ms
 RR interval 810 ms
 P-R-T axes 33 35 41

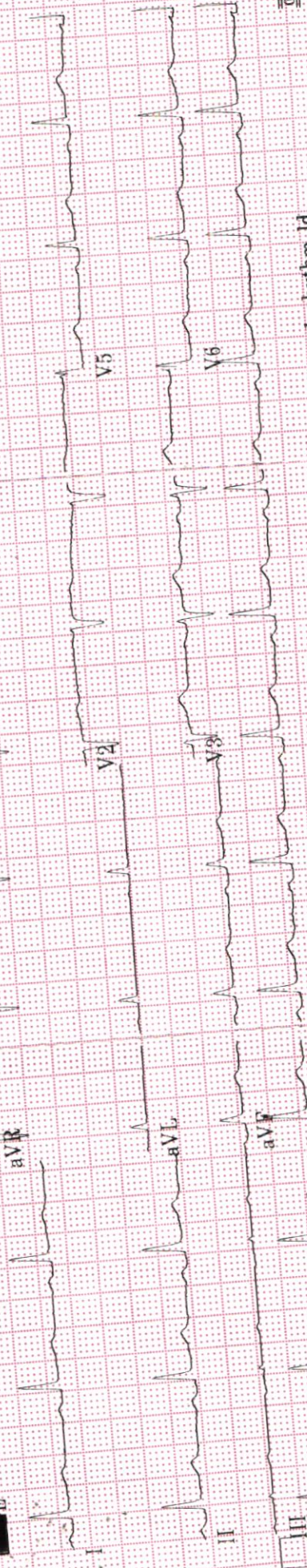Anu

28-Oct-2023 11:39:02

ID: 9713384497

MAC600 1.02

E



4 by 2.5s + 1 rhythm ld

74 bpm

50Hz

10.0 mm/mV

25.0 mm/s

0.16-20Hz

MAC600 1.02

12SL™ v239

Malik Radix HealthCare.

ELECTROCARDIOGRAM

Name: MRS. ANU GUPTA

Age & Sex: 32YR/ FEMALE

Ref By: MEDIWHEEL

Date: 28/10/2023

ECG FINDINGS:

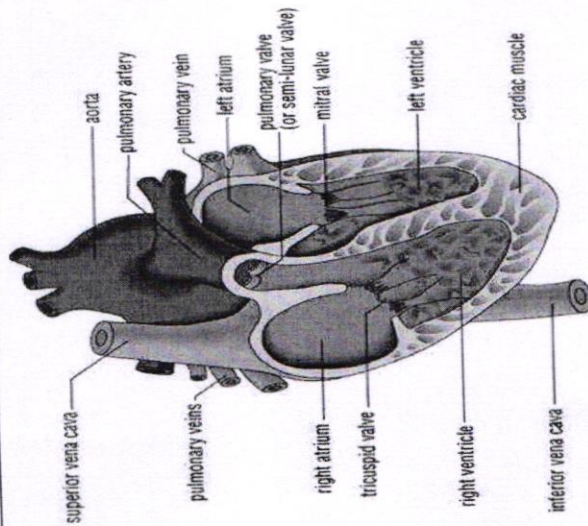
Rate 74 bpm Rhythm Sinus Mechanism Normal


Axis Normal P Wave Normal PR Interval 0.17/Sec

QRS Complex Normal QT Interval Normal Q Wave Normal

ST Segment Normal T Wave Normal

Conclusion Sinus Rhythm, Normal Axis, WNL.



Doctors Signature

 Dr. SHEKHANAZIR AHMED
 M.D. -Physician
 PGDCC
 DMC-46499




Echocardiogram Report

Patient Name	MRS. ANU GUPTA
Date of Test	28/10/2023
Age	32 YRS/ FEMALE
Ref. by	MEDIWHEEL

Dimensions	Result	Normal Range
AO (ed)	2.6 cm	(2.1 -3.7cm)
LA (es)	2.7 cm	(2.1 -3.7cm)
RVID (ed)	2.0 cm	(1.1-3.0cm)
LVID (ed)	3.7 cm	(3.6 – 5.5 cm)
LVID (es)	2.6 cm	(2.3-3.9cm)
IVS (ed)	1.0 cm	(0.6 – 1-2 cm)
LVPW (ed)	1.1 cm	(0.6 – 1-2 cm)
EF	60 %	
FS	30 %	(28 % - 42 %)

Impression:-

1. NO REGIONAL WALL MOTION ABNORMALITY SEEN.
2. LVEF= 60 %
3. NORMAL CHAMBER DIMENSIONS.
4. NORMAL MIP.
5. NORMAL COLOR FLOW.
6. NO INTRA CARDIAC CLOT/MASS/ VEGETATION/PERICARDIAL EFFUSION SEEN.


Dr. Sheikh Nazir Ahmed
M.D. "Physician" PGDCC
(Consultant Non – Invasive Cardiologist)

Facilities Available

- Multispeciality Hospital - 24 Hours Emergency - X-Ray/ ECG/ Ultrasound/ CT Scan - Dental - Fully Equipped Operation Theatre
- Fully Functional Lab - 24/7 Casualty/ ICU-Nursery 24/7 Pharmacy - Labour Room - All Speciality OPD - Laproscopic Surgery -
ECHO - Plastic Surgery



LAB REPORT

Reg. Date	28/10/2023	Patient Id	2310280012	DOB.	
Name	MRS. ANU GUPTA	Gender	F	Perm. ID	
Age	32 Yrs.	Panel	MEDIWHEEL	Reported	28/10/2023 18:22:05
Ref. By	MEDIWHEEL				

Test Name	Result	Units	Ref. Range
-----------	--------	-------	------------

MEDIWHEEL COM PLUS VIT (F)

HAEMATOLOGYCOMPLETE HAEMOGRAM

HAEMOGLOBIN (HB%)	13.1	gm/dl	12 - 15
TOTAL LEUCOCYTE COUNT (TLC)	5,000	/cumm	4000 - 11000
<u>DIFFERENTIAL LEUCOCYTE COUNT (DLC)</u>			
NEUTROPHIL	62	%	40 - 80
LYMPHOCYTE	31	%	28 - 55
MONOCYTE	05	%	02 - 10
EOSINOPHIL	02	%	01 - 06
BASOPHIL	00	%	0 - 0
ESR (WESTGREN'S METHOD)	10	mm/1st hr.	0 - 15
R B C COUNT	4.62	Millions/cmm	4.247 - 5.4
P.C.V / HAEMATOCRIT	40.8	%	35 - 45
M C V	88.3	fl.	80 - 100
M C H	28.4	Picogram	27.0 - 31.0
M C H C	32.1	gm/dl	33 - 37
PLATELET COUNT	2.10	Lakh/cu mm	1.50 - 4.50

Urine Routine Examination

PHYSICAL EXAMINATION

QUANTITY	10	ml.	
COLOUR	Pale Yellow		Pale Yellow
TRANSPARENCY	Clear		
SPECIFIC GRAVITY	1.025		
PH	6.0		

Checked by : _____
Page 1 Contd...2

If test results are alarming or unexpected, patient is advised to contact the laboratory immediately for possible remedial action.

Facilities Available

- Multispeciality Hospital - 24 Hours Emergency - X-Ray/ ECG/ Ultrasound/ CT Scan - Dental - Fully Equiped Operation Theatre
- Fully Functional Lab - Casualty/ ICU-Nursery - Labour Room - All Speciality OPD - Laproscopic Surgery - ECHO - Plastic Surgery



LAB REPORT

Reg. Date	28/10/2023	Patient Id	2310280012	DOB.
Name	MRS. ANU GUPTA	Gender	F	Perm. ID
Age	32 Yrs.	Panel	MEDIWHEEL	Reported
Ref. By	MEDIWHEEL			28/10/2023 18:22:05

Test Name	Result	Units	Ref. Range
CHEMICAL EXAMINATION			
ALBUMIN	Nil		
SUGAR	Nil		
MICROSCOPIC EXAMINATION			
PUS CELLS	2-3	/HPF	
RBC'S	Nil	/HPF	
CASTS	Nil		
CRYSTALS	NIL		
EPITHELIAL CELLS	2-3	/HPF	
BACTERIA	Nil		
OTHERS	Nil		
BLOOD GROUP ABO	" B "		
RH TYPING	Positive		
BLOOD SUGAR FASTING	97.92	mg/dl	70 - 100
BLOOD SUGAR PP	97.05	mg/dl	90 - 140
<u>THYROID PROFILE</u>			
Free T3 ELFA	2.51	ng/ml	02 - 04
Free T4 ELFA	1.45	ug/dl	0.8 - 2.7
TSH Serum/ELFA	3.910	uIU/ml	0.25 - 5.50 uIU/ml

Interpretation**Clinical Use**

- Diagnose Hypothyroidism and Hyperthyroidism

Checked by : -----
Page 2 Contd...3

If test results are alarming or unexpected, patient is advised to contact the laboratory immediately for possible remedial action.

Facilities Available

- Multispeciality Hospital - 24 Hours Emergency - X-Ray/ ECG/ Ultrasound/ CT Scan - Dental - Fully Equiped Operation Theatre
- Fully Functional Lab - Casualty/ ICU-Nursery - Labour Room - All Speciality OPD - Laproscopic Surgery - ECHO - Plastic Surgery



LAB REPORT

Reg. Date	28/10/2023	Patient Id	2310280012	DOB.	
Name	MRS. ANU GUPTA			Perm. ID	
Age	32 Yrs.	Gender	F	Reported	28/10/2023 18:22:05
Ref. By	MEDIWHEEL	Panel	MEDIWHEEL		

Test Name	Result	Units	Ref. Range
-----------	--------	-------	------------

- Monitor T4 replacement or T4 suppressive Therapy
- Quantify TSH levels in the subnormal range

Increased Levels : Primary Hypothyroidism Subclinical Hypothyroidism, TSH dependent, Thyroid Hormone Resistance.

Decreased Levels : Grave's Disease, Autonomous Thyroid Hormone Secretion, TSH Deficiency

LIPID PROFILE

TOTAL CHOLESTEROL	143.70	mg/dL	130.0 - 200.0 (<200)
TRIGLYCERIDES	70.40	mg/dL	80.5 - 150.0 (<150)
H D L CHOLESTEROL DIRECT	46.63	mg/dL	42.0 - 60.0 (<40->59)
V L D L	14.1	mg/dL	4.0 - 30. (23-45)
L D L CHOLESTEROL	83.0	mg/dL	50.0 - 150.0 (50-150)
TOTAL CHOLESTEROL / HDL RATIO	3.1		3.3 - 5.1
LDL / HDL CHOLESTEROL RATIO	1.8		1.5 - 3.5
SERUM URIC ACID	3.72	mg/dl	2.4 - 6.0
BLOOD UREA NITROGEN (BUN)	7.25	mg/dl	6.0 - 21.0
SERUM CREATININE	0.60	mg/dl	0.6 - 1.2
BUN/CREAT RATIO	12.0	mg/dl	

LIVER FUNCTION TEST (LFT)

BILIRUBIN TOTAL	0.90	mg/dl	0.2 - 1.2
CONJUGATED (D. BILIRUBIN)	0.14	mg/dl	0.00 - 0.3
UNCONJUGATED (I.D.BILIRUBIN)	0.76	mg/dl	0.2 - 0.9

Checked by : _____
Page 3 Contd...4

10 - 20

If test results are alarming or unexpected, patient is advised to contact the laboratory immediately for possible remedial action.

Facilities Available

- Multispeciality Hospital - 24 Hours Emergency - X-Ray/ ECG/ Ultrasound/ CT Scan - Dental - Fully Equiped Operation Theatre - Fully Functional Lab - Casualty/ ICU-Nursery - Labour Room - All Speciality OPD - Laproscopic Surgery - ECHO - Plastic Surgery

**LAB REPORT**

Reg. Date	28/10/2023	Patient Id	2310280012	DOB.	
Name	MRS. ANU GUPTA	Gender	F	Perm. ID	
Age	32 Yrs.	Panel	MEDIWHEEL	Reported	28/10/2023 18:22:05
Ref. By	MEDIWHEEL				

Test Name	Result	Units	Ref. Range
SGOT / AST	18.20	IU/L	0 - 35
SGPT / ALT	17.9	IU/L	0 - 35
ALKALINE PHOSPHATASE	67.70	U/L	64 - 306
TOTAL PROTEIN	7.02	gm/dl	6.0 - 8.3
ALBUMIN	4.01	gm/dl	3.2 - 5.0
GLOBULIN	3.01	gm/dl	2.5 - 5.6
A/G RATIO	1.33		0.9 - 2.0
GAMMA GT	20.31	IU/L	0.0 - 35.0
DR. NIDHI GUPTA (Eye Examination)			
VITAMIN D 25 HYDROXY CLIA	89.0	ng/ml	

DR. REEMA DAHIYA

M.B.B.S, MD (Path)

Checked by MD (Path)

Page 4 of 4

Malik Radix Healthcare Pvt. Ltd.

C-217, C-218, Nirman Vihar,

Delhi-92

DR. MEENU AGGARWAL

M.B.B.S, MD (Path.)

If test results are alarming or unexpected, patient is advised to contact the laboratory immediately for possible remedial action.

Facilities Available

- Multispeciality Hospital - 24 Hours Emergency - X-Ray/ ECG/ Ultrasound/ CT Scan - Dental - Fully Equipped Operation Theatre
- Fully Functional Lab - Casualty/ ICU-Nursery - Labour Room - All Speciality OPD - Laproscopic Surgery - ECHO - Plastic Surgery