

حکومت ہند  
Government of India  
بانک سبکو  
Name: Sogit  
تاریخ پیدائش - DOB: 12/02/1987  
رقم شناختی



6063 8354 3609

عام آدمی کا ادھیکار - ادھار

Handwritten signature and number: 90387

ادھار  
Address: S/O: Jagat Singh, Peth Gam, Gadoora, Pulwama, Tral, Jammu And Kashmir, 192123

ولد: حکمت سبکو، بیٹو گام، بلوگرام، ترال، جموں اے کشمیر، 192123

6063 8354 3609

1947 1800 300 1947 help@vaid.gov.in www.vaid.gov.in

Dr. M. M. Kamran  
MBBS, MD  
Fry Family Solutions

GILLY'S DIAGNOSTIC CENTER  
Police  
Karnal Nagar



# GILLANI'S DIAGNOSTIC CENTRE



MUNICIPALITY ROAD, OPP. POLICE HEADQUARTERS, KARAN NAGAR, SRINAGAR-190010, KMR.

B/O.: PEERWARI COMPLEX, OPP. SHIRAZ CINEMA, KHANYAR, SRINAGAR CELL: 9906476734

ID :- AHCN-32730112301001

Gender :- Male

Client Name:- Nanak Singh Bali.

Cell :- 7006590387

Provider :- Apollo

Dated: 09/Dec/2023

## URINE COTININE

ANALYTE

RESULT

\* Urine cotinine "Negative"/below 200ml

## URINE ANALYSIS

### Physical Examination

Colour :- Yellowish.  
 PH/Reaction :- Acidic.  
 Transparency :- Clear.  
 Sp. Gravity :- QNS.

### Chemical Examination

Sugar :- NIL  
 Albumin :- NIL

### MICROSCOPY :-

Pus Cells. (Nil)  
 RBC Cells. (1-2)  
 Sq. Epithelial. (Nil)  
 Calcium Oxalates. (1+)  
 Amorphous Phosphates. (Nil)  
 Mucus. (1+)  
 Others. (Nil)



### IMPORTANT

- \* AS PER UNIVERSAL ACCEPTANCE, ALL ANOMALIES MAY NOT BE APPARENT DURING SCANNING.
- \* NOT FOR PRENATAL SEX DETERMINATION OF FOETUS UNDER PNPT AT/MEDIAL LEGAL PURPOSE.
- \* THE INVESTIGATION FINDING SHOULD ALWAYS BE CONSIDERED IN CORRELATION WITH THE CLINICAL AND OTHER INVESTIGATION FINDING WHERE APPLICABLE.



# GILLANI'S DIAGNOSTIC CENTRE



MUNICIPALITY ROAD, OPP. POLICE HEADQUARTERS, KARAN NAGAR, SRINAGAR-190010, KMR.

B/O.: PEERWARI COMPLEX, OPP. SHIRAZ CINEMA, KHANYAR, SRINAGAR CELL: 9906476734

ID :- AHCN-32730112301001

Gender :- Male

Client Name:- Nanak Singh Bali.

Cell :- 7006590387

Provider :- Apollo

Dated: 09/Dec/2023

## TO WHOME IT MAY CONCERN

This is to certify that Nanak Singh Bali is physically/Mentally fit to join the Organization.

His: Vision/colour is good.

His: Dental Shape & Condition is good.

His: BMI=32, BP recumbent=130/90mm/Hg.

His: D.O.B is 12/02/1967.

His: Height is 154cms & weight is 95kgs

His: Chest expiration is 99cms & chest inspiration is 103cms

His: Abdomen is 101cms.

*Dr. M. Kamran Akh*  
MBBS, MD (Gen. Medicine)  
Physician/Specialist



Physical/ Medical Examiner

### IMPORTANT

- ★ AS PER UNIVERSAL ACCEPTANCE, ALL ANOMALIES MAY NOT BE APPRENT DURING SCANNING.
- ★ NOT FOR PRENATAL SEX DETERMINATION OF FOETUS UNDER PNOD AT/MEDIAL LEGAL PURPOSE.
- ★ THE INVESTIGATION FINDING SHOULD ALWAYS BE CONSIDERED IN CORRELATION WITH THE CLINICAL AND OTHER INVESTIGATION FINDING WHERE APPLICABLE.



# GILLANI'S DIAGNOSTIC CENTRE



MUNICIPALITY ROAD, OPP. POLICE HEADQUARTERS, KARAN NAGAR, SRINAGAR-190010, KMR.

B/O.: PEERWARI COMPLEX, OPP. SHIRAZ CINEMA, KHANYAR, SRINAGAR CELL: 9906476734

ID :- AHCN-32730112301001

Gender :- Male

Client Name:- Nanak Singh Bali.

Cell :- 7006590387

Provider :- Apollo

Dated: 09/Dec/2023

## BIO-CHEMISTRY/IMMUNO-REPORT

Test Required	Result	Units	Normal Value
Blood Sugar (Fasting)	(92)	mg/dl	(70-110)
Blood Sugar (p.p)	(125)	mg/dl	(80-140)
<b>K. F. T.</b>			
Blood Urea	(41)	mg/dl	(10-46)
BUN	(18)	mg/dl	(06-20)
Serum Creatinine	(1.01)	mg/dl	(0.6-1.2)
Serum Uric Acid	(6.7)	mg/dl	(3.0-7.0)
Serum Calcium.	(9.5)	mg/dl	(8.4-10.5)
Serum Phosphorus.	(4.1)	mg/dl	(2.5-4.8)
Serum Sodium.	(151)	mmol/L	(135-155)
Serum Potasium.	(4.9)	mmol/L	(3.5-5.5)
Serum Chloride.	(100.2)	mmol/L	(98.0-107.0)
<b>L. F. T.</b>			
Serum Bilirubin	(0.9)	mg/dl	(UP TO 1.2)
Direct Bilirubin	(0.4)	mg/dl	(0-5)
Indirect Bilirubin	(0.5)	mg/dl	(0-7)
Serum Total Protein	(7.4)	G/dl	(6.0-8.0)
Serum Albumin	(4.8)	G/dl	(3.7-5.3)
Serum Globulin	(3.1)	G/dl	(2.3-3.6)
Serum Alk. Phosphate	(118)	U/l	(56-130)
A/G RATIO	(1.41)	***	(1.0-2.0)
SG (OT)	(31)	Units/L	(5-40)
SG (PT)	(29)	Units/L	(5-35)
Gamma GTT	(33)	Units/L	(> 40)
<b>Lipid Profile:-</b>			
TRIGLYCERIDES	(161)	mg/dl	(40-165)
CHOLESTEROL	(198)	mg/dl	(50-200)
H.D.L - CHOLESTEROL	(55)	mg/dl	(40-60)
L.D.L - CHOLESTEROL	(177)	mg/dl	(50-190)
V.L.D.L - CHOLESTEROL	(34)	mg/dl	(10-40)
Ratio	(1.71)	mg/dl	

\*\*\*End of Report\*\*\*

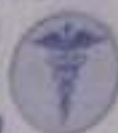### IMPORTANT

- AS PER UNIVERSAL ACCEPTANCE, ALL ANOMALIES MAY NOT BE APPRENT DURING SCANNING.
- NOT FOR PRENATAL SEX DETERMINATION OF FOETUS UNDER PNDT AT MEDICAL LEGAL PURPOSE.
- THE INVESTIGATION FINDING SHOULD ALWAYS BE CONSIDERED IN CORRELATION WITH THE CLINICAL AND OTHER INVESTIGATION FINDING WHERE APPLICABLE.





# GILLANI'S DIAGNOSTIC CENTRE



MUNICIPALITY ROAD, OPP. POLICE HEADQUARTERS, KARAN NAGAR, SRINAGAR-190010, KMR.

B/O.: PEERWARI COMPLEX, OPP. SHIRAZ CINEMA, KHANYAR, SRINAGAR CELL: 9906476734

ID :- AHCN-32730112301001

Gender :- Male

Client Name:- Nanak Singh Bali.

Cell :- 7006590387

Provider :-

Dated: 09/Dec/2023

## Haemotology Report

Test Required	Results	Units	Ref. Range
Haemoglobin Value (HB)	16.5	gm/dl	13.00-17.00
PCV/Haematocrit	46	%	40-50
M C V	96.4	fL	80-100
M C H	30.1	pg	27-32
M C H C	33.5	%	32-36
R D W - C V	12.4	%	11.5-14.5
Platelet Count	294	thousand	150-450
RBC Count	4.97	million/Cmm	4.50-5.50
Total Leucocyte Count	09.44	*10 <sup>3</sup> Cell/ul	4.0-11.0
<u>D L C (by Flow cytometry / Microscopy)</u>			
Neutrophil	70.1	%	40-75
Lymphocyte	29.9	%	20-40
Eosinophil	0.0	%	1- 5
Monocyte	0.0	%	2-10
Basophil	0.0	%	0- 2
RDW - SD	42.3	fL	35-46
PDW	20.4	fL	8.30-25.0
MPV	13.3	fL	8.60-15.5
PCT	0.55	%	0.15-0.62
Absolute Neutrophil Count	5.1	*10 <sup>3</sup> /UL	2-7
Absolute Lymphocyte Count	2.2	*10 <sup>3</sup> /UL	1-3
Absolute Monocyte Count	0.8	*10 <sup>3</sup> /UL	0.2-1.0
Absolute Basophil Count	0.06	*10 <sup>3</sup> /UL	0.02-0.1
Absolute Eosinophil Count	0.3	*10 <sup>3</sup> /UL	0.2-0.5
E.S.R.	08	mm	(M 0-9)
(Wintrob Method)			(F 0-20)
Blood Group	"B"		
Rh. Typing	(Positive)		

\*\*\*End Of Report\*\*\*

### IMPORTANT

- \* AS PER UNIVERSAL ACCEPTANCE, ALL ANOMALIES MAY NOT BE APPRENT DURING SCANNING.
- \* NOT FOR PRENATAL SEX DETERMINATION OF FOETUS UNDER PNDT AT MEDIAL LEGAL PURPOSE.
- \* THE INVESTIGATION FINDING SHOULD ALWAYS BE CONSIDERED IN CORRELATION WITH THE CLINICAL AND OTHER INVESTIGATION FINDING WHERE APPLICABLE.





# GILLANI'S DIAGNOSTIC CENTRE



MUNICIPALITY ROAD, OPP. POLICE HEADQUARTERS, KARAN NAGAR, SRINAGAR-190010, KMR.

B/O.: PEERWARI COMPLEX, OPP. SHIRAZ CINEMA, KHANYAR, SRINAGAR CELL: 9906476734

ID :- AHCN-32730112301001

Gender :- Male

Client Name:- Nanak Singh Bali.

Cell :- 7006590387

Provider :- Apollo

Dated: 09/Dec/2023

## IMMUNO-REPORT

Test Required	Result	Units	Normal Value
TOTAL TRIIODOTHYRONINE (T3)	(1.02)	ng/dl.	0.87 - 1.78
TOTAL THYROXINE (T4)	(10.21)	ng/dl.	3.06 - 12.54
THYROID STIMULATING HORMONE (TSH)	(4.91)	uIU/ml	0.34 - 5.60
Prostate Specific Antigen. (PSA)	(2.9)	ng/ml	< 4.0 ng/ml
Glycosylated Hemoglobin (Ghb/HbA1c)	(5.1)	%	<6:Non Diabetic

\*\*\*End of Report\*\*\*



### IMPORTANT

- AS PER UNIVERSAL ACCEPTANCE, ALL ANOMALIES MAY NOT BE APPARENT DURING SCANNING.
- NOT FOR PRENATAL SEX DETERMINATION OF FOETUS UNDER PNDT AT MEDICAL LEGAL PURPOSE.
- THE INVESTIGATION FINDING SHOULD ALWAYS BE CONSIDERED IN CORRELATION WITH THE CLINICAL AND OTHER INVESTIGATION FINDING WHERE APPLICABLE.



# GILLANI'S DIAGNOSTIC CENTRE



MUNICIPALITY ROAD, OPP. POLICE HEADQUARTERS, KARAN NAGAR, SRINAGAR-190010, KMR.

B/O.: PEERWARI COMPLEX, OPP. SHIRAZ CINEMA, KHANYAR, SRINAGAR CELL: 9906476734

ID :- AHCN-32730112301001  
Client Name:- Nanak Singh Bali.  
Provider :- Apollo

Gender :- Male  
Cell :- 7006590387  
Dated: 09/Dec/2023

## Ophthalmology Report

Eye (ophthalmology) examined on	normal	abnormal				
Lids, lachrymal apparatus, conjunctiva, cornea, pupil, lens, media, fund, tension	✓					
Visual fields (by confrontation method/test)	✓					
Ocular motility (associated palatal movement, nystagmus)	✓					
Cover test, if applicable/necessary	✓					
<b>Visual acuity tests</b>						
Does the candidate possess glasses	Yes / No, if 'YES' then - wears glasses (spectacles) / contact lenses - both					
Distance vision at 6 metres	Right Eye	Left Eye				
Without glasses/contact lenses	6/6	6/6				
With glasses (spectacles)	6/6	6/6				
With contact lenses	6/6	6/6				
Near vision - 'N' type at 30-50 cm	Right Eye	Left Eye				
Without glasses/contact lenses	N 6/6	N 6/6				
With glasses (spectacles)	N	N				
With contact lenses	N	N				
Prescription of corrective glasses and/or contact lenses, if applicable (as prescribed by ophthalmologist)						
Vision	Right Eye		Left Eye		Vision corrected to (visual acuity)	
	S	C	A	S	C	
Distance						6/6
Near						6/6
Colour vision / perception - use Ishihara plates only, held at 75 cm distance for reading/seeing (preferably use 38 plate edition)						
No. of plates used	Ishihara's - 24 plates / 36 plates					
Result	Normal / Abnormal (defective)					
	No. of errors =					
	Unread plate no's =					
	Misread plate no's =					
If Abnormal Colour Vision						
(mention those plates misread and number of errors, e.g. misread plate no. 2 and read as 3 but correct as 4, 5, 6, 7, 8, 9)						

**IMPORTANT**

- AS PER UNIVERSAL ACCEPTANCE, ALL ANOMALIES MAY NOT BE APPARENT DURING SCANNING
- NOT FOR PRENATAL SEX DETERMINATION OF FOETUS UNDER PNDT AT MEDICAL LEGAL PURPOSE
- THE INVESTIGATION FINDING SHOULD ALWAYS BE CONSIDERED IN CORRELATION WITH THE CLINICAL AND OTHER INVESTIGATION FINDING WHERE APPLICABLE



Signed: *[Signature]*



# GILLANI'S DIAGNOSTIC CENTRE



MUNICIPALITY ROAD, OPP. POLICE HEADQUARTERS, KARAN NAGAR, SRINAGAR-190010, KMR.

B/O.: PEERWARI COMPLEX, OPP. SHIRAZ CINEMA, KHANYAR, SRINAGAR CELL: 9906476734

ID :- AHCN-32730112301001  
Client Name:- Nanak Singh Bali.  
Provider :- Apollo

Gender :- Male  
Cell :- 7006590387  
Dated: 09/Dec/2023

## X-RAY CHEST P.A VIEW

No evidence of any active lung Parenchymal lesion detected.

Apices and C.P. Angles are clear.

Cardiac size is within normal range.



*[Signature]*  
Radiologist

### IMPORTANT

- \* AS PER UNIVERSAL ACCEPTANCE, ALL ANOMALIES MAY NOT BE APPARENT DURING SCANNING.
- \* NOT FOR PRENATAL SEX DETERMINATION OF FOETUS UNDER PNOD AT/MEDIAL LEGAL PURPOSE.
- \* THE INVESTIGATION FINDING SHOULD ALWAYS BE CONSIDERED IN CORRELATION WITH THE CLINICAL AND OTHER INVESTIGATION FINDING WHERE APPLICABLE.



10mm/mV 0.5-45Hz AC50

NANAK SINGH BALE

08-12-2023 12:41:18

aVR

V1

V4

II

aVL

V2

V5

III

aVF

V3

V6

25mm/s

V2.47

*Handwritten signature*

Average Template:

08-12-2023 12:41:18

ID : 231208-1241

Name : NANAK SINGH BALE

Age : ~~25~~ yr

Sex : Male

BP : mmHg

Height : cm

Weight : kg

HR : 73 bpm

P Dur : 115 ms

PR int : 194 ms

QRS Dur : 82 ms

QT/QTc int : 341/376 ms

P/QRST axis : 36/-8/25 °

RV5/SV1 amp : 1.277/0.778 mV

RV5+SV1 amp : 2.055 mV

RV6/SV2 amp : 1.778/0.991 mV



Diagnosis Information:

800: Sinus Rhythm

\*\*\*Normal ECG\*\*\*

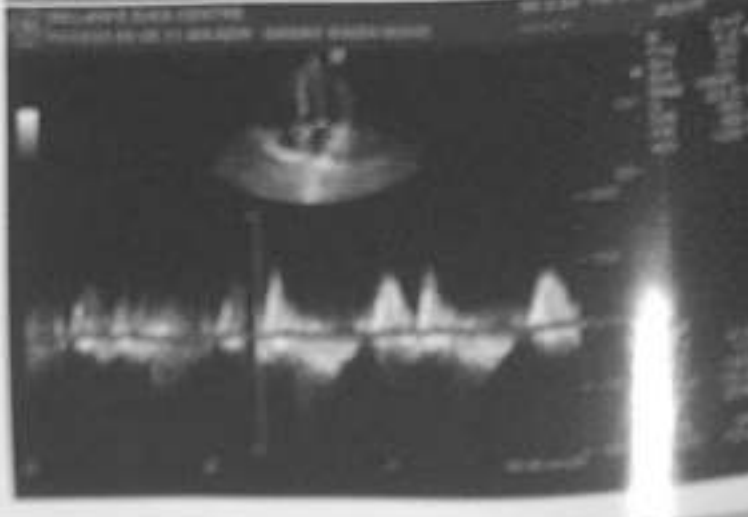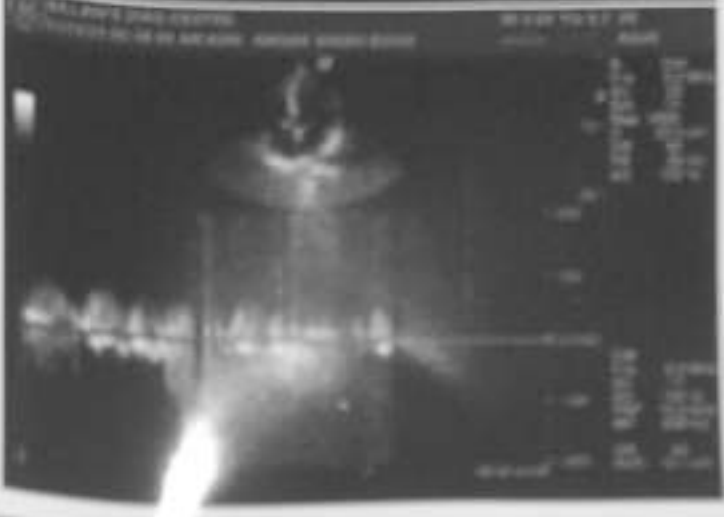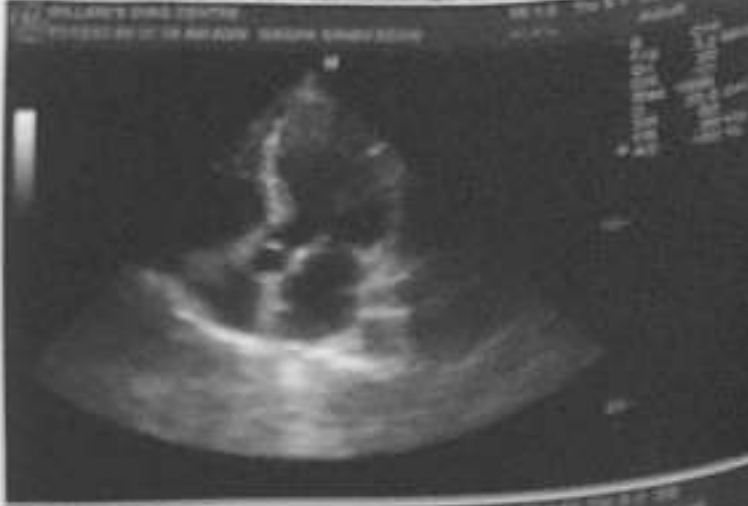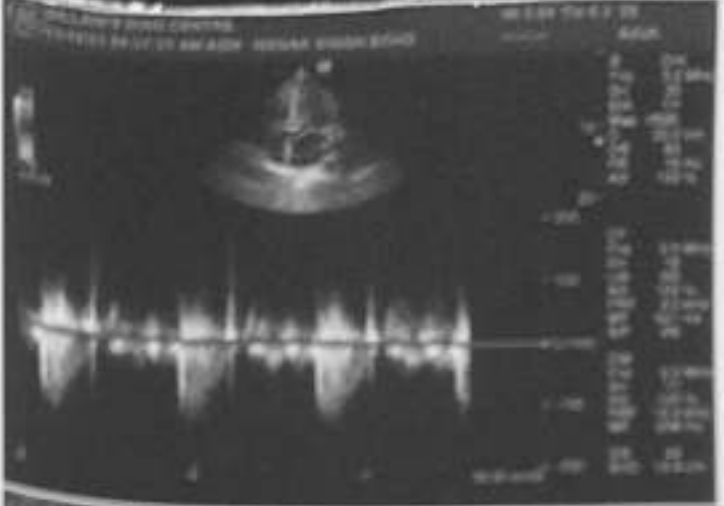
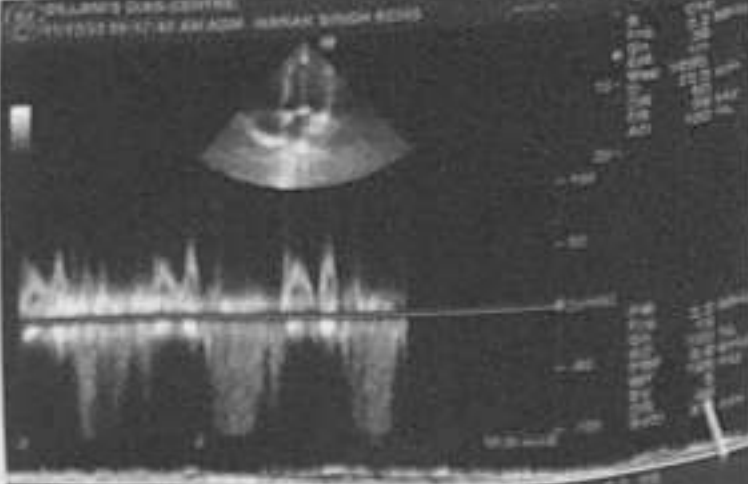
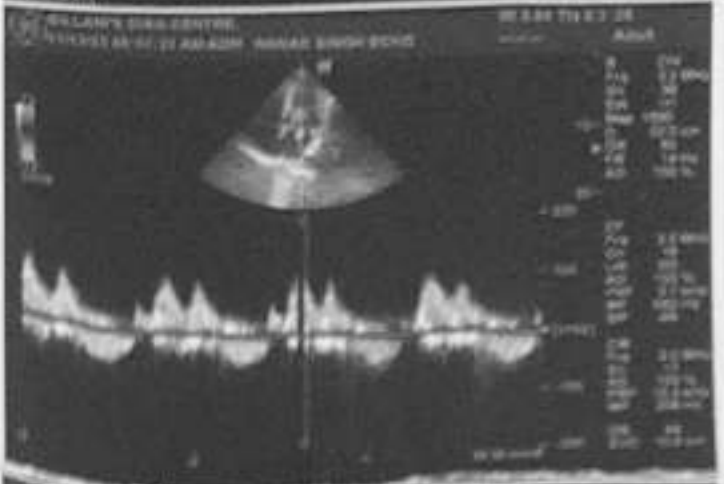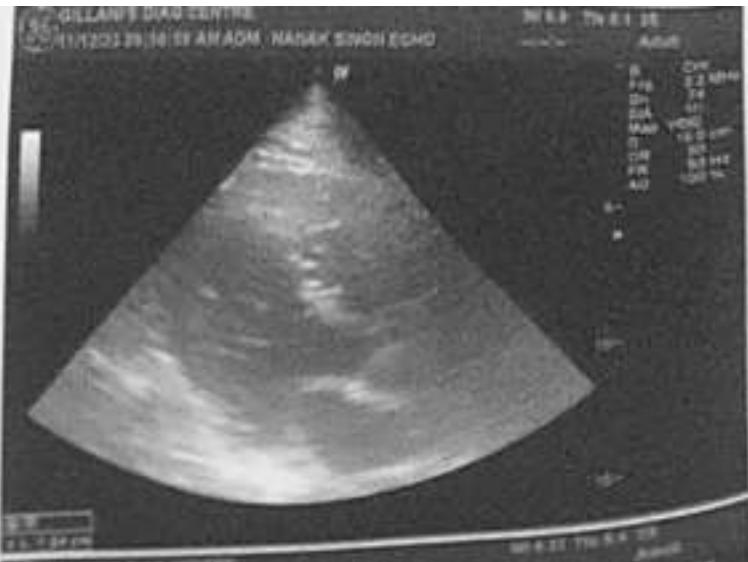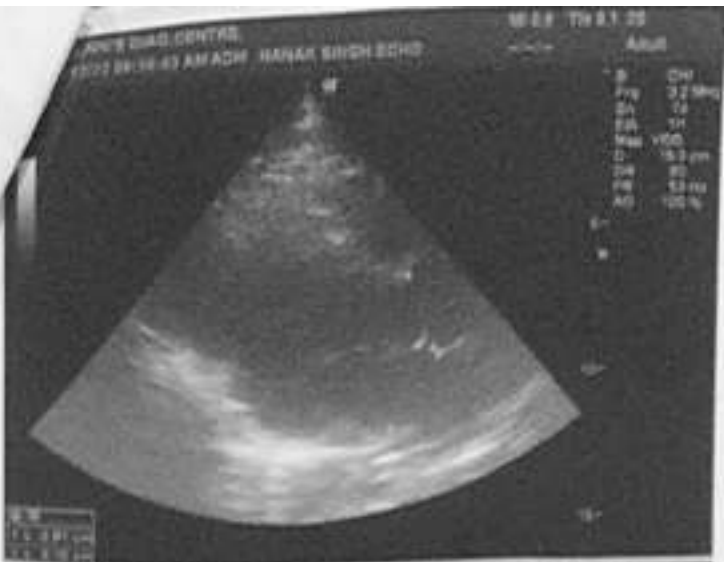Dr. Mahesh Kumar Singh  
MBBS, MD Gen. Medicine  
Physician/Scholarist

Report Confirmed by

10mm/mV 25mm/s

V2.47

*Handwritten signature*



# GILLANI'S DIAGNOSTIC CENTRE



MUNICIPALITY ROAD, OPP. POLICE HEADQUARTERS, KARAN NAGAR, SRINAGAR-190010, KMR.

B/O.: PEERWARI COMPLEX, OPP. SHIRAZ CINEMA, KHANYAR, SRINAGAR CELL: 9906476734

ID :- AHCN-32730112301001

Gender :- Male

Client Name:- Nanak Singh Bali.

Cell :- 7006590387

Provider :- Apollo

Dated: 11/Dec/2023

Clinical INFORMATION:-

MEASUREMENTS:-

AO Root:- 26 mm  
LA :- 26 mm

AORTIC VALVE:- NORMAL  
AR Grade :- \_\_\_\_\_  
AV gradient:- \_\_\_\_\_ mmHg  
Av Area :- \_\_\_\_\_ Cm2  
LVOT Diam :- \_\_\_\_\_ Cm2 VTI:- \_\_\_\_\_ cm/sec  
SV :- \_\_\_\_\_ ml CO:- \_\_\_\_\_ L/min

LVEDD:- 44 mm IVSd:- 13mm  
LVESD:- 27 mm PW:- 13mm

MITRAL VALVE:-  
2D-Evaluation:- A > E  
MR grade:- MILD  
Gradient:- \_\_\_\_\_ mmHg  
PHT:- \_\_\_\_\_ Cm2 VTI:- \_\_\_\_\_ CM2 HR  
2D \_\_\_\_\_ Cm2 CE:- \_\_\_\_\_ Cm2 PHT:- \_\_\_\_\_ Cm2  
E.....cm/s .....A.....cm/s  
DT.....ms.....IVRT.....ms

EF :- 65 %

TRICUPID VALVE:-

2D Evaluaton :- NORMAL  
TR grade:- \_\_\_\_\_  
Gradient:- 08 mmHg  
PHT:- \_\_\_\_\_ VTI

PULMONARY VALVE:-  
2D Evaluaton :- NORMAL  
PR grade:- \_\_\_\_\_ pr ed Vel. -MS  
Max. syst. Vel. :- MS



**IMPORTANT**

- AS PER UNIVERSAL ACCEPTANCE, ALL ANOMALIES MAY NOT BE APPARENT DURING SCANNING.
- NOT FOR PRENATAL SEX DETERMINATION OF FOETUS UNDER PNPT AT MEDICAL LEGAL PURPOSE.
- THE INVESTIGATION FINDING SHOULD ALWAYS BE CONSIDERED IN CORRELATION WITH THE CLINICAL AND OTHER INVESTIGATION FINDING WHERE APPLICABLE.

# GILLANI'S DIAGNOSTIC CENTRE



MUNICIPALITY ROAD, OPP. POLICE HEADQUARTERS, KARAN NAGAR, SRINAGAR-190010, KMR.

B/O.: PEERWARI COMPLEX, OPP. SHIRAZ CINEMA, KHANYAR, SRINAGAR CELL: 9906476734

Client Name:- Nanak Singh Bali.

Cell :- 7006590387

Dated: 11/Dec/2023

Provider :- Apollo

### Impression

LV :- No RWMA, Mild Concentric LVH .

MV :- Mild MR

AV :- Normal

PV :- Normal

TV :- Normal.

RA,RV :- Normal

### CONCLUSION :-

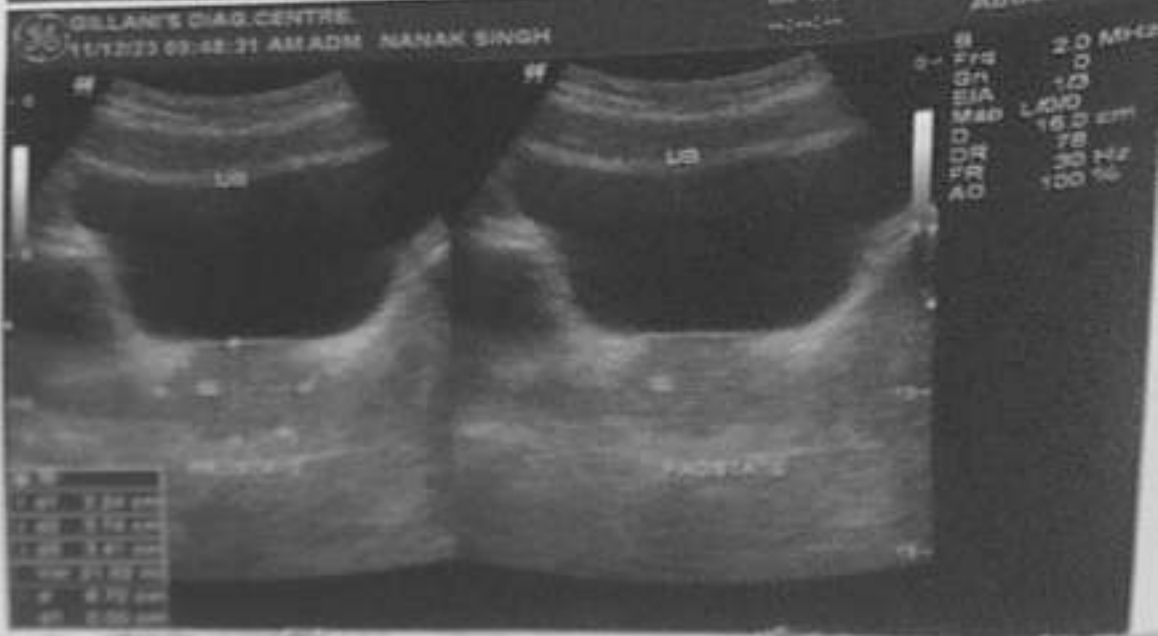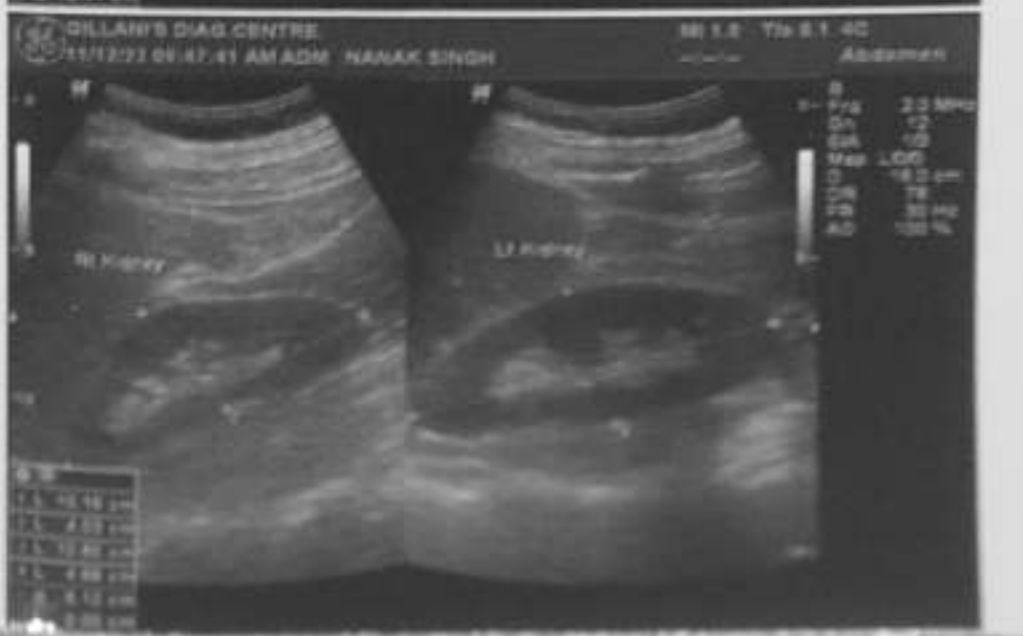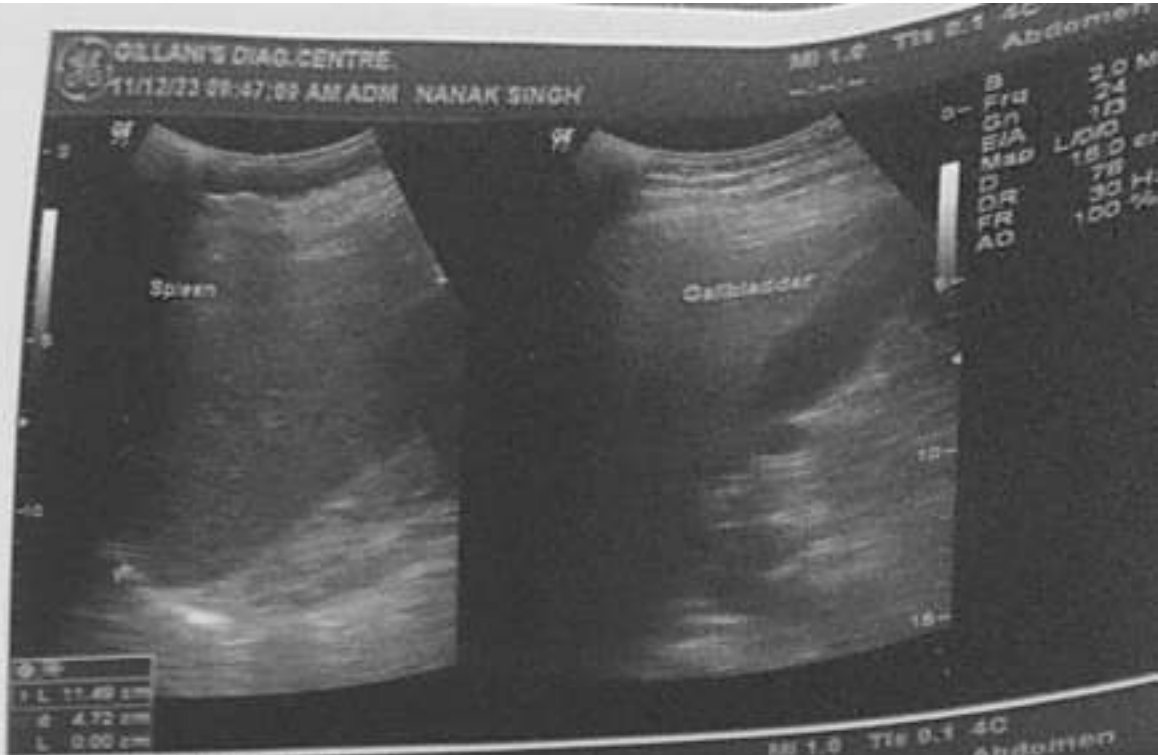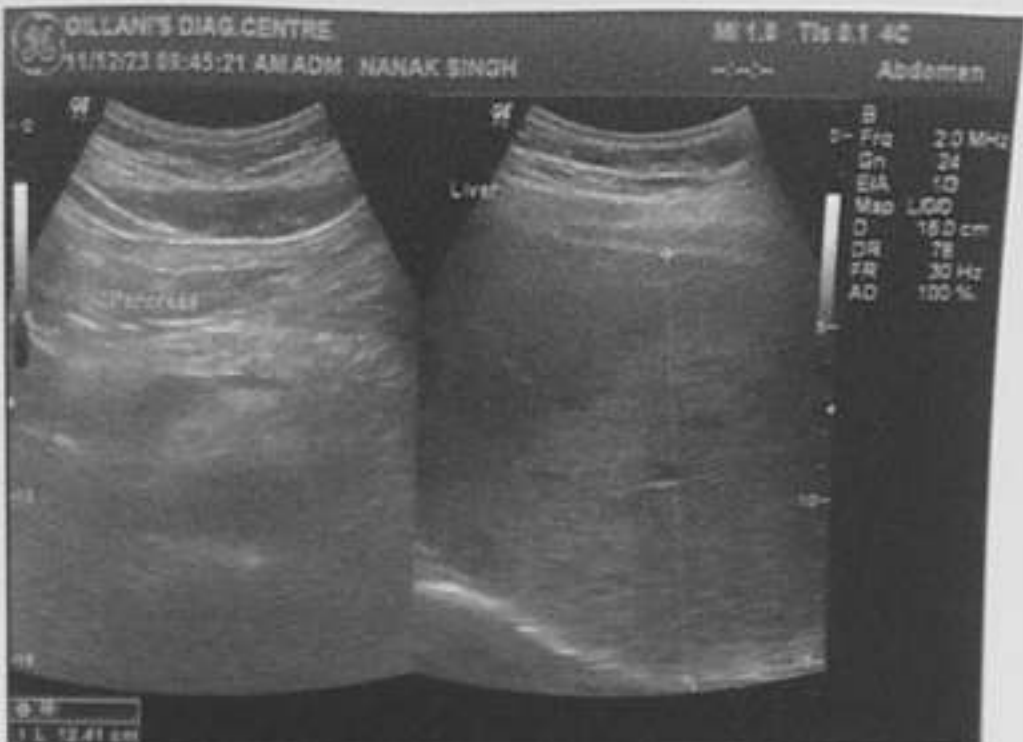NO RWMA, MILD MR  
MILD CONCENTRIC LVH  
GRADE I LV DIASTOLIC DYSFUNCTION  
NORMAL LV SYSTOLIC FUNCTION



*[Signature]*  
Cardiologist

### IMPORTANT

- AS PER UNIVERSAL ACCEPTANCE, ALL ANOMALIES MAY NOT BE APPARENT DURING SCANNING.
- NOT FOR PRENATAL SEX DETERMINATION OF FOETUS UNDER PRODT AT/MEDIAL LEGAL PURPOSE.
- THE INVESTIGATION FINDING SHOULD ALWAYS BE CONSIDERED IN CORRELATION WITH THE CLINICAL AND OTHER INVESTIGATION FINDING WHERE APPLICABLE.



# GILLANI'S DIAGNOSTIC CENTRE



MUNICIPALITY ROAD, OPP. POLICE HEADQUARTERS, KARAN NAGAR, SRINAGAR-190010, KMR.

B/O.: PEERWARI COMPLEX, OPP. SHIRAZ CINEMA, KHANYAR, SRINAGAR CELL: 9906476734

ID :- AHCN-32730112301001  
 Client Name:- Nanak Singh Bali.  
 Provider :- Apollo


Gender :- Male  
 Cell :- 7006590387  
 Dated: 11/Dec/2023

## U.S.G Abdomen /Pelvis.

- Liver :-** Normal in size, outline and Shows Bright echopattern, Liver span is 124 mm. IHBR not dilated. PV is normal.
- Gall Bladder:-** Well distended Wall thickness normal, No Calculus / Worm pericholecystic collection.
- C.B.D :-** Common bile duct is not dilated. No worm / calculus seen.
- Pancreas: -** Normal in size, outline and echopattern. No focal / diffuse pathology. Pancreatic duct not dilated.
- Spleen:-** Measuring 115 mm. Normal size & echopattern. No focal / diffuse pathology. Normal spleno-portal axis.
- Retroperitoneum:-** No nodes / mass.
- Kidneys:-** Both kidneys are normal in size, outline & echotexture. No calculus / hydronephrosis in Kidneys. CMD maintained in both kidneys. No cyst / mass seen. Rt. Kidney measuring 101 x 40mm & Lt. Kidney measuring 106 x 45mm
- Urinary Bladder:-** Normal in outline. Wall thickness normal. No calculus / diverticulum.
- Prostate:-** Measuring 32 x 37 x 34mm - Wt. 21 grams. Normal in outline and echopattern. No focal lesion. Capsule is intact. No free fluid.

**IMPRESSION:-**

**FATTY LIVER GRADE - I**  
 Normal Kidneys / UB / Prostate

  
**Dr. Khalid Ahmad**  
 Radiologist

**IMPORTANT**

- AS PER UNIVERSAL ACCEPTANCE, ALL ANOMALIES MAY NOT BE APPARENT DURING SCANNING
- NOT FOR PRENATAL SEX DETERMINATION OF FOETUS UNDER PHOT AT MEDICAL LEGAL PURPOSE.
- THE INVESTIGATION FINDING SHOULD ALWAYS BE CONSIDERED IN CORRELATION WITH THE CLINICAL AND OTHER INVESTIGATION FINDING WHERE APPLICABLE.





# GILLANI'S DIAGNOSTIC CENTRE



MUNICIPALITY ROAD, OPP. POLICE HEADQUARTERS, KARAN NAGAR, SRINAGAR-190010, KMR.

B/O.: PEERWARI COMPLEX, OPP. SHIRAZ CINEMA, KHANYAR, SRINAGAR CELL: 9906476734

ID :- AHCN-32730112301001

Gender :- Male

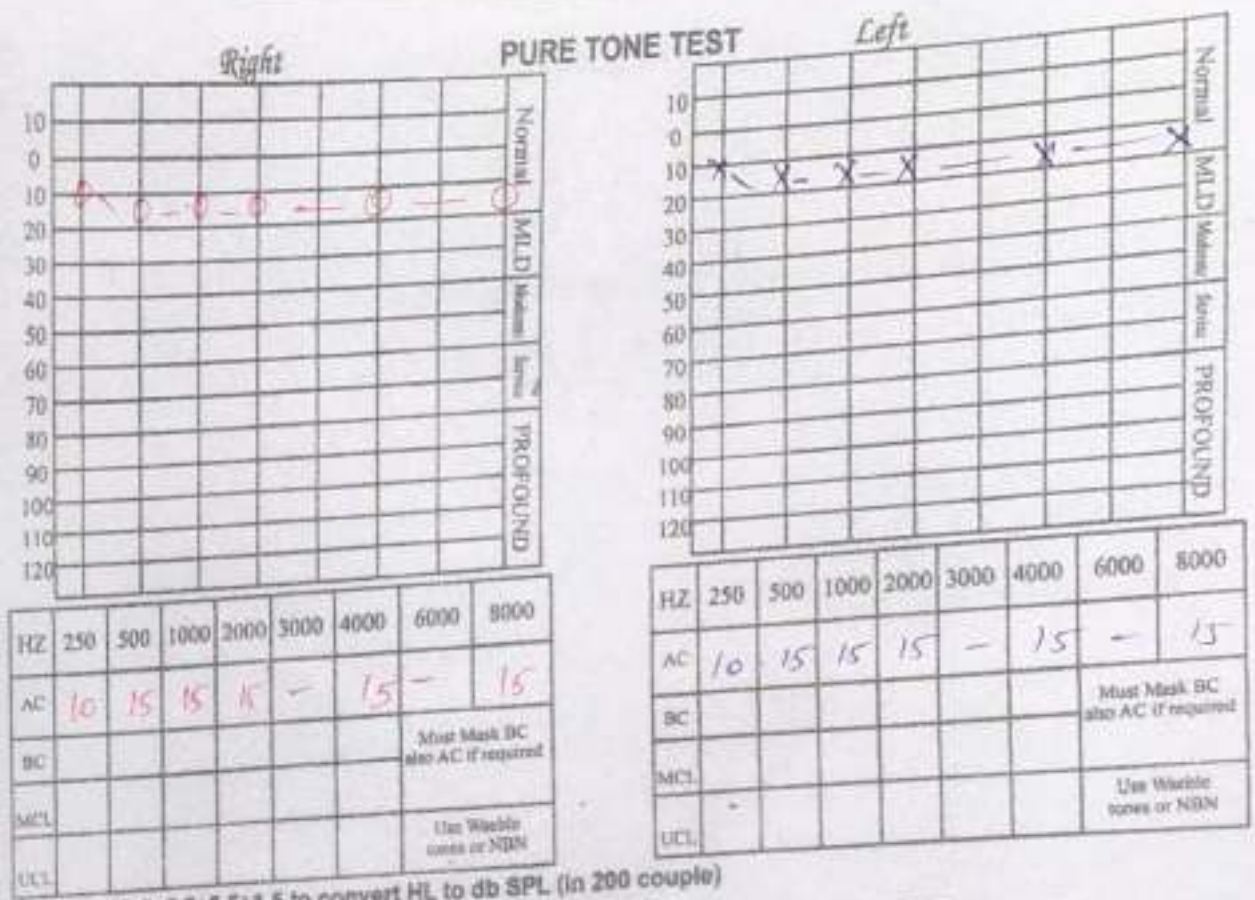
Client Name:- Nanak Singh Bali.

Cell :- 7006590387

Provider :- Apollo

Dated: 11/Dec/2023

## AUDIOMETRY REPORT



Add + 8.5+3.5+6.5+6.5+1.5 to convert HL to db SPL (in 200 couple)

TEST	Right Ear (dB)	Left Ear (dB)
AC	10	10
BC		
MCL		
UCL		



R  
Weber  
Rinne  
ABC Diagnosis



L  
Audiologist

**IMPORTANT**  
Essential Data: AC-BC Thresholds at 250 Hz, 500 Hz, 1000 Hz, 2000 Hz & 4000 Hz  
 \* AS PER DIRECTIVE OF ICMR, SINCE RESOLUTION POWER MAY NOT BE APPARENT DURING SCANNING  
 \* NOT FOR PUBLICATION OR USE IN ANY MANNER WITHOUT THE EXPRESS WRITTEN PERMISSION OF THE CENTRE UNDER PNPT AT MEDICAL LEGAL PURPOSE.  
 \* THE INVESTIGATION FINDING SHOULD ALWAYS BE CONSIDERED IN CORRELATION WITH THE CLINICAL AND OTHER INVESTIGATION FINDING WHERE APPLICABLE.



09/12/2023 13:06