

**Diwakar Diagnostic Centre**  
E-7/636, Arera Colony, Bhopal

658 / MR. ABHISHEK PACHORI32 / 32 Yrs / M / 169 Cms / 63 Kg Date: 09-Jul-2022 Refd By : BOB

**Report :**

TEST OBJECTIVE	: ROUTINE CHECK UP
RISK FACTOR	: MALE
ACTIVITY	: MODERATE ACTIVE
OTHER INVESTIGATION	: ROUTINE BLOOD INVESTIGATION
REASON FOR TERMINATION	: TEST COMPLETE
EXERCISE TOLERANCE	: GOOD
EXERCISE INDUCED ARRHYTHMIAS	: NO
HAEMODYNAMIC RESPONSE	: NORMAL
CHRONOTROPIC RESPONSE	: NORMAL
FINAL IMPRESSION	: STRESS TEST IS NEGATIVE FOR EXERCISE INDUCED ISCHAEMIC HEART DISEASE



Doctor : Cardiologist

Stage	Time	Duration	Belt Speed (mph)	Elevation	METs	Rate	% THR Achieved	BP	RPP	PVC	Comments
Supine	00:14	0:01	00.0	00.0	01.0	94	50 %	126/80	118	00	
Standing	00:17	0:01	00.0	00.0	01.0	94	50 %	126/80	118	00	
HV	00:26	0:01	00.0	00.0	01.0	105	56 %	126/80	132	00	
Warm Up	00:32	0:04	01.7	10.0	01.1	126	67 %	126/80	158	00	
ExStart	00:34	0:06	01.7	10.0	01.1	101	54 %	126/80	127	00	
BRUCE Stage 1	03:34	3:00	01.7	10.0	04.7	132	70 %	130/80	171	00	
BRUCE Stage 2	06:34	3:00	02.5	12.0	07.1	150	80 %	140/90	210	00	
BRUCE Stage 3	09:34	3:00	03.4	14.0	10.2	175	93 %	146/86	255	00	
PeakX	09:36	3:00	03.4	14.0	10.3	175	93 %	146/86	255	00	
Recovery	10:35	1:00	00.0	00.0	04.3	137	73 %	140/90	191	00	
Recovery	11:35	2:00	00.0	00.0	01.0	122	65 %	136/86	165	00	
Recovery	11:42	2:06	00.0	00.0	01.0	129	69 %	136/86	175	00	

**Findings :**

Exercise Time : 09:03  
 Max HR Attained : 175 bpm 93% of Target 188  
 Max BP Attained : (Sys) 146/86, (Dis) 140/90  
 Max Workload Attained : 10.3 Good response to induced stress  
 Test End Reasons : Test Complete


Doctor : Cardiologist

653 / MR. ABHISHEK PACHORI/32 Yrs / M / 169 Cms / 63 Kg / HR : 94

Date: 09-Jul-2022 02:02:11 PM METS: 1.0/ 94 bpm 50% of THR BP: 126/80 mmHg Raw ECG/ BLC On/ Notch On/ HF 0.05 Hz/LF 20 Hz

EXTime: 00:13 0.0 mph, 0.0%  
25 mm/Sec. 1.0 Cm/mV

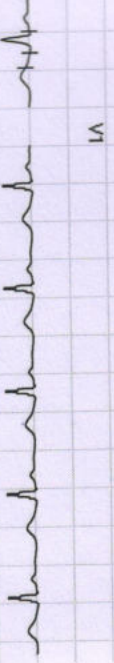
4X 80 ms Post J



I  
STL 0.6  
STS 0.6



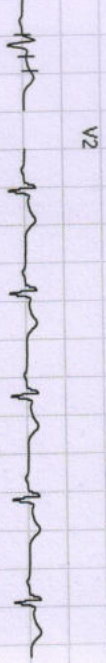V1  
-0.5  
-0.7



II  
2.1  
2.1




V2  
1.0  
0.6



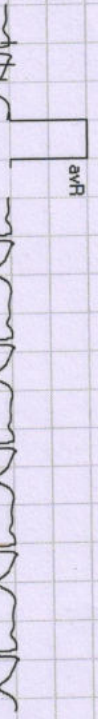III  
1.5  
1.5



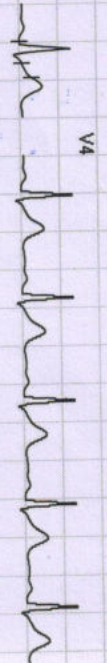V3  
2.2  
2.0



aVR  
-1.4  
-1.3



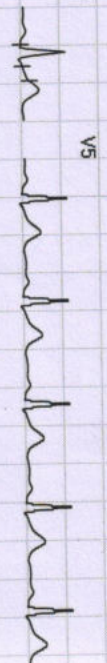V4  
1.5  
1.6




aVL  
-0.4  
-0.5



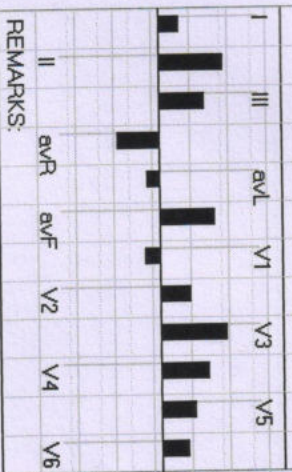
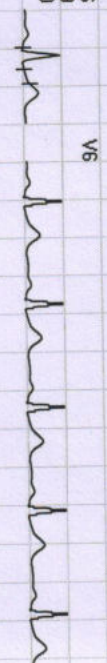V5  
1.1  
1.1



aVF  
1.8  
1.8



V6  
0.9  
1.0



REMARKS:



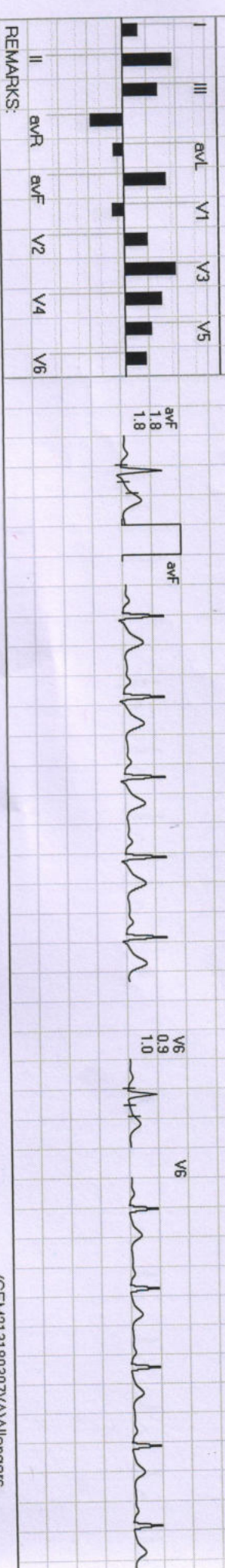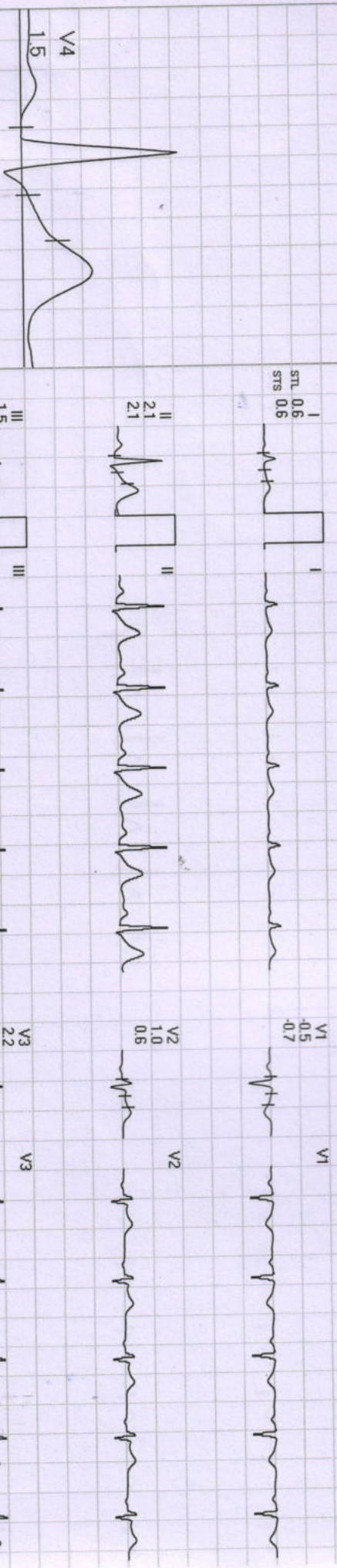658 / MR. ABHISHEK PACHORI/32 / 32 YRS / M / 169 Cms / 63 Kg / HR : 94

Date: 09-Jul-2022 02:02:11 PM METS: 1.0/ 94 bpm 50% of THR BP: 126/80 mmHg Raw ECG/ BLC On/ Notch On/ HF 0.05 Hz/LF 20 Hz

EXTime: 00:16 0.0 mph, 0.0%

25 mm/Sec. 1.0 Cm/mV

4X 80 mS Post J



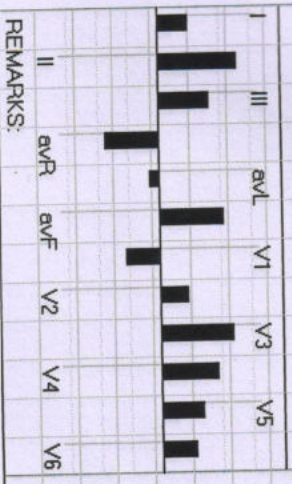
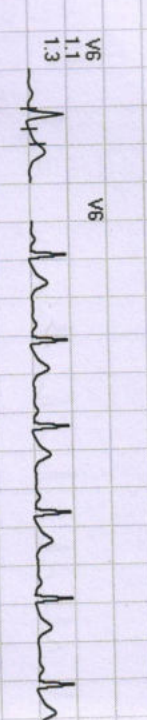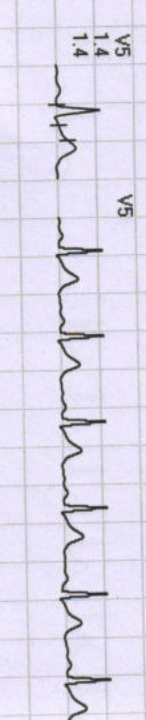
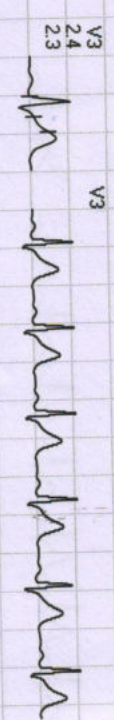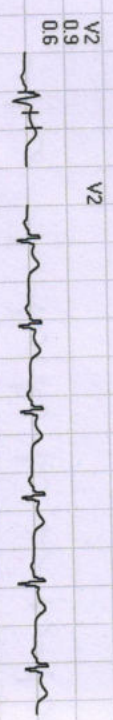


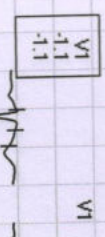


REMARKS:

658 / MR. ABHISHEK PACHORI 32 Yrs / M / 169 Cms / 63 Kg / HR : 105

Date: 09-Jul-2022 02:02:11 PM METS: 1.0/105 bpm 55% of THR BP: 126/80 mmHg Raw ECG/ BLC On/ Natch On/ HF 0.05 Hz/LF 20 Hz

EXTime: 00:25 0.0 mph, 0.0%  
25 mm/Sec. 1.0 Cm/mV

4X 80 ms Post J





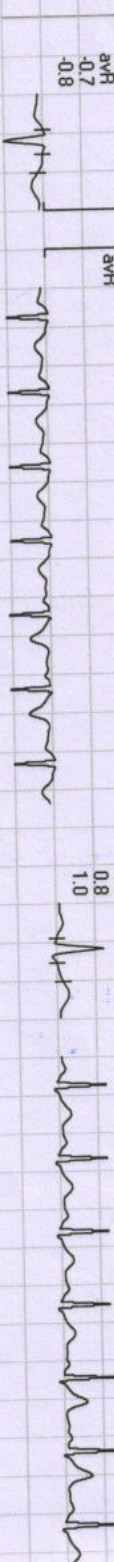


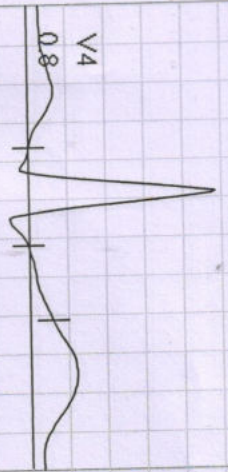
REMARKS:

658 / MR. ABHISHEK PACHORI/32 / 32 Yrs / M / 169 Cms / 63 Kg / HR : 126

Date: 09-Jul-2022 02:02:11 PM METS: 1.0/126 bpm 67% of THR BP: 126/80 mmHg Raw ECG/BLC On/ Natch On/ HF 0.05 Hz/LF 20 Hz

EXTime: 00:31 1.0 mph, 0.0%  
25 mm/Sec. 1.0 Cm/mV

4X 80 mS Post J



I	III	aVL	V1	V3	V5
II	aVR	aVF	V2	V4	V6

REMARKS:

658 / MR. ABHISHEK PACHORI/32 Yrs / M / 169 Cms / 63 Kg / HR : 126

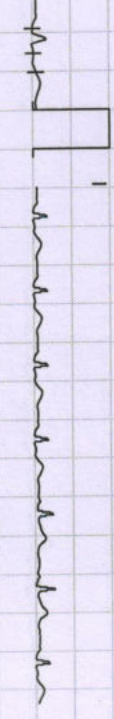Date: 09-Jul-2022 02:02:11 PM METS: 1.0/126 bpm 67% of THR BP: 126/80 mmHg Raw ECG/ BLC On/ Notch On/ HF 0.05 Hz/LF 20 Hz

ExTime: 00:00 0.0 mph, 0.0%

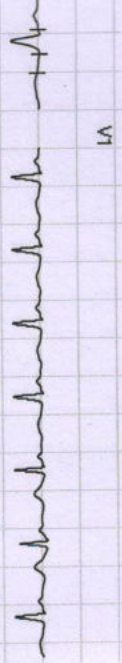4X 80 mS Post J

25 mm/Sec. 1.0 Cm/mV

I  
STL 0.4  
STS 0.4



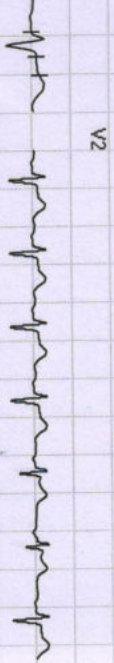
V1  
-0.1  
-0.4



II  
1.0  
1.3



V2  
1.0  
0.5



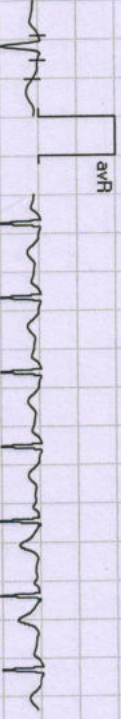III  
0.6  
0.9



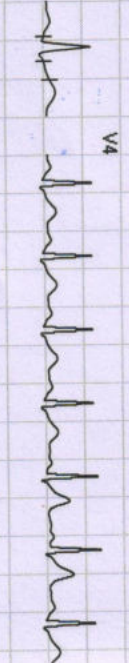V3  
1.1  
1.2



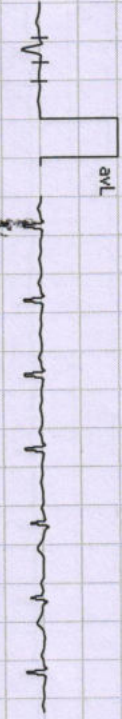
avR  
-0.7  
-0.8



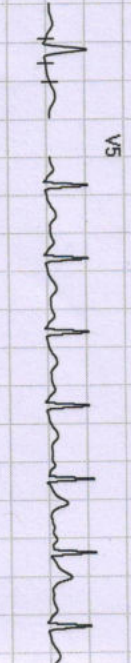
V4  
0.8  
1.0



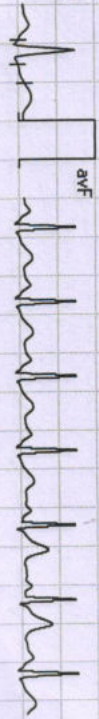avL  
-0.1  
-0.2



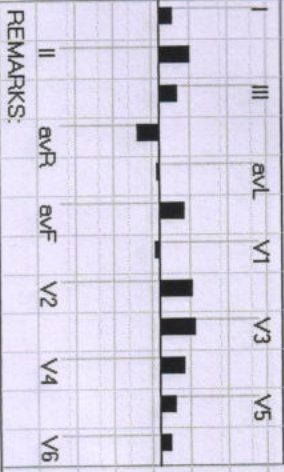
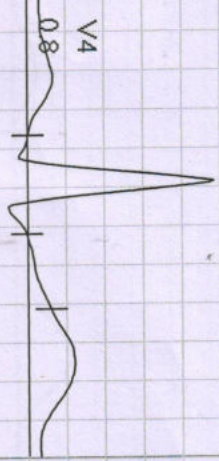
V5  
0.5  
0.7



avF  
0.8  
1.1



V6  
0.3  
0.5



REMARKS:



658 / MR. ABHISHEK PACHORI/32 / 32 Yrs / M / 169 Cms / 63 Kg / HR : 132

Date: 09-Jul-2022 02:02:11 PM

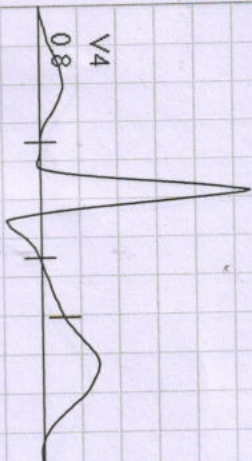
METS: 4.7 / 132 bpm 70% of THR

BP: 130/80 mmHg Raw ECG/ BLC On/ Notch On/ HF 0.05 Hz/LF 20 Hz

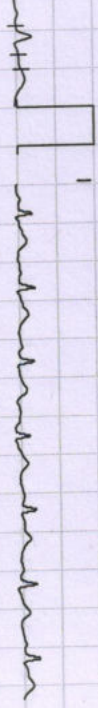EXTime: 03:00 1.7 mph, 10.0%

25 mm/Sec. 1.0 Cm/mV

4X 60 ms Post J



I  
STL 0.6  
STS 0.6



V1  
-0.4  
-0.8



II  
1.2  
1.6



V2  
0.7  
0.6



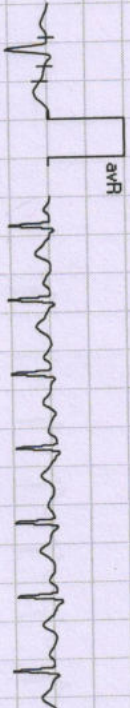
III  
0.6  
1.0



V3  
1.3  
1.8




avR  
-0.9  
-1.1



V4  
0.8  
1.4



avL  
0.0  
-0.2



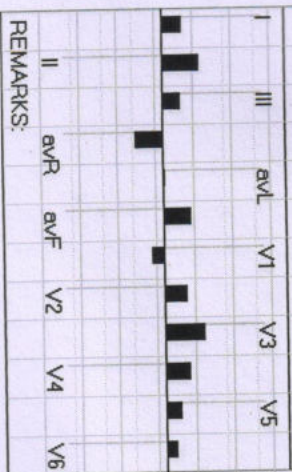
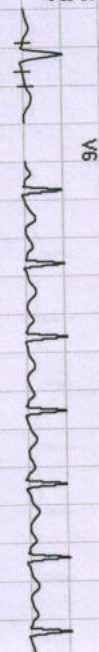V5  
0.5  
0.9



avF  
0.9  
1.3



V6  
0.3  
0.7



REMARKS:





658 / MR. ABHISHEK PACHORI/32 Yrs / M / 169 Cms / 63 Kg / HR : 150


Date: 09-Jul-2022 02:02:11 PM

MEETS: 7.1/150 bpm 79% of THR BP: 140/90 mmHg Raw ECG/ BLC On/ Notch On/ HF 0.05 Hz/LF 20 Hz

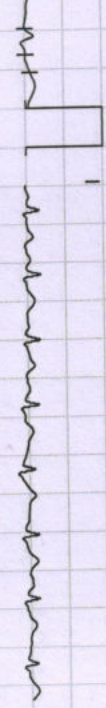
EXTime: 06:00 2.5 mph, 12.0%

4X 60 mS Post J

25 mm/Sec. 1.0 Cm/mV



I  
STL 0.6  
STS 1.0



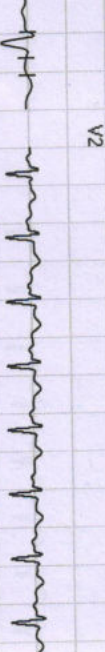V1  
-0.1  
-0.5



II  
1.2  
2.6



V2  
-0.1  
0.2



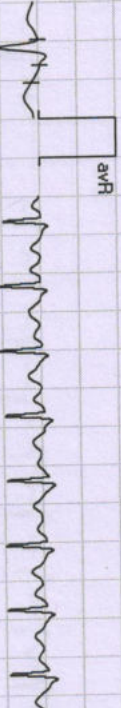
III  
0.6  
1.5



V3  
1.0  
2.2




avR  
-0.9  
-1.8



V4  
0.7  
1.7




avL  
0.0  
-0.2



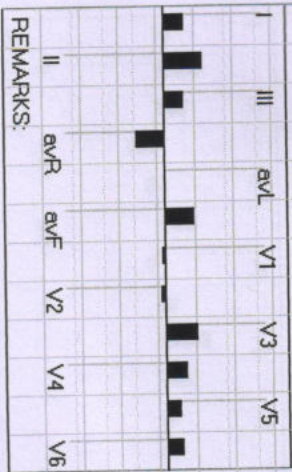
V5  
0.4  
1.2



avF  
0.9  
2.0



V6  
0.5  
0.9



REMARKS:



658 / MR. ABHISHEK PACHORIS2 / 32 Yrs / M / 169 Cms / 63 Kg / HR : 175

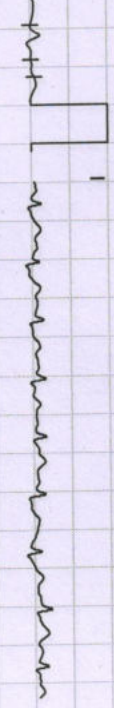Date: 09-Jul-2022 02:02:11 PM METS: 10.2/175 bpm 93% of THR BP: 146/86 mmHg Rew ECG/ BLC On/ Natch On/ HF 0.05 Hz/LF 20 Hz

ExTime: 09:00 3.4 mph, 14.0%

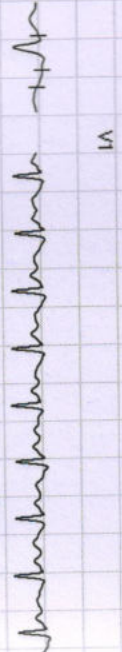
4X 60 ms Post J

25 mm/Sec. 1.0 Cm/mV

I  
STL 0.5  
STS 0.8



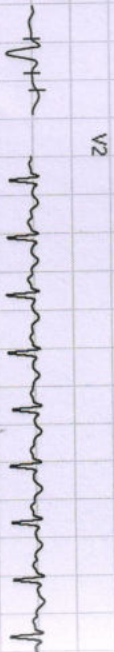
V1  
-0.3  
-1.3




II  
1.4  
2.8




V2  
0.7  
1.3



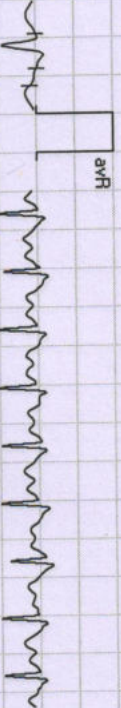
III  
1.0  
2.1



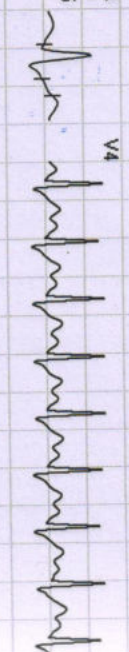V3  
1.7  
3.3



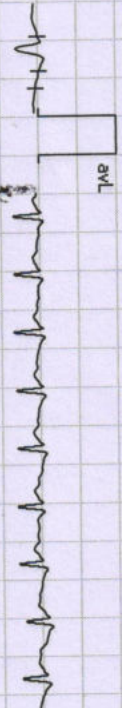
avR  
-0.9  
-1.7



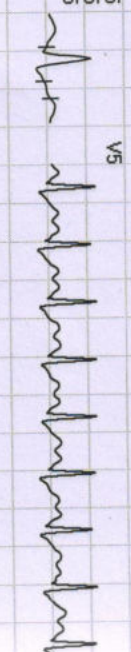
V4  
1.1  
2.5




avL  
-0.3  
-0.7



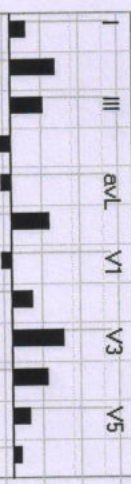
V5  
0.5  
1.5



avF  
1.2  
2.5



V6  
0.3  
1.0



REMARKS:  
II avR avF V2 V4 V6


658 / MR. ABHISHEK PACHORI/32 Yrs / M / 169 Cms / 63 Kg / HR : 175

Date: 09-Jul-2022 02:02:11 PM METS: 10.3/175 bpm 93% of THR BP: 146/86 mmHg Raw ECG/BLC On/ Notch On/ HF 0.05 Hz/LF 20 Hz

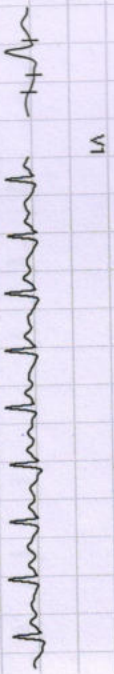
EXTime: 09:02 4.2 mph, 16.0%  
25 mm/Sec. 1.0 Cm/mV

4X 60 mS Post J


I  
STL 0.5  
STS 0.8



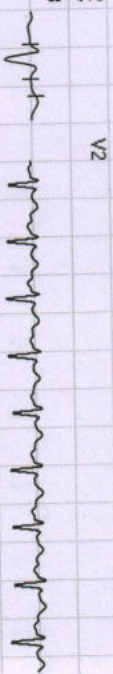
V1  
-0.3  
-1.3




II  
1.4  
2.8




V2  
0.7  
1.3



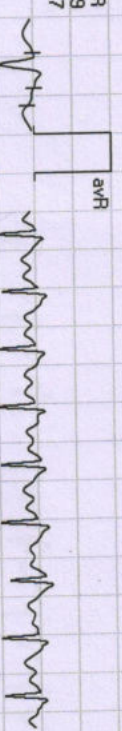
III  
1.0  
2.1



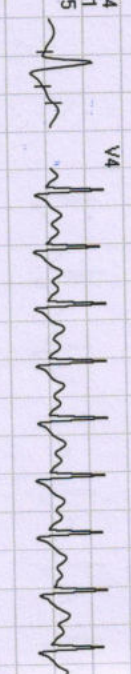
V3  
1.7  
3.3



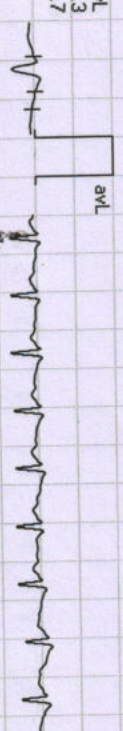avR  
-0.9  
-1.7



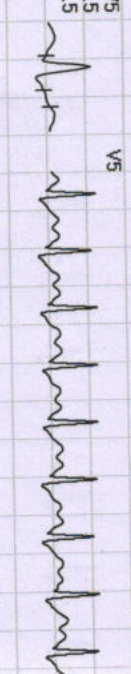V4  
1.1  
2.5




avL  
-0.3  
-0.7



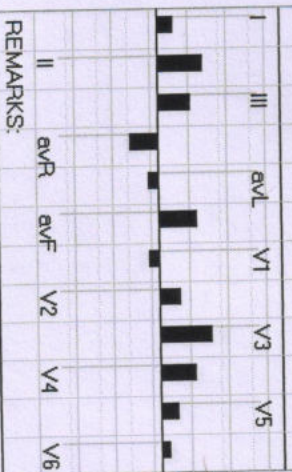

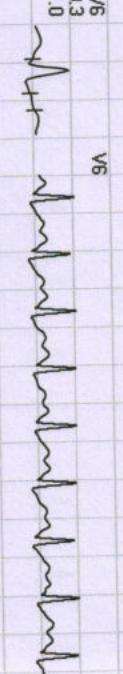
V5  
0.5  
1.5



avF  
1.2  
2.5



V6  
0.3  
1.0



REMARKS:

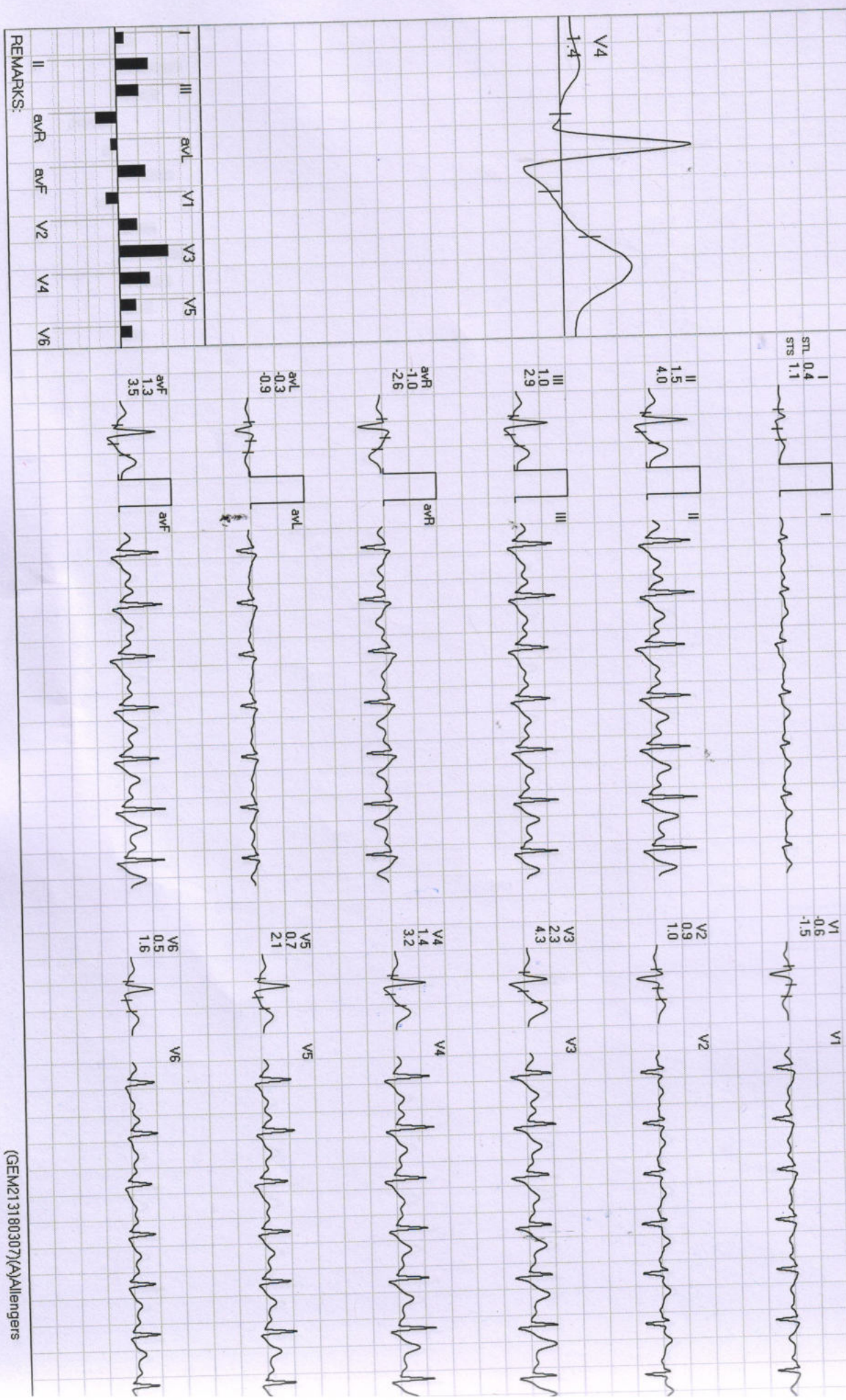


668 / MR. ABHISHEK PACHORI/32 Yrs / M / 169 Cms / 63 Kg / HR : 137

Date: 09-Jul-2022 02:02:11 PM METS: 4.2 / 137 bpm 72% of THR BP: 140/90 mmHg Raw ECG/ BLC On/ Notch On/ HF 0.05 Hz/LF 20 Hz

EXTime: 09:02 0.0 mph, 0.0%  
25 mm/Sec. 1.0 Cm/mV

4X 60 mS Post J



REMARKS:

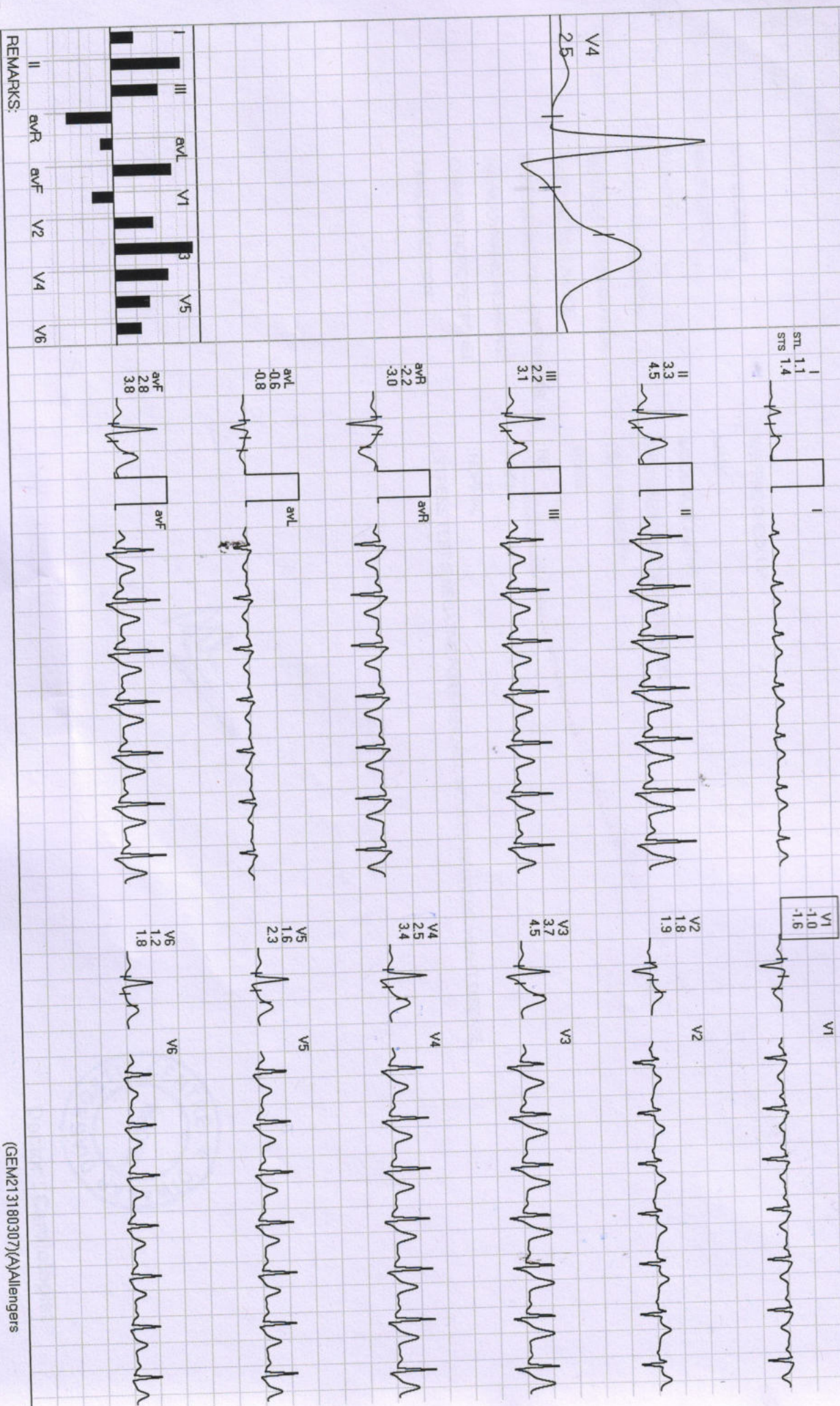


658 / MR. ABHISHEK PACHORI/32 YRS / M / 169 Cms / 63 Kg / HR : 122

Date: 09-Jul-2022 02:02:11 PM METS: 1.0/122 bpm 64% of THR BP- 136/86 mmHg Raw ECG/ BLC On/ Notch On/ HF 0.05 Hz/LF 20 Hz

EXTime: 09:02 0.0 mph, 0.0%  
25 mm/Sec. 1.0 Cm/mV

4X 80 mS Post J



REMARKS:

**INDIAN UNION DRIVING LICENCE** Form 7

MADHYA PRADESH STATE

Number: **MP0403008017397**  
 Name: **ASHISH K PACHORI**

SO/W of: **SH MADAN LAL PACHORI**  
 Address: **47 BHAWANI NAGAR BEHIND  
 INDRAPURI PIPLANI  
 BHOPAL, MP**

Issued on: **24-03-2009**  
 DOB: **28-06-1989** BG  
 is Licence to drive

Vehicle Class: **LMV/LA1**  
 Date of Issue: **23-03-2008** | **21-03-2008**  
 Valid till (Transport): **22-03-2015**  
 Valid till (Non-Transport): **22-03-2015**

Auth. by: **ASHOK SHARMA**

HOLDER SIGNATURE  
 Government Authentication  
 Bhopal, MP



**Dr. B. M. Agarwal**  
 MBBS, DCP  
 Consultant Pathologist

*For Health checkup purpose*

*Dr. B. M. Agarwal*



# द्विवाकर डायग्नोस्टिक सेंटर

E-7/636, पंजाब नेशनल बैंक के पास, मैन रोड, अरेरा कॉलोनी भोपाल ( म.प्र. )


फोन: 0755-2465288, 0755-3520545 मो: 9826340190

Pt.Name :-	Mr. Abhishek Pachori
Age :-	32y/M
Refd. By :-	BOB
Lab.pNo.:-	233
Date :-	09/07/2022

## EXAMINATION OF BLOOD

TEST	RESULT	NORMAL VALUE
Haemoglobin	15.1mgs%	Female 12-16gms%, Male 14-18gms%
Red Cell count	4.9	4.5-5.6 million /cumm
Platelate Count	2.64	1.5-5.6 Lac/cumm
Leucocytes per.cu.mm	7900/cumm	5000-11000/cumm
Neutrophils	58%	50-70%
Lymphocytes	32%	20-40%
Eosinophils	06%	0-7%
Monocytes	04%	2-8%
PCV	40.6	37-47
MCV	79.4	76-96
MCH	29.6	27-32
MCHC	33.2	31-35
ESR	06	Male 0-9, Female 0-20mm/FHR
Blood Group	"B "Positive	By slide Method
S.Bilirubin(Total)	0.76	0.2-1.0mg/dl
Direct	0.31	0.0-0.25mg/dl
Indirect	0.45	
SGOT	24.8	5-35U/L
SGPT	29.6	8-40U/L
Alk Phosphatase	10.1	3-13 KA units
S. Protein(Total)	7.0	6.0-8.0mg%
Albumin	4.0	3.7-5.3mg%
Globulin	3.0	1.5 to 3.5 mg%
AG Ratio	1.23	1.-2.0
Blood Urea Nitrogen (BUN)	13.7	7-20 mg/dl
S.Creatine	0.84	0.5-1.4mg/dl
Uric Acid	5.2	4.8 to 7.5 mg/dl
Calcium	9.1	8.5-10.5 gm/dl
GGTP	31.1	5-35 UL/dl
FastingBlood Sugar	82.8	70to 110mg/dl
Post Prandial Blood Sugar	133.8	Up tp 140mg/dl
Total Serum Cholesterol	177.1	100-250 mg%
Serum Triglyceride	146.5	Up to 160 mg%
Serum Cholesterol HDL	46.2	Up to 65 mg%
Serum Cholesterol LDL	101.6	Up to 125 mg%
VLDL	29.3	Up to 30 mg%
TC/HDL Ratio	3.28	Bellow 5
Glycosylated Hemoglobin HBA1c	5.2	Below - 6.0 % -Non Diabetic control 6-7 % -Excellent control Above- 8 % -Poor control

All test have technical limitation. Collaborative clinic pathological interpretation is mandatory. In case of disparity test may be repeated immediately. Typographical mistakes should be get correct instantly. This report is not valid for medico legal purpose.



Pathologist  
**Dr. B. M. Agarwal**  
MBBS, DCP  
Consultant Pathologist



# दिवकर डायग्नोस्टिक सेंटर

E-7/636, पंजाब नेशनल बैंक के पास, मैन रोड, अरेरा कॉलोनी भोपाल ( म.प्र. )

फोन: 0755-2465288, 0755-3520545 मो: 9826340190

Pt.Name :-	Mr. Abhishek Pachori
Age :-	32y/M
Refd. By :-	BOB
Lab.pNo.:-	233
Date :-	09/07/2022

## EXAMINATION OF BLOOD

### Thyroid profile

<u>TEST</u>	<u>RESULT</u>	<u>NORMAL VALUE</u>
T3 - TOTAL	91.6	82-213 ng/dL
T4 - TOTAL	6.88	6.09-12.23 ug/dL
THYROID STIMULATING HORMONE (TSH)	1.91	0.45-4.25 ul/mL

#### Interpretation:

TSH Levels will be elevated in primary hypothyroidism, TSH levels will be low in Hyperthyroidism there is decreased production of thyroid hormones by the thyroid hence the person may experience symptoms such as weight gain, constipation, cold intolerance and fatigue. Iodine deficiency and Hashimoto thyroiditis is the most common cause of hypothyroidism It makes Thyroid stimulating hormone. If TSH levels are abnormally high it could mean you have an underactive thyroid or hypothyroidism.

Dr. B. M. Agarwal  
Pathologist  
MBBS, DCP

All test have technical limitation. Collaborative clinic pathological interpretation is mandatory. In case of disparity test may be repeated immediately. Typographic mistakes should be get correct instantly. This report is not valid for medico legal purpose







# द्विवाकर डायग्नोस्टिक सेंटर


E-7/636, पंजाब नेशनल बैंक के पास, मैन रोड, असेरा कॉलोनी भोपाल ( म.प्र. )  
फोन: 0755-2465288, 0755-3520545 मो: 9826340190

Pt.Name :-	Mr. Abhishek Pachori
Age :-	32y/M
Refd. By :-	BOB
Lab.pNo.:-	233
Date :-	09/07/2022

## EXAMINATION OF BLOOD

<u>TEST</u>	<u>RESULT</u>	<u>NORMAL VALUE</u>
PSA	3.89 ng/ml.	0.21-6.77 ng/ml.



  
Dr. B. M. Agarwal  
Pathologist  
Consultant Pathologist

All test have technical limitation. Collaborative clinic pathological interpretation is mandatory. In case of disparity test may be repeated immediately. Typographic mistakes should be get correct instantly. This report is not valid for medico legal purpose



# दिवकर डायग्नोस्टिक सेंटर

E-7/636, पंजाब नेशनल बैंक के पास, मैन रोड, असेरा कॉलोनी भोपाल ( म.प्र. )

फोन: 0755-2465288, 0755-3520545 मो: 9826340190

Pt.Name :-	Mr. Abhishek Pachori
Age :-	32y/M
Refd. By :-	BOB
Lab.pNo.:-	233
Date :-	09/07/2022
Skigram	X Ray Chest PA View
Radiologist	Dr. B.M.Agarwal MD (Radiology)

## REPORT

Tricia Central

Thoracic cage normal

Both Lungs Field Clear.

Both hilers normal

Cardiac border normal

Both cp angles clear

Both domes and diaphragm normal

## IMPRESSION

\*\*\*\*\*

-NO CARDIO PULMONARY PATHOLOGY


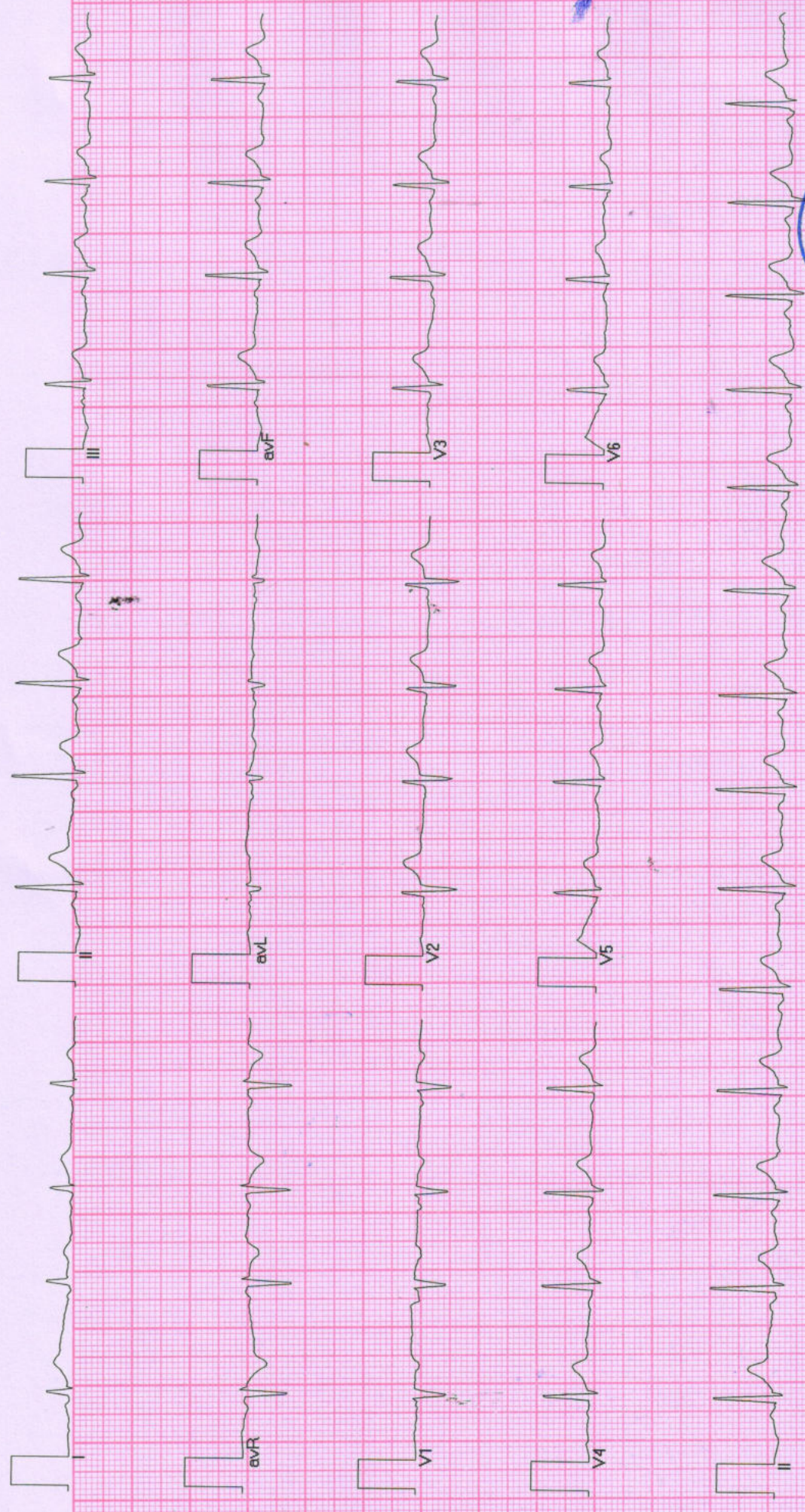
-COORELATE WITH CLINICAL FINDINGS.



**Dr. B. M. Agarwal**  
MD, Radiology  
Consultant Radiologist  
**Radiologist**

**Allengers Global Healthcare Pvt. Ltd.,**  
139 / MR. ABHISHEK PACHORI / 32 Yrs / M / 169Cms. / 63Kgs.  
Heart Rate : 87 bpm / Tested On : 09-Jul-22 14:00:59 / HF 0.05 Hz - LF 100 Hz / Notch 50 Hz / Sn 1.00 Cm/mV / Sw 25 mm/s  
/ Refd By: BOB

**ECG**



*AGHPL*

**BPL-DYNATRAC**

Allengers ECG (Pisces)(PIS213180317)



# डॉ. सविता क्लिनिक



34, भूतल, मोहिनी अदिति आर्केड, शाहपुरा मस्जिद के पास  
भरत नगर रोड, ई-7/194, अरेरा कॉलोनी, भोपाल - 462038

Mob. : 8989649694, 9516333619

Clinic Registration : CL/5392/Jun/2017

PNDT Registration : MPPCPNDT/BPL/2017/206

Name : Mrs. Abhe Sheti Pachori Age 32/Male YRS./F  
R/B Health check-up No. 9/7/2022 Date 9/7/2022

## WHOLE ABDOMES ULTRASOUND REPORT

### Indication:

Liver appears normal in size and shape with normal outline. Normal/  
increased perenchymal echogenicity is noted. No E/O focal lesion/ IHBR  
dilatation is sen. Hepatic veins and portal veins appear normal.

No E/O subdiaphragmatic Collection.

Gall Blader is physiologically well distended. No. E/O echogenic foci in GB  
lumen. GB wall is normal / thickened. No E/O pericholecystic collection.  
Common duct reveals normal course and caliber.

Pancreas appear normal in size, shape and echo texture with smooth  
contour. No peripancreatic pathology seen. (Not seen due to gases)

Spleen is normal in size and echo texture.

IVC and aorta appear to be normal.

No evidence of lymphadenopathy is noted.

No evidence of free fluid is noted.

Right Kidney is normal in size. size, shape and position. Corticomedullary  
defferentiation (CMD) is well maintained. Normal cortical thickness is  
noted. No E/O hydronephrosis or calculus is noted.

PTO

Left Kidney is normal in size, shape and position. CMD is well maintained. Normal cortical thickness is noted. No E/O hydronephrosis or calculus is noted.

Urinary Bladder is well distended (physiological). its contents are echo free. No E/O bladder wall thickening is noted. ~~Post-void residue is insignificant.~~

Prostate is normal in size. Shape and echo texture with smooth outline. No E/O focal lesion is noted.

Uterus is ante/ retro verted and normal in size, shape and echo texture with smooth outline. No E/O focal lesion is noted. Endometrial echo appear normal. Cervical and vaginal shadows appear normal.

Right Ovary appears enlarged / Normal in size, shape and echo texture.

Left Ovary appears enlarged / Normal in size, shape and echo texture.

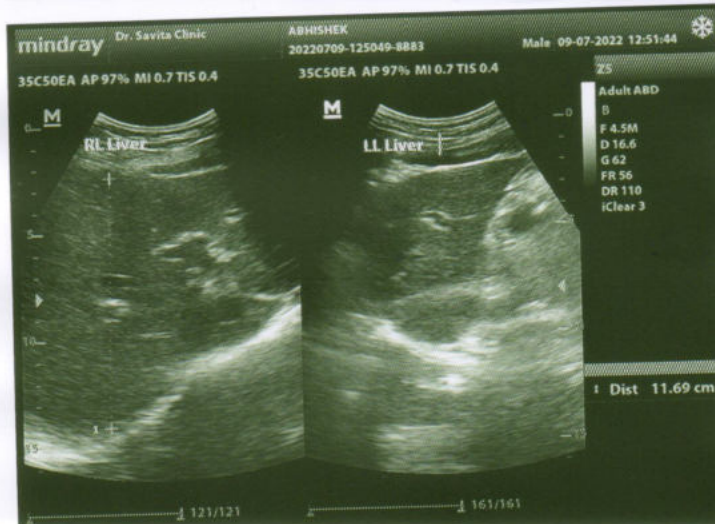
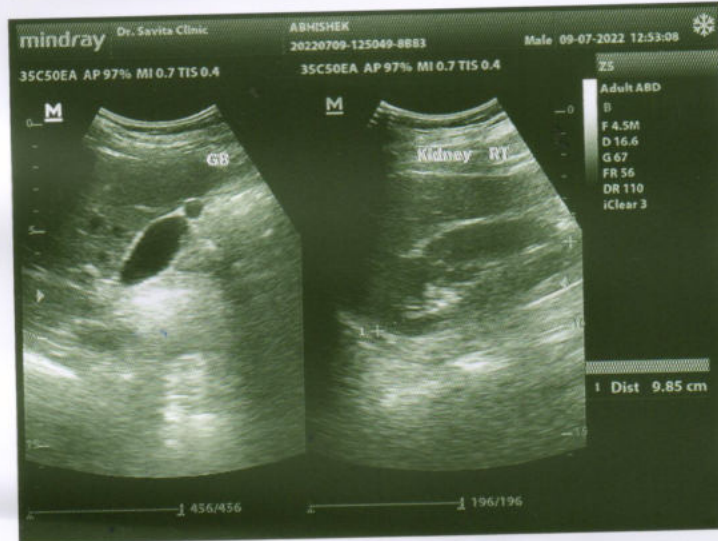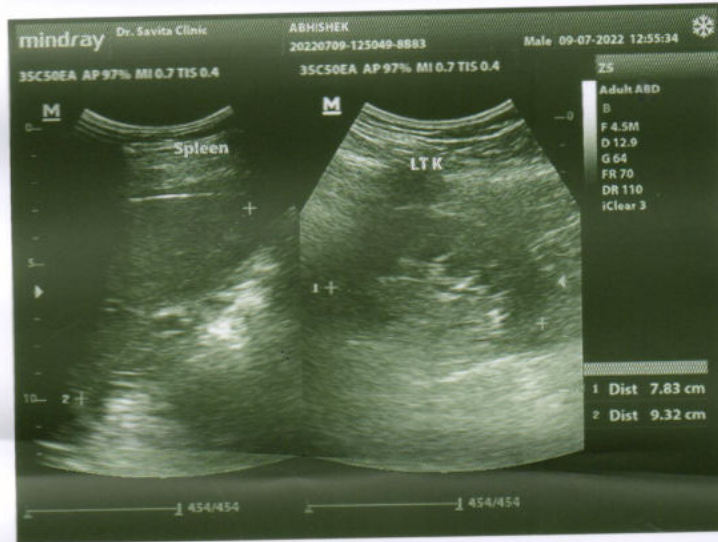
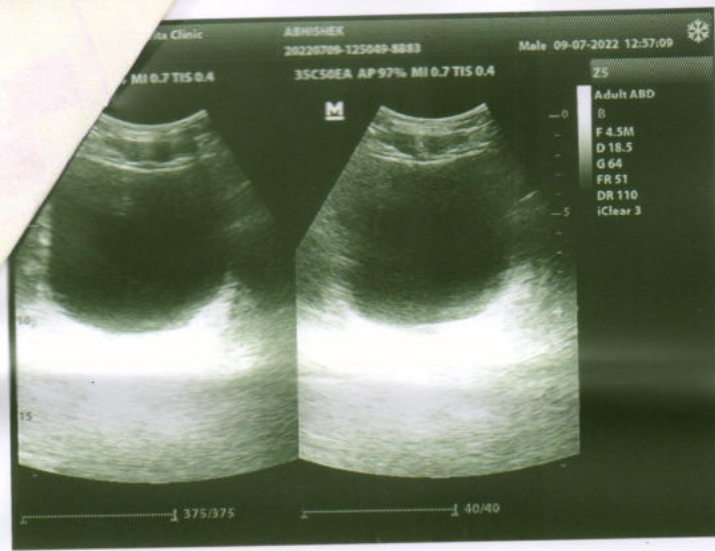
Impression : Normal study.

Advised clinical Correlation.

Dr. P. Savita, MD  
MBBS, MD (O&G) Reg. No. 9971  
स्त्री रोग विशेषज्ञ

Dr. Jayant Yadav, MD  
MBBS, MD (Radiologist) Reg. No. 4166  
रेडियोलॉजिस्ट

Patients are echo free.  
No significant  
well maintained.  
No cholelithiasis or calculus is



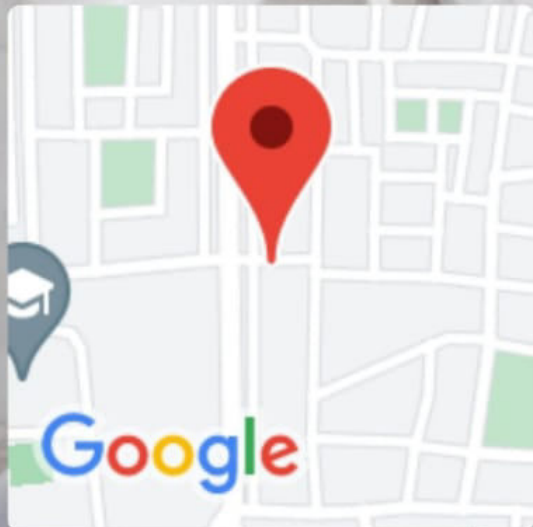


# Divya Diagnostic Centre

पेथोलॉजी | एक्स-रे | ई.सी.जी. | एको कार्डियो ग्राफी | सोनोग्राफी



GPS Map Camera



**Bhopal, Madhya Pradesh, India**

636, Champion School Rd, E-7, Arera Colony, Bhopal, Madhya Pradesh 462016, India

Lat 23.205917°

Long 77.431624°

09/07/22 10:57 AM