

905 / RASHMI KULKARNI / 41 Yrs / F / 0 Cms / 0 Kg Date: 10-Dec-2022 Refd By : BOB

Report :

TEST OBJECTIVE	: ROUTINE CHECK UP
RISK FACTOR	: FEMALE
ACTIVITY	: MODERATE ACTIVE
MEDICATION	: NONE
REASON FOR TERMINATION	: HEART RATE ACHIEVED
EXERCISE TOLERANCE	: GOOD
EXERCISE INDUCED ARRYTHMIAS	: NO
HAEMODYNAMIC RESPONSE	: NORMAL
CHRONOTROPIC RESPONSE	: NORMAL
FINAL IMPRESSION	: STRESS TEST IS NEGATIVE FOR EXERCVISE INDUCED ISCHAEMIC HEART DISEASE

Rashmi





डॉ. सविता क्लिनिक

34, भूतल, मोहिनी अदिति आर्केड, शाहपुरा मस्जिद के पास
भरत नगर रोड, ई-7/194, अरेरा कॉलोनी, भोपाल - 462038

Mob. : 8989649694, 9516333619

Clinic Registration : CL/5392/Jun/2017

PNDT Registration : MPPCPNDT/BPL/2017/206



Name : Mrs. Rashmi Kulkarni Age 41/F YRS./F
R/B Health check-up No. _____ Date 10/12/2022

WHOLE ABDOMEN ULTRASOUND REPORT

Indication :

Liver appears normal / ~~enlarged~~ in size and shape with smooth in outline. Normal / ~~increased~~ perenchymal echogenicity is noted. No E/O focal lesion / IHBR dilatation is seen. Hepatic veins and portal veins appear normal.

No E/O Subdiaphragmatic Collection.

Gall Bladder is physiologically well distended / ~~collapsed~~. No E/O echogenic foci in GB lumen. GB wall is normal / ~~thickened~~. No E/O pericholecystic collection. common duct reveals normal course and caliber.

Pancreas appear normal in size, shape and echo texture with smooth contour. No peripancreatic pathology seen. (Not seen due to gases)

Spleen is normal / ~~enlarged~~ in size and normal in echo texture.

IVC and aorta appear to be normal.

No evidence of lymphadenopathy is noted.

No evidence of free fluid is noted.

Right Kidney is normal in size, shape and position. Corticomedullary differentiation (CMD) is well maintained. Normal cortical thickness is noted. No E/O hydronephrosis or calculus is noted.

PTO

Dr. P. Savita, MD
MBBS, MD (O&G) Reg. No. 9971
स्त्री रोग विशेषज्ञ

Dr. Jayant Yadav, MD
MBBS, MD (Radiologist) Reg. No. 4166
रेडियोलॉजिस्ट

905 / RASHMI KULKARNI / 41 Yrs / F / 0 Cms / 0 Kg Date: 10-Dec-2022 Refd By : BOB

Stage	Time	Duration	Belt Speed (mph)	Elevation	METs	Rate	% THR Achieved	BP	RPP	PVC	Comments
Supine	00:15	0:01	00.0	00.0	01.0	80	45 %	118/70	094	00	
Standing	00:28	0:01	00.0	00.0	01.0	80	45 %	118/70	094	00	
HV	00:37	0:01	00.0	00.0	01.0	079	44 %	118/70	093	00	
Warm Up	00:52	0:01	01.0	00.0	01.0	082	46 %	118/70	096	00	
ExStart	00:58	0:06	01.7	10.0	01.1	082	46 %	118/70	096	00	
BRUCE Stage 1	03:58	3:00	01.7	10.0	04.7	118	66 %	128/78	151	00	
BRUCE Stage 2	06:58	3:00	02.5	12.0	07.1	142	79 %	134/82	190	00	
PeakEx	07:28	0:30	03.4	14.0	07.6	146	82 %	134/82	195	00	
Recovery	08:27	1:00	00.0	00.0	01.2	104	58 %	128/80	133	00	
Recovery	09:27	2:00	00.0	00.0	01.0	083	46 %	118/70	097	00	
Recovery	09:37	2:09	00.0	00.0	01.0	082	46 %	118/70	096	00	

Findings :

Exercise Time : 06:31
 Max HR Attained : 146 bpm 82% of Target 179
 Max BP Attained : (Sys) 134/82
 Max WorkLoad Attained : 7.6 Fair response to induced stress
 Test End Reasons : Heart Rate Acheived

Left Kidney is normal in size, shape and position. CMD is well maintained. Normal cortical thickness is noted. No E/O hydronephrosis or calculus is noted.

Urinary Bladder is well distended (physiological) / ~~collapsed~~. Its contents are echo free. No E/O bladder wall thickening is noted. Post-void residue is insignificant.

Prostate is normal in size, shape and echo texture with smooth outline. No E/O focal lesion is noted.

Uterus is ante / ~~retro~~ verted and normal in size, shape and echo texture with smooth outline. No E/O focal lesion is noted, endometrial echo appears normal. Cervical and vaginal shadows appear normal.

Right Ovary appears ~~Enlarged~~ / Normal in size, shape and echo texture.

Left Ovary appears ~~Enlarged~~ / Normal in size, shape and echo texture.

Impression : Normal study.

P. Sankh

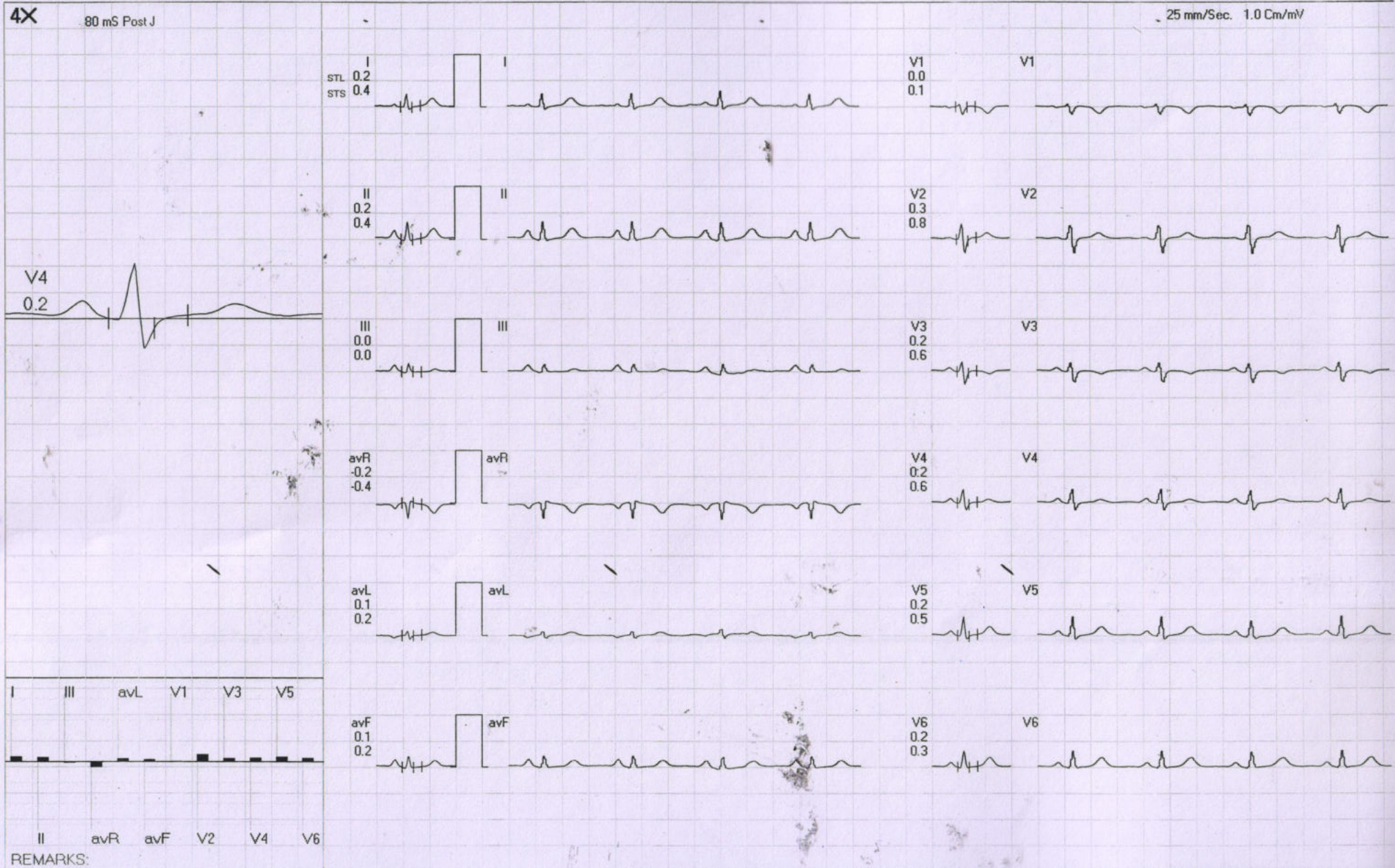Advised clinical Correlation.

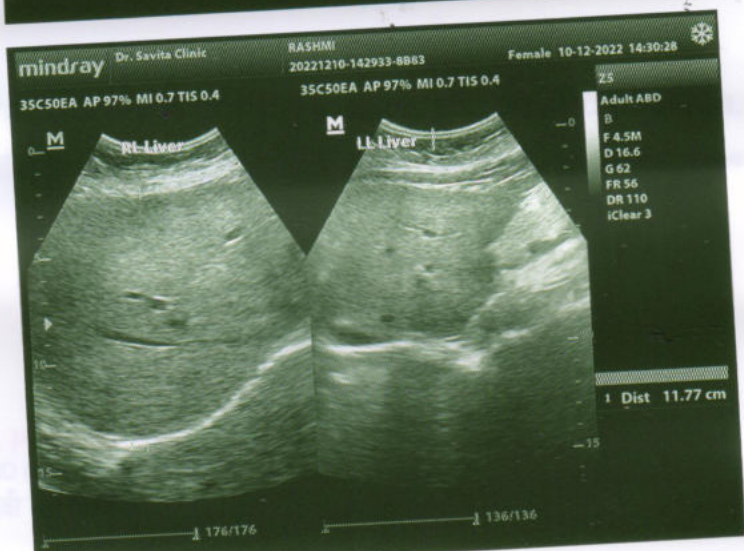
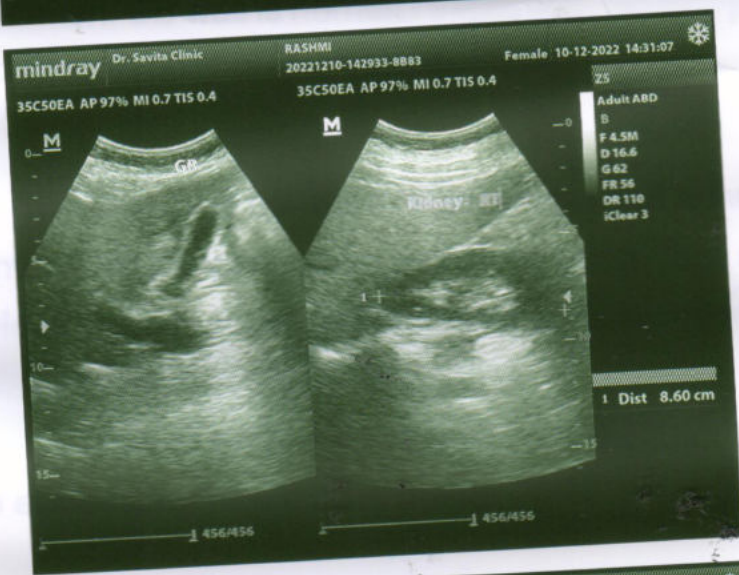
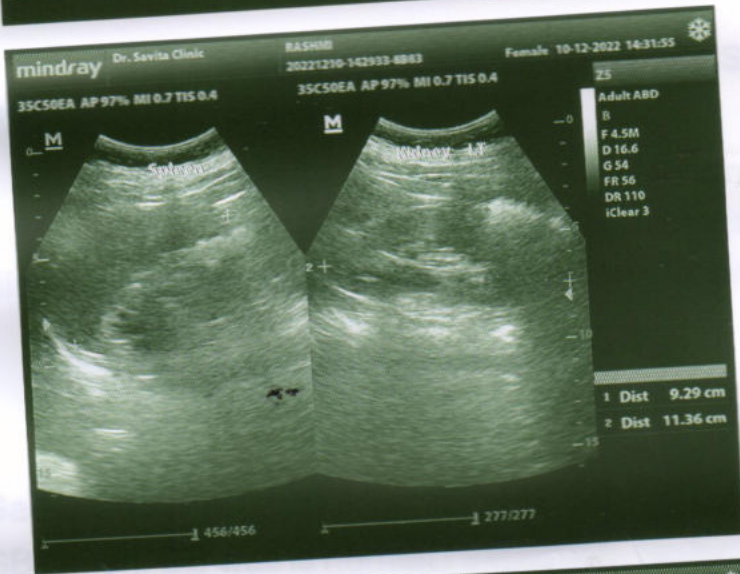
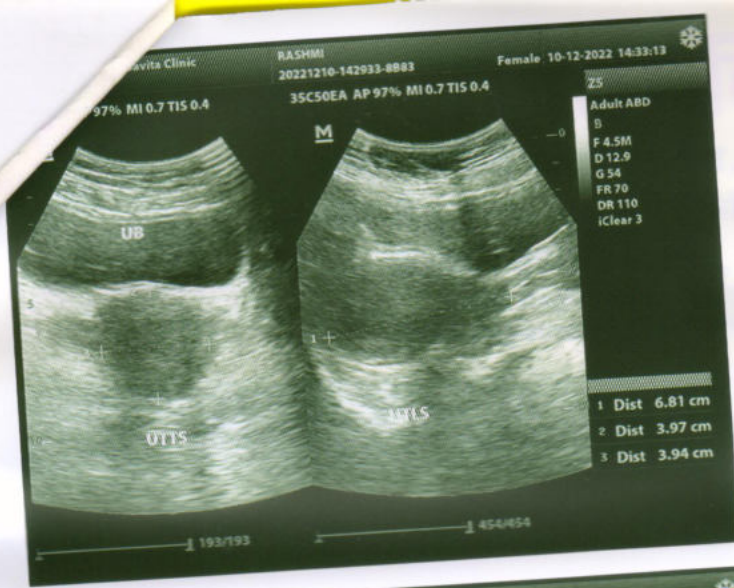


905/RASHMI KULKARNI / 41 Yrs / F

Date: 10-Dec-2022 02:26:24 PM METS: 1.0/ 80 bpm 44% of THR BP: 118/70 mmHg Raw ECG/BLC On/ Notch On/ HF 0.05 Hz/LF 20 Hz

ExTime: 00:14 0.0 mph, 0.0%





क्लीनिक

साहपुरा मस्जिद के पास
 रानी, भोपाल - 462038
 516333619
 2/ Jun/2017
 /BPL/2017/206



Age 41/F YRS./F
 Date 10/12/2022
 No. _____

ULTRASONOGRAPHY REPORT

shape with smooth in outline.
 noted. No E/O focal lesion / IHBR
 appear normal.

collapsed. No E/O echogenic foci in
 pericholecystic collection. common

texture with smooth
 (due to gases)
 cho texture.

corticomedullary defferentiation
 noted. No E/O hydronephrosis

PTO

Dr. Jayant Yadav, MD
 MBBS, MD (Radiologist) Reg. No. 4166
 रेडियोलॉजिस्ट

MBBS



905 / RASHMI KULKARNI / 41 Yrs / F

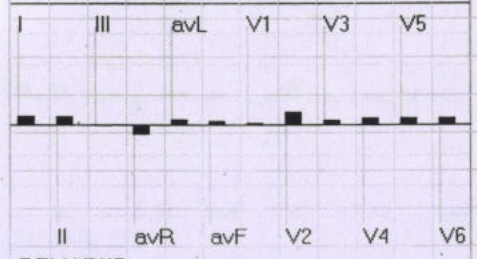
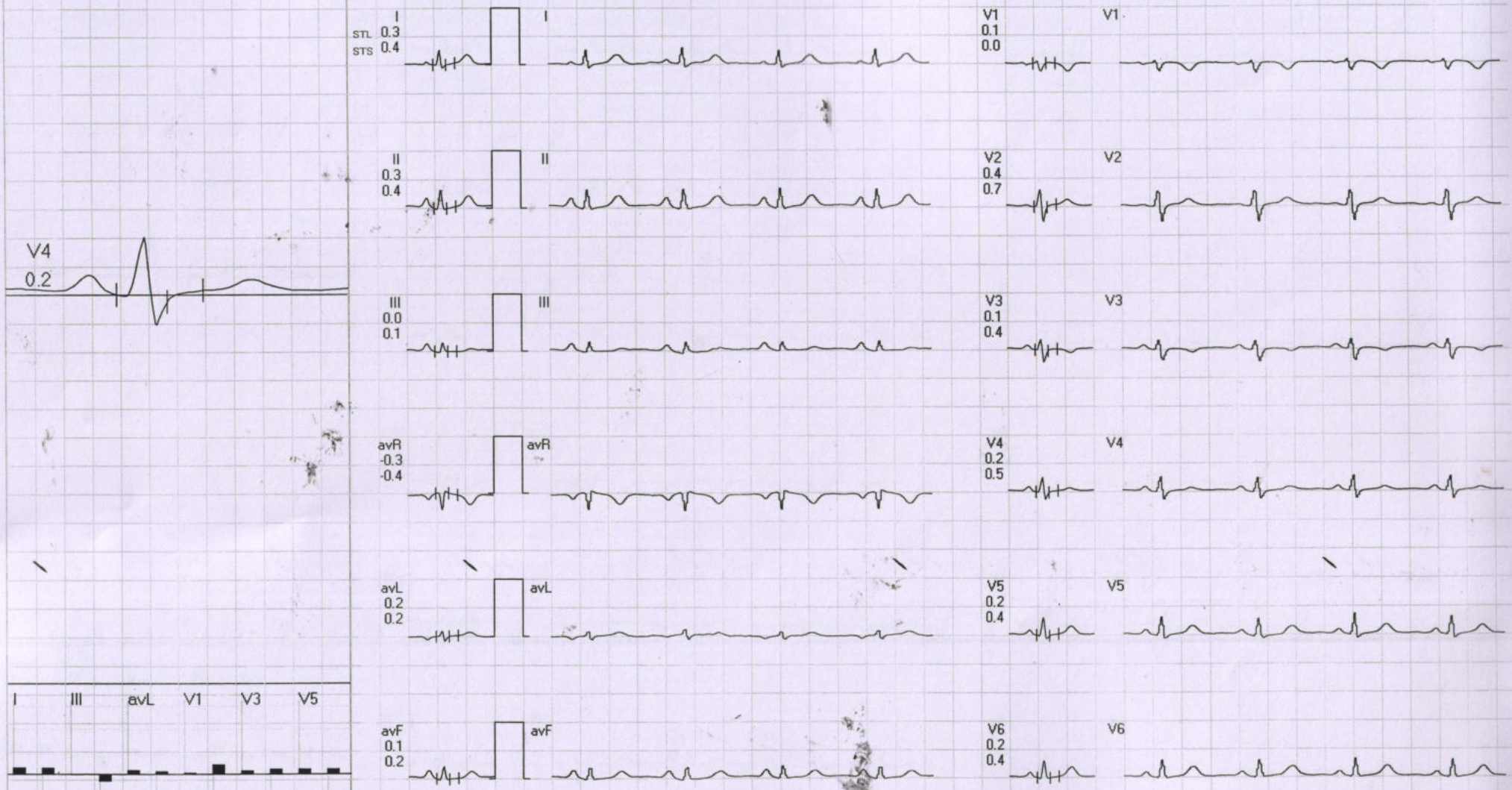
Date: 10-Dec-2022 02:26:24 PM METS: 1.0/ 80 bpm 44% of THR BP: 118/70 mmHg Raw ECG/BLC On/ Notch On/ HF 0.05 Hz/LF 20 Hz

ExTime: 00:27 0.0 mph, 0.0%

25 mm/Sec. 1.0 Cm/mV

4X

80 mS Post J



REMARKS:



दिवाकर डायग्नोस्टिक सेंटर

E-7/636, पंजाब नेशनल बैंक के पास, मैन रोड, अरेा कॉलोनी भोपाल (म.प्र.)

फोन: 0755-2465288, 0755-3520545 मो: 9826340190

Pt Name :- Mrs.Rashmi Kulkarni

Age :- 41/F

Lab. No. :- 02

Date :- 10/12/2022

EXAMINATION OF BLOOD

TEST	RESULT	NORMAL VALUE
Haemoglobin	13.3gms%	Female 12-16gms%, Male 14-18gms%
Red Cell count	4.82	4.5-5.6 million /cumm
Platelet Count	3.04	1.5-5.6 Lac/cumm
Leucocytes per.cu.mm	5800/cumm	5000-11000/cumm
Neutrophils	62%	50-70%
Lymphocytes	32%	20-40%
Eosinophils	03%	0-7%
Monocytes	03%	2-8%
PCV	39.7	37-47
MCV	82.5	76-96
MCH	27.5	27-32
MCHC	33.5	31-35
ESR	15	Male 0-9, Female 0-20mm/FHR
Blood Group	"O" Positive	By slide method
Total Serum Cholesterol	150.0	100-250 mg%
Serum Triglyceride	120.0	Up to 150 mg%
Serum Cholesterol HDL	46.0	Up to 65 mg%
Serum Cholesterol LDL	80.0	Up to 125 mg%
VLDL	24.0	Up to 30 mg%
S.Bilirubin(Total)	0.91	0.2-1.0mg/dl
Direct	0.50	0.0-0.25mg/dl
Indirect	0.41	
SGOT	20.0	5-35U/L
SGPT	23.0	8-40U/L
Alk Phosphatase	7.5	3-13 KA units
S. Protein(Total)	6.0	6.0-8.0mg%
Albumin	4.0	3.7-5.3mg%
Globulin	2.0	1.5 to 3.5 mg%
Blood Urea	20.9	Up to 40 mg%
S.Creatine	0.85	0.5-1.4mg/dl
S. Uric Acid	6.5	3.5-7.5mg%
GGTP	21.0	5-35 UL/dl
Fasting Blood Sugar	90.2	Up to 110 mg%
PP Blood Sugar	103.0	Up to 125 mg%
Glycosylated Hemoglobin HBA1c	5.0	Below - 6.0 % -Non Diabetic control 6-7 % -Excellent control Above- 8 % -Poor control
Thyrod Stimulating Hormone(TSH)	3.89	0.27-4.2

Pathologist

All test have technical limitation. Collaborative clinic pathological interpretation is mandatory. In case of disparity test may be repeated immediately. Typographical mistakes should be get correct instantly. This report is not valid for medico legal purpose



Dr. B. M. Agarwal
MBBS, DCP
Consultant Pathologist

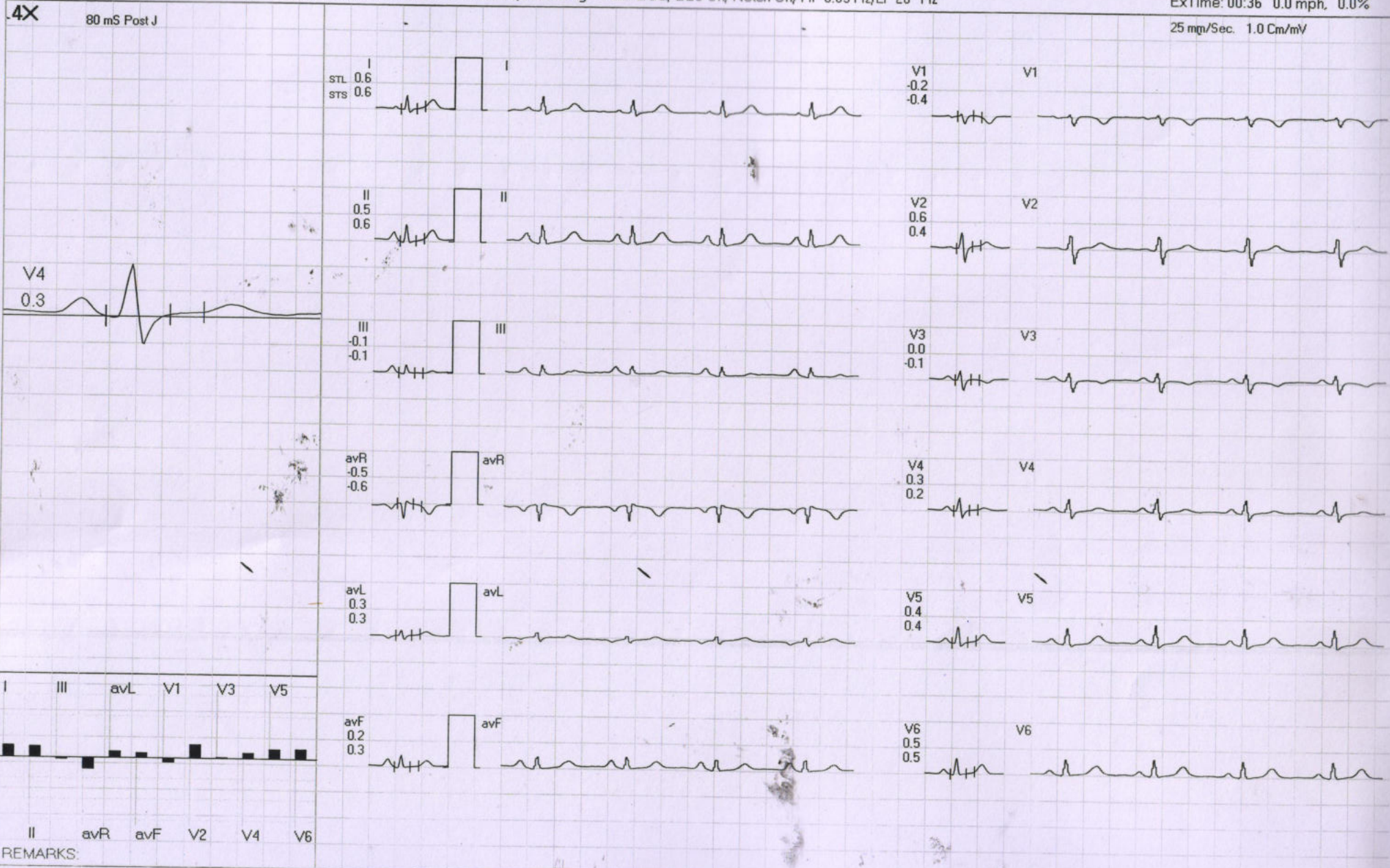M. Agarwal
MBBS, DCP
sultant Pathologist

905 / RASHMI KULKARNI / 41 Yrs / F

Date: 10-Dec-2022 02:26:24 PM METS: 1.0/ 79 bpm 44% of THR BP: 118/70 mmHg Raw ECG/ BLC On/ Notch On/ HF 0.05 Hz/LF 20 Hz

ExTime: 00:36 0.0 mph, 0.0%

25 mp/Sec. 1.0 Cm/mV





दिवाकर डायग्नोस्टिक सेंटर


E-7/636, पंजाब नेशनल बैंक के पास, मैन रोड, अरेरा कॉलोनी भोपाल (म.प्र.)

फोन: 0755-2465288, 0755-3520545 मो: 9826340190

Pt Name :- Mrs. Rashmi Kulkarni
Age :- 41/F
Lab. No. :- 02
Date :- 10/12/2022

URINE ANALYSIS

<u>A. PHYSICAL EXAMINATION</u>	
1. Colour	Pale Yellow
2. Appearance	Clear
3. Specific Gravity	Q.N.S.
<u>B. CHEMICAL EXAMINATION</u>	
1. Reaction	Acidic
2. Albumin	Nil
3. Sugar	Nil
4. Bile Salts	Absent
<u>C. MICROSCOPIE EXAMINATION</u>	
Pus Cells	1-2/HPF
R.B.C.	Nil
Epithelial Cell	2-3/HPF
Cast	Nil
Crystals (Cal. Oxa)	Nil
Bacteria	Nil
Amorphous	Nil
T. Vaginitis	Nil


Dr. B. M. Agarwal
MBBS, DCP
Consultant Pathologist

Pathologist



905 / RASHMI KULKARNI / 41 Yrs / F

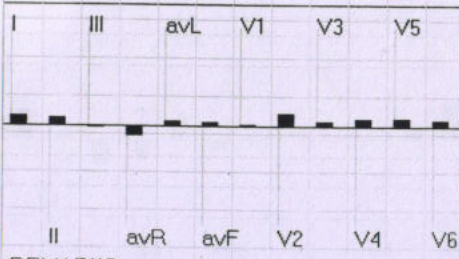
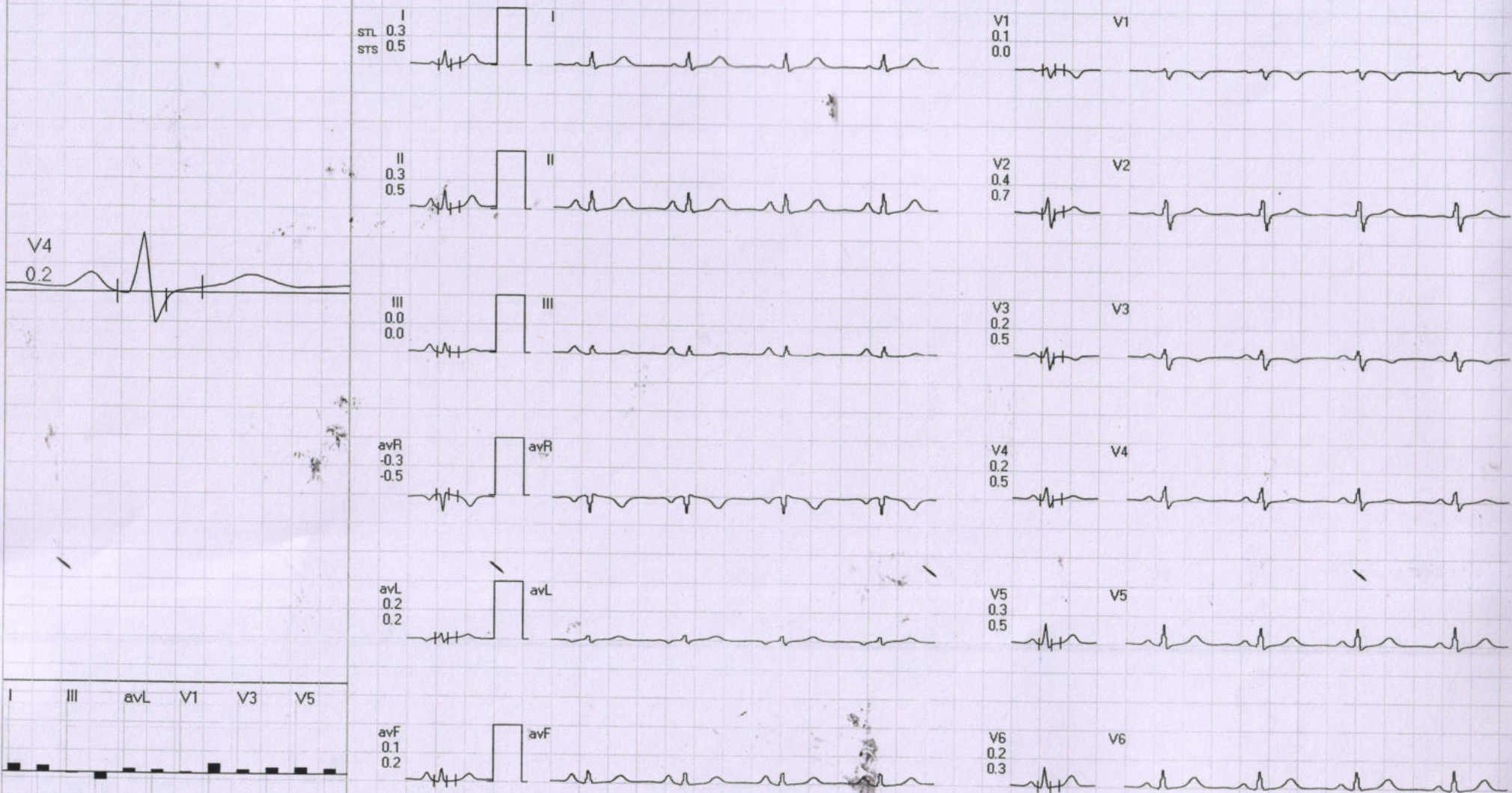Date: 10-Dec-2022 02:26:24 PM METS: 1.0/ 77 bpm 43% of THR BP: 118/70 mmHg Raw ECG/ BLC On/ Notch On/ HF 0.05 Hz/LF 20 Hz

ExTime: 00:51 1.0 mph, 0.0%

4X

80 mS Post J

25 mm/Sec. 1.0 Cm/mV

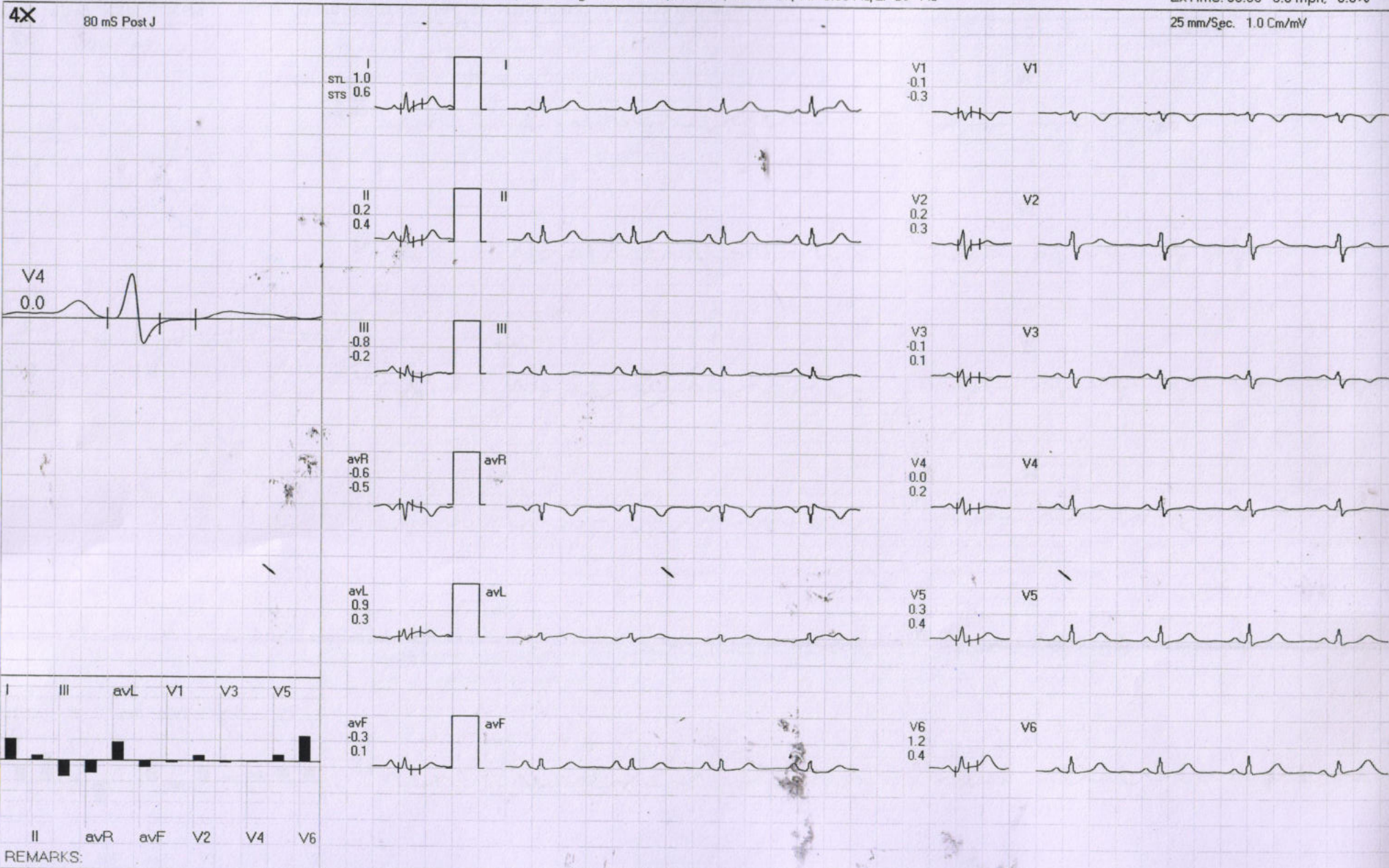


REMARKS:

905 / RASHMI KULKARNI / 41 Yrs / F

Date: 10-Dec-2022 02:26:24 PM METS: 1.0/ 82 bpm 45% of THR BP: 118/70 mmHg Raw ECG/ BLC On/ Notch On/ HF 0.05 Hz/LF 20 Hz

ExTime: 00:00 0.0 mph, 0.0%





905 / RASHMI KULKARNI / 41 Yrs / F

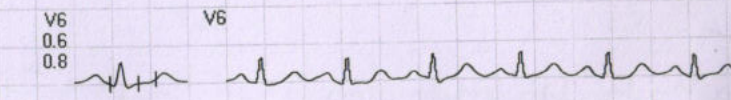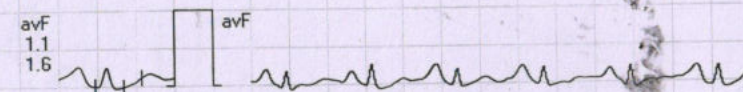

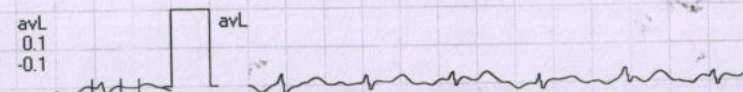
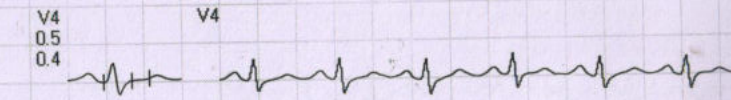
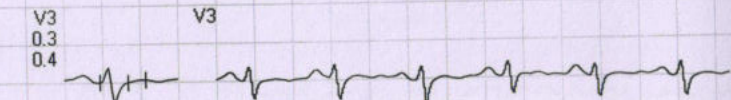

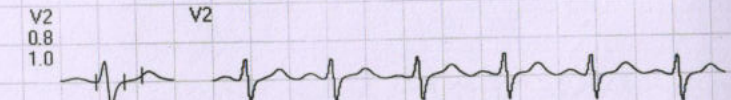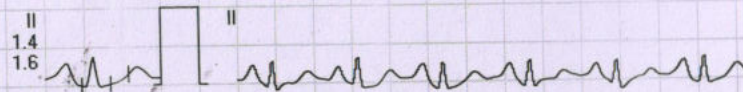

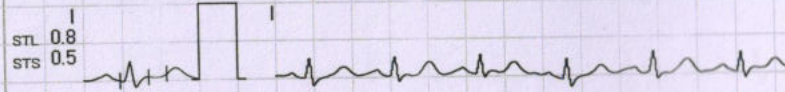
Date: 10-Dec-2022 02:26:24 PM METS: 4.7/118 bpm 65% of THR BP: 128/78 mmHg Raw ECG/BLC On/ Notch On/ HF 0.05 Hz/LF 20 Hz

ExTime: 03:00 1.7 mph, 10.0%

25 mm/Sec. 1.0 Cm/mV

4X

80 mS Post J



REMARKS:

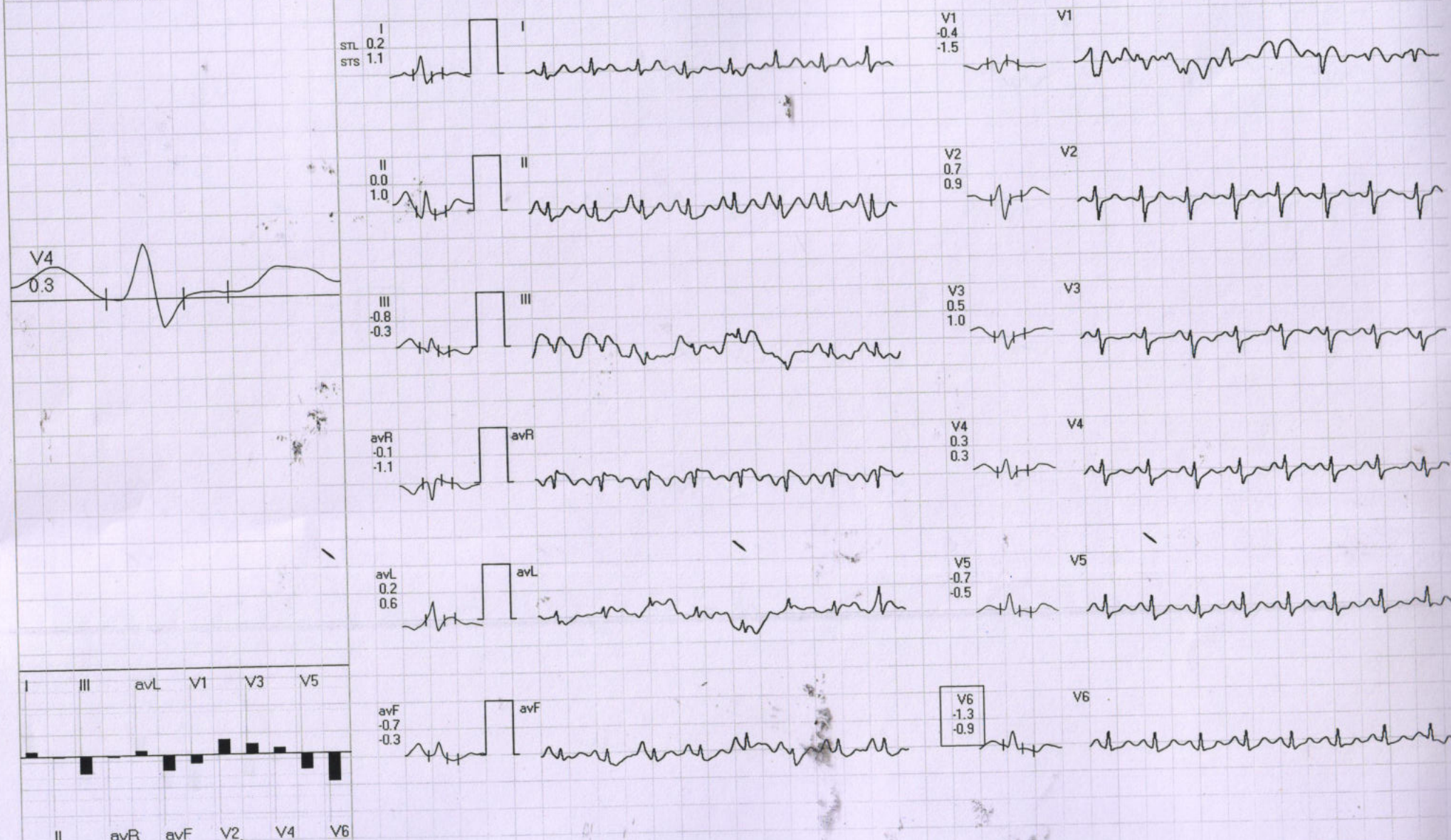

905 / RASHMI KULKARNI / 41 Yrs / F

Date: 10-Dec-2022 02:26:24 PM METS: 7.1/142 bpm 79% of THR BP: 134/82 mmHg Raw ECG/ BLC On/ Notch On/ HF 0.05 Hz/LF 20 Hz

ExTime: 06:00 2.5 mph, 12.0%
25 mm/Sec. 1.0 Cm/mV

4X - 60 mS Post J



REMARKS:

905 / RASHMI KULKARNI / 41 Yrs / F

Date: 10-Dec-2022 02:26:24 PM

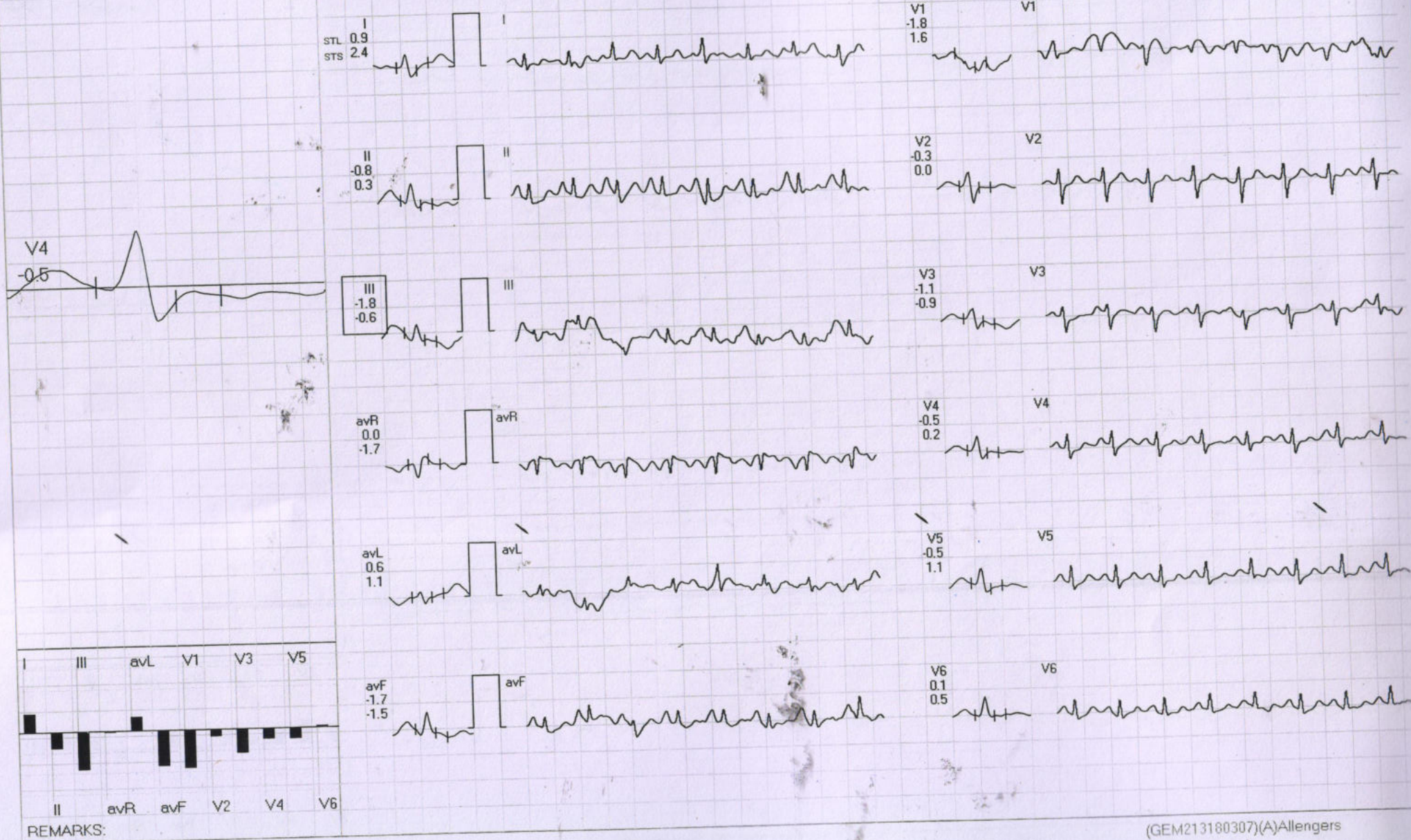
METS: 7.6 / 146 bpm 81% of THR BP: 134/82 mmHg Raw ECG/ BLC On/ Notch On/ HF 0.05 Hz/LF 20 Hz

ExTime: 06:30 3.4 mph 14.0%

25 mm/Sec. 1.0 Cm/mV

4X

60 mS Post J





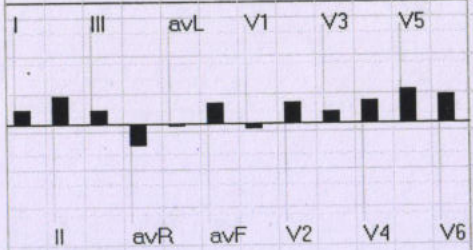
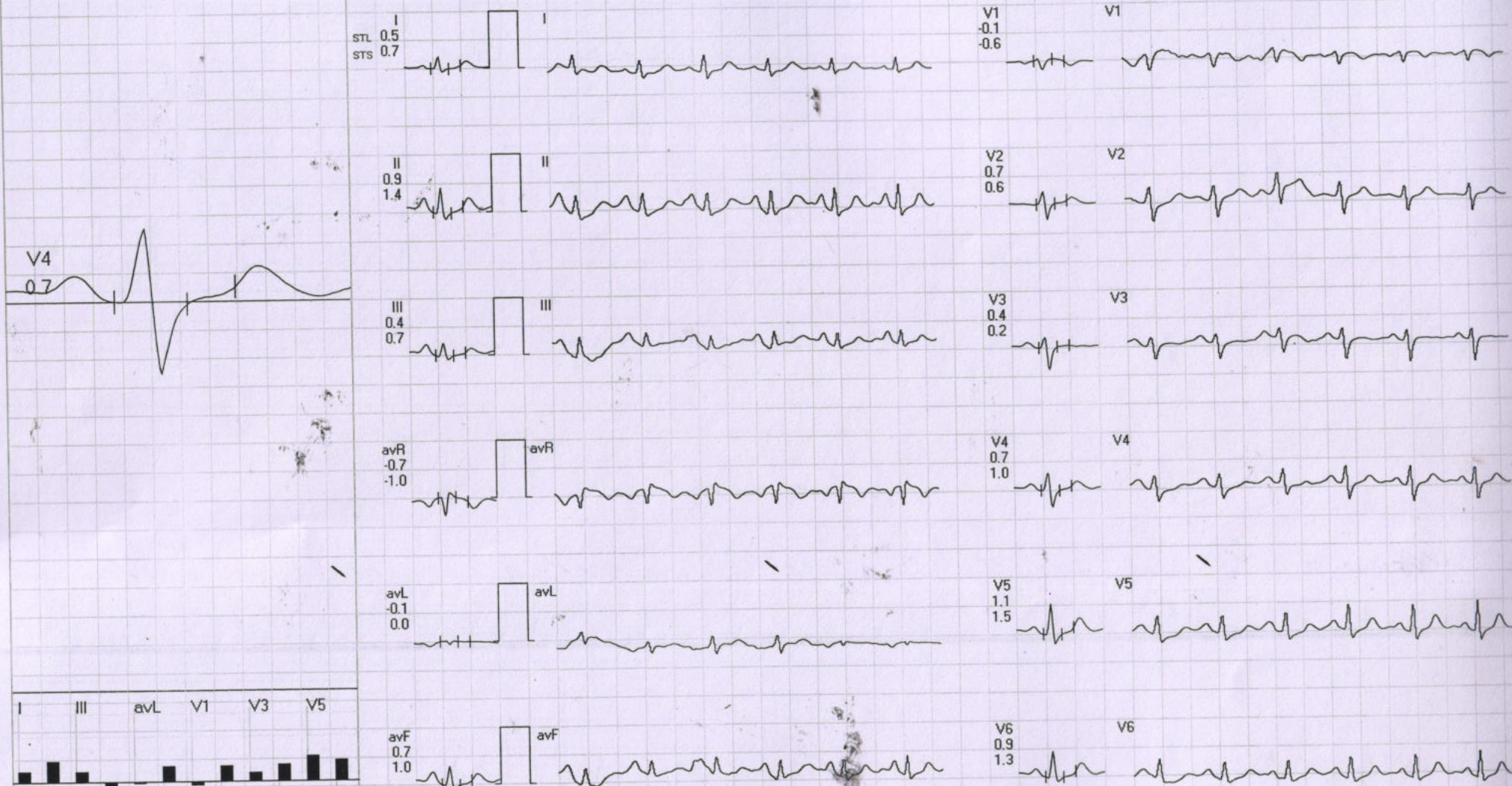
905 / RASHMI KULKARNI / 41 Yrs / F

Date: 10-Dec-2022 02:26:24 PM METS: 1.1/104 bpm 58% of THR BP: 120/80 mmHg Raw ECG/BLC On/Notch On/HF 0.05 Hz/LF 20 Hz

ExTime: 06:30 0.0 mph, 0.0%

25 mm/Sec. 1.0 Cm/mV

4X - 80 mS Post J



REMARKS:



905 / RASHMI KULKARNI / 41 Yrs / F

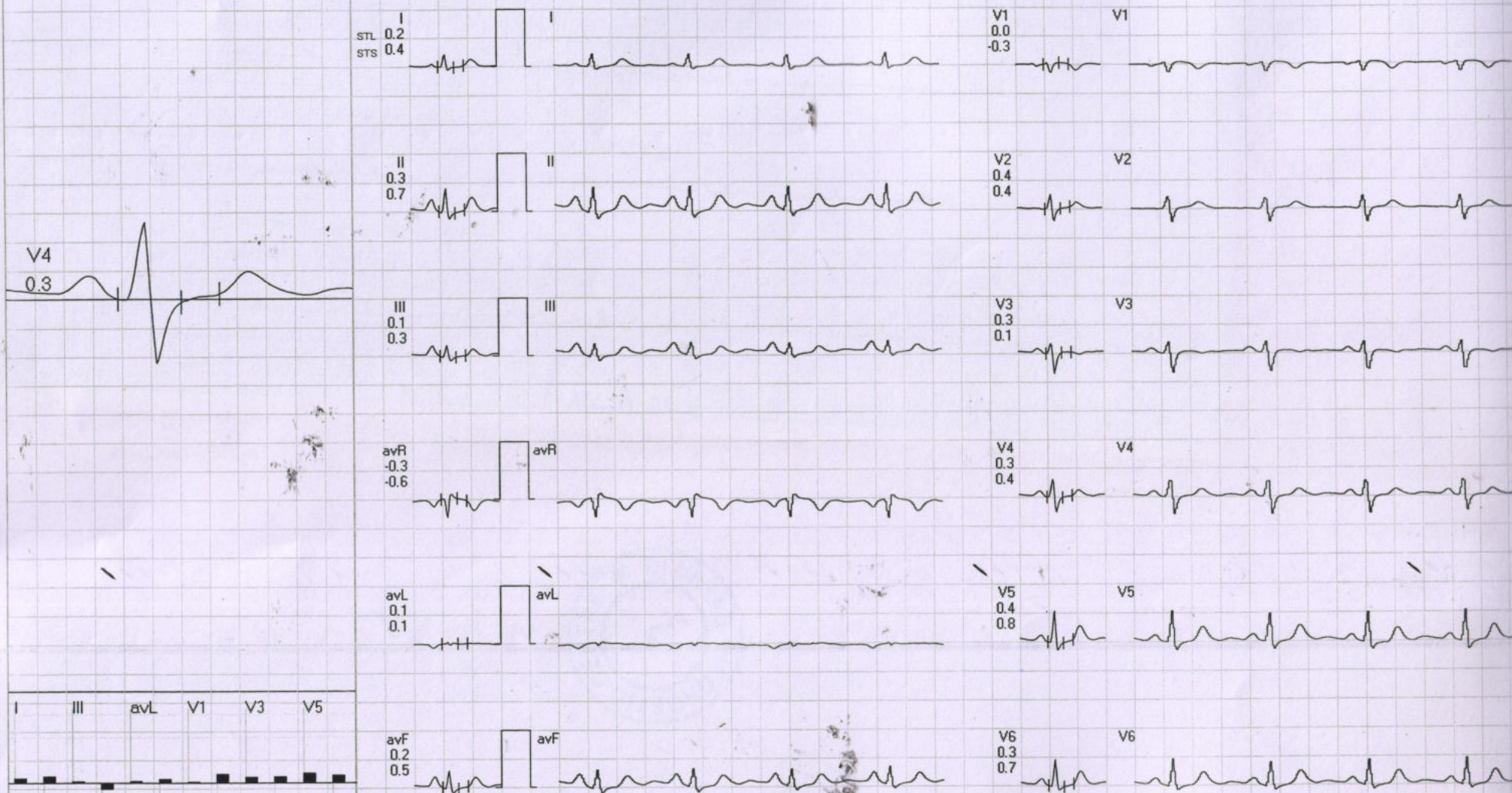
Date: 10-Dec-2022 02:26:24 PM METS: 1.0/ 83 bpm 46% of THR BP: 118/70 mmHg Raw ECG/ BLC On/ Notch On/ HF 0.05 Hz/LF 20 Hz

ExTime: 06:30 0.0 mph, 0.0%

25 mm/Sec. 1.0 Cm/mV

4X

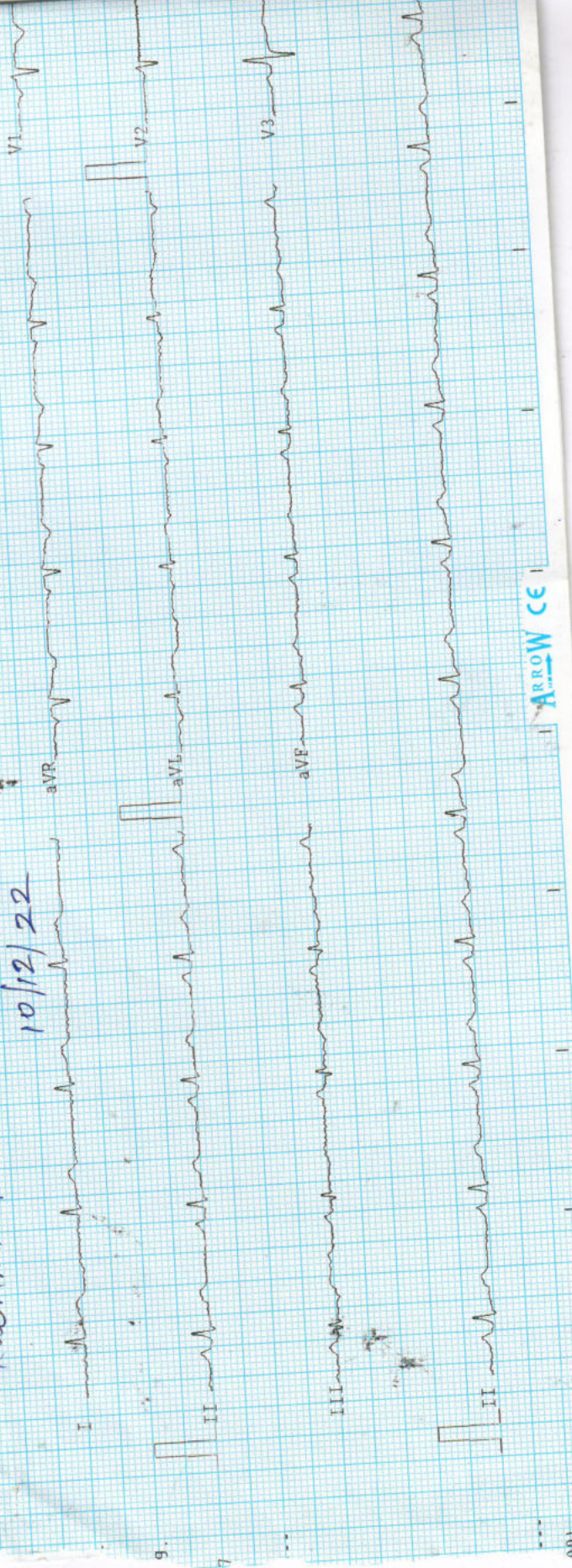
80 mS Post J



REMARKS:

Rashmi Kulkarni Age - 41/YF

10/12/22

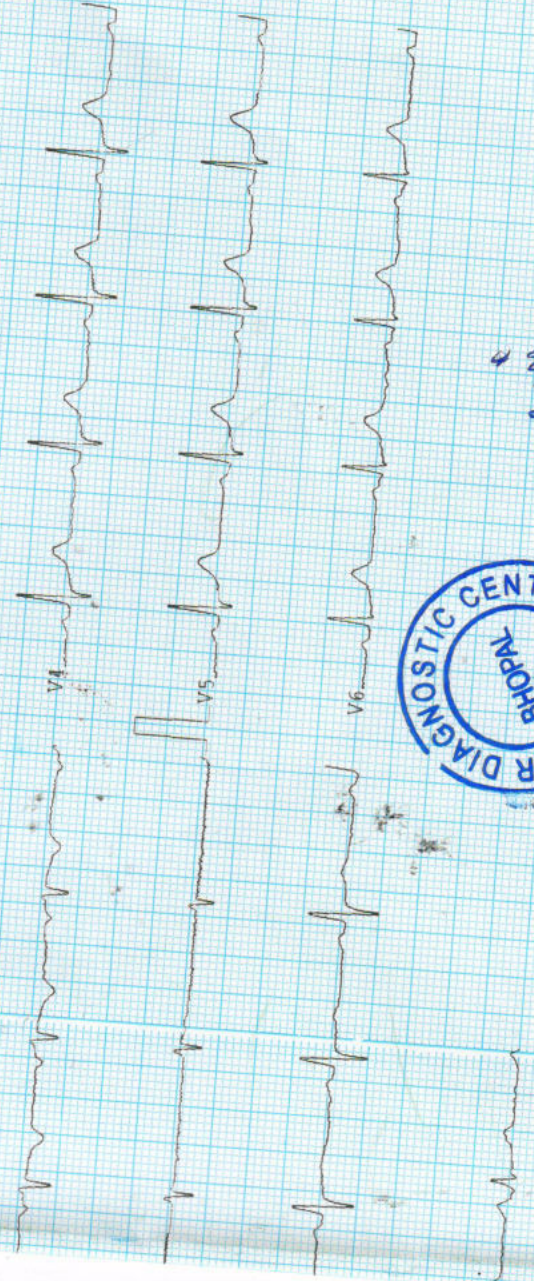


ARROW CE

09)

Observations :-

HR :- 73 bpm
R-R :- 812 ms
P-R :- 079 ms
QRS :- 63 ms
QT/QTc :- 330/366 ms
P Axis :- 76 °
R Axis :- 72 °
T Axis :- 72 °



Remarks :-



Pathan

Unconfirmed Report