



YASHFEEN

Kaivan Shah

CH22043570

28/01/2023

KETANKUMAR PARESHB

32/M

Jalalpore, Navsari

8980276265

HOSPITAL

Chief Complaint :



Refractive Check

Medical History : DM / HT / Asthama / Allergy / Heart / Thyroid /

No any, because of work

Ocular History :

Visual Acuity :

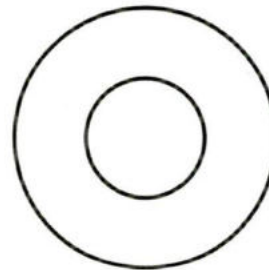
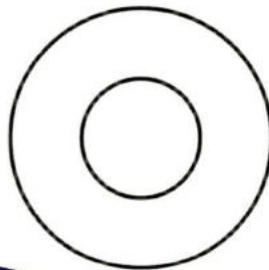
*6/9 R
6/9 L*

TOP :

<i>Next Visit Refractive</i>	RIGHT EYE (PH.....)				LEFT EYE (PH.....)			
	Sph.	Cyl.	Axis	V/A	Sph.	Cyl.	Axis	V/A
Distance								
Near								

Distance/Reading/Bi-Focal/Progressive/Separate Glasses

Sle :



*Next Visit
Refractive*



Handwritten signature/initials

Handwritten mark



YASHFEEN CARDIAC HOSPITAL™

MANAGED BY :- YASHFEEN FOUNDATION

VIRAVAL, NAVSARI. 396 445. PHONE : (H) (02637) 235725

Website : www.yashfeenhospital.in E-mail : info@yashfeenhospital.in



(Regd. No. E / 1390 / Navsari)

2D ECHO CARDIOGRAPHY COLOUR DOPPLER REPORT

Patient Name & No	: KETANKUMAR PARESHBHAI GANDHI CH22043	Age/Sex	UHID :	: 6719
Doctor	: Mohil Nagad	32/ M	No :	: 6912
Referred By	:		Date :	: 28/01/2023

M-Mode findings

LVIDd : 40mm
 LVIDs : 28mm
 IVSd : 10mm
 PWd : 10mm
 EF : 60%
 Aorta : 20mm
 LA : 28mm

2D Imaging

Aortic Valve : Trileaflet, Normal
 Mitral Valve : Thin, Pliable, Normal Mobility, Trivial MR
 Tricuspid Valve : Trivial TR, RVSP: 20+ RAP
 Pulmonary Valve : Normal

=> : All cardiac chambers are normal sized.
 => : All cardiac valves are normal.
 => : No regional wall motion abnormality.
 => : Normal LV systolic function.
 => : Normal LV diastolic function.
 => : IAS/IVS intact.
 => : No obvious clots/ vegetations/ or effusion.
 => : IVC Normal size.

Doppler Findings

=> : No MS/Trivial MR, No TS/Trivial TR, No AS/AR & No PS/PR
 Mitral inflow Pattern : E > A
 Tissue Doppler Findings : E' > A'

Impression : Normal LVEF:60%, No RWMA.



Report Prepared By

DR. MOHIL NAGAD
 M.D. Medicine, D.M. Cardiology
 Senior Consultant - Interventional Cardiology
 Non-Invasive Cardiologist
 YASHFEEN HOSPITAL, NAVSARI

Designed By : Sarita Infotech Pvt. Ltd., Navsari

YASHFEEN IMAGING & RADIOLOGY DEPARTMENT

MANAGED BY :- YASHFEEN FOUNDATION

VIRAVAL, NAVSARI. 396 445. PHONE : (H) (02637) 235725

Website : www.yashfeenhospital.in E-mail : info@yashfeenhospital.in

Name	KETANKUMAR PARESHBHAJI GANDHI	Age	32Y/M
Ref by Dr	SELF	Date	28/01/2023

USG ABDOMEN (SCREENING)

Liver appears normal in size & shape with normal echopattern.
No e/o focal or diffuse lesion. IHBR appear normal.
PV and CBD appear normal.

Gall bladder appears distended & normal in shape & size. No e/o calculus or mass seen.
Walls appear normal.

Pancreas appears normal in size and echogenicity. No e/o focal or diffuse lesion.

Spleen appears normal in size and shows normal echopattern. No e/o focal lesion.

Both Kidneys appear normal in size and echopattern. CM Differentiation is preserved.
No e/o calculus or hydronephrosis on either side.
Perirenal spaces appear normal on either side.
Suprarenal regions appear normal on either side. No e/o mass lesion.

Bladder is physiologically distended. No e/o calculus or mass. Walls appear normal.

Prostate appears normal in size & normal echopattern.
No e/o calcification.

RIF region appears normal.

No e/o ascites.

IMPRESSION:

No significant abnormality detected.



Dr. DHARMESH DESAI
(M.D. Radiology)
Dr. Dharmesh Desai, G - 45284
YASHFEEN GROUP OF HOSPITAL

Please contact immediately for any typographical error.

This is only professional opinion, not a final diagnosis. Kindly correlate clinically. Not valid for medicolegal purpose.

YASHFEEN IMAGING & RADIOLOGY DEPARTMENT

MANAGED BY :- YASHFEEN FOUNDATION

VIRAVAL, NAVSARI. 396 445. PHONE : (H) (02637) 235725

Website : www.yashfeenhospital.in E-mail : info@yashfeenhospital.in

Patient's Name:	KETANKUMAR GANDHI	Age & Sex:	32Yrs/M
Ref. by Dr.	SELF	Date:	28-01-2023

X RAY CHEST (PA VIEW)

Both lung fields appear normal.

Both hila appear normal.

Both CP angles appear clear.

Cardiac size appears within normal limit.

Both domes of diaphragm appear normal.

Bony thoracic cage appears normal.

IMPRESSION:

- Normal X-ray chest (PA view).



Dr. DHARMESH DESAI
Dr. Dharmesh Desai (M.D. Radio) (M.D. Radio)
Reg. No. GMB 5284
YASHFEEN GROUP OF HOSPITAL

Please contact immediately for any typographical error.

This is only professional opinion, not a final diagnosis. Kindly correlate clinically. Not valid for medicolegal purpose.



YASHFEEN CARDIAC HOSPITAL™

At. & Po. Viraval, Navsari. 396 445. Phone (H) (02637) 235725

Website : www.yashfeenhospital.in E-mail : info@yashfeenhospital.in
(For Laboratory Reports Only)



Patient Name : KETANKUMAR PARESHBHAI GANDHI Age : 32 Years Sex : M
Ref By Dr. : - Area : Jalalpore Date : 28/01/2023
Sample Time : 28/01/2023 10:01 No : 11 Time : 12:36PM

BLOOD SUGAR TEST REPORT

Test	Findings	UOM	Normal Range
FASTING BLOOD SUGAR	95.6	mg/dL	70-110
FASTING URINE SUGAR	NIL	-	NIL
POSTPANDRIAL BLOOD SUGAR	83.0	mg/dL	70-140
POSTPANDRIAL URINE SUGAR	NIL	-	NIL



P. Chaudhari
Dr. PIYUSH B. CHAUDHARI
M.D. Medicine
Reg. No. G-21518

Remarks

Designed By : Sarita Infotech Pvt. Ltd., Navsari

Yashfeen Cardiac Hospital

signature

Thanks for Reference

Technician



YASHFEEN CARDIAC HOSPITAL™

At. & Po. Viraval, Navsari. 396 445. Phone (H) (02637) 235725

Website : www.yashfeenhospital.in E-mail : info@yashfeenhospital.in
(For Laboratory Reports Only)



Patient Name : KETANKUMAR PARESHBHAI GANDHI Age : 32 Years Sex : M
Ref By Dr. : - Area : Jalalpore Date : 28/01/2023
Sample Time : 28/01/2023 09:13 No : 11 Time : 12:15PM

HAEMOGRAM

Test	Findings	UOM	Normal Range
HAEMOGLOBIN	15.1	gm/dl	M-13.5-17.0 F-11.5-15.5
HAEMOGRAM			
RED BLOOD CELL	5.08	10 ⁶ /μL	3.76 - 5.70
TOTAL LEUCOCYTE COUNT	6700	cells/cumm	4,000-11,000
Differential Count			
Neutrophil	53	%	40-75
Lymphocytes	40	%	20-40
Eosinophil	3	%	1-6
Monocytes	4	%	2-10
Basophils	0	%	0-0
PLATELET COUNT	315000	lacs/cumm	1.5-5.5 Lacs
RBC INDICES			
P.C.V.	43.9	%	M-40-56% F-37-47%
M.C.V.	86.4	cu/microns	76-94
M.C.H.	29.7	pg	27-30
M.C.H.C.	34.4	-	30-35
=			
BLOOD GROUP	" O "	-	-
RH FACTOR	POSITIVE	-	-
E.S.R.(1 hour)	2	mm/hr.	M-5-10, F-5-20

Remarks

Designed By : Santa Infotech Pvt. Ltd., Navsari



P. Chaudh.
Dr. PIYUSH B. CHAUDHARI

M.D. Medicine
Reg. No. G-21518

Yashfeen Cardiac Hospital

Signature
signature

Technician

KETANKUMAR ,
ID:
DOB:
32 Years , ,
Male ,Unknown
Med.:
Location:
Referring Physician:
Notes:

26-01-2023 23:10:04

Vent. Rate: 71 BPM
PR int: 135 ms
QRS dur: 97 ms
QT/QTc: 356/378 ms
P-R-T axes: 52 61 12
Avg. RR: 843 ms
QTcB: 387 ms
QTcF: 376 ms

SINUS RHYTHM
NONSPECIFIC T-WAVE ABNORMALITY
BORDERLINE ECG

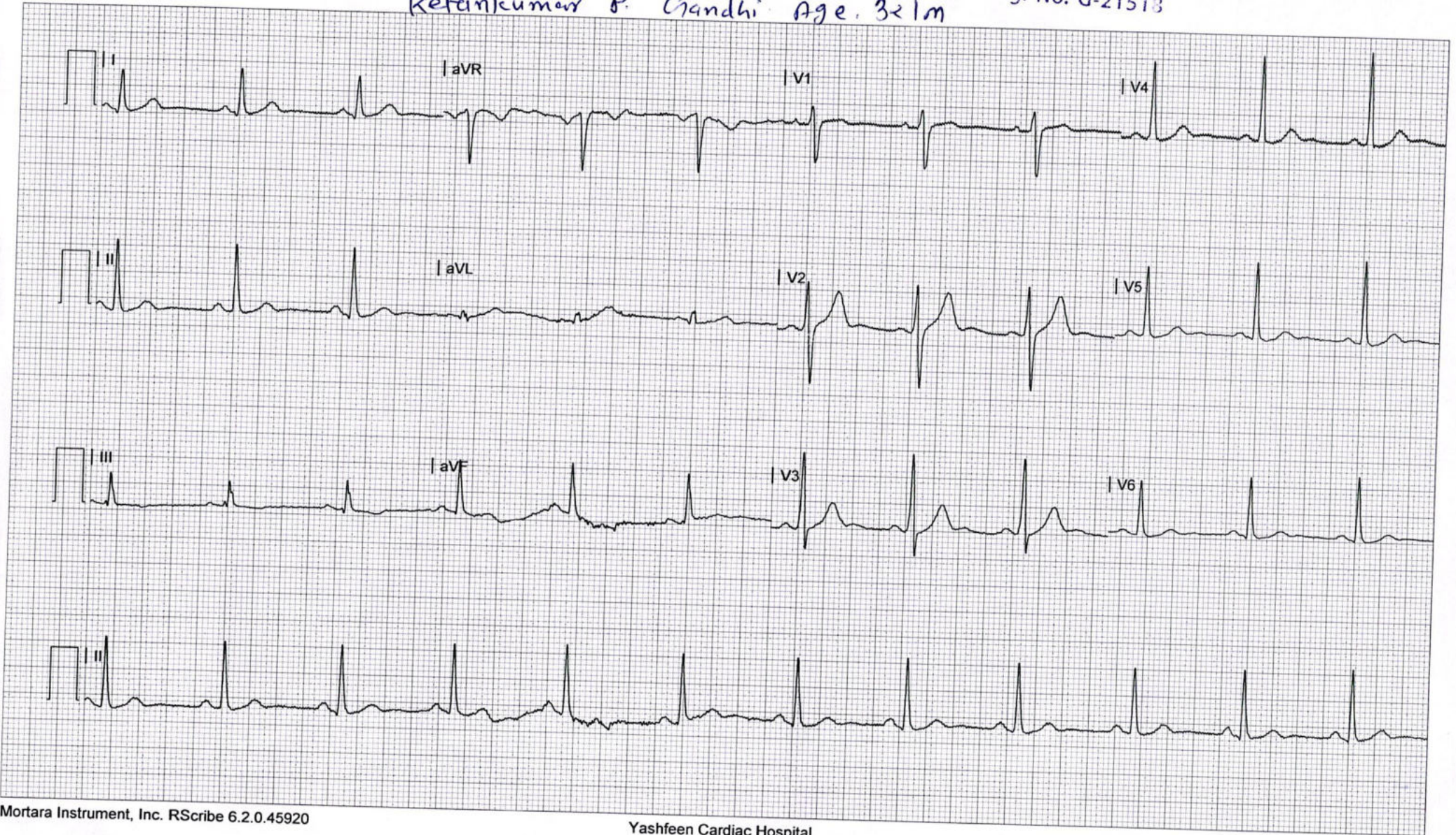
UNCONFIRMED REPORT
Reviewed by:

P. Chaudhari
Dr. PIYUSH B. CHAUDHARI
M.D. Medicine
Reg. No. G-21513

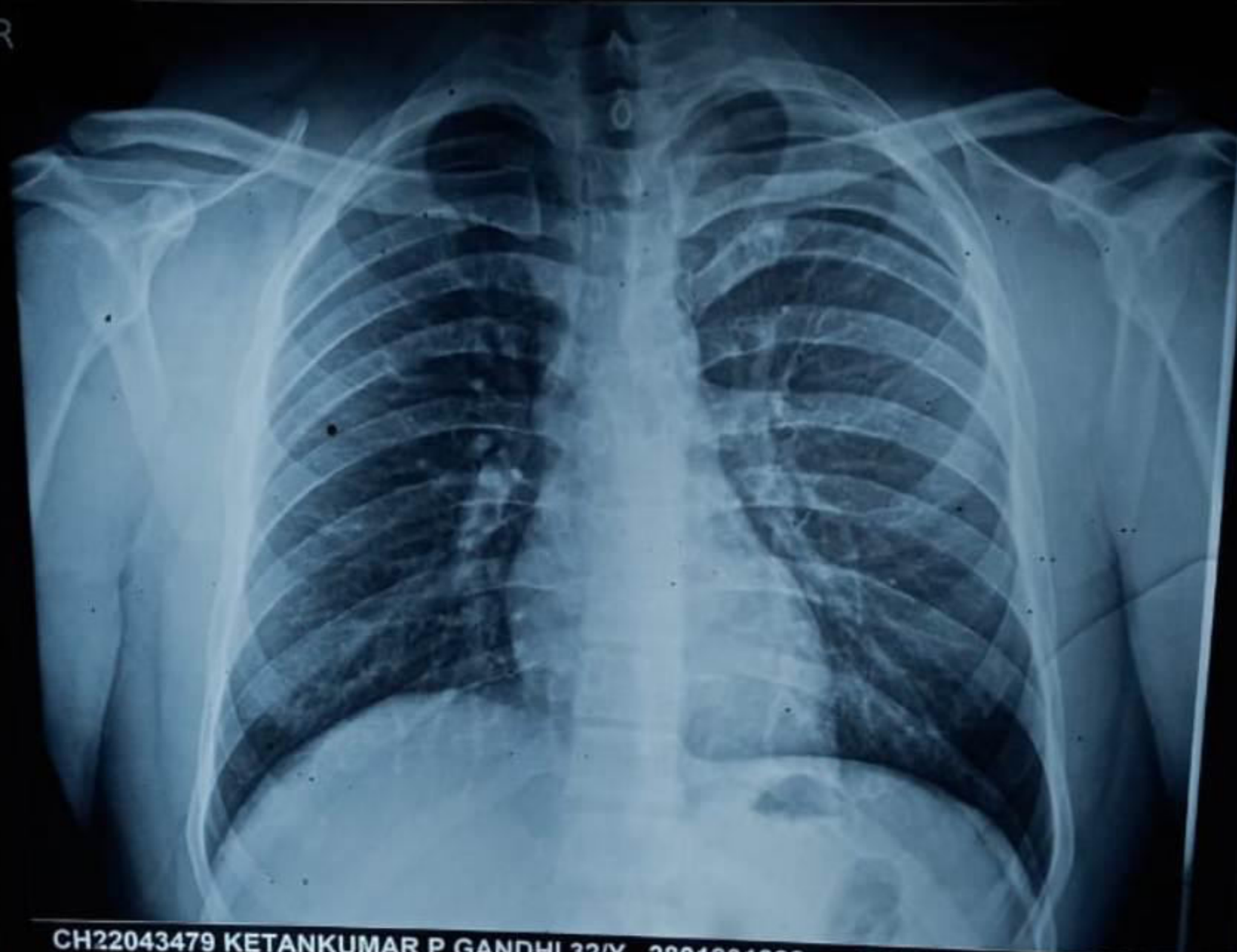Signed by:
Date:



Ketankumar P. Gandhi Age. 32m



R



CH22043479 KETANKUMAR P GANDHI 32/Y 2801231832 CHEST PA 28-01-2023
YASHFEEN GROUP OF HOSPITALS NAVSARI PH:9924047789