


भारत सरकार
Government of India

आधार

Issue Date: 14/08/2013



PINKI DEVI
DOB: 13/02/1994
Female

8311 0704 7350

मेरा आधार, मेरी पहचान

पिंकी

[Signature]
Dr. NITIN AGARWAL
MBBS, MD
Regn. No. DMC-R-1436

1947

help@uidai.gov.in

www.uidai.gov.in

8311 0704 7350


Print Date: 03/02/2021

Address: W/O Chandan Kumar Ray, 13, ps-
bithupur, ward no-02, sirsi manthi, Manthi,
Samastipur, Bihar, 848211

आधार

Unique Identification Authority of India

ONEPLUS ULTRASOUND LAB
47, Harsh Vihar, Pitam Pura,
Delhi-110034
Ph. 011-42480101, 9599913051
E-mail: oneplusul@gmail.com



पिकी

Dr. NITIN AGARWAL
MBBS, MD
Regn. No. DMC-R-1436

ONEPLUS ULTRASOUND LAB
47, Harsh Vihar, Pitam Pura,
Delhi-110034
Ph. 011-42480101, 9599913051
E-mail: oneplusul@gmail.com

To

The one plus ultrasound
mediawheel

Sir/madam,

I am not providing that sample
as I am unable to do so currently.

Yours truly,

निधि

Pinki Devi

Dr. NITIN AGARWAL
MBBS, MD
Regn. No. DMC-R-1436

ONEPLUS ULTRASOUND LAB
47, Harsh Vihar, Pitam Pura,
Delhi-110034
Ph. 011-42480101, 9599913051
E-mail: oneplusul@gmail.com



OnePLUS
Ultrasound Lab
— QUALITY FIRST... ALWAYS! —

Dr. Nitin Agarwal
Pathologist & Director
Ex. Sr. Res. MAMC
& Lok Nayak Hospital
Ex. Chief of Lab Dr. Lal Path Labs.

Dr. Pooja (Garg) Agarwal
Radiologist & Director
MAMC & Lok Nayak Hospital

Name	: Mrs. PINKI DEVI	Age/Sex	: 28 YRS/Female
Ref. By	: Dr. MEDIWHEEL	Lab No	: 012203120017
Date	: 12-Mar-2022	Patient ID	: LSHHI92436

X-ray-Chest PA view

Bony cage and soft tissues are normal.
Cardiothoracic ratio is normal.
Mediastinum is normal.
Both hila are normal.
Both costophrenic angles are clear.
Both domes of diaphragm are normal.
Lung fields are clear. No parenchymal lesion seen.

IMPRESSION: Normal Study.

DR. POOJA GARG
RADIOLOGIST
REG NO- DMC/R/03398

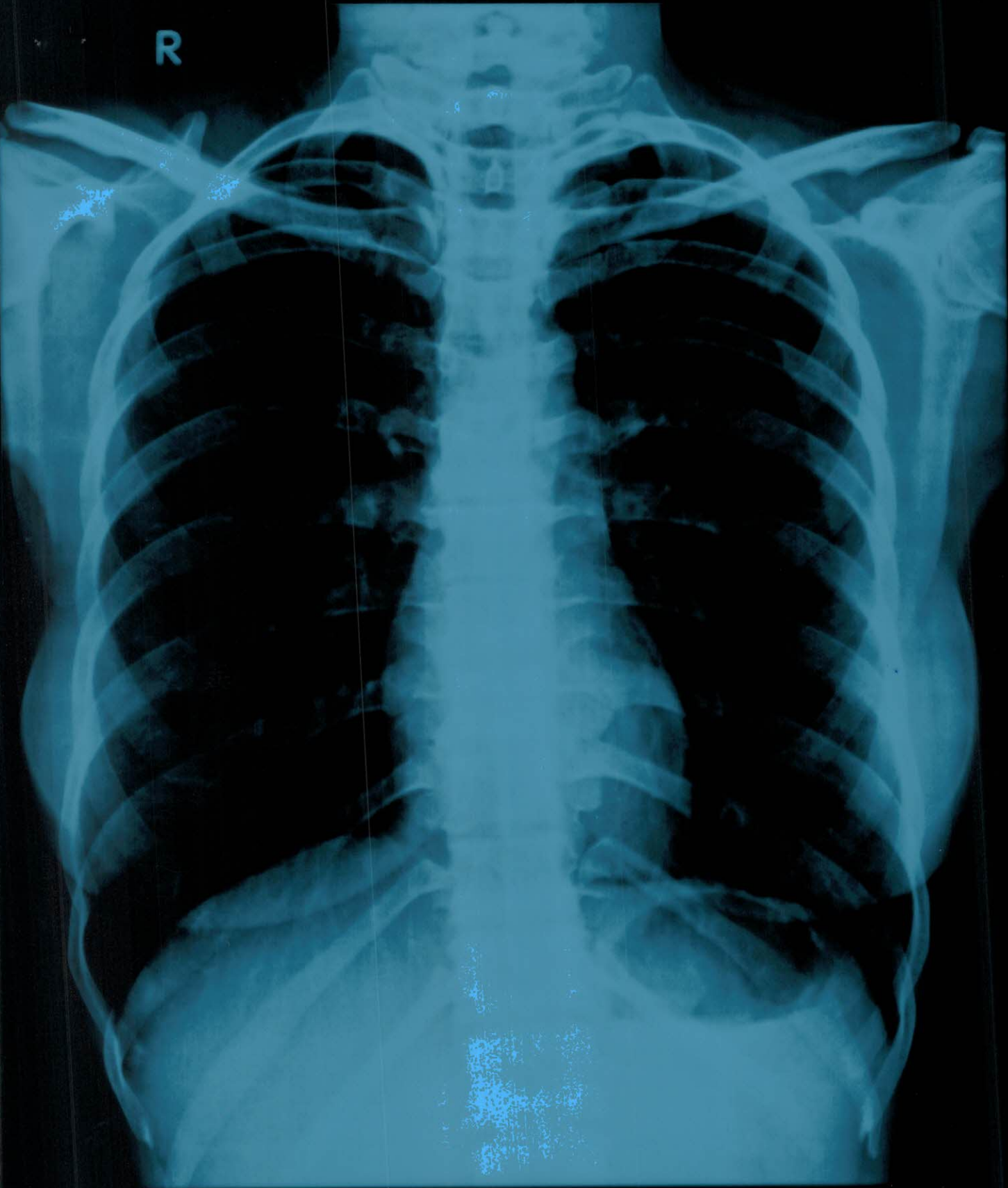
Dr. POOJA GARG
M.B.B.S., D.M.R.D
Reg No. DMC/R/03398
Radiologist

Type By : darshita

47, Harsh Vihar, Pitampura, New Delhi-110034 | Ph.: 011-42480101, 9599913051
E-mail: oneplusul@gmail.com | Web.: www.oneplusul.in

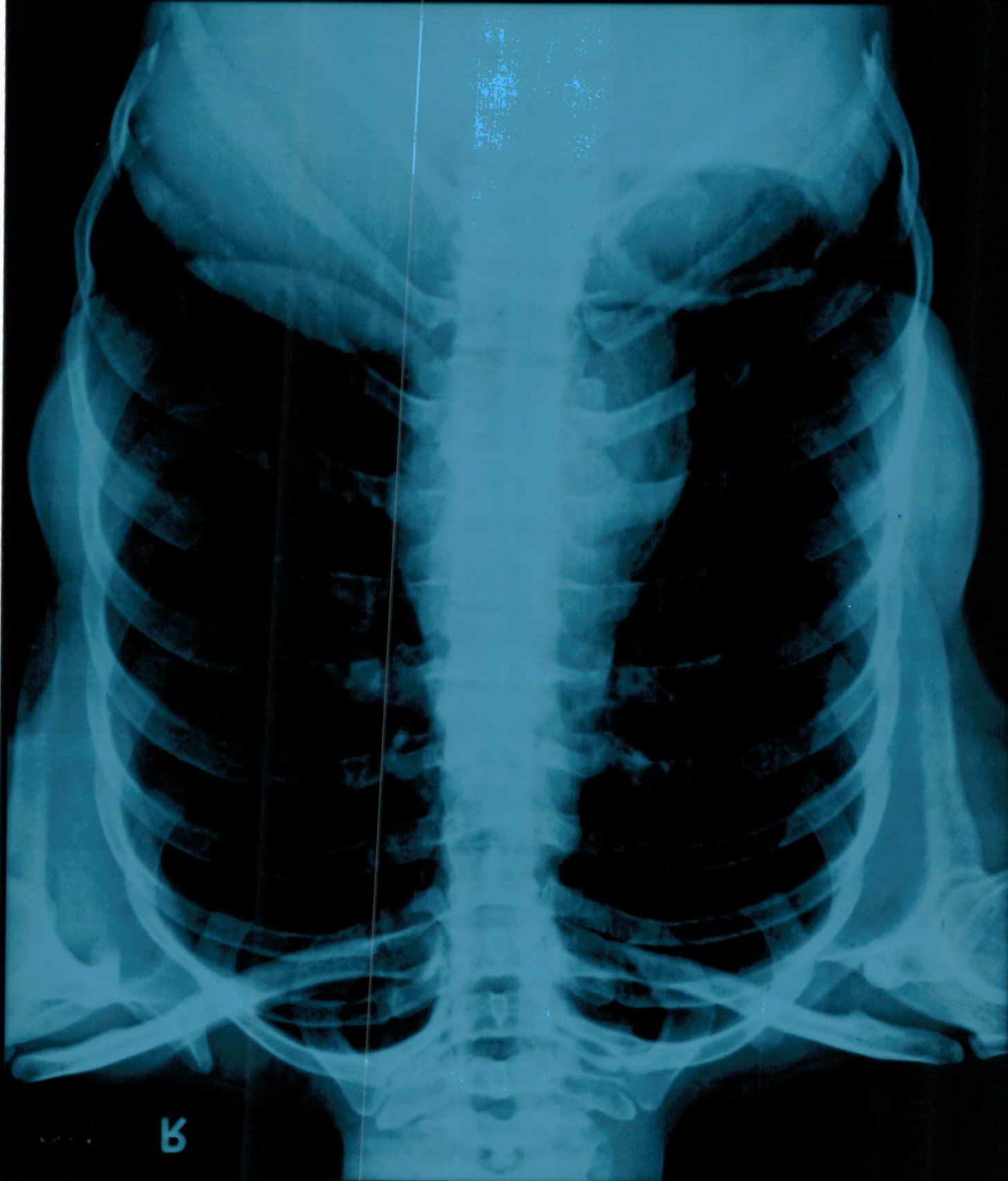
Clinical correlation is essential for final diagnosis. • If test results are unsatisfactory please contact personally or on phone. • This report is for perusal of doctors only.
• All disputes Subject to Delhi Jurisdiction only. • Not for medicolegal purposes. • All congenital anomalies in a foetus may not be diagnosed in routine obstetric ultrasound.

R



MRS.PINKI DEVI 28 YRS 12-03-2022 F CHEST PA VIEW
ONEPLUS ULTRASOUND LAB,47-HARSH VIHAR,PITAMPURA

ОИЕБГУС ПГТРАСОИИД ГЛВ.47-НАРЭН ЛННВР'ПТАМРУРА
МРЭ.ПИНКИ ДЕЛІ 58 УРС 15-03-5055 Е СРЕТ РА ЛІЕМ



В



OnePLUS
Ultrasound Lab

— QUALITY FIRST... ALWAYS! —

Dr. Nitin Agarwal

Pathologist & Director
Ex. Sr. Res. MAMC
& Lok Nayak Hospital
Ex. Chief of Lab Dr. Lal Path Labs.

Dr. Pooja (Garg) Agarwal

Radiologist & Director
MAMC & Lok Nayak Hospital

Name	: Mrs. PINKI DEVI	Age/Sex	: 28 YRS/Female
Ref. By	: Dr. MEDIWHEEL	Lab No	: 012203120017
Date	: 12-Mar-2022	Patient ID	: LSHHI92436

ULTRASOUND EXAMINATION----WHOLE ABDOMEN

Liver is normal in size and outline with normal echopattern. Intrahepatic biliary radicles are not dilated. No abscess or mass lesion seen. Hepatic veins, portal vein, IVC and aorta are normal. CBD is normal in caliber.

Gall bladder is well distended with anechoic lumen. Wall thickness is normal.

Both kidneys are normal in size, shape, position, outline and echopattern. Corticomedullary differentiation is maintained. No pelvicalyceal dilation or mass lesion is seen.

Spleen is normal in size and echotexture. No mass lesion seen.

Pancreas is normal in size, outline and echotexture.

Urinary bladder is normal in shape and position. No evidence of intravesical stone or mass seen.

Uterus is normal in size (measures 7.1 x 3.6 cm), shape, position and echopattern. No mass seen

Uterine cavity contains IUCD insitu. Endometrial thickness is 5.9 mm.

Both ovaries appear normal in size, shape and echopattern. No tubo-ovarian mass seen.

No abnormal bowel wall thickening seen in right iliac fossa.
No free fluid seen anywhere in abdomen.

IMPRESSION:

- Normal study.

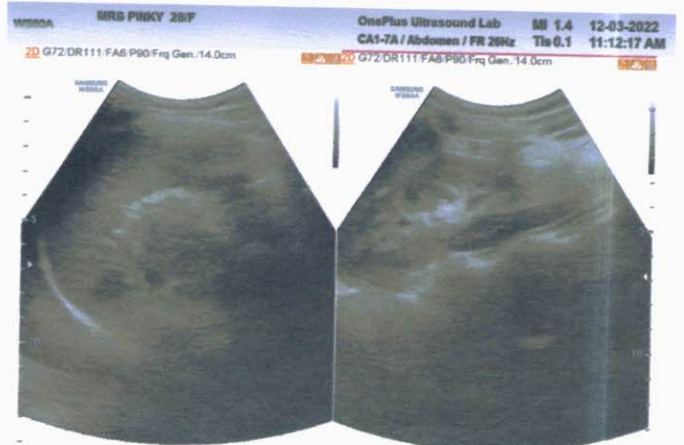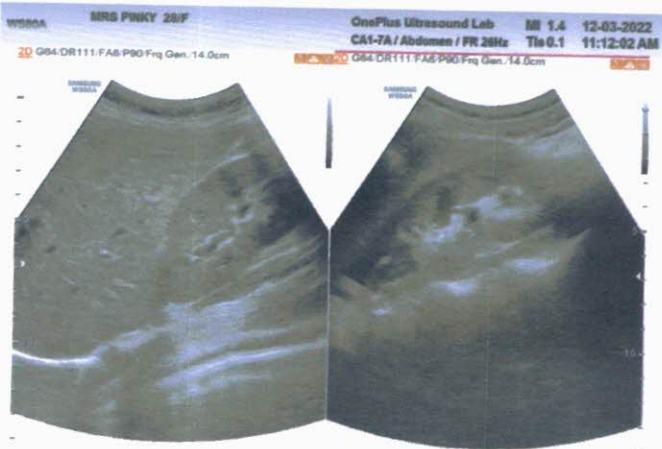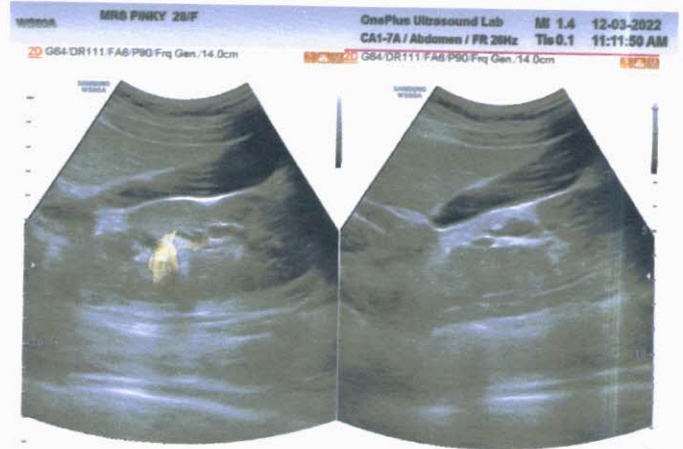
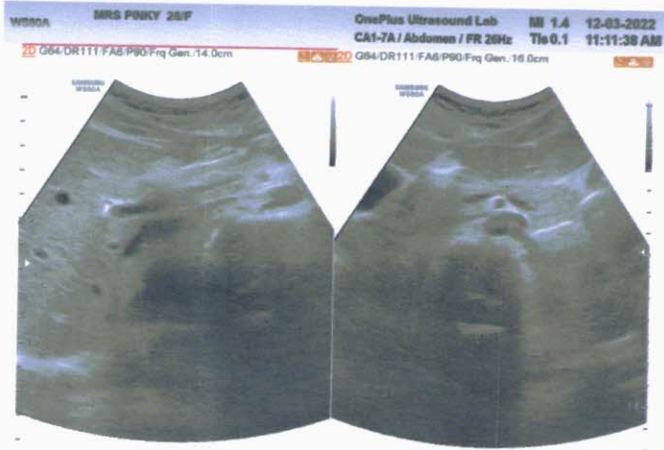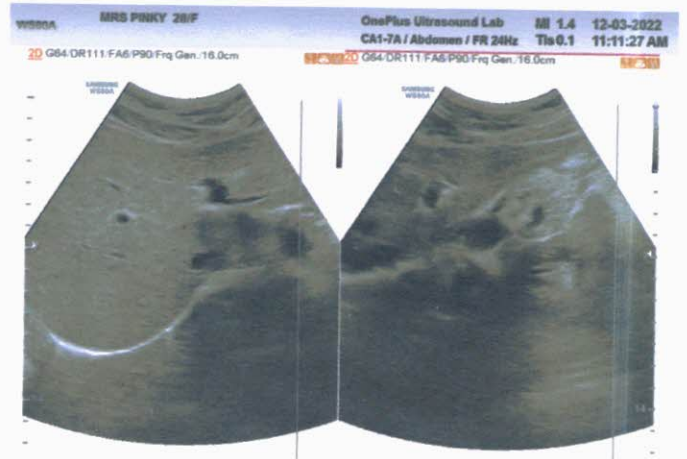
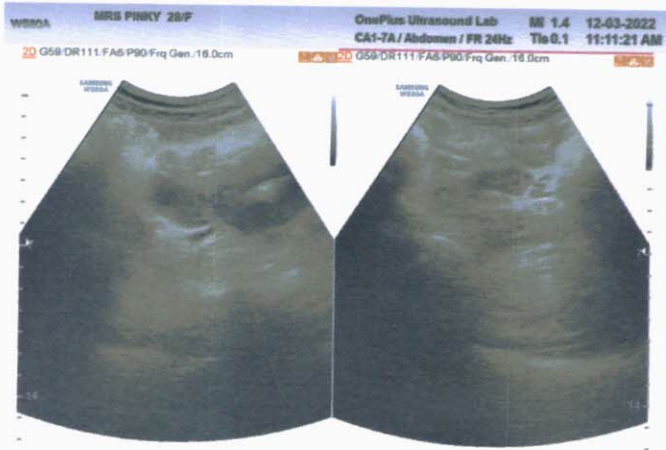
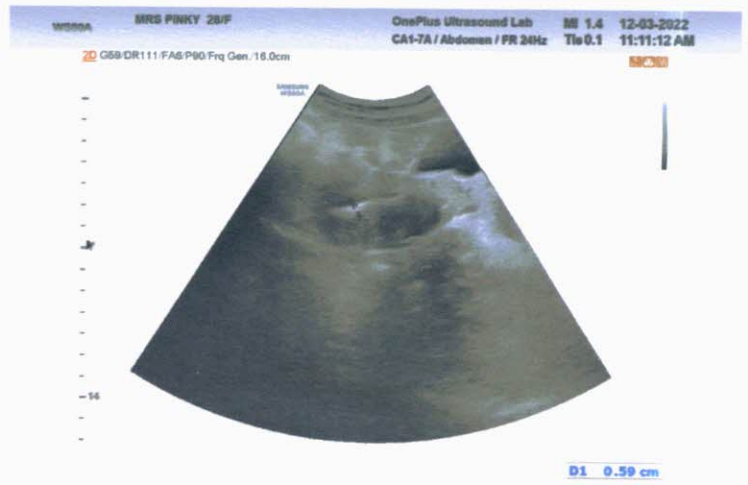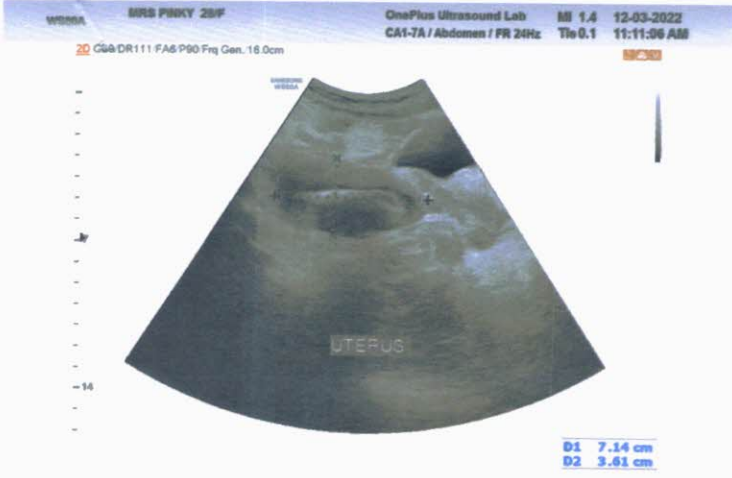
DR. POOJA GARG
RADIOLOGIST
REG NO- DMC/R/03398


Dr. POOJA GARG
M.B.B.S., D.M.R.D
Reg No. DMC/R/03398
Radiologist

Type By : darshita

47, Harsh Vihar, Pitampura, New Delhi-110034 | Ph.: 011-42480101, 9599913051
E-mail: oneplusul@gmail.com | Web.: www.oneplusul.in

Clinical correlation is essential for final diagnosis. • If test results are unsatisfactory please contact personally or on phone. • This report is for perusal of doctors only.
• All disputes Subject to Delhi Jurisdiction only. • Not for medicolegal purposes. • All congenital anomalies in a foetus may not be diagnosed in routine obstetric ultrasound.







OnePLUS

Ultrasound Lab

Dr. Nitin Agarwal
Pathologist & Director
Ex. Sr. Res. MAMC
& Lok Nayak Hospital
Ex. Chief of Lab Dr. Lal Path Labs.

Dr. Pooja (Garg) Agarwal
Radiologist & Director
MAMC & Lok Nayak Hospital



NAME	QUALITY FIRST... ALWAYS!	Mrs. PINKI DEVI	Barcode No	:10115144
AGE/GENDER		:28 YRS/Female	SPECIMEN DATE	:12/Mar/2022 09:46AM
PATIENT ID		:92436	SPECIMEN RECEIVED	:12/Mar/2022 09:53AM
REFERRED BY		:Dr. MEDIWHEEL	REPORT DATE	:12/Mar/2022 04:35PM
CENTRE NAME		:ONEPLUS ULTRASOUND LAB	LAB NO.	:012203120017

Test Name	Result	Unit	Ref. Range
-----------	--------	------	------------

HAEMATOLOGY

Health checkup 2 Female

Glycosylated Hemoglobin (HbA1c)	4.3	%	Non Diabetic adults <5.7 Prediabetic (at risk) 5.7-6.4 Diabetes >6.4
--	-----	---	--

Estimated average blood glucose (eag) 77

Reference range (mg/dl):

90 - 120:Excellent control, 121 - 150:Good Control, 151 - 180:Average Control, 181 - 210:Action Suggested

>211:Panic value

BLOOD GROUP (ABO)	B
Rh typing	POSITIVE

NOTE :

- * Apart from major A,B,H antigens which are used for ABO grouping and Rh typing, many minor blood group antigens exist. Agglutination may also vary according to titre of antigen and antibody.
- * So before transfusion, reconfirmation of blood group as well as cross-matching is needed.
- * Presence of maternal antibodies in newborns, may interfere with blood grouping.
- * Auto agglutination (due to cold antibody, falciparum malaria, sepsis, internal malignancy etc.) may also cause erroneous result.

CBC

Haemoglobin	9.9	g/dl	11.5-15.0
Total Leucocyte Count	6010	/cumm	4000-10000
Differential leucocyte count			
Neutrophils	58.9	%	40-80
Lymphocyte	27.70	%	20-40
Monocytes	6.30	%	2-10
Eosinophils	6.5	%	1-6
Basophils	0.6	%	0-2
RBC Count	4.04	million/cumm	3.8-4.8

Checked By.

DR. NITIN AGARWAL
MBBS,MD(PATHOLOGIST)

47, Harsh Vihar, Pitampura, New Delhi-110034 | Ph.: 011-42480101, 9599013051
E-mail: oneplusul@gmail.com | Web.: www.oneplusul.in

DR. NITIN AGARWAL
MBBS, MD (Path)
DMC/R/01436



OnePLUS Ultrasound Lab

Dr. Nitin Agarwal
Pathologist & Director
Ex. Sr. Res. MAMC
& Lok Nayak Hospital
Ex. Chief of Lab Dr. Lal Path Labs.

Dr. Pooja (Garg) Agarwal
Radiologist & Director
MAMC & Lok Nayak Hospital



NAME	QUALITY FIRST... ALWAYS! :MRS. PINKI DEVI	Barcode No	:10115144
AGE/GENDER	:28 YRS/Female	SPECIMEN DATE	:12/Mar/2022 09:46AM
PATIENT ID	:92436	SPECIMEN RECEIVED	:12/Mar/2022 09:53AM
REFERRED BY	:Dr. MEDIWHEEL	REPORT DATE	:12/Mar/2022 04:35PM
CENTRE NAME	:ONEPLUS ULTRASOUND LAB	LAB NO.	:012203120017

Test Name	Result	Unit	Ref. Range
PCV(Hematocrit)	32.8	%	36-46
MCV	81.3	fL	83-101
MCH	24.6	Pg	27-32
MCHC	30.3	G/dL	32-35
Platelet count	273000	/cumm	150000-450000
RDW-CV	15.9	%	11.4-14.0
ESR(WESTEGRENs METHOD)	20	mm/1hr	<20

BIOCHEMISTRY

<u>Blood sugar fasting</u>	75	mg/dL	70-110
<u>Blood sugar pp</u>	104	mg/dL	70.0-140.0
<u>Bun (blood urea nitrogen)</u>	12.20	mg/dl	7-18.7
<u>Uric acid, serum</u>	4.6	mg/dl	2.4-5.7
<u>Creatinine, serum</u>	0.62	mg/dl	0.50-0.9

LFT(LIVER FUNCTION TEST)

Bilirubin Total	0.62	mg/dl	0.1-1.2
Bilirubin Conjugated	0.38	mg/dl	0-0.4
Bilirubin Unconjugated	0.24	mg/dl	up to 0.7
SGOT (AST)	26	U/L	0-31
SGPT (ALT)	24	U/L	<34
Alkaline phosphatase	80	U/L	35-104
Gamma glutamyl transpeptidase	24	U/L	<39
Total Protein	7.0	gm/dl	6.60 - 8.70
Albumin	4.0	g/dL	3.8-5.1
Globulin	3.00	gm/dl	1.8-3.4
Albumin/Globulin Ratio	1.33		1.10 - 2.50

LIPID PROFILE

Cholesterol	156	mg/dl	50-200
Triglycerides	100	mg/dL	25-150

Checked By.

DR. NITIN AGARWAL
M.B.B.S., M.D. (Path)
DMC/R/01436

47, Harsh Vihar, Pitampura, New Delhi-110034 | Ph.: 011-42480101, 9599913051
E-mail: oneplusul@gmail.com | Web.: www.oneplusul.in



OnePLUS

Ultrasound Lab

Dr. Nitin Agarwal
Pathologist & Director
Ex. Sr. Res. MAMC
& Lok Nayak Hospital
Ex. Chief of Lab Dr. Lal Path Labs.

Dr. Pooja (Garg) Agarwal
Radiologist & Director
MAMC & Lok Nayak Hospital



NAME QUALITY FIRST... ALWAYS!	Mrs. PINKI DEVI	Barcode No	:10115144
AGE/GENDER	:28 YRS/Female	SPECIMEN DATE	:12/Mar/2022 09:46AM
PATIENT ID	:92436	SPECIMEN RECEIVED	:12/Mar/2022 09:53AM
REFERRED BY	:Dr. MEDIWHEEL	REPORT DATE	:12/Mar/2022 04:35PM
CENTRE NAME	:ONEPLUS ULTRASOUND LAB	LAB NO.	:012203120017

Test Name	Result	Unit	Ref. Range
HDL Cholesterol	38	mg/dL	30 - 70
LDL cholesterol	98	mg/dL	< 130
VLDL cholesterol	20.0	mg/dL	5-40
Cholesterol/HDL Ratio	4.1		Low Risk 3.3-4.97 Average Risk 4.4-7.1 Moderate Risk 7.1-11.0 High Risk >11.0
LDL/HDL Ratio	2.6		0 - 3.55

According to ATP III and NCEP guidelines

Parameter	Normal	Desirable	Borderline	High
Total cholesterol	<200	200-239		240
Triglycerides	<150	150-199	200-499	500
LDL	Optimal <100 Near Optimal 100-129	130-159	160-180	190
HDL	<40 : LOW 60 : HIGH			

ENDOCRINOLOGY

THYROID PROFILE(T3,T4,TSH)

Triiodothyronine total [t3]	0.62	ng/dl	0.52-1.9
Thyroxine total [t4]	7.40	µg/dl	4.8-11.6
TSH (Thyroid Stimulating Hormone)	2.90	µIU/ml	0.25-5.0

AGE WISE VARIATION IN TSH

AGE	TSH(µIU/ml)	AGE	TSH(µIU/ml)
1-4 weeks	1.00 - 19.0	16-20 yrs	0.25 - 5.0
1-12 mths	1.70 - 9.1	21 - 80 yrs	0.25 - 5.0
1-5 yrs	0.80 - 8.2	I st trimester	0.25 - 5.0
6-10 yrs	0.25 - 5.0	II nd trimester	0.50 - 5.0
11-15 yrs	0.25 - 5.0	III rd trimester	0.4 - 6.0

Checked By.

DR. NITIN AGARWAL
MBBS, MD (PATHOLOGIST)
Dr. NITIN AGARWAL
MBBS, MD (Path)
MNC/R/01436

47, Harsh Vihar, Pitampura, New Delhi-110034 | Ph.: 011-42480101, 9599913051

E-mail: oneplusul@gmail.com | Web.: www.oneplusul.in



OnePLUS Ultrasound Lab

Dr. Nitin Agarwal

Pathologist & Director
Ex. Sr. Res. MAMC
& Lok Nayak Hospital
Ex. Chief of Lab Dr. Lal Path Labs.

Dr. Pooja (Garg) Agarwal

Radiologist & Director
MAMC & Lok Nayak Hospital



NAME	QUALITY FIRST... ALWAYS! :MRS. PINKI DEVI	Barcode No	:10115144
AGE/GENDER	:28 YRS/Female	SPECIMEN DATE	:12/Mar/2022 09:46AM
PATIENT ID	:92436	SPECIMEN RECEIVED	:12/Mar/2022 09:53AM
REFERRED BY	:Dr. MEDIWHEEL	REPORT DATE	:12/Mar/2022 04:35PM
CENTRE NAME	:ONEPLUS ULTRASOUND LAB	LAB NO.	:012203120017

Test Name	Result	Unit	Ref. Range
-----------	--------	------	------------

Reference ranges - Interpretation of Diagnostic tests - (Jacques Wallach)

1. Primary hypothyroidism is accompanied by depressed serum T3 and T4 values and elevated serum TSH level.
2. Primary hyperthyroidism is accompanied by elevated serum T3 and T4 levels along with depressed TSH values.
3. Slightly elevated T3 levels may be found in pregnancy and estrogen therapy, while depressed levels may be encountered in severe illness, renal failure and during therapy with drugs like propranolol and propyl thiouracil.
4. Although elevated TSH levels are nearly always indicative of primary hypothyroidism, and may be seen in secondary thyrotoxicosis

Checked By.

DR. NITIN AGARWAL
MBBS, MD (PATHOLOGIST)
Dr NITIN AGARWAL
MBBS, MD (Path)
DMC/R/01436

47, Harsh Vihar, Pitampura, New Delhi-110034 | Ph.: 011-42480101, 9599923051

E-mail: oneplusul@gmail.com | Web.: www.oneplusul.in



OnePLUS Ultrasound Lab

Dr. Nitin Agarwal
Pathologist & Director
Ex. Sr. Res. MAMC
& Lok Nayak Hospital
Ex. Chief of Lab Dr. Lal Path Labs.

Dr. Pooja (Garg) Agarwal
Radiologist & Director
MAMC & Lok Nayak Hospital



NAME	QUALITY FIRST... ALWAYS! :Mrs. PINKI DEVI	Barcode No	:10115144
AGE/GENDER	:28 YRS/Female	SPECIMEN DATE	:12/Mar/2022 09:46AM
PATIENT ID	:92436	SPECIMEN RECEIVED	:12/Mar/2022 09:53AM
REFERRED BY	:Dr. MEDIWHEEL	REPORT DATE	:12/Mar/2022 02:01PM
CENTRE NAME	:ONEPLUS ULTRASOUND LAB	LAB NO.	:012203120017

Test Name	Result	Unit	Ref. Range
CLINICAL PATHOLOGY			
URINE ROUTINE			
Physical examination			
Quantity	30		ML
Colour	PALE YELLOW		
Transparency	SLIGHTLY TURBID		CLEAR
Sp.gravity	1.015		1.010-1.030
pH	6.00		
Reaction	ACIDIC		ACIDIC
Chemical examination			
Urine protein	NIL		NIL
Urine sugar	NIL		NIL
Bilirubin, urine	NEGATIVE		NEGATIVE
Urobilinogen	NORMAL		NORMAL
Ketones	NEGATIVE		NEGATIVE
Microscopic examination			
Pus cells.	4-6	/HPF	1-2
Epithelial cells	3-5	/HPF	0-5
R.B.C.	NIL	/HPF	NIL
Casts	NIL	/HPF	NIL
Crystals	NIL	/HPF	NIL
Bacteria	NIL	/HPF	NIL
Others.	NIL		NIL

*** End Of Report ***

Checked By.

DR. NITIN AGARWAL
MBBS, MD (Pathology)

DR. NITIN AGARWAL
MBBS, MD (Path)
DMC/R/01436

47, Harsh Vihar, Pitampura, New Delhi-110034 | Ph.: 011-42480101, 9599913051

E-mail: oneplusul@gmail.com | Web.: www.oneplusul.in

ONEPLUS ULTRASOUND LAB

47, HARSH VIHAR, PITAMPURA, DELHI- 110034

RAD

Ms. PINKI DEVI
 Age : 28/F
 Ref. by : MED/WHEEL
 Indication1 :
 Medication2 :
 Medication3 :
 COMMENTS : Short PR Interval To be Ruled Out Likely Inferior Myocardial Ischemia Sinus Tachycardia, Prolonged QTc Interval.

ID : 1910
 HtWt : 152/39
 Recorded : 12-3-2022 13:15
 Medication1 :
 Medication2 :
 Medication3 :

BPM : 125
 BP : 110/66
 P Axis : 83 deg
 QRS Axis : 90 deg
 T Axis : -38 deg

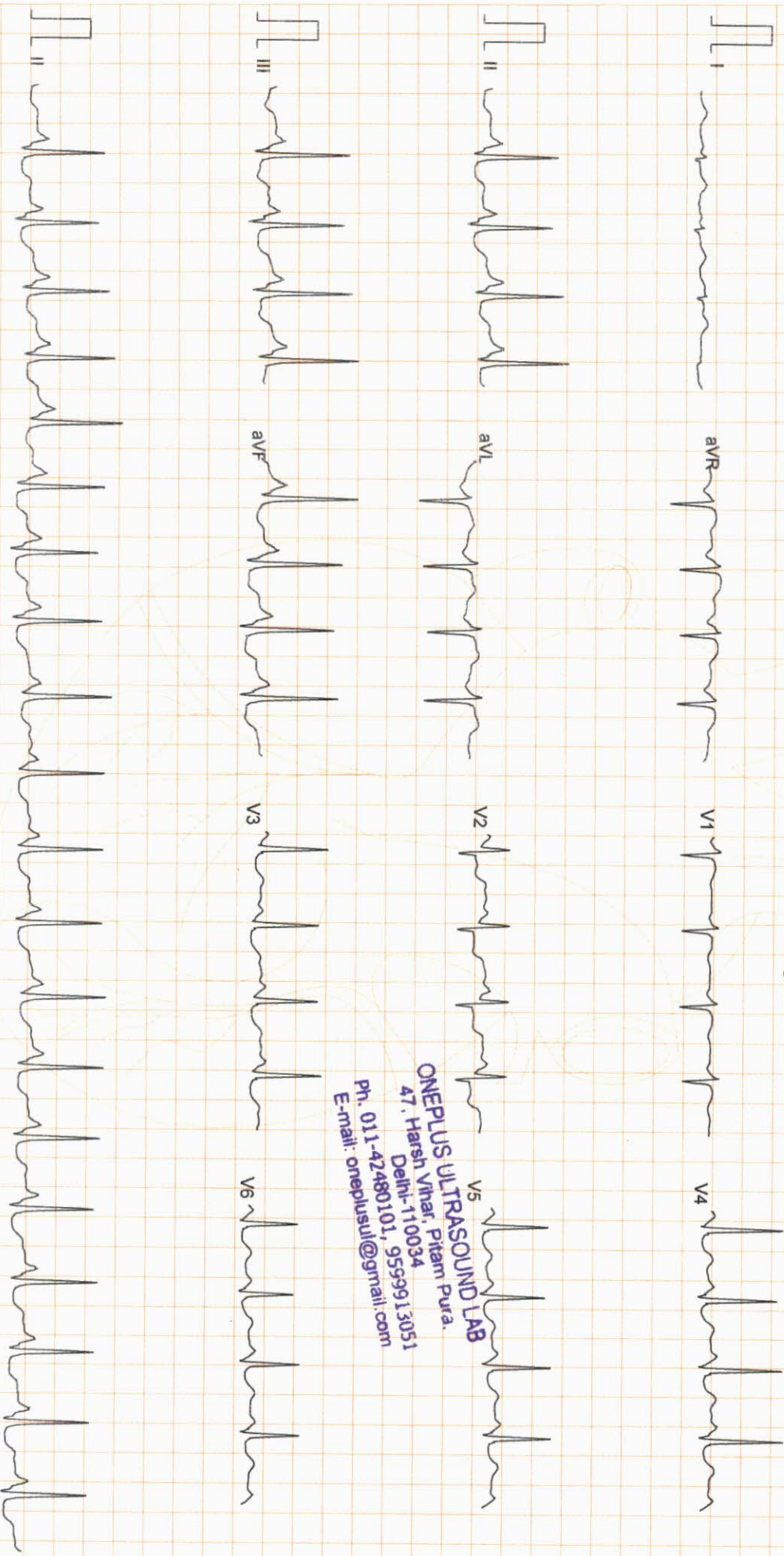
P duration : 73 msec
 PR duration : 96 msec
 QRS duration : 103 msec
 QT interval : 323 msec
 QTc interval : 436 msec

Raw E.C.G. (Seq)

Unconfirmed Report Reviewed By:
 Cardiologist

P Singh
Dr. B.S. SINGLA
 MBBS MD
 Reg. No. 57807

ONEPLUS ULTRASOUND LAB
 47, Harsh Vihar, Pitam Pura,
 Delhi-110034
 Ph. 011-42480101, 9599913051
 E-mail: oneplusul@gmail.com



Filtered

25mm/sec 10mm/mV

AV22W

CardiCom, INDIA

ONEPLUS ULTRASOUND LAB

47, HARSH VIHAR PITAMPURA DELHI 110034

Ms. PINKI DEVI

ID : 996

TREADMILL TEST SUMMARY REPORT

Age : 28/F
Ref. by : MEDWHEEL

H/Wt : 152/39
Recorded : 12-3-2022 13:17

Protocol: BRUCE
History:

Indication1 :
Indication2 :
Indication3 :

Medication1 :
Medication2 :
Medication3 :

PHASE	PHASE TIME	STAGE TIME	SPEED (Km./Hr.)	GRADE (%)	H.R. (BPM)	B.P. (mmHg)	RPP X100	II	ST LEVEL (mm) V2	V5	METS
SUPINE					120	110/66	132	-1.9	-0.9	0.0	
STANDING					120	110/66	132	-1.0	-1.0	-0.1	
STAGE 1	2:59	2:59	2.70	10.00	188	122/70	229	0.0	0.9	0.9	4.80
STAGE 2	4:59	1:59	4.00	12.00	195	130/76	253	0.9	1.8	1.5	6.33
PEAK EXER	5:11	2:11			195	130/76	253	0.7	1.8	1.7	6.48
RECOVERY	2:59	2:59	0.00	0.00	129	110/66	141	-0.3	1.0	0.3	

RESULTS

Exercise Duration : 5:11 Minutes
Max Heart Rate : 195 bpm 101 % of target heart rate 192 bpm
Max Blood Pressure : 130/76 mmHg
Max Work Load : 6.48 METS
Reason of Termination :

IMPRESSIONS

Negative for inducible ischemia

Pass

DR. B.S. SINGLA
MBBS MD
Reg. No. 57807

Pin

Cardiologist

ONEPLUS ULTRASOUND LAB
47, Harsh Vihar, Pitampura,
Delhi-110034
Ph. 011-42480101, 9559913051
E-mail: oneplusul@gmail.com

ONEPLUS ULTRASOUND LAB

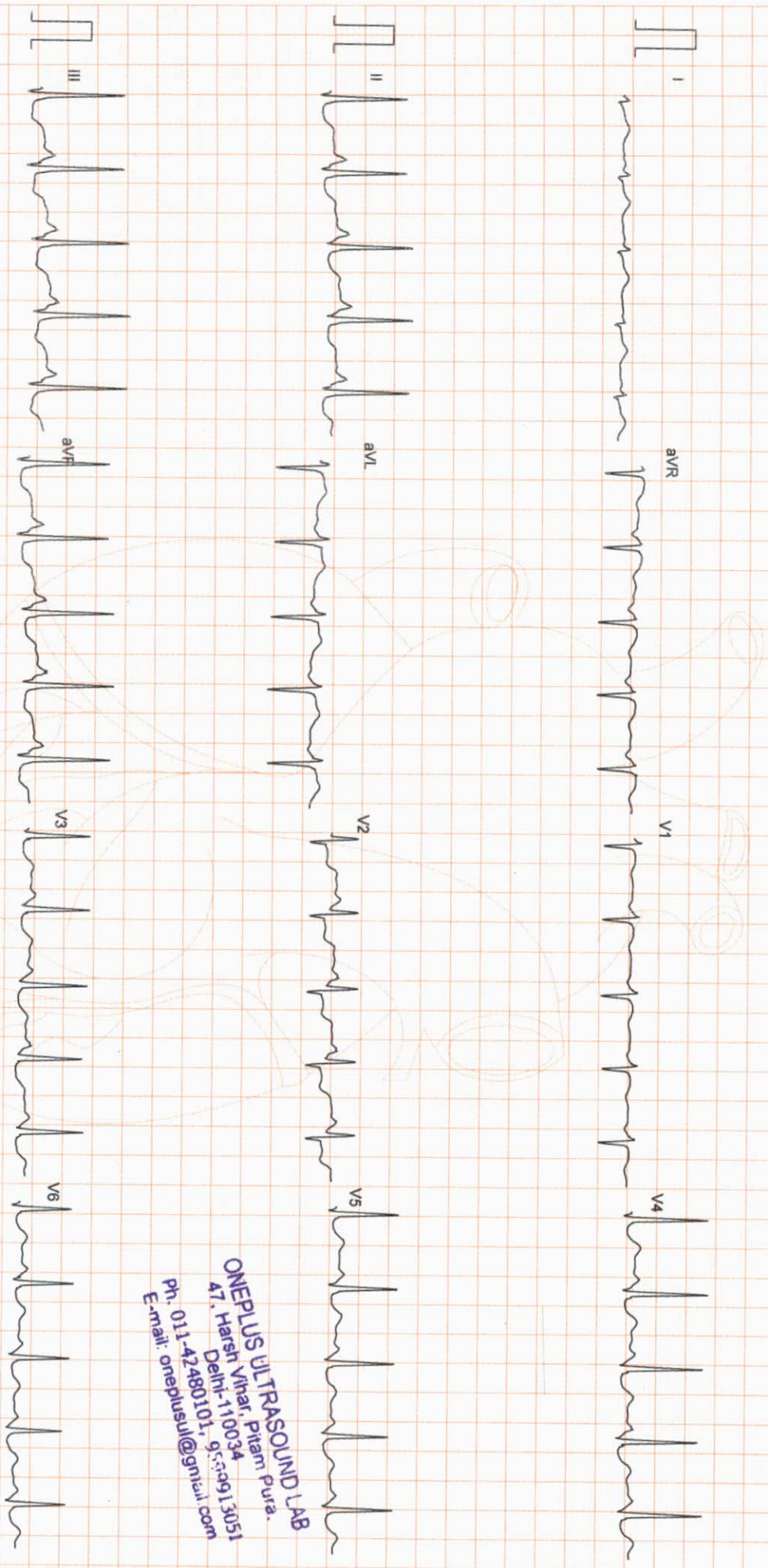
SUPINE
PRETEST

ST @ 10mm/mV
80ms PostJ

Ms. PINKI DEVI
I.D. : 996
AGE/SEX : 28/F
RECORDED : 12-3-2022 13:17

RATE : 120 BPM
B.P. : 110/66 mmHg

RAW E.C.G.



ONEPLUS ULTRASOUND LAB
47, Harsh Vihar, Pitam Pura,
Delhi-110034
Ph: 011-42480101, 9550913051
E-mail: oneplusul@gnicall.com

ONEPLUS ULTRASOUND LAB

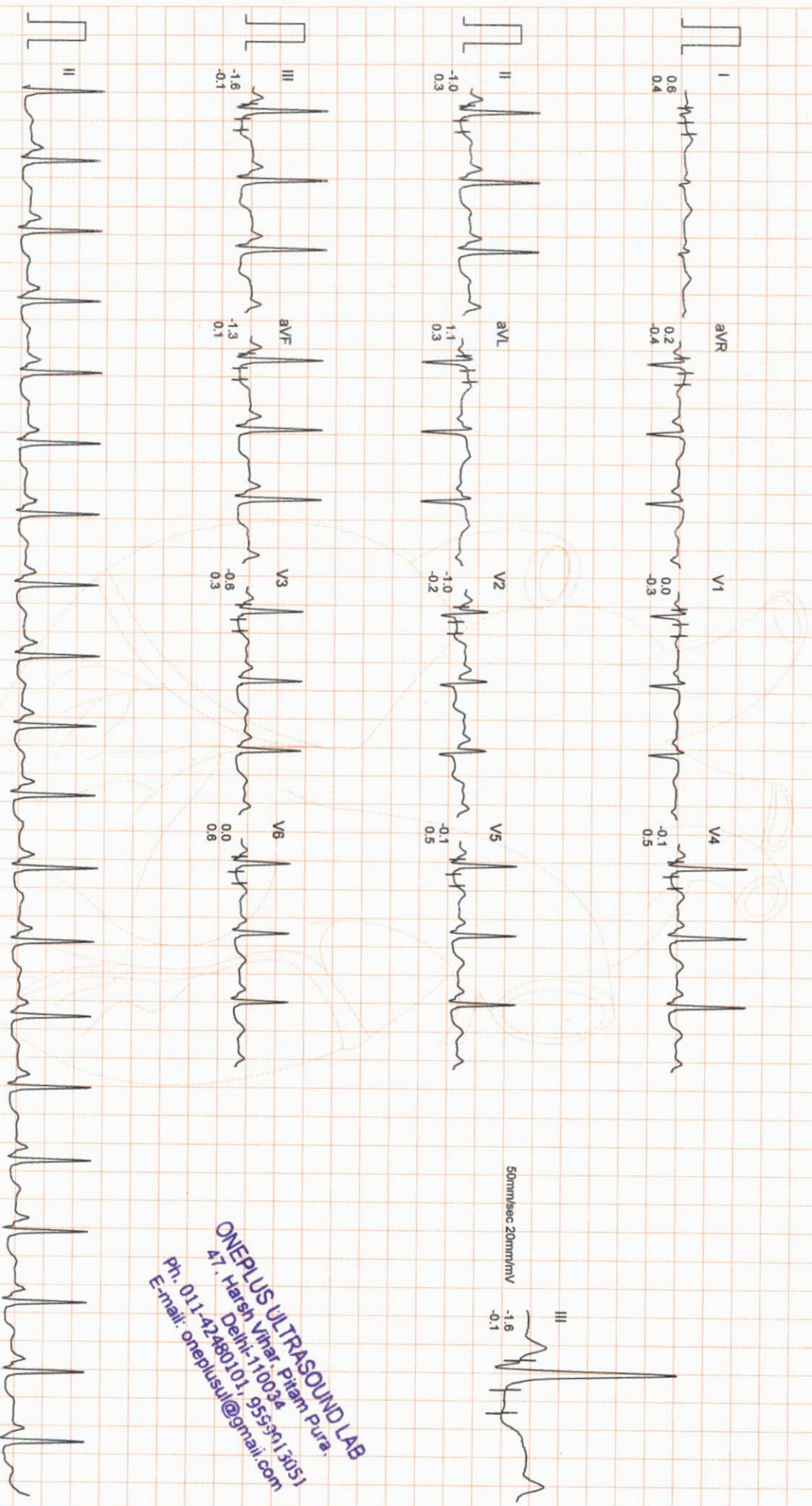
STANDING
PRETEST

ST @ 10mm/mV
80ms PostJ

Ms. PINKI DEVI
I.D. : 996
AGE/SEX : 28/F
RECORDED : 12-3-2022 13:17

RATE : 120 BPM
B.P. : 110/66 mmHg

LINKED MEDIAN



ONEPLUS ULTRASOUND LAB
47, Harsh Vihar, Pitam Pura,
Delhi-110034
Ph. 011-4248010, 9593913051
E-mail: oreplusul@gmail.com

ONEPLUS ULTRASOUND LAB

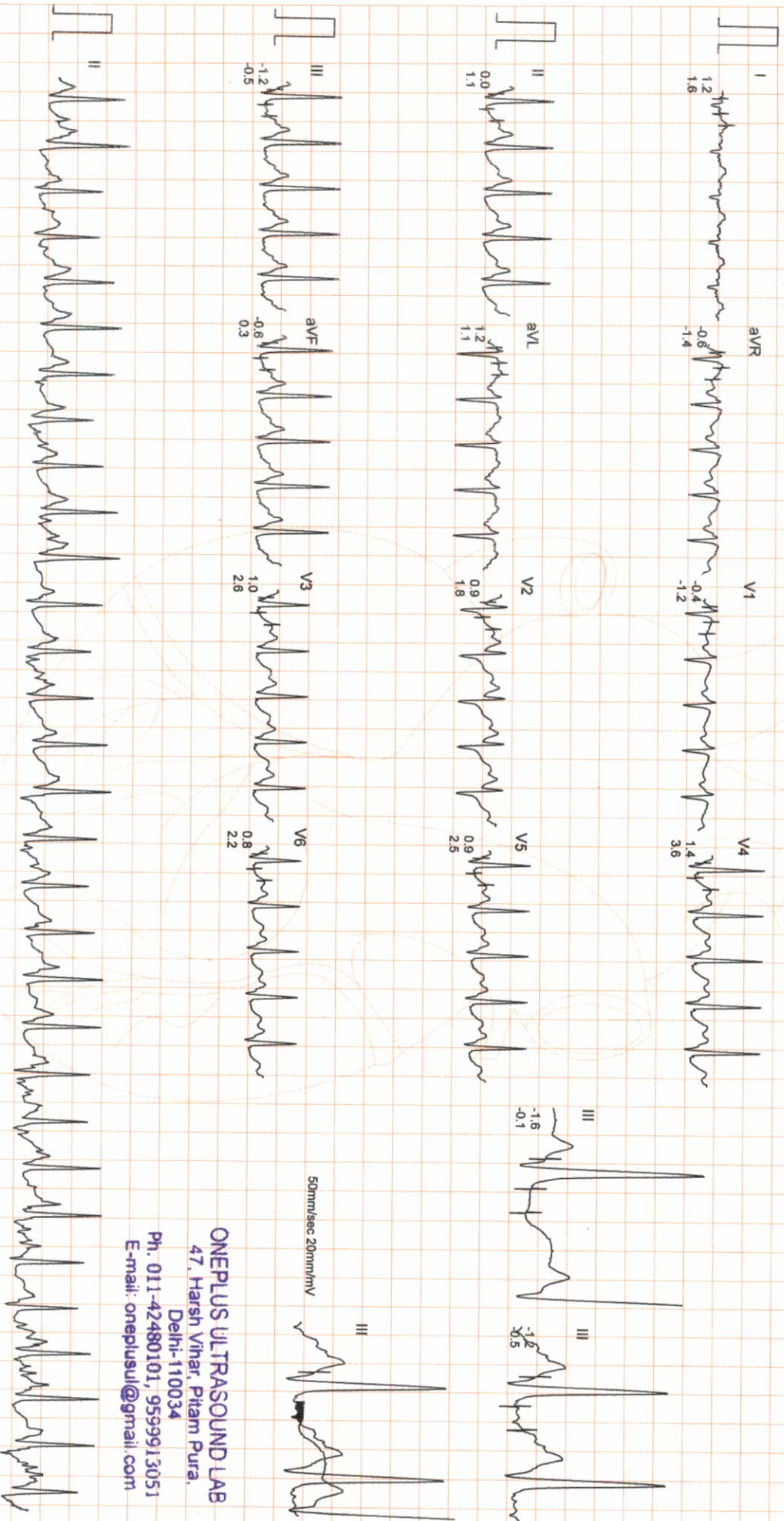
Ms. PINKI DEVI
 I.D. : 996
 AGE/SEX : 28/F
 RECORDED : 12-3-2022 13:17

RATE : 188 BPM
 B.P. : 122/70 mmHg

BRUCE
 EXERCISE 1
 PHASE TIME : 2:59
 STAGE TIME : 2:59

ST @ 10mm/mV
 80ms PostJ
 SPEED : 2.7 Km./Hr.
 GRADE : 10.0 %

LINKED MEDIAN



ONEPLUS ULTRASOUND LAB
 47, Harsh Vihar, Pitam Pura,
 Delhi-110034
 Ph. 011-42480101, 9599913051
 E-mail: oneplusul@gmail.com

ONEPLUS ULTRASOUND LAB

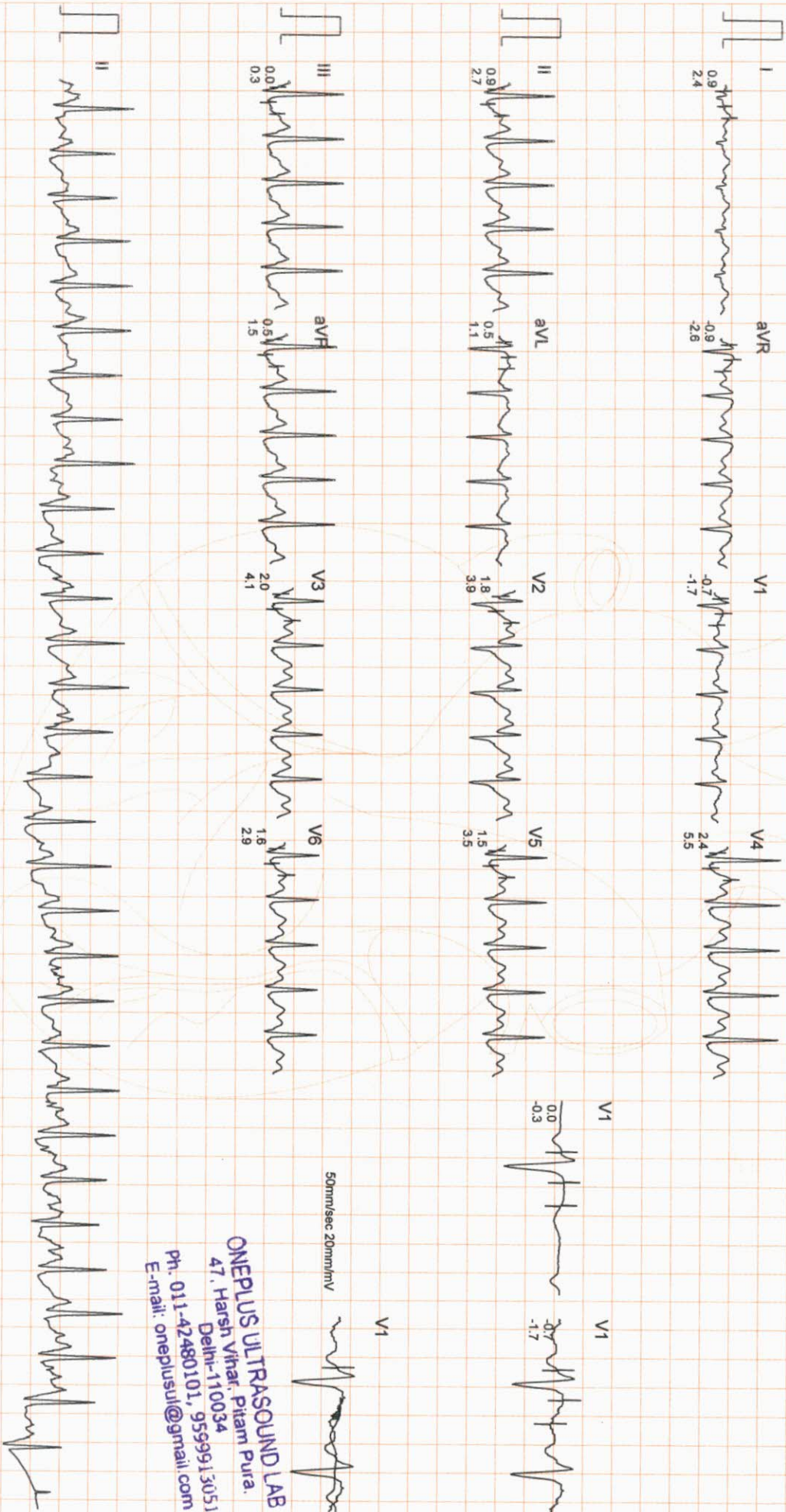
Ms. PINKI DEVI
I.D. : 996
AGE/SEX : 28/F
RECORDED : 12-3-2022 13:17

RATE : 195 BPM
B.P. : 130/76 mmHg

BRUCE
EXERCISE 2
PHASE TIME : 4:59
STAGE TIME : 1:59

ST @ 10mm/mV
80ms PostJ
SPEED : 4.0 Km./Hr.
GRADE : 12.0 %

LINKED MEDIAN



50mm/Sec 20mm/mV

ONEPLUS ULTRASOUND LAB
47, Harsh Vihar, Pitam Pura.
Delhi-110034
Ph. 011-42480101, 9599913051
E-mail: oneplusul@gmail.com

ONEPLUS ULTRASOUND LAB

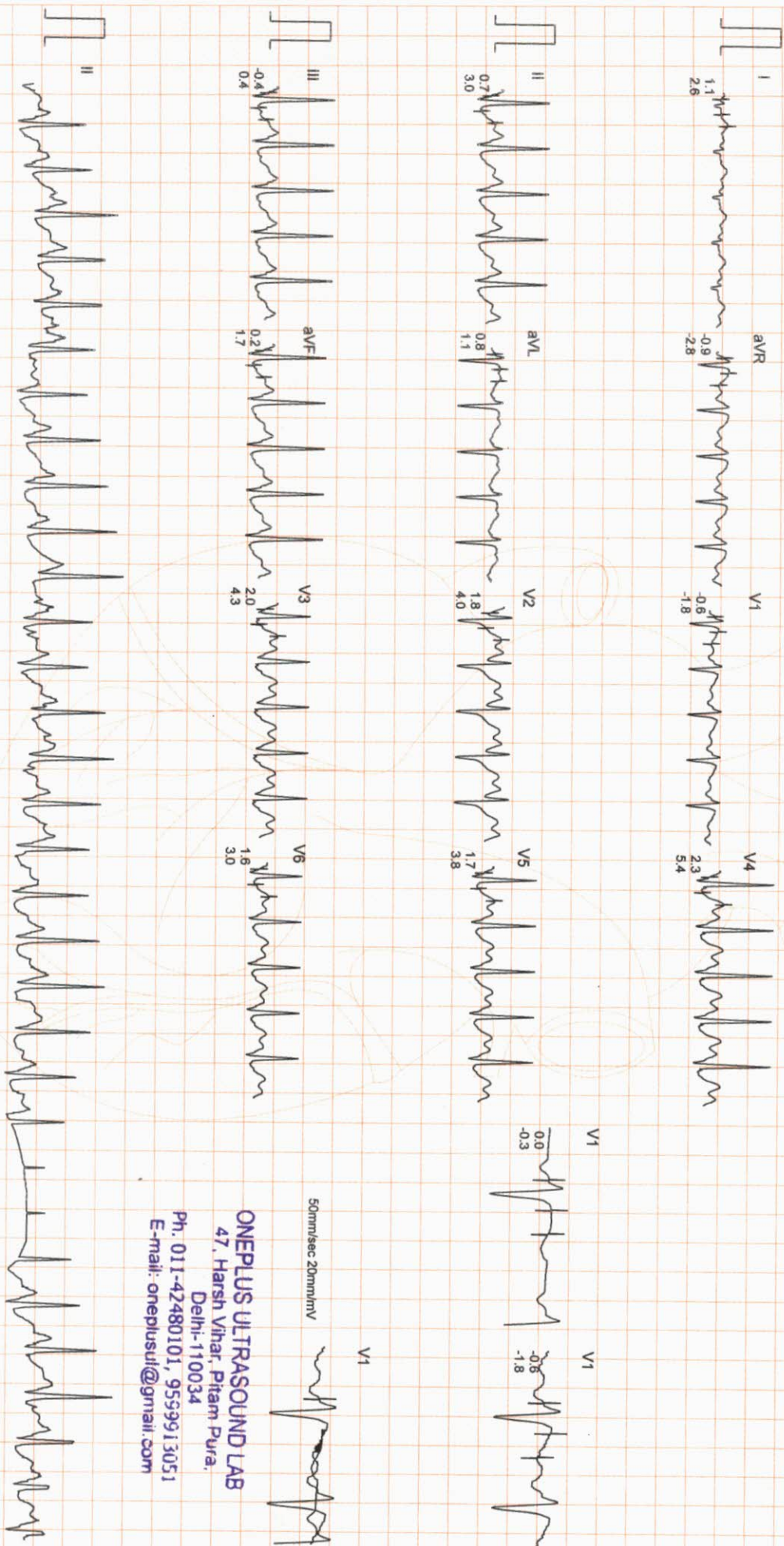
Ms. PINKI DEVI
I.D. : 996
AGE/SEX : 28/F
RECORDED : 12-3-2022 13:17

RATE : 195 BPM
B.P. : 130/76 mmHg

BRUCE
PEAK EXER
PHASE TIME : 5:11
STAGE TIME : 2:11

ST @ 10mm/mV
80ms PostJ
SPEED : 4.0 Km./Hr.
GRADE : 12.0 %

LINKED MEDIAN



50mm/sec 20mm/mV
ONEPLUS ULTRASOUND LAB
47, Harsh Vihar, Pitam Pura,
Delhi-110034
Ph. 011-42480101, 9559913051
E-mail: oneplusul@gmail.com

ONEPLUS ULTRASOUND LAB

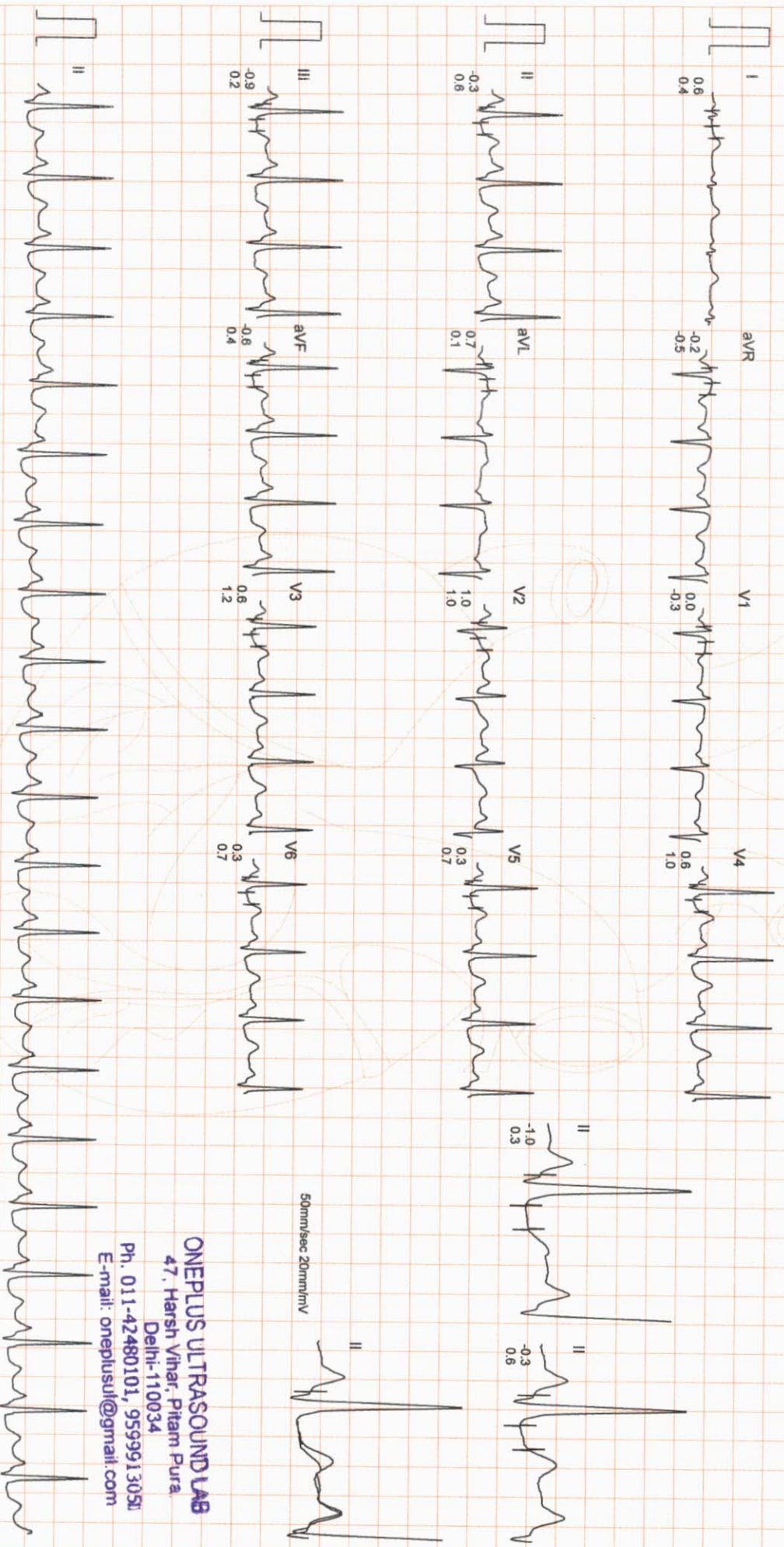
Ms. PINKI DEVI
I.D. : 996
AGE/SEX : 28/F
RECORDED : 12-3-2022 13:17

RATE : 129 BPM
B.P. : 110/66 mmHg

BRUCE
RECOVERY
PHASE TIME : 2:59

ST @ 10mm/mV
80ms PostJ
SPEED : 0.0 Km./Hr.
GRADE : 0.0 %

LINKED MEDIAN



50mm/sec 20mm/mV

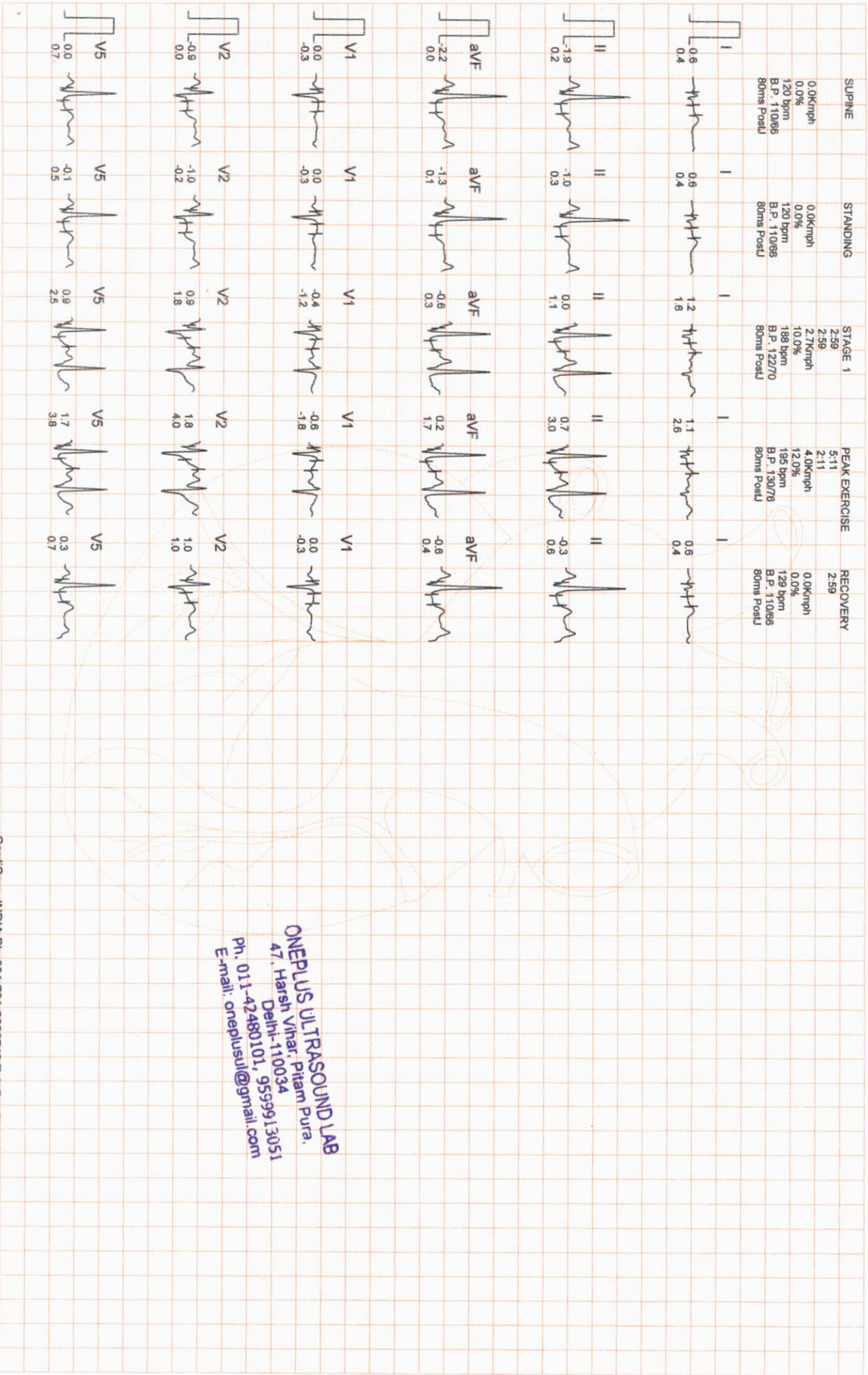
ONEPLUS ULTRASOUND LAB
47, Harsh Vihar, Pitam Pura
Delhi-110034
Ph. 011-42480101, 9599913051
E-mail: oneplusul@gmail.com

Filtered Computer Corrected Baseline

25mm/sec 10mm/mV

ARTIVA

CardiCom, INDIA Ph.:091-731-2620740, TeleFax:091-731-2431214







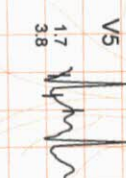








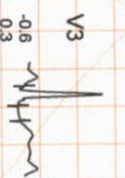



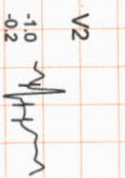

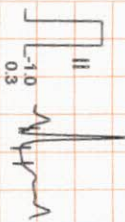


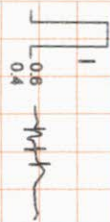
ONEPLUS ULTRASOUND LAB
 47, Harsh Vihar, Pitam Pura,
 Delhi-110034
 Ph. 011-42480101, 9559913051
 E-mail: oneplusul@gmail.com

STANDING
 0.0kmph
 0.0%
 120 bpm
 B.P. 110/66
 80ms PostJ

PEAK EXERCISE
 5:11
 2:11
 4.0kmph
 12.0%
 196 bpm
 B.P. 130/76
 80ms PostJ

STANDING
 0.0kmph
 0.0%
 120 bpm
 B.P. 110/66
 80ms PostJ

PEAK EXERCISE
 5:11
 2:11
 4.0kmph
 12.0%
 196 bpm
 B.P. 130/76
 80ms PostJ



ONEPLUS ULTRASOUND LAB
 47, Harsh Vihar, Pitam Pura.
 Delhi-110034
 Ph. 011-42480101, 9559913051
 E-mail: oneplusul@gmail.com