

India Driving License (Tamil Nadu)
Form 7

ISSUE DATE: 08/12/2011

DL No: TN74 20110012467

Name: HERVIN PRAISON T
S.D.W. THANGARAJA T

Address:
505 B7, M.S. ROAD,
VETTOORNIMADAM PO, NAGERCOIL,
KANYAKUMARI DIST 629003

Driving School:
VELAYUDHAN DRIVING SCHOOL

Date of Birth: 22-11-1989


Sex: M



ISSUE DATE: 08-12-2011 TN74

EXPIRES: 08/12/2011 TN74


New Transport Veh. Valid upto: 07/12/2031



Handwritten signature

T. Hevin Praisson.

Stool Sample Analysis - Not Interested.





MURUGAN HOSPITALS

HEALING HANDS



LAB REPORT

Patient Name : Mr. HERVIN PRAISON,T
Age / Gender : 32-Years / Male
UHID ID : MH20220035814
Doctor Name : Dr. ARUN PRAKASH

OP Report No. : INVA2104920
Bill No. : INV2108805
Sample Date : 26/03/2022 - 03:46 PM
Report Date : 26/03/2022 - 05:06 PM

Test Name	Result	Units	Reference Interval
-----------	--------	-------	--------------------

HAEMATOLOGY

Complete Blood Cell Count(CBC)

HAEMOGLOBIN	13.5	gms/dl	male :13.0 - 17.0 female :12.0 - 15.0
PACKED CELL VOLUME	42.4	%	male : 40 - 50 female : 36 - 46
RBC COUNT	<u>5.08</u>	millions cells/cu.mm	female: 3.8 - 4.8 male : 4.5 - 5.5
TOTAL WBC	6,600	Cells/Cumm	4,000 - 11,000
Differential Count			
NEUTROPHILS	50	%	40 - 65
LYMPHOCYTES	42	%	30-50
EOSINOPHILS	06	%	01-06
MONOCYTES	02	%	1-10
BASOPHILS	00	%	0-2
ESR 60 MTS	06	mm	5 - 20
PLATELET COUNT	2.48	Lakhs/cumm	1.5 - 4.5
MCV	83.5	fL	76 - 96
MCH	<u>26.5</u>	pg	27 - 32
MCHC	31.8	gms/dl	30 - 36

INTERPRETATION: Test done on automated three part cell counter, all abnormal results are reviewed and confirmed microscopically.

BLOOD GROUPING & RH TYPING " O " POSITIVE

Page 1 of 4

Healing Hearts and Lives

264/125, Kilpauk Garden Road, Kilpauk, Chennai - 600 010.
Phone : +91 44 4644 8989 / 75500 53335 | Email : muruganhosp@gmail.com
Website : www.muruganhospitals.in



MURUGAN HOSPITALS

HEALING HANDS



LAB REPORT

Patient Name : Mr. HERVIN PRAISON.T
Age / Gender : 32-Years / Male
UHID ID : MH20220035814
Doctor Name : Dr. ARUN PRAKASH

OP Report No. : INVA2104920
Bill No. : INV2108805
Sample Date : 26/03/2022 - 03:46 PM
Report Date : 26/03/2022 - 05:06 PM

Test Name	Result	Units	Reference Interval
BIO CHEMISTRY			
BLOOD SUGAR FASTING	87	mgs/dl	70-110
BLOOD SUGAR POST PRANDIAL	92	mgs/dl	80- 160
SERUM CREATININE	0.7	mg/dl	0.7-1.4
SERUM URIC ACID	5.6	mg/dl	male 3.1-7.0 , female 2.5-5.6
LIPID PROFILE			
TOTALCHOLESTEROL	234 ↑	mg/dl	< 200
TRIGLYCERIDE	91	mg/dl	< 150
HDL	52	mg/dl	35 - 80
VLDL	18	mg/dl	2 to 30
LDL	164	mg/dl	<130
CHOLESTEROL/ HDL RATIO	4.5	mg/dl	

Healing Hearts and Lives

264/125, Kilpauk Garden Road, Kilpauk, Chennai - 600 010.
Phone : +91 44 4644 8989 / 75500 53335 | Email : muruganhosp@gmail.com
Website : www.muruganhospitals.in



MURUGAN HOSPITALS

HEALING HANDS



LAB REPORT

Patient Name : Mr. HERVIN PRAISON.T
 Age / Gender : 32-Years / Male
 UHID ID : MH20220035814
 Doctor Name : Dr. ARUN PRAKASH

OP Report No. : INVA2104920
 Bill No : INV2108805
 Sample Date : 26/03/2022 - 03:46 PM
 Report Date : 26/03/2022 - 05:06 PM

Test Name	Result	Units	Reference Interval
LIVER FUNCTION TEST			
BILLIRUBIN(TOTAL)	1.0	mg/dl	0.0 -1.0
BILLIRUBIN(DIRECT)	0.3	mg/dl	0.1- 0.30
BILLIRUBIN(INDIRECT)	0.7	mg/dl	0.2-0.8
SGOT	30	IU/L	0-38
SGPT	24	IU/L	0.0-40
ALKALINE PHOSPHATASE	102	IU/L	40-140 4-6Years 93-309 13-15Years 74-390
TOTAL PROTEIN	7.6	gm/dl	6.6-8.7
ALBUMIN	4.5	gm/dl	3.5 - 5.5
GLOBULIN	3.1	gm/dl	2.0-3.5
AG RATIO	1.4		
GAMMA G T	16	U/L	male<49 female<32
BLOOD UREA NITROGEN	9.8	mg/dl	7-21
HBA1C	5.3	%	normal: <6.0 good control: 6.1-7.0 fair control: 7.1-8.0 poor control:8.1 -10.0 unsatisfactory: >10.0

Healing Hearts and Lives

264/125, Kilpauk Garden Road, Kilpauk, Chennai - 600 010.
 Phone : +91 44 4644 8989 / 75500 53335 | Email : muruganhosp@gmail.com
 Website : www.muruganhospitals.in



MURUGAN HOSPITALS

HEALING HANDS



LAB REPORT

Patient Name : Mr. HERVIN PRAISON.T
Age / Gender : 32-Years / Male
UHID ID : MH20220035814
Doctor Name : Dr. ARUN PRAKASH

OP Report No. : INVA2104920
Bill No. : INV2108805
Sample Date : 26/03/2022 - 03:46 PM
Report Date : 26/03/2022 - 05:06 PM

Test Name	Result	Units	Reference Interval
CLINICAL PATHOLOGY			
URINE SUGAR (PP)	NIL		
URINE ROUTINE			
COLOUR	PALE YELLOW		
APPEARANCE	CLEAR		
REACTION	ACIDIC		
SUGAR	NIL		
ALBUMIN	NIL		
DEPOSITES			
PUS CELLS	2 - 3	/ HPF	
EPI CELLS	2 - 3	/ HPF	
RBC COUNT	NIL	/ HPF	
CAST	NIL		
CRYSTALS	NIL		
OTHERS	NIL		

NITHYALAB

Verified by

*** End of Report ***



Healing Hearts and Lives

264/125, Kilpauk Garden Road, Kilpauk, Chennai - 600 010.
Phone : +91 44 4644 8989 / 75500 53335 | Email : muruganhosp@gmail.com
Website : www.muruganhospitals.in



MURUGAN HOSPITALS

HEALING HANDS



SCAN REPORT

NAME : MR.HERVIN PRAISON.T UHID NO : MH20220035814
AGE / SEX : 32/MALE IP / OP NO: OUTPATIENT
CONSULTANT: DR. ARUN PRAKASH DATE : 26.03.2022

ULTRA SOUND SCAN OF ABDOMEN

LIVER: Normal in size and measures- 13.6 cm and normal in echotexture. No focal lesions are seen. No dilatation of intra-hepatic biliary radicals present. Hepatic veins and IVC appear normal. Portal vein is normal in caliber. Common bile duct is normal in caliber.

GALL BLADDER: Contracted.

PANCREAS: Normal in size and echotexture. No focal lesions are seen. No evidence of calculi or calcifications. No evidence of pancreatic duct dilation.

PARA AORTIC AREAS: Aorta and IVC appear normal. No evidence of para aortic lymphadenopathy.

SPLEEN: Normal in size . Normal in echotexture. No evidence of focal lesions.

RIGHT KIDNEY: Measures 9.1 x 3.8 cm and is normal in size and echotexture. Cortico medullary differentiation is well maintained. There is no calculus or hydronephrosis or mass.

LEFT KIDNEY: Measures 8.9 x 4.9 cm and is normal in size and echotexture. Cortico medullary differentiation is well maintained. There is no or hydronephrosis or mass.

Healing Hearts and Lives

264/125, Kilpauk Garden Road, Kilpauk, Chennai - 600 010. Phone : +91 44 4644 8989 / 75500 53335

Email : muruganhosp@gmail.com | Website : www.muruganhospitals.in

URINARY BLADDER: Normal in size, contour and wall thickness. There is no evidence of calculus or mass. No vesical diverticulum present.


PROSTATE: Normal in size and echotexture. Measures 1.8 x 4.4 x 2.8 cm and approximate volume being 9.6 cc. Seminal vesicles appear normal.

No ascites present. No retroperitoneal lymphadenopathy present.

IMPRESSION:

- **No significant abnormality detected in the visualized organ**

Dr. SAKTHI, MDRD.
Consultant Radiologist.





MURUGAN HOSPITALS

HEALING HANDS



ECHO CARDIOGRAM REPORT

NAME : MR. HERVIN PRAISON .T

UHID NO: MH20220035814

AGE&SEX :32 Y /MALE

IP/OP : OUTPATIENT

CONSULTANT: DR.ARUN PRAKASH

DATE : 26-03-2022

2D PLAX (mm)

RV - 25 mm
AO - 26 mm
LA - 26 mm

COLOR DOPPLER

Normal

M-Mode (mm)

IVS - 09 mm
PW - 08 mm
LVD - 49 mm
LVS - 31 mm
EF - 65 %
FS - 36 %

DOPPLER (m/sec)

MITRAL E - 0.5 m/s
MITRAL A - 0.3 m/s
PULMONARY - 1.0 m/s
AORTIC - 0.8 m/s
TRICUSPID - 0.3 m/s

IMPRESSION:

No RWMA
Normal biventricular function
No pulmonary hypertension
No pericardial effusion
No clot/ Vegetation.



DR.SIDHARTHAN MD.,DM.,
CONSULTANT CARDIOLOGIST

Healing Hearts and Lives

264/125, Kilpauk Garden Road, Kilpauk, Chennai - 600 010.

Phone : +91 44 4644 8989 / 75500 53335 | Email : muruganhosp@gmail.com

Website : www.muruganhospitals.in

ID 2203260010
Name Mrs YAMINI
Sex Female
Divisions:

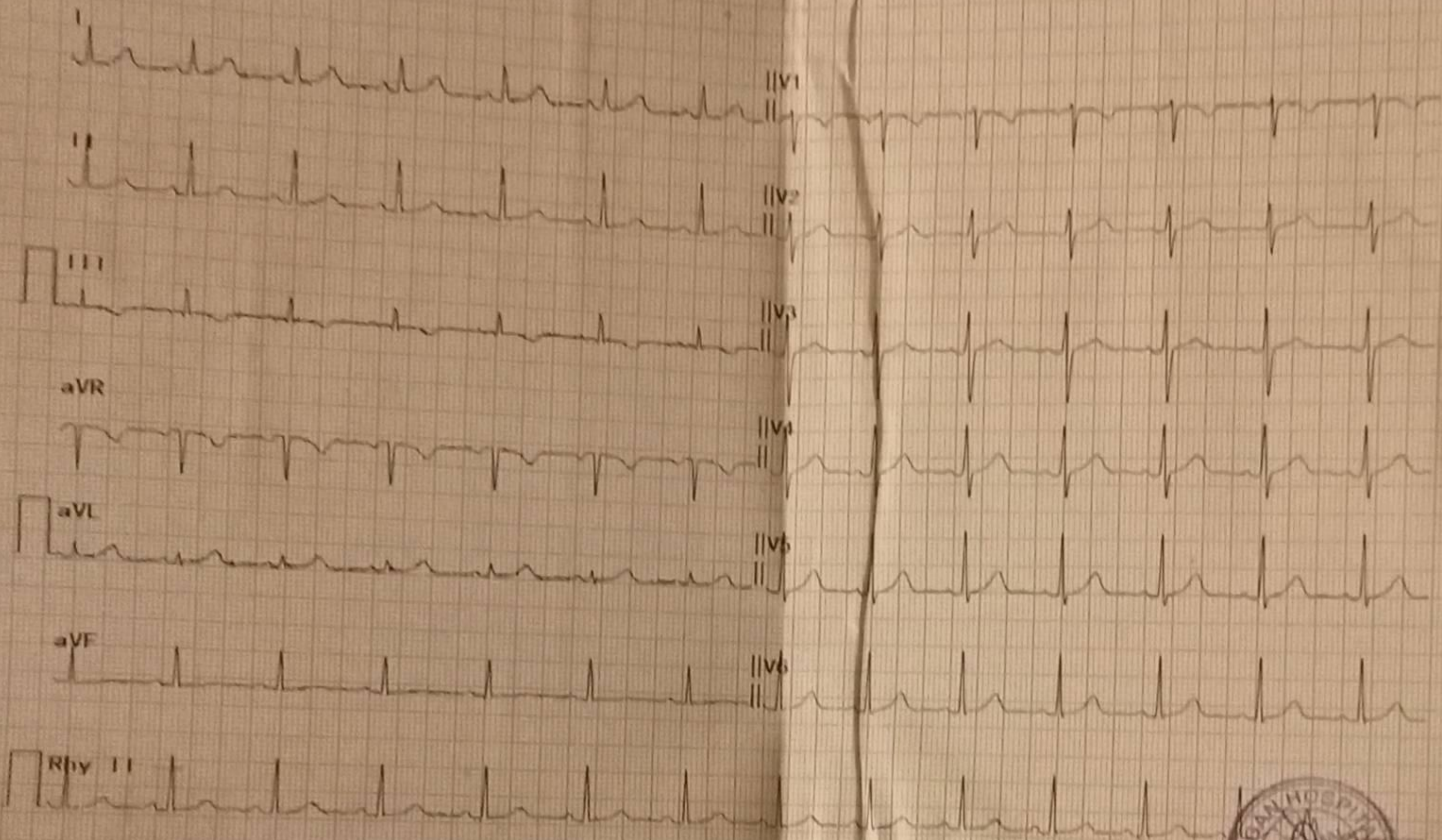
HR 86 bpm
P Dur PR int 89 131ms
QRS Dur 80 ms
QT QTc int 354 425 ms
P QRS T axis 36 46 11

Dateline: 2022-03-26 10:15
Age 30
BP 110/70 mmHg
Bed No.
RV5-SV1 amp 1.238 O. 723mV
RV5+SV1 amp 1.961mV
RV6-SV2 amp 1.200 O. 496mV

Hospital MURUGAN HOSPITALS
Height 150 cm
Weight 78 kg
Hospital No.

Minnesota Code

Diagnosis Info
800: Sinus Rhythm
Normal ECG



Diagnosis for reference, ask your doctor to confirm
AUTO PRINT 6X2+1R 86bpm 10 mm mV 0.50Hz-45Hz AC 60Hz 25 mm/sec Confirmed By:





MURUGAN HOSPITALS

HEALING HANDS



SCAN REPORT

NAME : Mr.T.HERVINPRAISON
AGE / SEX: 32 YEARS /MALE
CONSULTANT: DR. ARUN PRAKASH

UHID NO : MH20220035814
DATE : 26- 03- 2022
OP/IP :OUT PATIENT

CHEST XRAY PA VIEW

- Trachea is in midline.
- Hila appear Normal.
- Mediastinal shadow appears normal.
- Costophrenic&Cardiophrenic angles appear free.
- Cardiothoracic ratio is within normal limits.
- Lungs fields appear clear
- Bony thorax and soft tissue appear normal

IMPRESSION:

- No significant abnormality noted.



CONSULTANT RADIOLOGIST

Healing Hearts and Lives

264/125, Kilpauk Garden Road, Kilpauk, Chennai - 600 010. Phone : +91 44 4644 8989 / 75500 53335
Email : muruganhosp@gmail.com | Website : www.muruganhospitals.in



MURUGAN HOSPITALS

HEALING HANDS

Date : 26/03/2022

NAME OF PATIENT : **Mr.HERVIN PRAISON**

AGE : 32 / **MALE**

● Nil visual complaints

O/E

V/A

OD : 6/6 N6

OS : 6/6 N6

Within normal limits in both eyes.

IMPRESSION :

- Nil ophthalmic problem

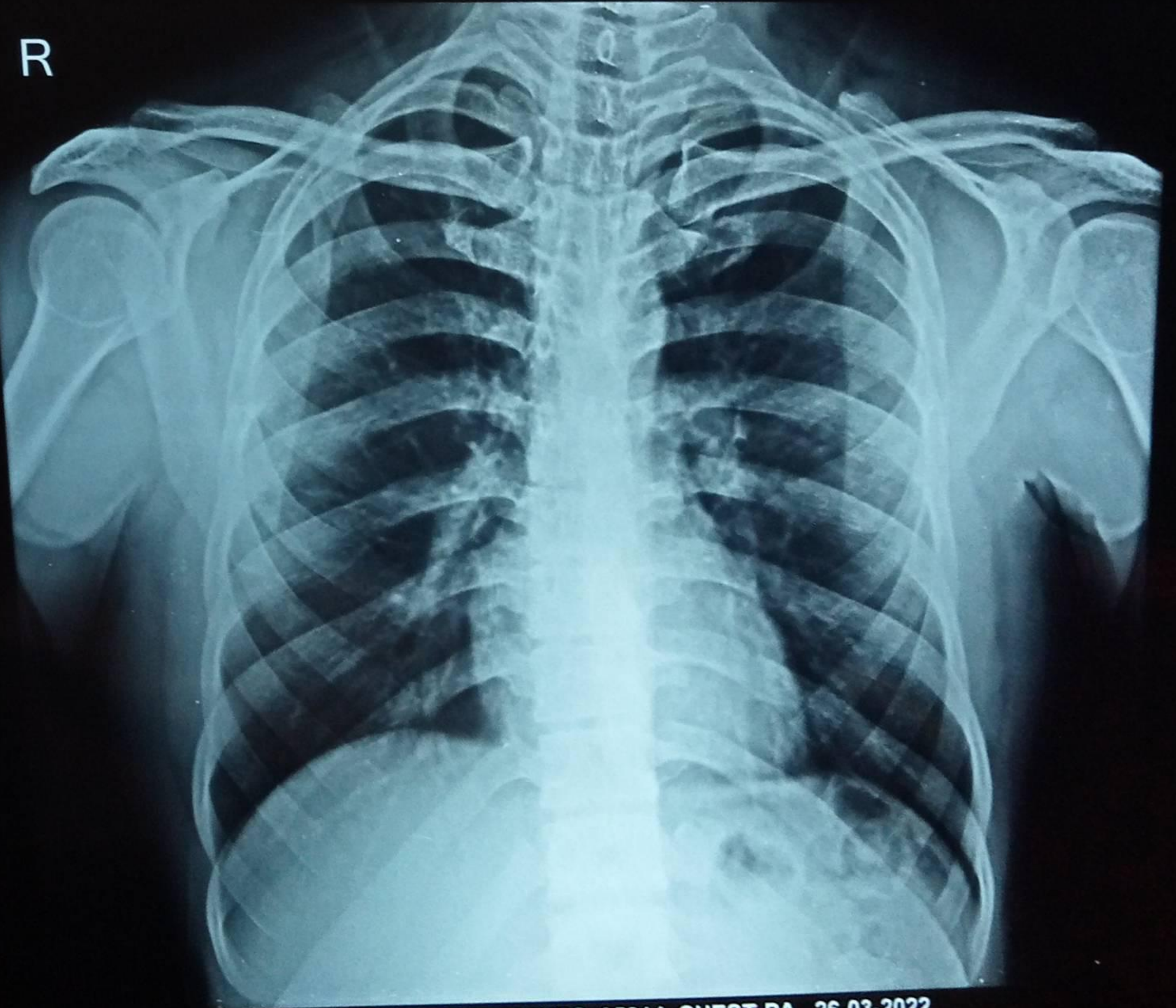

-Medical Officer

264/125, Kilpauk Garden Road, Kilpauk, Chennai - 600 010.

☎ : +91 44 4644 8989 / 75500 53335 email : muruganhosp@gmail.com

Website : www.muruganhospitals.in

R



MR.HERVIN PRAISON.T 32YRS 35814 CHEST-PA 26-03-2022

MURUGAN HOSPITALS, KILPAIK, CHENNAI 10 PH NO. 7550053335 / 4542885

