


 भारतीय विशिष्ट पहचान प्राधिकरण  
 Unique Identification Authority of India
 

पता:  
 C/O रमेश बाकरे, एच. नं. 367 प्रीमियम पार्क कालोनी,  
 जाख्या, इंदौर,  
 मध्य प्रदेश - 453111

Address:  
 C/O Ramesh Bakre, H. No. 367 Premium  
 Park Colony, Jakhaya, Indore,  
 Madhya Pradesh - 453111





**2573 1970 2669**  
 VID : 9123 2564 5811 1492

1947 | help@uidai.gov.in | www.uidai.gov.in

Mr. D. S. Ch...  
 M.J.  
 888 No





 भारत सरकार  
 Government of India
 
 आधार

अनुप बाकरे  
 Anup Bakre  
 जन्म तिथि/DOB: 23/07/1986  
 पुरुष/ MALE

Download Date: 19/09/2020  
 Issue Date: 31/12/2019

**2573 1970 2669**  
 VID : 9123 2564 5811 1492

मेरा आधार, मेरी पहचान

  
 8989550782

**DR. MAHENDRA CHOURASIYA**  
*M.D.,D.M.*  
**CONSULTANT CARDIOLOGIST**

**UNIQUE DIAGNOSTIC CENTRE**  
45-B, Jaora Compound,  
Opp. M.Y.Hospital, M.Y.H. Road,  
INDORE - 452 001. ( M. P. ).  
Phone : 2704118. 4082228

## **ECHOCARDIOGRAPHY REPORT**

**NAME** : **MR. ANUP BOKRE** **Age** : **36 Yrs./ M**  
**REFERRED BY** : **BOB** **Date** : **30th Mar, 2023**

### **ECHOCARDIOGRAPHIC OPINION**

**INTERPRETATION :-**

- \*\* Normal sized cardiac chambers.
- \*\* Normal biventricular functions. LVEF : 60 %.
- \*\* Normal cardiac valves.

*Dr. Mahendra Chourasiya*  
*M.D., D.M. (Cardio)*  
**DR. MAHENDRA CHOURASIYA. M.D.,D.M.**



---

## TWO DIMENSIONAL ECHOCARDIOGRAPHY

---

M Mode examination revealed normal movement of both mitral leaflets during diastole.

No SAM or mitral valve prolapse is seen.

Aortic cusps are not thickened and enclosure line is central.

Tricuspid valve is normal, pulmonary valve is normal, aortic root is normal in size, dimensions of left atrium and left ventricle are normal.

2 - D imaging in PLAX, SAX and apical views revealed a normal sized left ventricle.

Movement of septum, anterior, posterior, inferior and lateral walls is normal. Global LVEF is 60 %.

Mitral valve opening is normal. No evidence of mitral valve prolapse is seen.

Aortic valve has three cusps and its opening is not restricted.

Right atrium and right ventricle are normal in size.

Tricuspid valve leaflets move normally.

Pulmonary valve is normal.

Interatrial and interventricular septa are intact.

No intracardiac mass or thrombus is seen.

No pericardial pathology is observed.

## MEASUREMENTS :

[C] DIMENSIONS	OBSERVED VALUES	Normal Values (For Adults)
1. Aortic Root diameter	: 2.7 cms.	2.0-3.7 cm < 2.2 cm / M <sup>2</sup>
2. Aortic Valve Opening	: 2.0 cms.	1.5-2.6 cm
3. Right Ventricular Dimension	: --	
4. Left Atrial Dimension	: 2.9 cms.	1.9-4.0 cm < 2.2 cm / M <sup>2</sup>
5. Left Ventricular ED Dimension	: 3.6 cms.	3.7-5.6 cm < 3.2 cm / M <sup>2</sup>
6. Left Ventricular ES Dimension	: 2.0 cms.	2.2-4.0 cm
7. Inter Ventricular ED Septal thickness	: 1.2 cms.	0.6-1.2 cm
8. Left Ventricular ED PW thickness	: 1.2 cms.	0.5-1.0 cm
9. IVS / LVPW	: 01	< 1.3

[E] INDICES OF LEFT VENTRICULAR FUNCTION		
1. Mitral E - Septal Separation	: 0.5	< 0.9- cm
2. Left Ventricular Ejection Fraction	: 60 %	60 - 80 %



---

---

## DOPPLER

---

---

Peak Flow Velocity ( M/Sec.)		Peak Gradient ( mmHg.)	Regurgitation
MV	Normal	--	Normal
TV	Normal	--	Normal
AV	Normal	--	Normal
PV	Normal	--	Normal

PASP : Normal

\*\*\*\*\*

MR. ANUP BAKRE  
BANK OF BARODA36 Years /M  
30-03-2023**BIOCHEMISTRY**

Test Name	Results	Normal Range
SERUM BILIRUBIN	:-	
TOTAL BILIRUBIN	0.86	0 - 1 mg/dl
DIRECT BILIRUBIN	0.12	<0.25 mg/dl
INDIRECT BILIRUBIN	0.74	< 1.0 mg/dl
S.G.O.T	21.0	0 - 45 IU/L
S.G.P.T	29.0	0 - 45 IU/L
ALKALINE PHOSPHATE	83.0	Adult - 42 - 128 IU/L Child - 150 - 630 IU/L
TOTAL PROTEIN	6.32	6.0 to 8.0 g/dl
ALBUMIN	4.15	3.2 to 5.0 g/dl
GLOBULIN	2.17	1.9 to 3.5
A:G RATIO	1.91	1.2 TO 2.3
GAMA GT	18.0	5 - 43 Iu/l

Dr. POOJA PRAPANNA  
MD  
DR. POOJA PRAPANNA

M.D.

MR. ANUP BAKRE  
BANK OF BARODA36 Years /M  
30-03-2023**HEAMOGRAM**

Test Name	Results	Normal Range
Haemoglobin (HB)	14.0	13 - 18 gm%
R.B.C. Count	4.97	4.5 - 5.5 milli./cu.mm
PCV	44.0	40 - 50 %
MCV	88.53	80 - 95 fl
MCH	28.17	27 - 32 pg
MCHC	31.82	31.5 - 34.5 %
TOTAL WBC COUNT	6,200	4,000 to 11,000 /cu.mm
DIFFERENTIAL WBC COUNT	.	
Neutrophils	56	40 - 75 %
Lymphocytes	38	20 - 40 %
Monocytes	04	02 - 08 %
Eosinophils	02	01 - 05 %
Basophils	00	00 - 01 %
PLATELET COUNT	3.66	1.5 - 4 Lacs/cu.mm.
E.S.R	12	M- 0-10 at the end of 1 hr. F- 0-20 at the end of 1 hr

Note :- All pathological tests have technical and biological limitations. Please correlate clinically as well as with other investigative findings.  
A review should be requested in case of any disparity. This report is not valid for medicolegal purpose.

Dr. POOJA PRAPANNA  
DR. POOJA PRAPANNA  
M.D.

4D SONOGRAPHY • COLOR DOPPLER • ECHO • PATHOLOGY • DIGITAL X-RAY &amp; OPG • TMT • ECG • HOLTER

**MR. ANUP BAKRE**  
**BANK OF BARODA****36 Years /M**  
**30-03-2023**

Test Name	Results	Normal Range
	<b><u>BIOCHEMISTRY</u></b>	
URIC ACID	4.56	3.5 - 7 mg/dl
BUN	10.0	5 - 21 Mg/dl

**DR. POOJA PRAPANNA**  
**DR. POOJA PRAPANNA**  
M.D.

Note :- All pathological tests have technical and biological limitations. Please correlate clinically as well as with other investigative findings.  
A review should be requested in case of any disparity. This report is not valid for medicolegal purpose.



MR. ANUP BAKRE  
BANK OF BARODA36 Years /M  
30-03-2023

Test Name	Results	Normal Range
-----------	---------	--------------

**HAEMATOLOGY PROFILE**

BLOOD GROUP	: -
"ABO " GROUP	"A"
Rh (D) Factor	Positive
	.
	.
(Cross matching & recheck of Blood Group is mandatory before any transfusion)	.

**SEROLOGY PROFILE**

HBsAg	Non Reactive
	.
	.
* Test done by screening methods. Requires confirmation at referral centre.	.

**BIOCHEMISTRY**

FASTING BLOOD SUGAR	75.0	70 - 110 mg/dl
P.P. BLOOD SUGAR	83.0	upto 140 mg/dl
CREATININE	0.98	0.6 - 1.4 mg\dl

Dr. POOJA PRAPANNA  
DR. POOJA PRAPANNA M.D.  
M.D.

Note :- All pathological tests have technical and biological limitations. Please correlate clinically as well as with other investigative findings. A review should be requested in case of any disparity. This report is not valid for medicolegal purpose.

MR. ANUP BAKRE

36 Years /M

BANK OF BARODA

30-03-2023

**LIPID PROFILE**

Test Name	Results	Normal Range
TOTAL LIPIDS	489	400 - 700 mg/dl
CHOLESTROL	161.0	<200 mg/dl- Desirable 200 - 239 mg/dl - Borderline High >240 Mg/dl High
HDL CHOLESTROL	40.0	35- 60 mg/dl
TRIGLYCERIDE	117.0	<150 mg/dl Normal 150 - 199 mg/dl Borderline High 200 - 499 mg/dl High
LDL CHOLESTROL	97.6	<100 mg/dl Optimal 100- 129 mg/dl Borderline high 160 - 189 mg/dl High
VLDL CHOLESTROL	23.4	<40 mg/dl
RISK RATIO	4.03	3 - 6

**DR. POOJA PRAPANNA**  
DR. POOJA PRAPANNA MD

M.D.

Note :- All pathological tests have technical and biological limitations. Please correlate clinically as well as with other investigative findings.  
A review should be requested in case of any disparity. This report is not valid for medicolegal purpose.

MR. ANUP BAKRE

36 Years /M

BANK OF BARODA

30-03-2023

**URINE EXAMINATION**

Test Name	Results	Normal Range
<b>PHYSICAL EXAMINATION</b>		
Quantity	30 ml	
Colour	Pale Yellow	
Appearance	Clear	
Deposits	Absent	
Specific Gravity	1.015	
Reaction	Acidic	
<b>CHEMICAL EXAMINATION</b>		
Albumin	Nil	
Sugar	Nil	
Ketones	Absent	
Bile Pigments	Negative	
Bile Salt	Negative	
Hematuria	Negative	
<b>MICROSCOPIC EXAMINATION</b>		
Pus Cells	1- 2 /hpf	
Red Blood Cells	Nil/hpf	
Epithelial Cell	1 - 2 /hpf	
Crystals	Nil	
Casts	Absent	

**DR. POOJA PRAPANNA**  
DR. POOJA PRAPANNA MD

M.D.

Note :- All pathological tests have technical and biological limitations. Please correlate clinically as well as with other investigative findings.  
A review should be requested in case of any disparity. This report is not valid for medicolegal purpose.

4D SONOGRAPHY • COLOR DOPPLER • ECHO • PATHOLOGY • DIGITAL X-RAY & OPG • TMT • ECG • HOLTER

MR. ANUP BOKRE

36 Yrs./M.

BOB

30th Mar, 2023

X-RAY CHEST PA VIEW

Bony cage is normal.

Trachea is central.

C.P. angles are clear.

Cardiac contour and cardiothoracic ratio are normal.

Lung fields are clear.

**DR.D.S.CHHABRA.**

M.D.

MR. ANUP BOKRE

36 Yrs./M.

BOB

30th Mar, 2023

ABDOMINAL SONOGRAPHY

Liver is of normal size, shape, has smooth margins & regular contours and the parenchyma is mildly hyperechoic in echostructure, **early fatty changes**. No focal lesion.

Gall bladder is of normal size, shape, has thin walls & the contents are clear fluid. Few small ( around 2.5 mms. ), **Polyyps** are seen. No evidence of any calculus. Biliary tree is undilated.

Pancreas is normal, no focal / diffuse pathology. Spleen is normal.

Both Kidneys are normal in size [ measure about 10.5 cms. in length ], shape and echostructure. No calculus in both. The collecting system and ureter on both side are undilated.

Urinary bladder is normal in size, shape & has thin walls.

Prostate is of normal size ( around 16 gms.) & is normal in echostructure.

There is no ascitis. No obvious abdominal lymphadenopathy. No sub / supra diaphragmatic pathology on either side.

IMPRESSION :

Early fatty changes in liver.



DR.D.S.CHHABRA.

M.D.



## LABORATORY REPORT



Name : <b>Mr. ANUP BAKRE</b>	Sex/Age : <b>Male / 36 Years</b>	Case ID : <b>30301607396</b>
Ref. By :	Dis. At :	Pt. ID :
Bill. Loc. : <b>UNIQUE DIAGNOSTIC CENTRE INDORE</b>		Pt. Loc. :
Reg Date and Time : <b>30-Mar-2023 11:28</b>	Sample Type : <b>Serum</b>	Mobile No. :
Sample Date and Time : <b>30-Mar-2023 11:28</b>	Sample Coll. By : <b>non</b>	Ref Id1 :
Report Date and Time : <b>30-Mar-2023 12:28</b>	Acc. Remarks : <b>-</b>	Ref Id2 :

TEST	RESULTS	UNIT	BIOLOGICAL REF RANGE	REMARKS
<b>Thyroid Function Test</b>				
<b>Triiodothyronine (T3)</b> <small>CMIA</small>	<b>119.61</b>	ng/dL	58 - 159	
<b>Thyroxine (T4)</b> <small>CMIA</small>	<b>7.9</b>	µg/dL	4.6 - 10.5	
<b>TSH</b> <small>CMIA</small>	<b>0.969</b>	µIU/mL	0.4 - 4.2	

### INTERPRETATIONS

- Circulating TSH measurement has been used for screening for euthyroidism, screening and diagnosis for hyperthyroidism & hypothyroidism. Suppressed TSH (<0.01 µIU/mL) suggests a diagnosis of hyperthyroidism and elevated concentration (>7 µIU/mL) suggest hypothyroidism. TSH levels may be affected by acute illness and several medications including dopamine and glucocorticoids. Decreased (low or undetectable) in Graves disease. Increased in TSH secreting pituitary adenoma (secondary hyperthyroidism), PRTN and in hypothalamic disease thyrotropin (tertiary hyperthyroidism). Elevated in hypothyroidism (along with decreased T4) except for pituitary & hypothalamic disease.
- Mild to modest elevations in patient with normal T3 & T4 levels indicates impaired thyroid hormone reserves & incipient hypothyroidism (subclinical hypothyroidism).
- Mild to modest decrease with normal T3 & T4 indicates subclinical hyperthyroidism.
- Degree of TSH suppression does not reflect the severity of hyperthyroidism, therefore, measurement of free thyroid hormone levels is required in patient with a suppressed TSH level.

### CAUTIONS

Sick, hospitalized patients may have falsely low or transiently elevated thyroid stimulating hormone. Some patients who have been exposed to animal antigens, either in the environment or as part of treatment or imaging procedure, may have circulating antianimal antibodies present. These antibodies may interfere with the assay reagents to produce unreliable results.

### TSH ref range in Pregnancy

First trimester  
Second trimester  
Third trimester

### Reference range (microIU/ml)

0.24 - 2.00  
0.43-2.2  
0.8-2.5

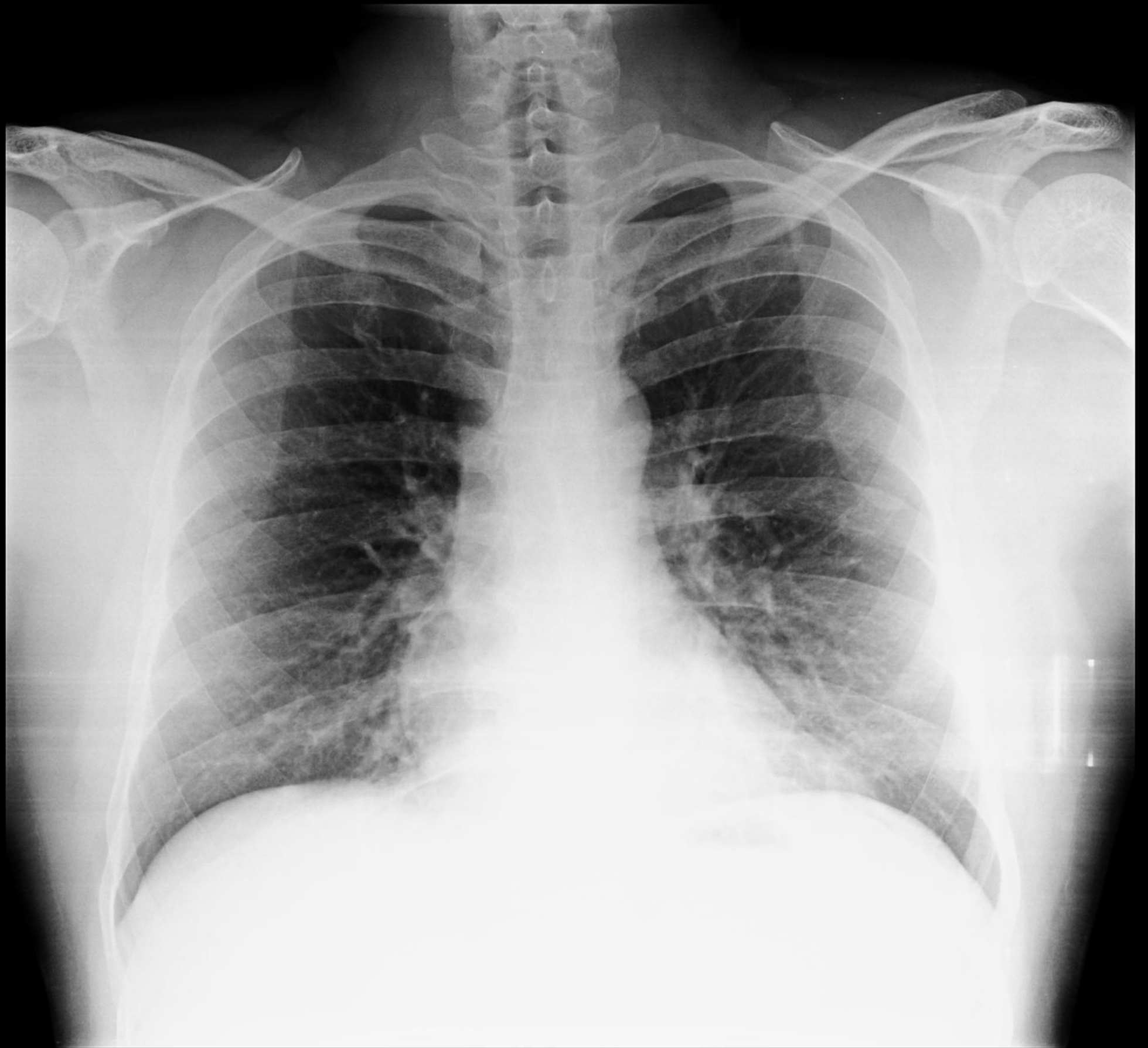
Note:(LL-VeryLow,L-Low,H-High,HH-VeryHigh ,A-Abnormal)

**Dr. Soma Yadav**  
M.D. (Pathology)

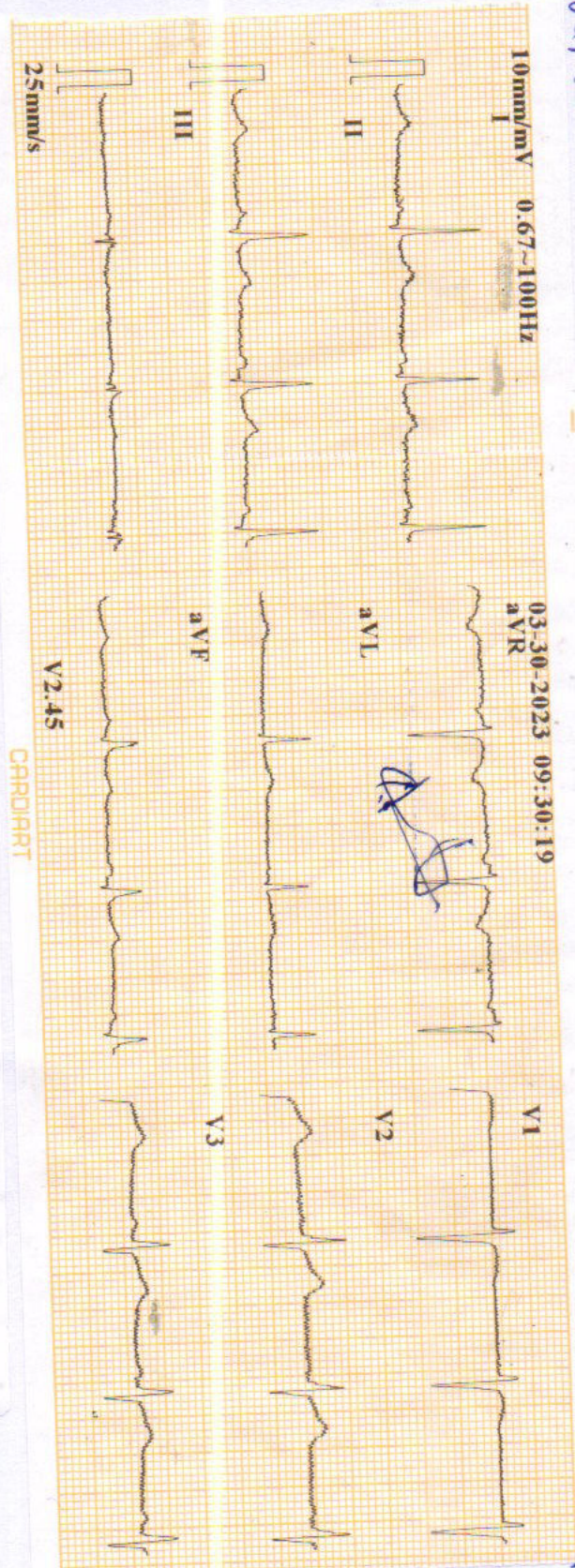
**Dr. A Mishra**  
M.D. Microbiology

Page 1 of 2

Printed On : 30-Mar-2023 12:38



NAME NR ANUP BALEME AGE 36/M Date 30/08/2023




**BPL**

ID	: 230330-0931	Minnesota Code:	9-4-1(V3)
Name	:		
Age	: 36 yr		
Sex	: Male		
BP	:	mmHg	
Height	:	cm	
Weight	:	kg	
HR	: 75 bpm		
P Dur	: 86 ms		
PR int	: 135 ms		
QRS Dur	: 90 ms		
QT/QTc int	: 346/387 ms		
P/QRS/T axis	: 57/38/38 °		
RV5/SV1 amp	: 1.451/1.026 mV		
RV5+SV1 amp	: 2.477 mV		
RV6/SV2 amp	: 1.326/0.553 mV		

Report Confirmed by: *M*

Diagnosis Information:  
800: Sinus Rhythm  
\*\*\*\*Normal ECG\*\*\*\*



*M*  
Dr. Mahendra Chourasiya  
M.D., D.M. (Cardio)



30 Mar 2023

Name : MR. ANUP BOKRE

Age : 36 Yrs./M

# UNIQUE DIAGNOSTIC CENTRE INDORE

Done by : DR. MAHENDRA CHOURASIYA

Ref. by : E  
M.D...

