

Health Check up Booking Request(bobE39592), Beneficiary Code-49320

1 message

Mediwheel <wellness@mediwheel.in>  
To: vidhidiagnostics@gmail.com  
Cc: customercare@mediwheel.in

22 May 2023 at 17:51



011-41195959

Email:wellness@mediwheel.in

Dear VIDHI DIAGNOSTICS,

City : Ahmedabad . Address : L-86 Swatantra - Senani Nagar , Opp- Akhbarnagar Bus Terminals, New Wadaj , Ahmedabad -13,

We have received the confirmation for the following booking .

Name : MS. TIWARI SHRUTI  
 Age : 32  
 Gender : Female  
 Package Name : Medi-Wheel Metro Full Body Health Checkup Female Below 40  
 User Location : ,AHMEDABAD,Gujarat,380028  
 Contact Details : 7987603621  
 Booking Date : 22-05-2023  
 Appointment Date : 27-05-2023

Member Information			
Booked Member Name	Age	Gender	Cost(In INR)
MS. TIWARI SHRUTI	32	Female	Cashless
Total amount to be paid			Cashless

We will get back to you with confirmation update shortly. Please find the package details as attached for your reference.

Package Name : Medi-Wheel Metro Full Body Health Checkup Female Below 40 - Includes (37)Tests

Tests included in this Package : Ecg, TSH, X-ray Chest, Stress Test (tmt)/ 2d Echo, Blood Sugar Postprandial, A:g Ratio, Blood Group, Total Cholesterol, Triglycerides, Fasting Blood Sugar, Ultrasound Whole Abdomen , Glycosylated Haemoglobin (hba1c), Hdl, Vldl, Urine Analysis, LDL, Total Protine, General Consultation, HDL/ LDL ratio, GGT(Gamma-glutamyl Transferase), Eye Check-up consultation, ALP (ALKALINE PHOSPHATASE), Uric Acid, AST/ALT Ratio, Serum Protein, CBC with ESR, Stool Analysis, Urine Sugar Fasting, Urine Sugar PP, T3, T4, Cholesterol Total / HDL Ratio, BUN, BUN/Creatinine Ratio, Bilirubin Total & Direct and Indirect, Albumin, Globulin



Medical Examination Report

Date : 10/06/2023

1. Personal Particulars

Name : Shweta Tivedani

Age : 34 years

Gender : ~~Male~~ / Female

Marital Status : Married

Past & Present Medical History : H/o Piles operated in 2017  
- surgical amputation of Lt thumb & index finger  
: due to electric shock at age of 10 months

2. Clinical Medical Examination

Height : 154 cm

Weight : 69 kg

Blood Pressure : 128/82 mmHg

Pulse : 86 p/min

General Condition :

Skin :

Central Nervous System :

Head & Neck :

Cardiovascular System :

Chest :

Abdomen :

Limbs :

Last menstrual period : 10/05/2023

Vision: : Right: 6/6  
N/6

Left: 6/6 with specs  
N/6

Colour vision : Normal/Colour Blind

Personal Habit : NO

Remarks : Fit / ~~Unfit~~ for employment

Dr. Vidhi D. Modh  
MBBS

Dr's name, signature & phone no. - 74540

Vidhi Diagnostics  
L-86, Swatantra-Senani Nagar,  
Opp. Akhbarnagar Bus Terminals,  
Nr. Akhbarnagar Circle,  
New Wadaj, Ahmedabad-13.



ID: 9615  
Name: shruti tiwari  
Age: 34yrs  
Sex: Female  
Hospital:  
Department:

**Dr. Avinash Bhaskar**  
MBBS, D-Cardio  
REG. No.: G-45946

HR : 89 bpm  
PR : 142 ms  
QRS : 90 ms  
QT/QTc : 332/404 ms  
P/QRS/T : 47/73/57 deg.  
RV5/SV1 : 1.139/-0.765 mv  
RV5+SV1 : 1.904 mv

<< Analysis Result >>

\*\* normal ECG \*\*

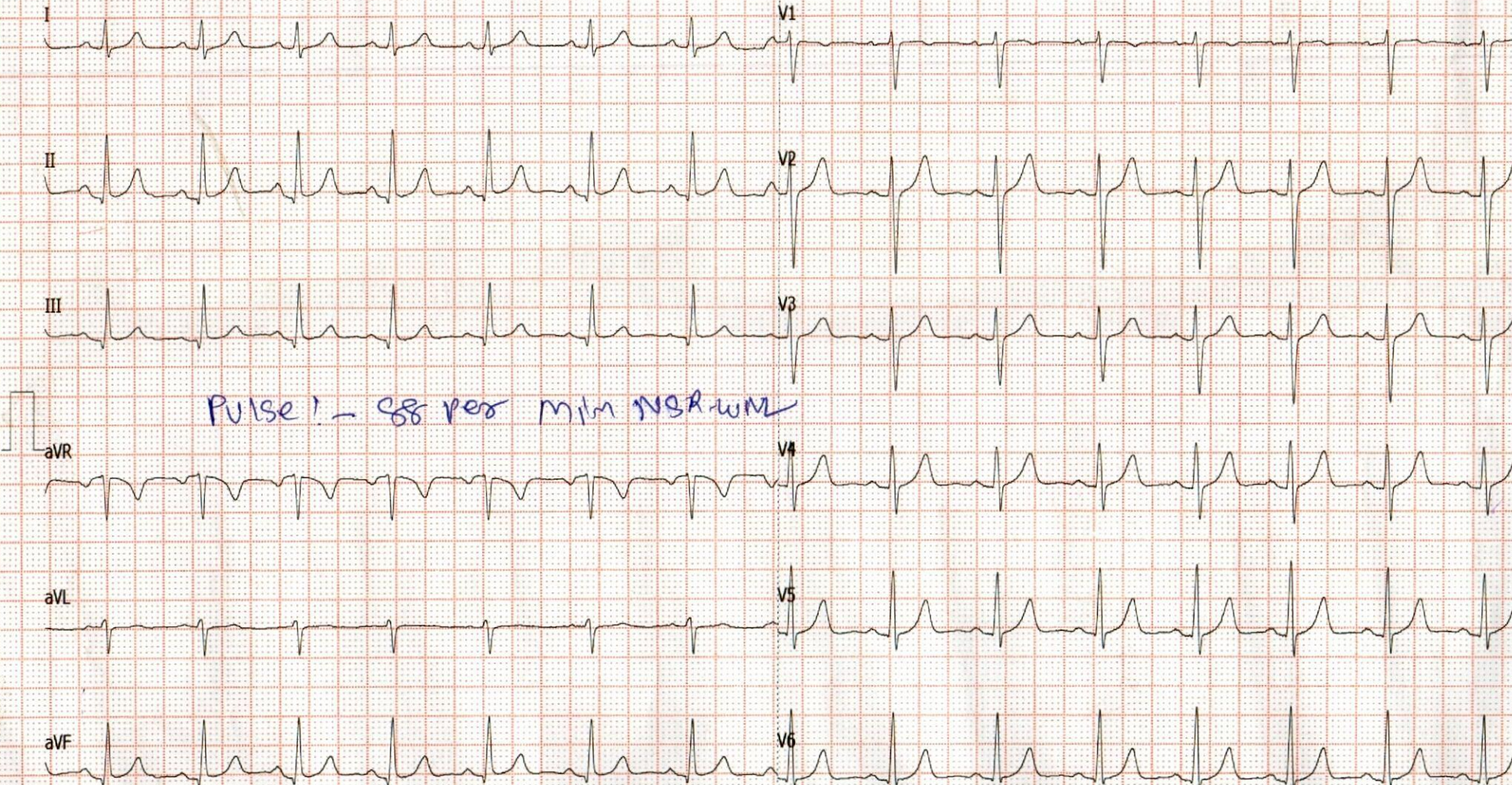
Sinus rhythm

**Vidhi Diagnostics**

Swatantra-Senani Nagar,  
Akhbaragar Bus Terminals,  
nr. Akhbaragar Circle,  
New Wadaj, Ahmedabad-13.

Need to be confirmed by doctor. Doctor Name: \_\_\_\_\_

0.67Hz - 35Hz AC 50Hz 25 mm/s 10 mm/mv





## Dr. Dinesh S. Modh

M.D., D.M.R.E. (Radiodiagnosis)

Consultant Radiologist & Sonologist

Ex. Junior Lecturer, B.J. Medical College, Civil Hospital, A'bad.

Panel Doctor of L.I.C.



Patient's name : SHRUTI TIWARI

Reg. ID : R-2864-23

Referred by : Dr. MEDIWHEEL

Age/Sex : 34 Years/Female

Accession : 7138

Date : 10/06/2023

### X-RAY CHEST (PA VIEW)

Both lung fields appear normal.  
No e/o consolidation or cavitations is seen.  
Both costo-phrenic angles appear clear.  
Cardiac size is within normal limits.  
Both domes of diaphragm appear normal.  
Bony thoracic cage appears normal.

Thanks for reference.

Dr. Dinesh S. Modh

M.D. (RADIATION PHYSICS)

M.D. DMRE (RADIODIAGNOSIS)

ISO 9001:2015 Certified Diagnostics Center

Vidhi Imaging Center

L-86, Swatantra Senani Nagar, Opp. Indian Oil Petrol Pump, Akhbar Nagar Circle, Nava Vadaj, Ahmedabad - 380 013.

Phone : (Radiology) 079-2762 1406 | M. 98799 29406, 98250 09406 | Time (Radiology) : Mon. to Sat. 9 am to 2 pm, 5 to 9 pm, Sunday 9 am to 12 Noon

E-mail : vidhidiagnostics@gmail.com, Website : www.vidhidiagnostics.com

Multislice CT Scan | CBCT-Dental Scan | Live 3D-4D Sonography | Colour Doppler | Echo Cardiography | Interventional Radiology | Maxillofacial Radiology | Fetal Medicine  
Digital X-Ray | Digital Mammography | Digital OPG/TMJ | ECG/TMT/PFT/EEG/EMG | Audiometry | Pathology Laboratory | Health Check Up Plans | Pre Employment Check Up

**CT SCAN & CBCT FACILITY NOW AVAILABLE**



## Dr. Dinesh S. Modh

M.D., D.M.R.E. (Radiodiagnosis)  
Consultant Radiologist & Sonologist  
Ex. Junior Lecturer, B.J. Medical College, Civil Hospital, A'bad.  
Panel Doctor of L.I.C.



Patient's name: SHRUTI TIWARI  
Reg. ID : R-2864-23  
Referred by : Dr. MEDIWHEEL

Age/Sex : 34 Years/Female  
Accession : 7138  
Date : 10/06/2023

### USG ABDOMEN

LIVER: - Liver appears normal in size & show normal echotexture. No evidence of diffuse or focal lesion is seen. Intrahepatic biliary radicals appear normal. Portal vein and CBD appear normal. No e/o calculus is seen in bile duct.

GALL BLADDER: - Gall bladder is distended & appears normal. No evidence of calculus or cholecystitis is seen. No evidence of pericholecystic fluid is seen.

SPLEEN: - Spleen appears normal in size & shows normal echotexture. No evidence of diffuse or focal lesion is seen.

PANCREAS: - Pancreas appears normal size and echopattern. No e/o diffuse or focal lesion is seen. Main pancreatic duct appears normal.

KIDNEY: - Both Kidneys appear normal in size & echotexture.

No e/o calculus or hydronephrosis or hydroureter is seen in either side.

Cortico-medullary differentiation is maintained on either side.

Both suprarenal regions appear normal.

RIF & BOWEL LOOPS (By high frequency probe): - Normal.

No evidence of pre & para aortic lymphadenopathy is seen.

No evidence of free fluid is seen in abdomen.

No evidence of dilated or thickened bowel loops is seen.

Urinary bladder: - appears normal. No e/o calculus or mass lesion is seen in bladder.

Uterus appears normal in size and echopattern.

No evidence of diffuse or focal lesion is seen.

Cervical region appears normal.

Endometrial thickness is 6.4mm.

Both ovaries and adnexal regions appear normal.

No e/o free fluid is seen in pouch of Douglas.

Thanks for reference.

Dr. Dinesh S. Modh

MD DMRE (Radiodiagnosis)

R-2864-23  
DR DINESH S. MODH

M.D. DMRE(RADIODIAGNOSIS)

ISO 9001:2015 Certified Diagnostics Center

Vidhi Imaging Center

L-86, Swatantra Senani Nagar, Opp. Indian Oil Petrol Pump, Akharnagar Circle, Nava Vadaj, Ahmedabad - 380 013.

Phone : (Radiology) 079-2762 1406 | M. 98799 29406, 98250 09406 | Time (Radiology) : Mon. to Sat. 9 am to 2 pm, 5 to 9 pm, Sunday 9 am to 12 Noon

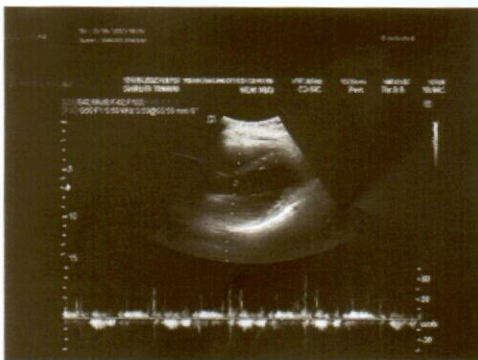
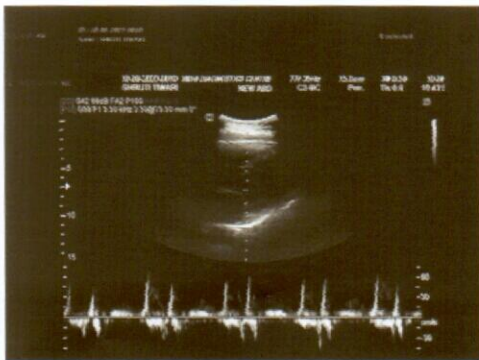
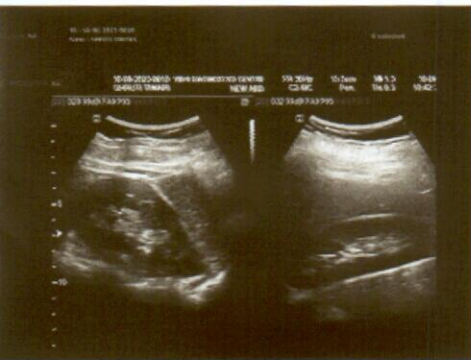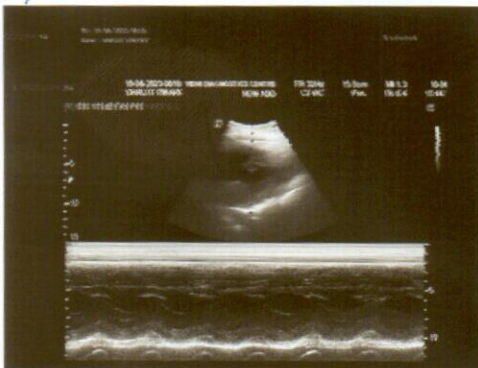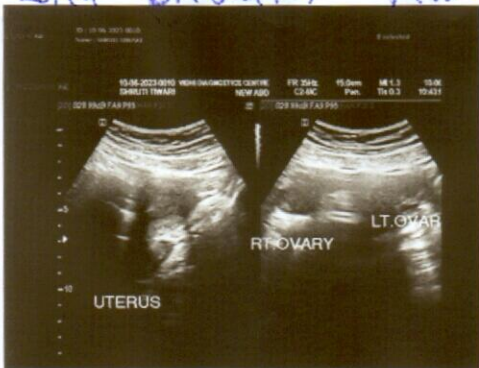
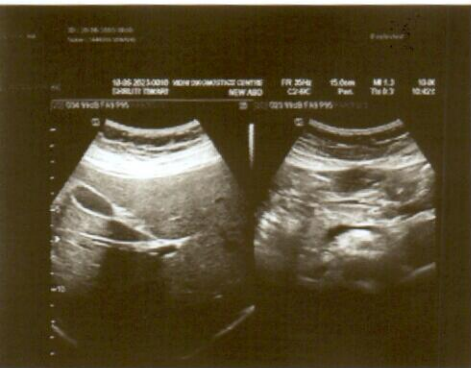
E-mail : vidhidiagnostics@gmail.com, Website : www.vidhidiagnostics.com

Multislice CT Scan | CBCT-Dental Scan | Live 3D-4D Sonography | Colour Doppler | Echo Cardiography | Interventional Radiology | Maxillofacial Radiology | Fetal Medicine  
Digital X-Ray | Digital Mammography | Digital OPG/TMJ | ECG/TMT/PFT/EEG/EMG | Audiometry | Pathology Laboratory | Health Check Up Plans | Pre Employment Check Up

**CT SCAN & CBCT FACILITY NOW AVAILABLE**



Star Shouti Twardzi



# Dr. Dinesh S. Modh

M.D., D.M.R.E. (Radiodiagnosis)

Consultant Radiologist & Sonologist

Ex. Junior Lecturer, B.J. Medical College, Civil Hospital, A'bad.

Panel Doctor of L.I.C.



Patient's name : SHRUTI TIWARI  
Reg. ID : R-2864-23  
Referred by : Dr. MEDIWHEEL

Age/Sex : 34 Years/Female  
Accession : 7138  
Date : 10/06/2023

## 2D- ECHO REPORT

### FINAL CONCLUSION:

LV IS NORMAL SIZE. GOOD LV SYSTOLIC FUNCTION NO RWMA.  
LVEF - 60%. NO CONCENTRIC LVH.  
NORMAL LV COMPLIANCE.  
LA IS NORMAL SIZE. NO LA CLOT.  
RV IS NORMAL SIZE. GOOD RV SYSTOLIC FUNCTION.  
RA IS NORMAL SIZE.  
MITRAL VALVE IS NORMAL. NO MS. MILD MR (15%). NO MVP.  
AORTIC VALVE IS NORMAL. NO AS. NO AR.  
TRICUSPID VALVE IS NORMAL. NO TR. RVSP-26 mmHg. NO PAH.

NO CLOT, NO VEGETATION, NO PERICARDIAL EFFUSION.

### DIMENSIONS:

AORTA	2.6 C.M
LEFT ATRIUM	2.7 C.M
LVDD	4.1 C.M.
IVSD	1.0 C.M
PWD	1.0 C.M
LVDS	2.6 C.M.

### COLOUR DOPPLER FINDING:

STRUCTURE	VELOCITY m/sec
	Max
PULMONARY VALVE	0.7
MITRAL VALVE	E : 0.7 A: 0.4
AORTIC VALVE	1.0

Dr. Avinash Bhaskar  
MBBS, D Cardiac  
DR. AVINASH BHASKAR

ISO 9001:2015 Certified Diagnostics Center

Vidhi Imaging Center

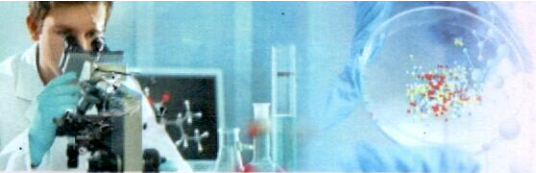L-86, Swatantra Senani Nagar, Opp. Indian Oil Petrol Pump, Akhbar Nagar Circle, Nava Vadaj, Ahmedabad - 380 013.

Phone : (Radiology) 079-2762 1406 | M. 98799 29406, 98250 09406 | Time (Radiology) : Mon. to Sat. 9 am to 2 pm, 5 to 9 pm, Sunday 9 am to 12 Noon  
E-mail : vidhidiagnostics@gmail.com, Website : www.vidhidiagnostics.com

Multislice CT Scan | CBCT-Dental Scan | Live 3D-4D Sonography | Colour Doppler | Echo Cardiography | Interventional Radiology | Maxillofacial Radiology | Fetal Medicine  
Digital X-Ray | Digital Mammography | Digital OPG/TMJ | ECG/TMT/PFT/EEG/EMG | Audiometry | Pathology Laboratory | Health Check Up Plans | Pre Employment Check Up

**CT SCAN & CBCT FACILITY NOW AVAILABLE**





Pathology Department



Patient's name : SHRUTI TIWARI  
Age/Sex : 34 Years/Female  
Referred by : Dr. MEDIWHEEL  
Collection Time : 10:30

Reg. ID : P-1304-23  
Accession : 7133  
Order Dt/time : 10/06/2023 10:30

### Complete Blood Count

Sample Type: EDTA

Test Name	Result	Units	Biological Reference Interval
<b><u>Blood Counts</u></b>			
Haemoglobin :	<b>9.0</b>	Gms%	12.5 - 16.0
Total R.B.C. :	4.32	mill/c.mm	4.2 - 5.4
Total W. B. C. :	6830	/cu mm	4000 - 10500
Platelet Count :	374000	/cu.mm	1,50,000 - 4,50,000
<b><u>Differential Count</u></b>			
Neutrophils :	59	%	40 - 70
Lymphocytes :	36	%	20 - 40
Eosinophils :	03	%	1 - 4
Monocytes :	02	%	2 - 6
Basophils :	00	%	0 - 01
<b><u>Blood Indices</u></b>			
P. C. V :	<b>28.6</b>	%	37 - 47
M. C. V. :	<b>66.3</b>	fl	78 - 100
M.C.H :	<b>20.9</b>	pg	27 - 31
M. C. H. C :	<b>31.5</b>	%	32 - 36
R.D.W :	<b>15.7</b>	%	11.5 - 14.0

### E.S.R.( Westergren Method )

After one hour : 10 mm/hr 3 - 12

TESTS DONE ON FULLY AUTOMATED HEMATOLOGY ANALYZER.

*Dr. Gayatri M. Mehta*  
M. D. (Patho)  
DR GAYATRI MEHTA  
MD(PATHOLOGY) G-32210

DR. ANAND D. PARIKH  
MD(PATHOLOGY)

LAB USE ONLY (Entered by :GM Enter Date/Time:10/06/2023 3:20:00 PM) (Verify by :GM Verify Date/Time:10/06/2023 3:20:00 PM)



Vidhi Imaging Center | Pathology Department

L-86, Swatantra Senani Nagar, Opp. Akhbarnagar Petrol Pump, Nr. Akhbarnagar Circle, Nava-Vadaj, Ahmedabad - 380 013.

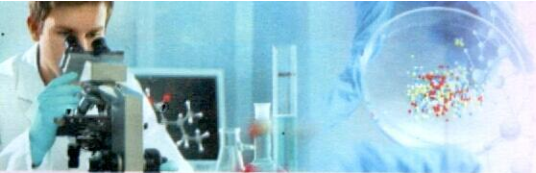Ph. (Pathology) : 8849893954 M. 98799 29406, 98250 09406, E-mail : vidhidiagnostics@gmail.com, Web. : www.vidhidiagnostics.com

Time (Pathology) : Mon. to Sat. 8.30 am to 8.00 pm, Sunday 9 am to 12 Noon

*Pathology means science behind medicine*

**CT SCAN & CBCT FACILITY NOW AVAILABLE**





Pathology Department

**VIDHI**<sup>®</sup>  
**DIAGNOSTICS**

Creating life in Punjab

Patient's name : SHRUTI TIWARI  
Age/Sex : 34 Years/Female  
Referred by : Dr. MEDIWHEEL  
Collection Time : 10:30

Reg. ID : P-1304-23  
Accession : 7133  
Order Dt/time : 10/06/2023 10:30

### Blood Group

Sample Type: EDTA sample.

Test Name	Result
BG :	" O "
RH :	POSITIVE
Remarks	Done by forward grouping method.

*Dr. Gayatri M. Mehta*

M. D. (Patho)

Reg. No. G-32215

DR GAYATRI MEHTA  
MD(PATHOLOGY)

DR. ANAND D. PARIKH  
MD(PATHOLOGY)

LAB USE ONLY (Entered by :GM Enter Date/Time:10/06/2023 3:27:00 PM) (Verify by :GM Verify Date/Time:10/06/2023 3:27:00 PM)



Vidhi Imaging Center | Pathology Department

L-86, Swatantra Senani Nagar, Opp. Akhbarnagar Petrol Pump, Nr. Akhbarnagar Circle, Nava-Vadaj, Ahmedabad - 380 013.

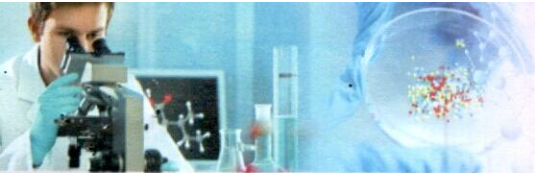Ph. (Pathology) : 8849893954 M. 98799 29406, 98250 09406, E-mail : vidhidiagnostics@gmail.com, Web. : www.vidhidiagnostics.com

Time (Pathology) : Mon. to Sat. 8.30 am to 8.00 pm, Sunday 9 am to 12 Noon

*Pathology means science behind medicine*

**CT SCAN & CBCT FACILITY NOW AVAILABLE**





Patient's name : SHRUTI TIWARI  
Age/Sex : 34 Years/Female  
Referred by : Dr. MEDIWHEEL  
Collection Time : 10:30

Reg. ID : P-1304-23  
Accession : 7133  
Order Dt/time : 10/06/2023 10:30

**Blood Glucose**

Sample Type: Serum

Test Name	Result	Units	Biological Reference Interval
Fasting Blood Glucose : <i>GOD-POD Method.</i>	86.2	mg/dl	70 - 110

**Blood Glucose**

Sample Type: Serum

Test Name	Result	Units	Biological Reference Interval
Post Prandial Blood Glucose After 2hr. : <i>GOD-POD Method.</i>	97.6	mg/dl	80 - 140

*Dr. Gayatri M. Mehta*  
M. D. (Patho)

DR GAYATRI MEHTA  
MD(PATHOLOGY)

DR. ANAND D. PARIKH  
MD(PATHOLOGY)

LAB USE ONLY (Entered by :GM Enter Date/Time:10/06/2023 3:22:00 PM) (Verify by :GM Verify Date/Time:10/06/2023 3:22:00 PM)



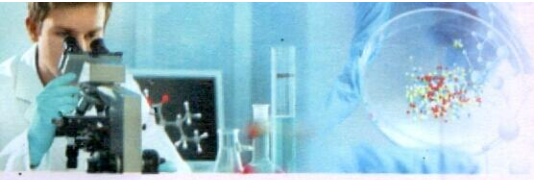Vidhi Imaging Center | Pathology Department

L-86, Swatantra Senani Nagar, Opp. Akhbarnagar Petrol Pump, Nr. Akhbarnagar Circle, Nava-Vadaj, Ahmedabad - 380 013.  
Ph. (Pathology) : 8849893954 M. 98799 29406, 98250 09406, E-mail : vidhidiagnostics@gmail.com, Web. : www.vidhidiagnostics.com  
Time (Pathology) : Mon. to Sat. 8.30 am to 8.00 pm, Sunday 9 am to 12 Noon

*Pathology means science behind medicine*

**CT SCAN & CBCT FACILITY NOW AVAILABLE**





Pathology Department



Patient's name : SHRUTI TIWARI  
Age/Sex : 34 Years/Female  
Referred by : Dr. MEDIWHEEL  
Collection Time : 10:30

Reg. ID : P-1304-23  
Accession : 7133  
Order Dt/time : 10/06/2023 10:30

**Lipid Profile**

Sample Type: Serum

Test Name	Result	Units	Biological Reference Interval
<b>S. Cholesterol :</b> Oxidase-esterase method.	166	mg/dl	0 - 200
<b>S. Triglyceride :</b> Enzymatic Colorimetry method	145.7	mg/dL	0 - 200
<b>S. HDL - Cholesterol :</b> Serum by Enzymatic method.	42.9	mg/dL	35 - 65
<b>S. LDL - Cholesterol :</b> Serum by Enzymatic method	93.96	mg/dL	0 - 130
<b>S. VLDL - Cholesterol :</b>	29.14	mg/dL	0 - 30
<b>S. Chole/HDL.Ratio :</b>	3.87		1 - 6
<b>S. LDL / HDL Cholesterol Ratio :</b>	2.19		0 - 3.5

*Dr. Gayatri M. Mehta*

M.D. (Patho)

Reg. No. G-32215

DR GAYATRI MEHTA  
MD(PATHOLOGY)

DR. ANAND D. PARIKH  
MD(PATHOLOGY)

LAB USE ONLY (Entered by :GM Enter Date/Time:10/06/2023 3:21:00 PM) (Verify by :GM Verify Date/Time:10/06/2023 3:21:00 PM)



Vidhi Imaging Center | Pathology Department

L-86, Swatantra Senani Nagar, Opp. Akharnagar Petrol Pump, Nr. Akharnagar Circle, Nava-Vadaj, Ahmedabad - 380 013.

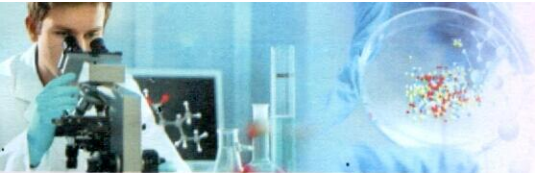Ph. (Pathology) : 8849893954 M. 98799 29406, 98250 09406, E-mail : vidhidiagnostics@gmail.com, Web. : www.vidhidiagnostics.com

Time (Pathology) : Mon. to Sat. 8.30 am to 8.00 pm, Sunday 9 am to 12 Noon

*Pathology means science behind medicine*

**CT SCAN & CBCT FACILITY NOW AVAILABLE**





Pathology Department



Patient's name : SHRUTI TIWARI  
Age/Sex : 34 Years/Female  
Referred by : Dr. MEDIWHEEL  
Collection Time : 10:30

Reg. ID : P-1304-23  
Accession : 7133  
Order Dt/time : 10/06/2023 10:30

### HbA1C

Sample Type: Serum

Test Name	Result	Units	Biological Reference Interval
HbA1C :	5.1	%	Non-diabetic: 4.2-6.2 Pre-diabetic : 6.3-7.2 Diabetic : 7.3-8.2
Mean Blood Glucose of Last 03 months.	100	mg/dl	

#### Comment

\*As per the new 2009 update of American Diabetes Association regarding HbA1C & Mean Blood Glucose relationship.

#### NOTE:

This test is used to monitor diabetic patients compliance with the therapeutic regimen and logo It's level is proportional to both the average blood glucose concentration and the life span of the red blood cells (RBC) in circulation. HbA1c values are free of day to day glucose fluctuations and are unaffected by exercise or recent food intake.

*Dr. Gayatri M. Mehta*  
M. D. (Patho)

Reg. No. G-32215

DR GAYATRI MEHTA  
MD(PATHOLOGY)

DR. ANAND D. PARIKH  
MD(PATHOLOGY)

LAB USE ONLY (Entered by :GM Enter Date/Time:10/06/2023 3:21:00 PM) (Verify by :GM Verify Date/Time:10/06/2023 3:21:00 PM)



Vidhi Imaging Center | Pathology Department

L-86, Swatantra Senani Nagar, Opp. Akharnagar Petrol Pump, Nr. Akharnagar Circle, Nava-Vadaj, Ahmedabad - 380 013.

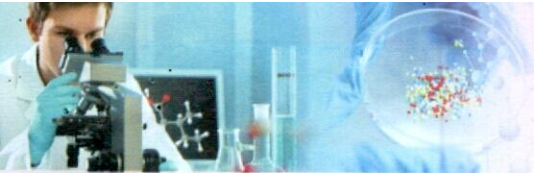Ph. (Pathology) : 8849893954 M. 98799 29406, 98250 09406, E-mail : vidhidiagnostics@gmail.com, Web. : www.vidhidiagnostics.com

Time (Pathology) : Mon. to Sat. 8.30 am to 8.00 pm, Sunday 9 am to 12 Noon

*Pathology means science behind medicine*

**CT SCAN & CBCT FACILITY NOW AVAILABLE**





Pathology Department



Patient's name : SHRUTI TIWARI  
 Age/Sex : 34 Years/Female  
 Referred by : Dr. MEDIWHEEL  
 Collection Time : 10:30

Reg. ID : P-1304-23  
 Accession : 7133  
 Order Dt/time : 10/06/2023 10:30

**BIOCHEMISTRY**

Sample type :Serum

Test Name	Result	Units	Biological Reference Interval
Urea, (Serum by GLDH method ) :	18.5	mg/dl	10 - 50
S.Uric acid, (Serum by Uricase method ) :	3.8	mg/dl	2.6-6.0
Bun :	8.6	mg/dl	6-20
Creatinine, (Serum by Enzymatic reaction ) :	0.64	mg/dl	0.5-1.2
BUN/CREATRATIO	13.43		13 - 20
S.G.P.T (ALT) : (Serum by IFCC method )	17.8	U/L	0 - 40
S.G.O.T (AST) : (Serum by IFCC method )	13.7	U/L	0 - 37
ALK.PHOSPHATASE : (Serum by PNP method )	83	U/L	35-104
G.G.T :	14.5	U/L	8 - 78
<b><u>BILIRUBIN</u></b>			
Total :	0.21	mg/dl	Up to 1.2
Direct :	0.12	mg/dl	0-0.7
Indirect :	0.09	mg/dl	0 - 0.5
<b><u>SERUM PROTEINS</u></b>			
Total Protein (Serum by Biuret method ) :	6.68	gms/dl	6.4 - 8.5
Albumin (Serum by BCG method ) :	3.97	gms/dl	3.97-4.94
Globulins :	2.71	gms/dl	2.3 - 3.5
A/G Ratio :	1.465		0.9 - 2.9

*Dr. Gayatri M. Mehta*  
 M. D. (Patho)

Reg No. G-32215  
 DR GAYATRI MEHTA  
 MD(PATHOLOGY)

DR. ANAND D. PARIKH  
 MD(PATHOLOGY)



(Entered by :GM Enter Date/Time:10/06/2023 3:19:00 PM) (Verify by :GM Verify Date/Time:10/06/2023 3:19:00 PM)

Vidhi Imaging Center | Pathology Department

L-86, Swatantra Senani Nagar, Opp. Akhbarnagar Petrol Pump, Nr. Akhbarnagar Circle, Nava-Vadaj, Ahmedabad - 380 013.

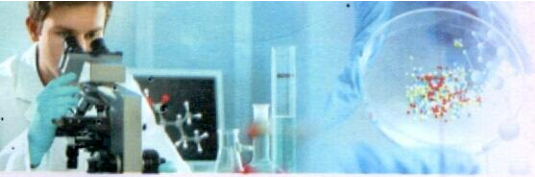Ph. (Pathology) : 8849893954 M. 98799 29406, 98250 09406, E-mail : vidhidiagnostics@gmail.com, Web. : www.vidhidiagnostics.com

Time (Pathology) : Mon. to Sat. 8.30 am to 8.00 pm, Sunday 9 am to 12 Noon

*Pathology means science behind medicine*

**CT SCAN & CBCT FACILITY NOW AVAILABLE**





Pathology Department

**VIDHI**<sup>®</sup>  
**DIAGNOSTICS**



Creating Life in Samples

Patient's name : SHRUTI TIWARI  
Age/Sex : 34 Years/Female  
Referred by : Dr. MEDIWHEEL  
Collection Time : 10:30

Reg. ID : P-1304-23  
Accession : 7133  
Order Dt/time : 10/06/2023 10:30

### Thyroid Function Test

Sample Type: Serum

Test Name	Result	Units	Biological Reference Interval
TOTAL T3 :	1.11	ng/ml	0.84 - 2.0
TOTAL T4 :	9.62	ug/dl	5.1 - 14.0
TSH(Ultra sensitive) :	1.853	mIU/L	0.27 - 4.2

*Dr. Gayatri M. Mehta*  
M. D. (Pathol)

Reg. No. G-32215  
DR GAYATRI MEHTA  
MD(PATHOLOGY)

DR. ANAND D. PARIKH  
MD(PATHOLOGY)

LAB USE ONLY (Entered by :GM Enter Date/Time:10/06/2023 3:25:00 PM) (Verify by :GM Verify Date/Time:10/06/2023 3:25:00 PM)



Vidhi Imaging Center | Pathology Department

L-86, Swatantra Senani Nagar, Opp. Akhbarnagar Petrol Pump, Nr. Akhbarnagar Circle, Nava-Vadaj, Ahmedabad - 380 013.

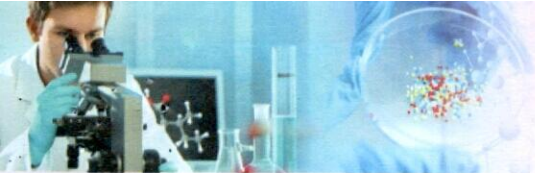Ph. (Pathology) : 8849893954 M. 98799 29406, 98250 09406, E-mail : vidhidiagnostics@gmail.com, Web. : www.vidhidiagnostics.com

Time (Pathology) : Mon. to Sat. 8.30 am to 8.00 pm, Sunday 9 am to 12 Noon

*Pathology means science behind medicine*

**CT SCAN & CBCT FACILITY NOW AVAILABLE**





Patient's name : SHRUTI TIWARI  
Age/Sex : 34 Years/Female  
Referred by : Dr. MEDIWHEEL  
Collection Time : 10:30

Reg. ID : P-1304-23  
Accession : 7133  
Order Dt/time : 10/06/2023 10:30

**Urine Analysis**

Sample Type: Urine

Test Name	Result	Units	Biological Reference Interval
<b><u>Physical Examination</u></b>			
Quantity :	30	ml	0 - 500 ml
Colour :	Pale Yellow		Pale Yellow
Transparency :	Slight Turbid.		Clear
Reaction :	Acidic		4.6 - 8.0
Specific Gravity :	1.025		1.016 - 1.022
Sediment :	Present		
<b><u>Chemical Examination</u></b>			
Albumin :	Present (Faint Trace)		Absent
Sugar :	NIL		Absent
Acetone :	Absent		Absent
Bile Salts :	Absent		Absent
Bile Pigments :	Absent		Absent
Urobilogen :	Absent		Absent
Nitrites :	Absent		Absent
<b><u>Microscopic Examination</u></b>			
Red blood Cells :	1-2	/h.p.f	Absent
Pus Cells :	2-3	/h.p.f	Absent
Epithelial Cells :	2-3	/h.p.f	< 10.0
Amorphous :	Absent	/h.p.f	Absent
Bacteria :	Absent	/h.p.f	Absent
Crystals :	Absent	/h.p.f	Absent
Casts :	Absent	/h.p.f	Absent
Fungus :	Not seen	/h.p.f	Absent

*Dr. Gayatri M. Mehta*

M. D. (Patho)

Reg. No. G-32215



DR. ANAND D. PARIKH  
MD(PATHOLOGY)

(Entered by :GM Enter Date/Time:10/06/2023 3:26:00 PM) (Verify by :GM Verify Date/Time:10/06/2023 3:26:00 PM)

Vidhi Imaging Center | Pathology Department

L-86, Swatantra Senani Nagar, Opp. Akharnagar Petrol Pump, Nr. Akharnagar Circle, Nava-Vadaj, Ahmedabad - 380 013.

Ph. (Pathology) : 8849893954 M. 98799 29406, 98250 09406, E-mail : vidhidiagnostics@gmail.com, Web. : www.vidhidiagnostics.com

Time (Pathology) : Mon. to Sat. 8.30 am to 8.00 pm, Sunday 9 am to 12 Noon

*Pathology means science behind medicine*

**CT SCAN & CBCT FACILITY NOW AVAILABLE**



ભારત સરકાર  
Government of India

શ્રુતિ તિવારી  
Shruti Tiwari


જન્મ તારીખ/DOB: 16/01/1989  
સ્ત્રી/ FEMALE

2666 7406 8482  
VID : 9185 9534 6267 6747

મારી આધાર, મારી ઓળખ

ભારત સરકાર  
Government of India

Issue Date: 15/01/2012

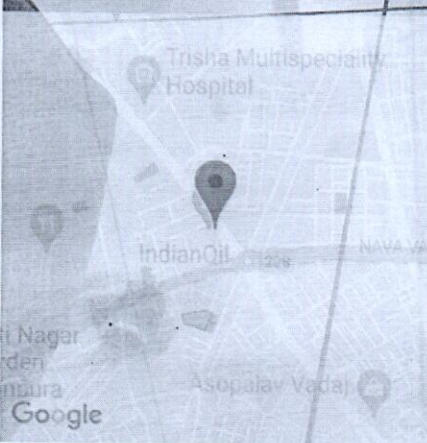


*Shruti*

Dr. Vidhi D. Modh  
MBBS  
Reg. No. G-74540

**Vidhi Diagnostics**  
L-86, Swatantra-Senani Nagar,  
Opp. Akhbarnagar Bus Terminats,  
Nr. Akhbarnagar Circle,  
New Wadaj, Ahmedabad-13.






Jun 10, 2023 10:23:13 AM

Nirnay Nagar  
Ahmedabad

Gujarat

  
**Dr. Vidhi D. Modh**  
MBBS  
Reg. No. G-74540

**Vidhi Diagnostics**  
L-86, Swatantra-Senani Nagar,  
Opp. Akhbarnagar Bus Terminal,  
Nr. Akhbarnagar Circle,  
New Wadaj, Ahmedabad-13.