


 **बैंक ऑफ़ बड़ौदा**
Bank of Baroda

नाम : **DHANYA K. DAS**
Name

कर्मचारी कूट क्र : **169418**
E.C. No.


धिकारी



धारक के हस्ताक्षर
Signature of Holder



Dhanya



MURUGAN HOSPITALS

HEALING HANDS



LAB REPORT

Patient Name : Mrs. DHANYA K DAS
Age / Gender : 33-Years / Female
UHID ID : MH20210033524
Doctor Name : Dr. ARUN PRAKASH

OP Report No. : INVA2103707
Bill No. : INV2106347
Sample Date : 25/12/2021 - 11:00 AM
Report Date : 26/12/2021 - 04:05 PM

Test Name	Result	Units	Reference Interval
-----------	--------	-------	--------------------

HAEMATOLOGY

Complete Blood Cell Count(CBC)

HAEMOGLOBIN	12.3	gms/dl	male :13.0 - 17.0 female :12.0 - 15.0
PACKED CELL VOLUME	38.5	%	male : 40 - 50 female : 36 - 46
RBC COUNT	<u>4.58</u>	millions cells/cu.mm	female: 3.8 - 4.8 male : 4.5 - 5.5
TOTAL WBC	5,600	Cells/Cumm	4,000 - 11,000
Differential Count			
NEUTROPHILS	60	%	40 - 65
LYMPHOCYTES	34	%	30-50
EOSINOPHILS	04	%	01-06
MONOCYTES	02	%	1-10
BASOPHILS	00	%	0-2
ESR 60 MTS	10	mm	5 - 20
PLATELET COUNT	3.08	Lakhs/cumm	1.5 - 4.5
MCV	84.2	fL	76 - 96
MCH	<u>26.8</u>	pg	27 - 32
MCHC	31.9	gms/dl	30 - 36

INTERPRETATION: Test done on automated three part cell counter, all abnormal results are reviewed and confirmed microscopically.

BLOOD GROUPING & RH TYPING " B " POSITIVE

Page 1 of 4

Healing Hearts and Lives

264/125, Kilpauk Garden Road, Kilpauk, Chennai - 600 010.
Phone : +91 44 4644 8989 / 75500 53335 | Email : muruganhosp@gmail.com
Website : www.muruganhospitals.in



MURUGAN HOSPITALS

HEALING HANDS



LAB REPORT

Patient Name : Mrs. DHANYA K DAS
Age / Gender : 33-Years / Female
UHID ID : MH20210033524
Doctor Name : Dr. ARUN PRAKASH

OP Report No. : INVA2103707
Bill No. : INV2106347
Sample Date : 25/12/2021 - 11:00 AM
Report Date : 26/12/2021 - 04:05 PM

Test Name	Result	Units	Reference Interval
BIO CHEMISTRY			
BLOOD SUGAR FASTING	97	mgs/dl	70-110
BLOOD SUGAR POST PRANDIAL	120	mgs/dl	80- 160
SERUM URIC ACID	3.2	mg/dl	male 3.1-7.0 , female 2.5-5.6
SERUM CREATININE	0.8	mg/dl	0.7-1.4
LIPID PROFILE			
TOTALCHOLESTEROL	229	mg/dl	< 200
TRIGLYCERIDE	100	mg/dl	< 150
HDL	57	mg/dl	35 - 80
VLDL	20	mg/dl	2 to 30
LDL	152	mg/dl	<130
CHOLESTEROL/ HDL RATIO	4.0	mg/dl	

Healing Hearts and Lives

264/125, Kilpauk Garden Road, Kilpauk, Chennai - 600 010.
Phone : +91 44 4644 8989 / 75500 53335 | Email : muruganhosp@gmail.com
Website : www.muruganhospitals.in



MURUGAN HOSPITALS

HEALING HANDS



LAB REPORT

Patient Name : Mrs. DHANYA K DAS

Age / Gender : 33-Years / Female

UHID ID : MH20210033524

Doctor Name : Dr. ARUN PRAKASH

OP Report No. : INVA2103707

Bill No. : INV2106347

Sample Date : 25/12/2021 - 11:00 AM

Report Date : 26/12/2021 - 04:05 PM

Test Name	Result	Units	Reference Interval
LIVER FUNCTION TEST			
BILLIRUBIN(TOTAL)	0.7	mg/dl	0.0 -1.0
BILLIRUBIN(DIRECT)	0.2	mg/dl	0.1- 0.30
BILLIRUBIN(INDIRECT)	0.5	mg/dl	0.2-0.8
SGOT	24	IU/L	0-38
SGPT	39	IU/L	0.0-40
ALKALINE PHOSPHATASE	42	IU/L	40-140
			4-6Years 93-309
			13-15Years 74-390
TOTAL PROTEIN	7.5	gm/dl	6.6-8.7
ALBUMIN	4.7	gm/dl	3.5 - 5.5
GLOBULIN	2.8	gm/dl	2.0-3.5
AG RATIO	1.6		
GAMMA G T	13	U/L	male<49
			female<32
BLOOD UREA NITROGEN	9.3	mg/dl	7-21
HBA1C	5.2	%	normal: <6.0
			good control: 6.1-7.0
			fair control: 7.1- 8.0
			poor control:8.1 -10.0
			unsatisfactory: >10.0

Healing Hearts and Lives

264/125, Kilpauk Garden Road, Kilpauk, Chennai - 600 010.

Phone : +91 44 4644 8989 / 75500 53335 | Email : muruganhosp@gmail.com

Website : www.muruganhospitals.in



MURUGAN HOSPITALS

HEALING HANDS



LAB REPORT

Patient Name : Mrs. DHANYA K DAS
 Age / Gender : 33-Years / Female
 UHID ID : MH20210033524
 Doctor Name : Dr. ARUN PRAKASH

OP Report No. : INVA2103707
 Bill No. : INV2106347
 Sample Date : 25/12/2021 - 11:00 AM
 Report Date : 26/12/2021 - 04:05 PM

Test Name	Result	Units	Reference Interval
<u>CLINICAL PATHOLOGY</u>			
URINE SUGAR (F)	NIL		
URINE SUGAR (PP)	NIL		
URINE ROUTINE			
COLOUR	PALE YELLOW		
APPEARANCE	CLEAR		
REACTION	ACIDIC		
ALBUMIN	NIL		
DEPOSITES			
PUS CELLS	2 - 4	/ HPF	
EPI CELLS	1 - 2	/ HPF	
RBC COUNT	NIL	/ HPF	
CAST	NIL		
CRYSTALS	NIL		
OTHERS	NIL		
<u>ENDOCRINOLOGY</u>			
T3	1.018	ng/ml	0.52-1.85
T4	9.211	ug/dl	5.0 -13.0 ug/dl
TSH	2.328	uIU/ml	0.39 - 6.16 uIU/ml

Dr. PAVITHRA, MD.
 Pathologist
 Reg. No. : 78256

KAVIYARASAN
 Verified by

*** End of Report ***



Healing Hearts and Lives

ID : 2112250001
Name: MRS DHANYA K DAS
Sex ~~Male~~
Divisions:

DataTime: 2021-12-25 00:15
Age : 33
BP : 100/80 mmHg
Bed No. :

Hospital: MURUGAN HOSPITALS
Height : 162 cm
Weight : 71 kg
Hospital No. :

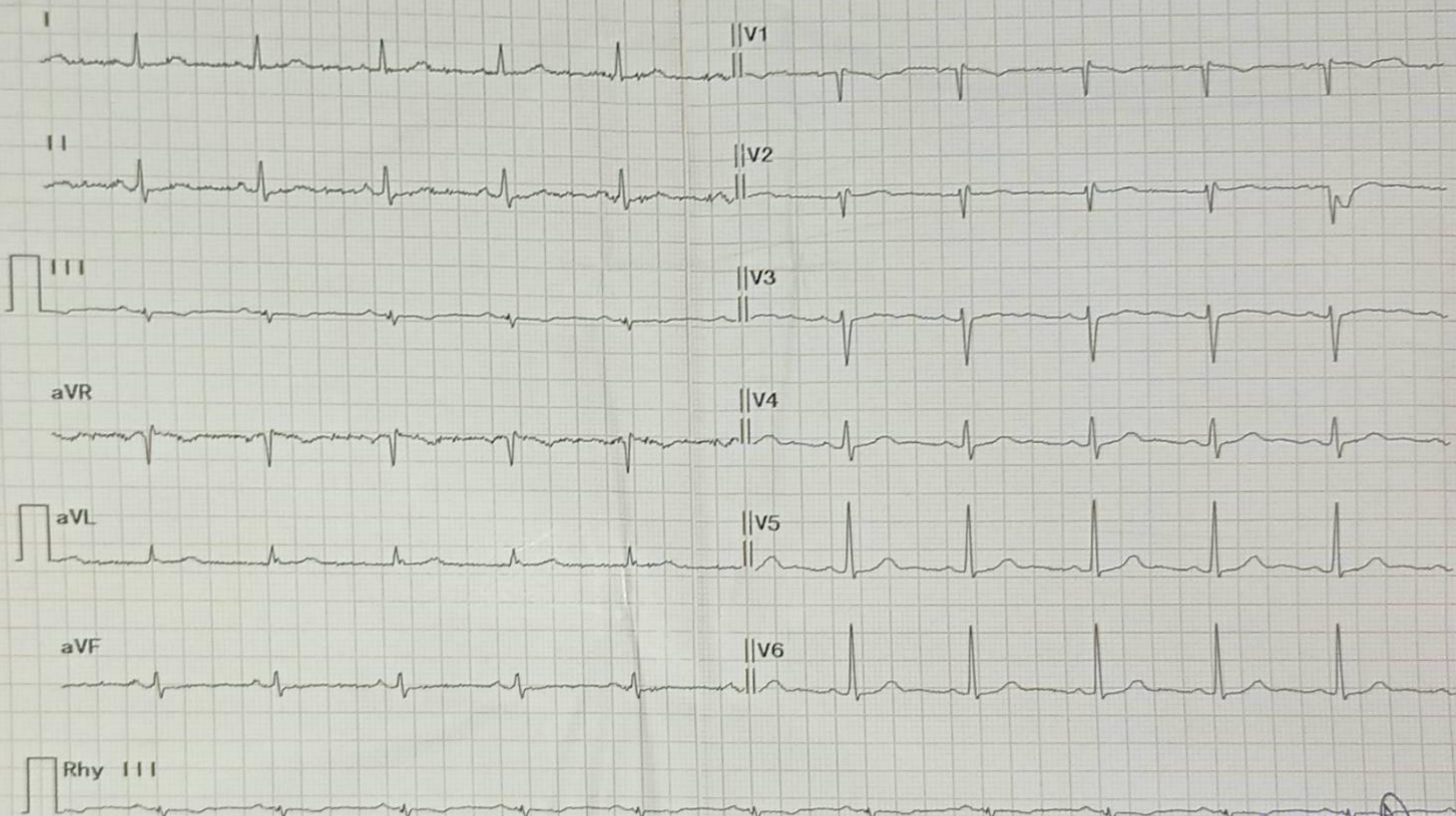
HR 75 bpm
P Dur/PR int 112/166ms
QRS Dur 100ms
QT/QTc int 372/409 ms
P/QRS/T axis 61/7/16 °

RV5/SV1 amp 1.323/0.584mV
RV5+SV1 amp 1.907mV
RV6/SV2 amp 1.350/0.426mV

Minnesota Code

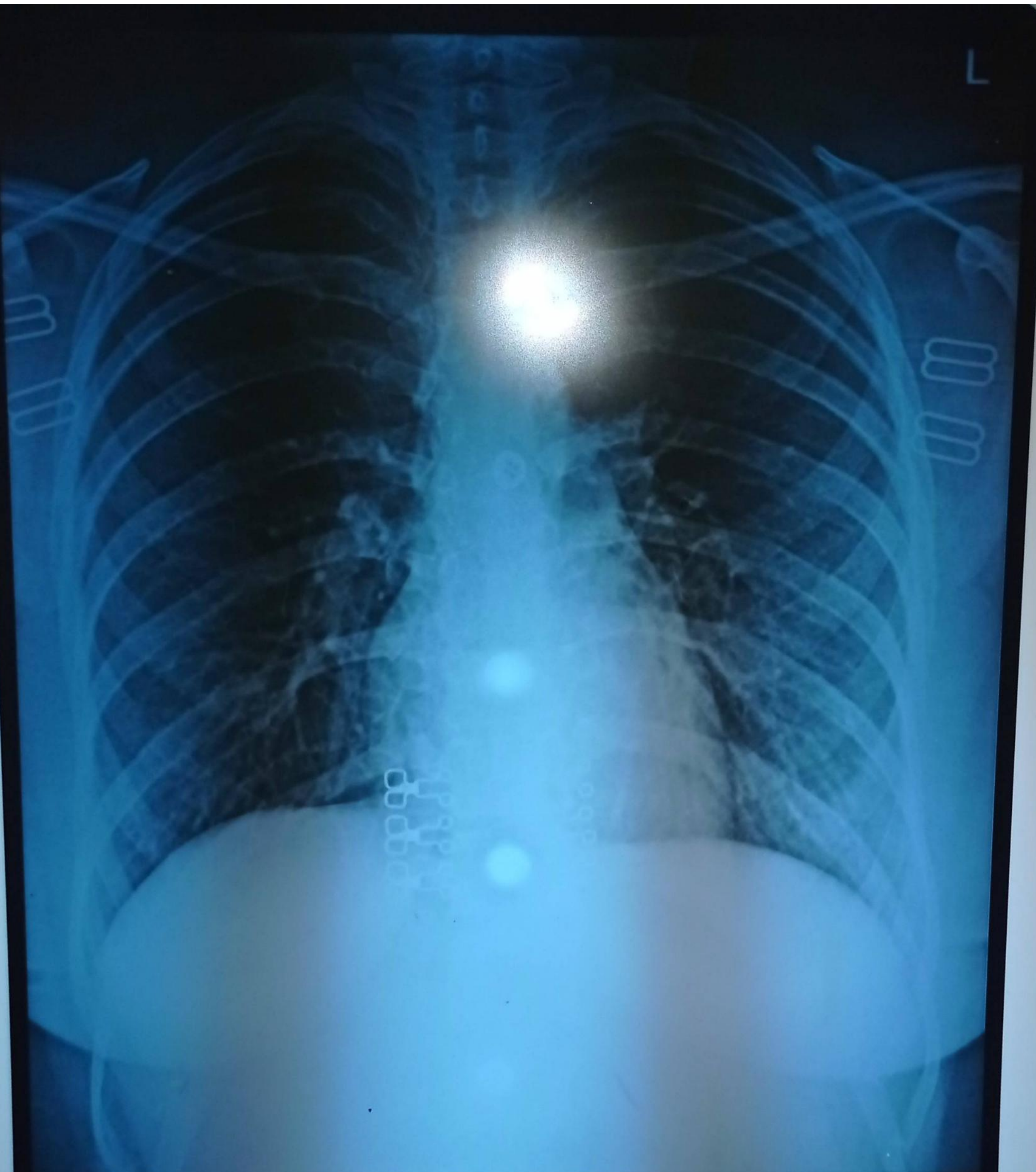
Diagnosis Info
800: Sinus Rhythm

Normal ECG



Diagnosis for reference, ask your doctor to confirm
AUTO PRINT 6X2+1R 75bpm 10 mm/mV 0.50Hz-45Hz AC 50Hz 25 mm/sec Confirmed By:

Dr. SIDHARTHAN, MD.,DM.,
Consultant Cardiologist
Reg. No. 62979



MRS.DHANYA K DAS 33YRS 33524 CHEST-PA 25-12-2021

MURUGAN HOSPITALS, KILPAIK, CHENNAI 10 PH NO. 75005136 3644000



MURUGAN HOSPITALS
HEALING HANDS

Mrs. Dhanya K Das

33/F

No dental caries / decay.

no discolorisation

H₁₀ tooth extraction Ⓟ Molar. lower.

H₁₀ tooth cavity fully.

no tonsils. enlargement.

no discharge from ear

no nasal block.



264/125, Kilpauk Garden Road, Kilpauk, Chennai - 600 010.

☎ : +91 44 4644 8989 / 75500 53335 email : muruganhosp@gmail.com

Website : www.muruganhospitals.in



MURUGAN HOSPITALS
HEALING HANDS

25/12/2021

Mrs. Dhanya K Das

33/F

H/o tooth extraction ⊕

tooth filling ⊕

No active dental caries.

No dislodgement



264/125, Kilpauk Garden Road, Kilpauk, Chennai - 600 010.

☎ : +91 44 4644 8989 / 75500 53335 email : muruganhosp@gmail.com

Website : www.muruganhospitals.in



MURUGAN HOSPITALS

HEALING HANDS

Mrs. Dhanya K DAS

331F

No Ear discharge @

tongue normal.

Throat (N).

No DNS @.

B

All Specific complaints



264/125, Kilpauk Garden Road, Kilpauk, Chennai - 600 010.

☎ : +91 44 4644 8989 / 75500 53335 email : muruganhosp@gmail.com

Website : www.muruganhospitals.in

From,

Dhanya K. Das
Bank of Baroda
(Medi wheel)


To

Duty doctor
Musugan hospital

This is with regard to my medical
health check, I didn't give sample for my
stool testing kindly omit the report
related to stool testing.

Chennai
25.12.2021

Yours faithfully





MURUGAN HOSPITALS

HEALING HANDS



ECHO CARDIOGRAM REPORT

NAME : MRS.DHANYA K DAS

UHID NO:MH20210033522

AGE&SEX : 33 /FEMALE

IP/OP : OUTPATIENT

CONSULTANT: DR. ARUN PRAKASH

DATE : 25-12-2021

2D PLAX (mm)

RV - 23 mm
AO - 30mm
LA - 26 mm

COLOR DOPPLER

Normal

M-Mode (mm)

IVS - 08 mm
PW - 08 mm
LVD - 43 mm
LVS - 25 mm
EF - 72 %
FS - 41 %

DOPPLER (m/sec)

MITRAL E - 0.6 m/s
MITRAL A - 1.0 m/s
PULMONARY - 0.7 m/s
AORTIC - 0.9 m/s
TRICUSPID - 0.4 m/s

IMPRESSION:

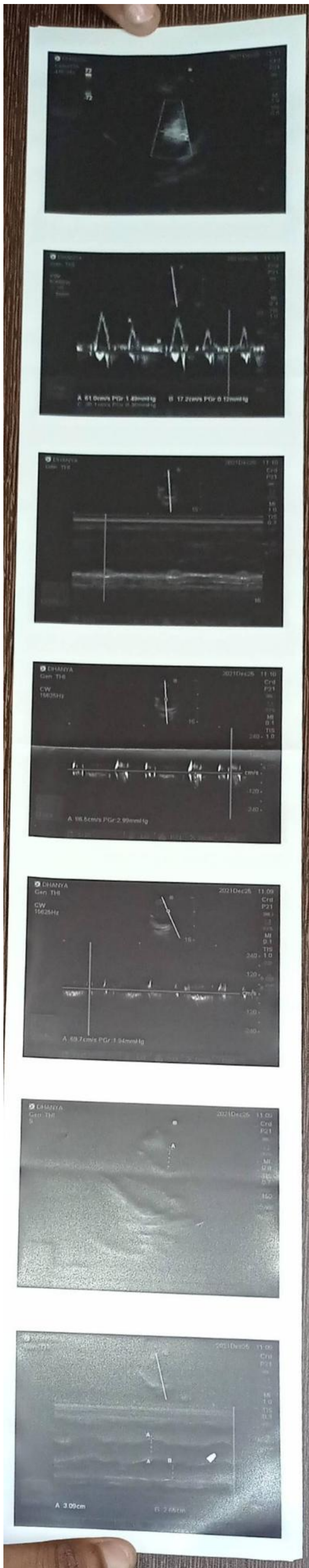
No RWMA
Normal LV Systolic function
Grade I left ventricular diastolic dysfunction
Normal valves and chambers.
Normal RV function
No pulmonary hypertension
No pericardial effusion
No clot/ Vegetation.



DR.SIDHARTHAN, MD.,DM.,
CONSULTANT CARDIOLOGIST

Healing Hearts and Lives

264/125, Kilpauk Garden Road, Kilpauk, Chennai - 600 010.
Phone : +91 44 4644 8989 / 75500 53335 | Email : muruganhosp@gmail.com
Website : www.muruganhospitals.in





MURUGAN HOSPITALS

HEALING HANDS



SCAN REPORT

NAME : MRS. DHANYA K DAS
AGE / SEX : 33/FEMALE
CONSULTANT: DR. ARUN PRAKASH

UHID NO :MH20210033522
IP / OP NO: OUTPATIENT
DATE : 25.12.2021

ULTRA SOUND SCAN OF ABDOMEN

LIVER: Normal in size and measures 15.2 cm and **increased in** echotexture. No focal lesions are seen. No dilatation of intra-hepatic biliary radicals present. Hepatic veins and IVC appear normal. Portal vein is normal in caliber. Common bile duct is normal in caliber.

GALL BLADDER: Normal in size and wall thickness. No evidence of any calculus or mass present. No evidence of pericholecystic collections.

PANCREAS: Normal in size and echotexture. No focal lesions are seen. No evidence of calculi or calcifications. No evidence of pancreatic duct dilation.

PARA AORTIC AREAS: Aorta and IVC appear normal. No evidence of para aortic lymphadenopathy.

SPLEEN: Normal in size and measures 8.2 cm. Normal in echotexture. No evidence of focal lesions.

RIGHT KIDNEY: Measures 8.5 x 3.9 cm and is normal in size and echotexture. Cortico medullary differentiation is well maintained. There is no hydronephrosis or mass.

LEFT KIDNEY: Measures 8.9 x 3.6 cm and is normal in size and echotexture. Cortico medullary differentiation is well maintained. There is no calculus or hydronephrosis or mass.

Healing Hearts and Lives

264/125, Kilpauk Garden Road, Kilpauk, Chennai - 600 010. Phone : +91 44 4644 8989 / 75500 53335
Email : muruganhosp@gmail.com | Website : www.muruganhospitals.in

URINARY BLADDER: Normal in size, contour and wall thickness. There is no evidence of calculus or mass. No vesical diverticulum present.

UTERUS AND OVARIES: Measures- 6.6 x 4.4 cm ,normal in size and echotexture.
ET- 4 mm.

Right ovary measures- 2.0 x 2.5 cm.

Left ovary could not be assessed.

No ascites present. No retroperitoneal lymphadenopathy present.

IMPRESSION:

- Fatty liver grade I
- No other significant abnormality.



Dr. SAKTHI, MDRD.
Consultant Radiologist.



MURUGAN HOSPITALS

HEALING HANDS



LAB REPORT

Reg.ID : I - 33218
Patient Name : MRS. DHANYA K DAS
Contact No : -
Age : 33 (Female)
Referral : DR. ARUN PRAKASH S.
Source : MURUGAN HOSPITALS
Report ID : 50300

Reg. Date : Dec 25, 2021, 04:20 p.m.
Sample Date : Dec 25, 2021, 04:25 p.m.
Report Date : Dec 28, 2021, 12:53 p.m.
Print Date : Dec 28, 2021, 01:44 p.m.
Sample ID :



1921120731

Test Description	Value(s)	Reference Range
------------------	----------	-----------------

TEST REPORT

LAB ID: PAP - 131/2021

SPECIMEN:

Cervical PAP smear (LBC).


SPECIMEN ADEQUACY:

Satisfactory for evaluation without endocervical cells.

INTERPRETATION / RESULT:

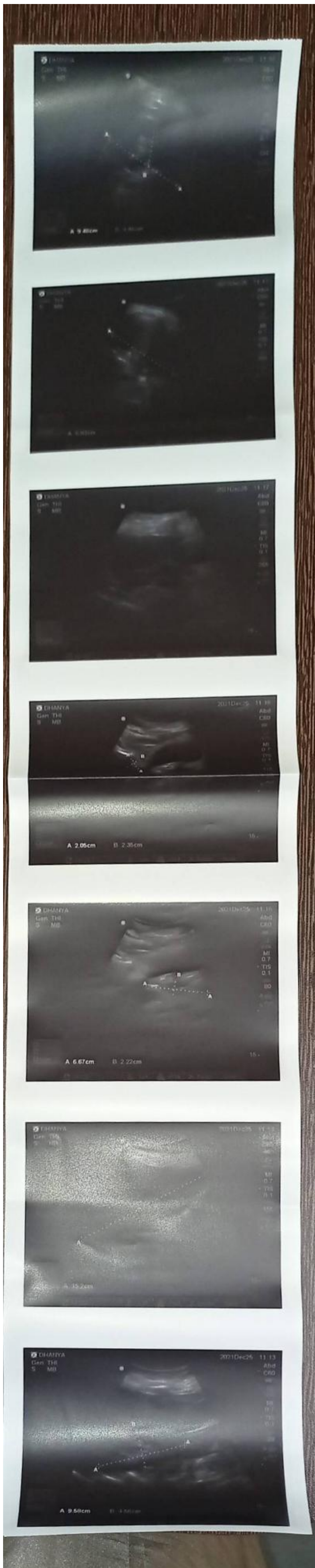NEGATIVE FOR INTRAEPITHELIAL LESION OR MALIGNANCY.

END OF REPORT


Dr. P. Preetha D.C.P., D.N.B (Path)
Consultant Pathologist

Note: All Lab test values are subjective and may have variation in context to age, gender and clinical status. The reference values given are a guidance, all variations in test values are to be interpreted with clinical correlation and physician's advice.
Verified By / Date Time : - / Dec 28, 2021, 01:44 p.m.

Healing Hearts and Lives
264/125, Kilpauk Garden Road, Kilpauk, Chennai - 600 010.
Phone : +91 44 4644 8989 / 75500 53335 | Email : muruganhosp@gmail.com
Website : www.muruganhospitals.in





MURUGAN HOSPITALS

HEALING HANDS



SCAN REPORT

NAME : MRS.DHANYA K DAS
AGE / SEX: 33 YEARS / FEMALE
CONSULTANT: DR. ARUN PRAKASH

UHID NO: 33524/ 2021/MH

DATE : 25 - 12- 2021

CHEST XRAY PA VIEW

- Trachea is in midline.
- Hila appear Normal.
- Mediastinal shadow appears normal.
- Costophrenic&Cardiophrenic angles appear free.
- Cardiothoracic ratio is within normal limits.
- Lungs fields appear clear
- Bony thorax and soft tissue appear normal

IMPRESSION:

- No significant abnormality noted.

CONSULTANT RADIOLOGIST



Healing Hearts and Lives

264/125, Kilpauk Garden Road, Kilpauk, Chennai - 600 010. Phone : +91 44 4644 8989 / 75500 53335
Email : muruganhosp@gmail.com | Website : www.muruganhospitals.in