



Aakriti Labs

3, Mahatma Gandhi Marg, Gandhi Nagar Mod,
Tonk Road, Jaipur (Raj.) Ph.: 0141-2710661
www.aakritilabs.com
CIN No. U85195RJ2004PTC019563

PATIENT NAME: MRS. KRISHNA VERMA	AGE & SEX: 29 Y/FEMALE
REF. By: MEDI WHEEL	DATE: 08/04/2023

REPORT: DIGITAL X-RAY CHEST PA VIEW

Soft tissue shadow and bony cages are normal.

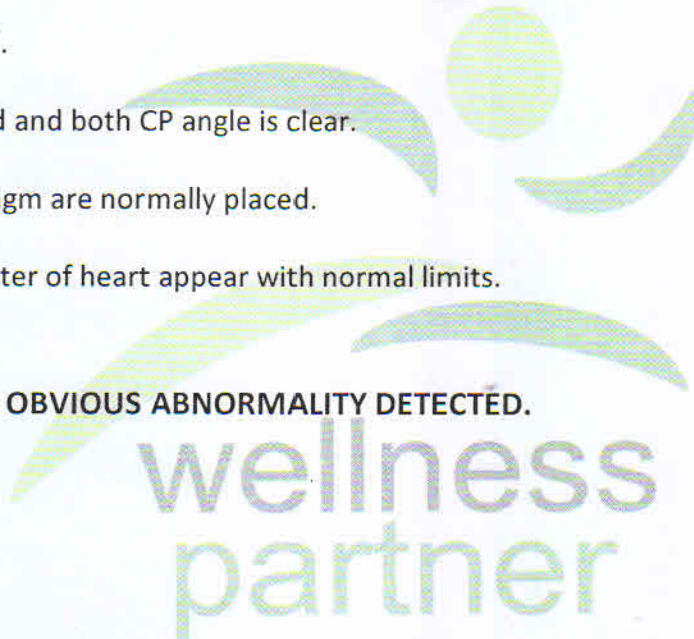
Trachea is central.

Bilateral lung field and both CP angle is clear.

Domes of diaphragm are normally placed.

Transverse diameter of heart appear with normal limits.

IMPRESSION:- NO OBVIOUS ABNORMALITY DETECTED.




RADIOLOGIST



Aakriti Labs

3, Mahatma Gandhi Marg, Gandhi Nagar Mod,
Tonk Road, Jaipur (Raj.) Ph.: 0141-2710661
www.aakritilabs.com
CIN No. U85195RJ2004PTC019563

NAME	MRS KRISHNA VERMA	AGE	29Y	SEX	FEMALE
REF BY	MEDI WHEEL	DATE	08/04/2023	REG NO	

ECHOCARDIOGRAM REPORT

WINDOW- POOR/ADEQUATE/GOODVALVE

MITRAL	NORMAL	TRICUSPID	NORMAL
AORTIC	NORMAL	PULMONARY	NORMAL

2D/M-MOD

IVSD mm	9.1	IVSS mm	8.5	AORTA mm	22.7
LVID mm	37.5	LVIS mm	20.0	LA mm	23.7
LVPWD mm	9.8	LVPWS mm	9.1	EF%	60%

CHAMBERS

LA	NORMAL	RA	NORMAL
LV	NORMAL	RV	NORMAL
PERICARDIUM	NORMAL		

DOPPLER STUDY MITRAL

PEAK VELOCITY m/s E/A	1.44/0.75	PEAK GRADIANT MmHg	
MEAN VELOCITY m/s		MEAN GRADIANT MmHg	
MVA cm2 (PLANIMETERY)		MVA cm2 (PHT)	
MR			

AORTIC

PEAK VELOCITY m/s	1.74	PEAK GRADIANT MmHg	
MEAN VELOCITY m/s		MEAN GRADIANT MmHg	
AR			

TRICUSPID

PEAK VELOCITY m/s	0.79	PEAK GRADIANT MmHg	
MEAN VELOCITY m/s		MEAN GRADIANT MmHg	
TR		PASP mmHg	

PULMONARY

PEAK VELOCITY m/s	1.42	PEAK GRADIANT MmHg	
MEAN VELOCITY m/s		MEAN GRADIANT MmHg	
PR		RVEDP mmHg	

IMPRESSION

- NORMAL LV SYSTOLIC & DIASTOLIC FUNCTION
- NO RWMA LVEF 60%
- NORMAL RV FUNCTION
- NORMAL CHAMBER DIMENSIONS
- NORMAL VALVULAR ECHO
- INTACT IAS / IVS
- NO THROMBUS, NO VEGETATION, NORMAL PERICARDIUM.
- IVC NORMAL

CONCLUSION : FAIR LV FUNCTION.


Cardiologist



Aakriti Labs

3, Mahatma Gandhi Marg, Gandhi Nagar Mod,
Tonk Road, Jaipur (Raj.) Ph.: 0141-2710661
www.aakritilabs.com
CIN No. U85195RJ2004PTC019563



Name : C/O KRISHNA VERMA

Age/Gender: 29 Y/Male

Patient ID : 012304080066

BarcodeNo : 10081725

Referred By : Self

Registration No: 55385

Registered : 08/Apr/2023 10:40AM

Analysed : 08/Apr/2023 02:58PM

Reported : 08/Apr/2023 02:58PM

Panel : MEDI WHEEL (ARCOFEMI
HEALTHCARE LTD)

USG: WHOLE ABDOMEN (Female)

LIVER : Is normal in size, shape and echogenicity.
The IHBR and hepatic radicals are not dilated.
No evidence of focal echopoor/echorich lesion seen.
Portal vein diameter and Common bile duct normal in size

GALL BLADDER : Is normal in size, shape and echotexture. Walls are smooth and regular with normal thickness. There is no evidence of cholelithiasis.

PANCREAS: Is normal in size, shape and echotexture. Pancreatic duct is not dilated.

SPLEEN : Is normal in size, shape and echogenicity. Splenic hilum is not dilated.

KIDNEYS : Bilateral Kidneys are normal in size, shape and echotexture, corticomedullary differentiation is fair and ratio appears normal. Pelvi calyceal system is normal. No evidence of hydronephrosis/ nephrolithiasis.

URINARY : Bladder is partially filled as patient not willing to hold urine

BLADDER : Pre Void Vol: 36 ml

UTERUS : Uterus and ovaries could not be seen due to partially filled bladder


SPECIFIC : No evidence of retroperitoneal mass or free fluid seen in peritoneal cavity.
NO evidence of lymphadenopathy or mass lesion in retroperitoneum.
Visualized bowel loop appear normal. Great vessels appear normal.

IMPRESSION: Ultra Sonography findings are suggestive of: **NORMAL STUDY.**

*** End Of Report ***

Page 1 of 1




Dr. Neera Mehta
M.B.B.S., D.M.R.D.
RMCNO.005807/14853

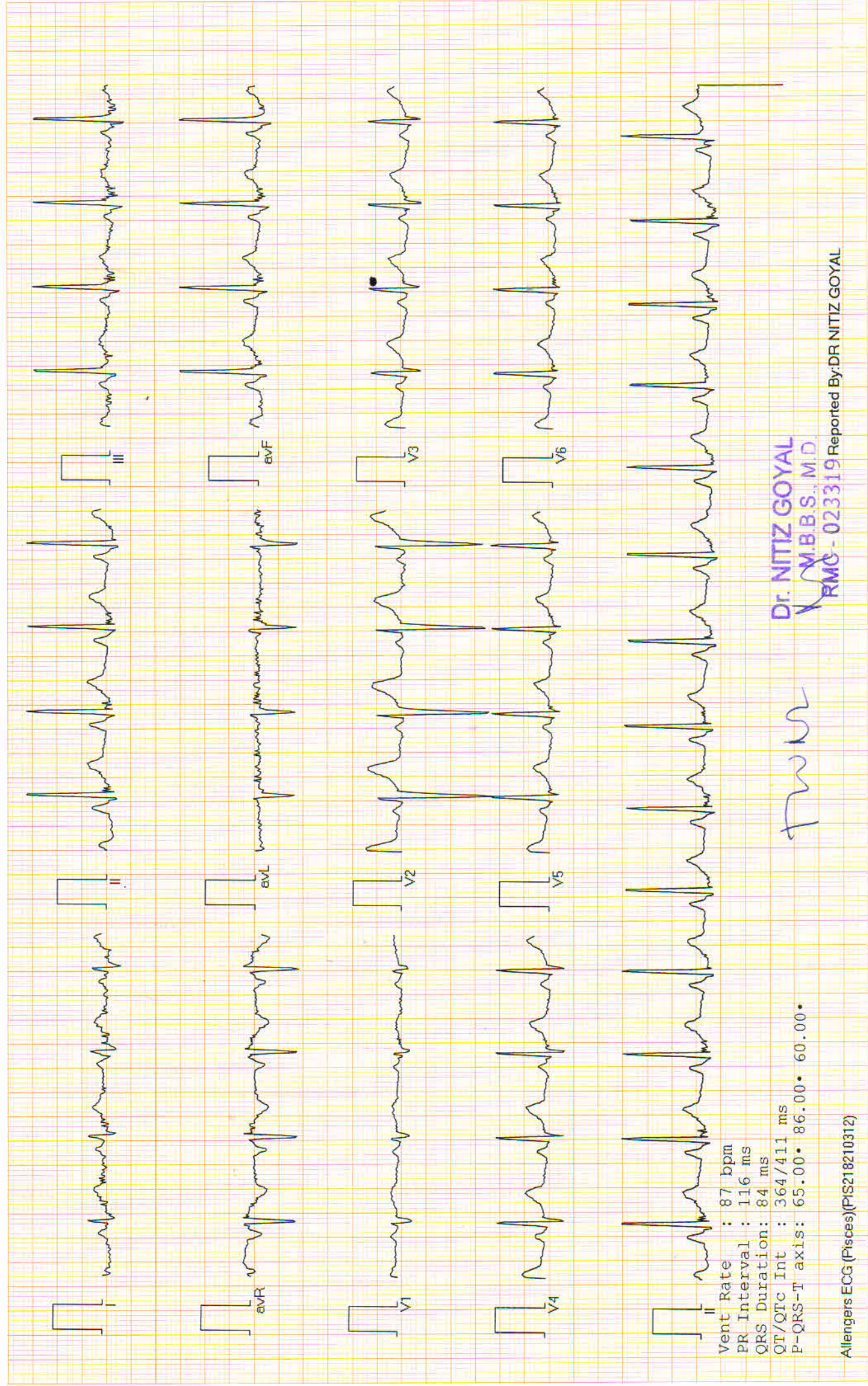
ECG

AAKRITI LABS PVT.LTD. 3 MAHATMA GANDHI MARG, TONK ROAD JAIPUR-15

55352 / MRS KRISHNA VERMA / 29 Yrs / F / Non Smoker

Heart Rate : 87 bpm / Tested On : 08-Apr-23 13:28:11 / HF 0.05 Hz - LF 100 Hz / Notch 50 Hz / Sn 1.00 Cm/mV / Sw 25 mm/s

Dr.: DR NITIZ GOYAL / Refd By.: MEDI WHEEL



Vent Rate : 87 bpm
PR Interval : 116 ms
QRS Duration: 84 ms
QT/QTc Int : 364/411 ms
P-QRS-T axis: 65.00• 86.00• 60.00•

Dr. NITIZ GOYAL
M.B.B.S., M.D
RMC - 023319

TUN

Allegers ECG (Pisces)(PIS218210312) Reported By:DR NITIZ GOYAL



Aakriti Labs

3, Mahatma Gandhi Marg, Gandhi Nagar Mod,
Tonk Road, Jaipur (Raj.) Ph.: 0141-2710661
www.aakritilabs.com
CIN No. U85195RJ2004PTC019563

(22)

ms. KRISHIMA VARMA

Age - 29

→

QATIMA CHOKA

Urea { 6/18 PH 6/9
6/10 PH 6/9

P2 Urea { 6/6
6/6

Coler. Urea { normal
normal BE

Range Urea - BE →

Phd