



भारत सरकार  
GOVERNMENT OF INDIA



संजीव कुमार गुप्ता  
Sanjeev Kumar Gupta  
जन्म तिथि/ DOB: 18/11/1971  
पुरुष / MALE



7462 3906 1414

आधार-आम आदमी का अधिकार



भारतीय विशिष्ट पहचान प्राधिकरण  
UNIQUE IDENTIFICATION AUTHORITY OF INDIA

पता:

S/O: राम स्वरूप गुप्ता, ए-  
93, थर्ड फ्लोर, नज़दीक  
यमुना स्पोर्ट्स कॉम्प्लेक्स गेट  
नं०. 3, योजना विहार,  
करकरडूमा, पूर्वी दिल्ली,  
दिल्ली - 110092

Address:

S/O: Ram Swarup Gupta, A-93,  
THIRD FLOOR, NEAR YAMUNA  
SPORTS COMPLEX GATE NO. 3,  
YOUNA VIHAR, Karakooma, East  
Delhi,  
Delhi - 110092

7462 3906 1414

Aadhaar-Aam Admi ka Adhikar

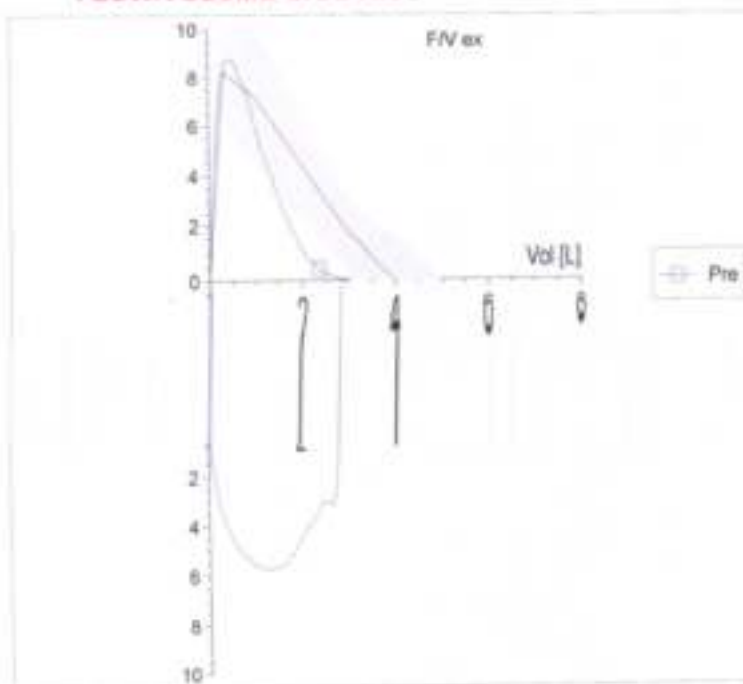
MALIK RADIX HEALTH CARE PVT. LTD.  
C-217, C-218, Nirman Vihar,  
Delhi-110092  
Ph.: 011-49287456, 011-81381379  
Regd. No. 607

**RADIX RESPIRATORY CARE**  
**(UNIT OF MALIK RADIX HEALTH CARE PVT.LTD.)**  
**C-218, Nirman Vihar, Vikas Marg, New Delhi-110092**  
**Tel.: 011-22011192, 22011208 Fax :22011208**

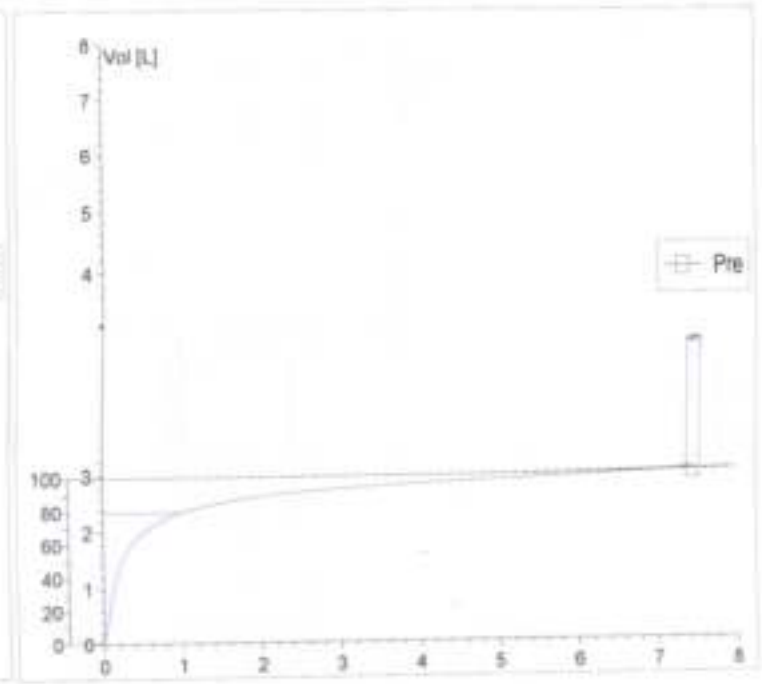
First Name: MR. SANJEEV KUMAR GUPTA  
 Identification: 06032024      Height: 168 cm      Gender: male  
 Age: 52 Years      BMI: 24      Weight: 69.0 kg  
 Patient History:      Ref. Physician:

		Pred LL	PRED	PRE	% PRED	POST	%PRED	% CHANGE
<b>DYNAMIC LUNG VOLUMES &amp; FLOW RATES</b>								
FVC	L	2.98	3.98	2.97	74 %			
FEV1	L	2.39	3.23	2.35	73 %			
FEV6	L			2.92				
FEV1%F	%	66.06	77.85	79.12	102 %			
PEF	L/s	6.24	8.23	8.77	107 %			
MMEF	L/s	2.01	3.72	2.13	57 %			
MEF75	L/s	4.38	7.19	7.77	108 %			
MEF50	L/s	2.23	4.41	3.13	71 %			
MEF25	L/s	0.41	1.69	0.66	39 %			
FVC IN	L	3.22	4.14	2.82	68 %			
MIF	L/s							
PIF	L/s			5.84				
FET	sec			7.42				

## FLOW/VOLUME GRAPHICS



## VOLUME/TIME GRAPHICS




MALIK RADIX HEALTH CARE PVT. LTD.  
 C-217, C-218, Nirman Vihar,  
 Delhi-110092  
 Ph.: 011-49287450, 011-61381379  
 Regd. No. 607



## Echocardiogram Report

Patient Name	MR. SANJEEV KUMAR GUPTA
Date of Test	06/03/2024
Age	52 YRS/ MALE
Ref. by	MEDIWHEEL

Dimensions	Result	Normal Range
AO (ed)	2.1 cm	( 2.1 -3.7cm)
LA (es)	2.9 cm	(2.1 -3.7cm)
RVID (ed)	2.0 cm	(1.1-3.0cm)
LVID (ed)	4.3 cm	(3.6 – 5.5 cm)
LVID (es)	3.1 cm	(2.3-3.9cm)
IVS (ed)	1.1 cm	(0.6 – 1-2 cm)
LVPW (ed)	1.1 cm	(0.6 – 1-2 cm)
EF	56 %	
FS	28 %	(28 % - 42 %)

### Impression

- NO REGIONAL WALL MOTION ABNORMALITY SEEN.
- LVEF= 56 %
- NORMAL CHAMBER DIMENSIONS.
- NORMAL MIP.
- TRACE TRICUSPID REGURGITATION. NORMAL PA PRESSURE.
- NO INTRA CARDIAC CLOT/MASS/ VEGETATION/PERICARDIAL EFFUSION SEEN.

Dr. Sheikh Nazeem Ahmed  
 M.D. "Physician" PGDCC  
 (Consultant Non – Invasive Cardiologist)

#### Facilities Available

Multispeciality Hospital - 24 Hours Emergency - X-Ray/ ECG/ Ultrasound/ CT Scan - Dental - Fully Equipped Operation Theatre  
 Fully Functional Lab - 24/7 Casualty/ ICU-Nursery 24/7 Pharmacy - Labour Room - All Specialty OPD - Laproscopic Surgery -  
 ECHO - Plastic Surgery



**LAB REPORT**

Reg. Date	06/03/2024	Patient Id	2403060001	DOB.	18/11/1971
Name	MR. SANJEEV KUMAR GUPTA	Gender	M	Perm. ID	
Age	52 Yrs. 3 Mn. 18 Day	Panel	MEDIWHEEL	Reported	06/03/2024 16:38:45
Ref. By	MEDIWHEEL				

Test Name	Result	Units	Ref. Range
-----------	--------	-------	------------

Full Body Plus Annual Check Advanced Mal

**HAEMATOLOGY**

**COMPLETE HAEMOGRAM**

HAEMOGLOBIN (HB%)	15.7	gm/dl	13 - 18
TOTAL LEUCOCYTE COUNT (TLC)	7,700	/cumm	4000 - 11000

**DIFFERENTIAL LEUCOCYTE COUNT (DLC)**

NEUTROPHIL	68	%	40 - 80
LYMPHOCYTE	25	%	28 - 55
MONOCYTE	05	%	02 - 10
EOSINOPHIL	02	%	01 - 06
BASOPHIL	00	%	0 - 0
ESR (WESTEGREN'S METHOD)	12	mm/1st hr.	0 - 10
R B C COUNT	5.07	Millions/cmm	4.247 - 5.4
P.C.V / HAEMATOCRIT	48.9	%	40 - 54
M C V	96.4	fL	80 - 100
M C H	31.0	Picogram	27.0 - 31.0
M C H C	32.1	gm/dl	33 - 37
PLATELET COUNT	1.91	Lakh/cu mm	1.50 - 4.50

BLOOD GROUP ABO

RH TYPING

BLOOD SUGAR FASTING

BLOOD SUGAR PP

**THYROID PROFILE**

Free T3 ELFA	2.96	ng/ml	02 - 04
Free T4 ELFA	2.01	ug/dl	0.8 - 2.7

Checked by : \_\_\_\_\_  
 Page 1 Contd...2

If test results are alarming or unexpected, patient is advised to contact the laboratory immediately for possible remedial action.

**Facilities Available**

- Multispeciality Hospital - 24 Hours Emergency - X-Ray/ ECG/ Ultrasound/ CT Scan - Dental - Fully Equipped Operation Theatre
- Fully Functional Lab - 24/7 Casualty/ ICU-Nursery 24/7 Pharmacy - Labour Room - All Speciality OPD - Laproscopic Surgery - ECHO - Plastic Surgery



**LAB REPORT**

Reg. Date	06/03/2024	Patient Id	2403060001	DOB	18/11/1971
Name	MR. SANJEEV KUMAR GUPTA	Gender	M	Perm. ID	
Age	52 Yrs. 3 Mn. 18 Day	Panel	MEDIWHEEL	Reported	06/03/2024 16:38:45
Ref. By	MEDIWHEEL				

Test Name	Result	Units	Ref. Range
TSH <small>Serum/ELFA</small>	6.480	uIU/ml	0.25 - 5.50 uIU/ml

**Interpretation**

**Clinical Use**

- Diagnose Hypothyroidism and Hyperthyroidism
- Monitor T4 replacement or T4 suppressive Therapy
- Quantify TSH levels in the subnormal range

Increased Levels : Primary Hypothyroidism Subclinical Hypothyroidism, TSH dependent, Thyroid Hormone Resistance.

Decreased Levels : Grave's Disease, Autonomous Thyroid Hormone Secretion, TSH Deficiency

**LIPID PROFILE**

TOTAL CHOLESTEROL	181.00	mg/dL	130.0 - 200.0 (<200)
TRIGLYCERIDES	120.00	mg/dL	80.5 - 150.0 (<150)
H D L CHOLESTEROL DIRECT	38.48	mg/dL	35.0 - 60.0 (<40->59)
V L D L	24.0	mg/dL	4.0 - 30. (23-45)
L D L CHOLESTEROL	118.5	mg/dL	50.0 - 150.0 (50-150)
TOTAL CHOLESTEROL / HDL RATIO	4.7		3.3 - 5.1
LDL / HDL CHOLESTEROL RATIO	3.1		1.5 - 3.5

**LIVER FUNCTION TEST (LFT)**

BILIRUBIN TOTAL	1.04	mg/dl	0.2 - 1.2
-----------------	------	-------	-----------

Checked by : \_\_\_\_\_  
Page 2 Contd...3

If test results are alarming or unexpected, patient is advised to contact the laboratory immediately for possible remedial action.

**Facilities Available**

- Multispeciality Hospital - 24 Hours Emergency - X-Ray/ ECG/ Ultrasound/ CT Scan - Dental - Fully Equipped Operation Theatre
- Fully Functional Lab - 24/7 Casualty/ ICU-Nursery 24/7 Pharmacy - Labour Room - All Speciality OPD - Laproscopic Surgery - ECHO - Plastic Surgery



**LAB REPORT**

Reg. Date	06/03/2024	Patient Id	2403060001	DOB	18/11/1971
Name	MR. SANJEEV KUMAR GUPTA	Gender	M	Perm. ID	
Age	52 Yrs. 3 Mn. 18 Day	Panel	MEDIWHEEL	Reported	06/03/2024 16:38:45
Ref. By	MEDIWHEEL				

Test Name	Result	Units	Ref. Range
CONJUGATED (D. BILIRUBIN)	0.28	mg/dl	0.00 - 0.3
UNCONJUGATED (L.D. BILIRUBIN)	0.76	mg/dl	0.2 - 0.9
SGOT / AST	35.20	IU/L	0 - 35
SGPT / ALT	36.2	IU/L	0 - 35
ALKALINE PHOSPHATASE	145.60	U/L	64 - 306
TOTAL PROTEIN	8.70	gm/dl	6.0 - 8.3
ALBUMIN	4.50	gm/dl	3.2 - 5.0
GLOBULIN	4.20	gm/dl	2.5 - 5.6
A/G RATIO	1.07		0.9 - 2.0
GAMMA GT	20.40	IU/L	0.0 - 45.0
SERUM CREATININE	0.80	mg/dl	0.7 - 1.4
SERUM URIC ACID	6.28	mg/dl	3.4 - 7.0
BLOOD UREA NITROGEN (BUN)	13.20	mg/dl	6.0 - 21.0
BUN/CREAT RATIO	16.5	mg/dl	
TOTAL PSA <small>Chemiluminescence</small>	0.98	ng/ml	

10 - 20

**INTERPRETATION :**

**Expected Values :**

99%	:	of Healthy males	0.0-4.0 ng/ml
80%	:	of Benign prostatic hypertrophy	0.0-4.0 ng/ml
81%	:	of Prostatic Carcinomas	Above 4.0 ng/ml

**PSA** is reliable tumour marker for already diagnosed prostatic carcinomas. It is uniquely associated only with prostatic tissue, and therefore is specific for it. Baseline levels measured prior to therapeutic intervention and followed later by serial periodical measurements will predict the outcome of therapy. It also helps in early discovery of recurrences, relapses and metastases.

Urine Routine Examination

Checked by : \_\_\_\_\_  
Page 3 Contd...4

If test results are alarming or unexpected, patient is advised to contact the laboratory immediately for possible remedial action.

**Facilities Available**

- Multispeciality Hospital - 24 Hours Emergency - X-Ray/ ECG/ Ultrasound/ CT Scan - Dental- Fully Equipped Operation Theatre
- Fully Functional Lab - 24/7 Casualty/ ICU-Nursery 24/7 Pharmacy - Labour Room - All Speciality OPD - Laproscopic Surgery - ECHO - Plastic Surgery



**LAB REPORT**

Reg. Date	06/03/2024	Patient Id	2403060001	DOB.	18/11/1971
Name	MR. SANJEEV KUMAR GUPTA	Gender	M	Perm. ID	
Age	52 Yrs. 3 Mn. 18 Day	Panel	MEDIWHEEL	Reported	06/03/2024 16:38:45
Ref. By	MEDIWHEEL				

Test Name	Result	Units	Ref. Range
-----------	--------	-------	------------

**PHYSICAL EXAMINATION**

QUANTITY	30	ml.	
COLOUR	Pale Yellow		Pale Yellow
TRANSPARENCY	Clear		
SPECIFIC GRAVITY	1.010		
PH	6.0		

**CHEMICAL EXAMINATION**

ALBUMIN	(+)
SUGAR	Nil

**MICROSCOPIC EXAMINATION**

PUS CELLS	1-2	/HPF
RBC'S	Nil	/HPF
CASTS	Nil	
CRYSTALS	NIL	
EPITHELIAL CELLS	1-2	/HPF
BACTERIA	Nil	
OTHERS	Nil	

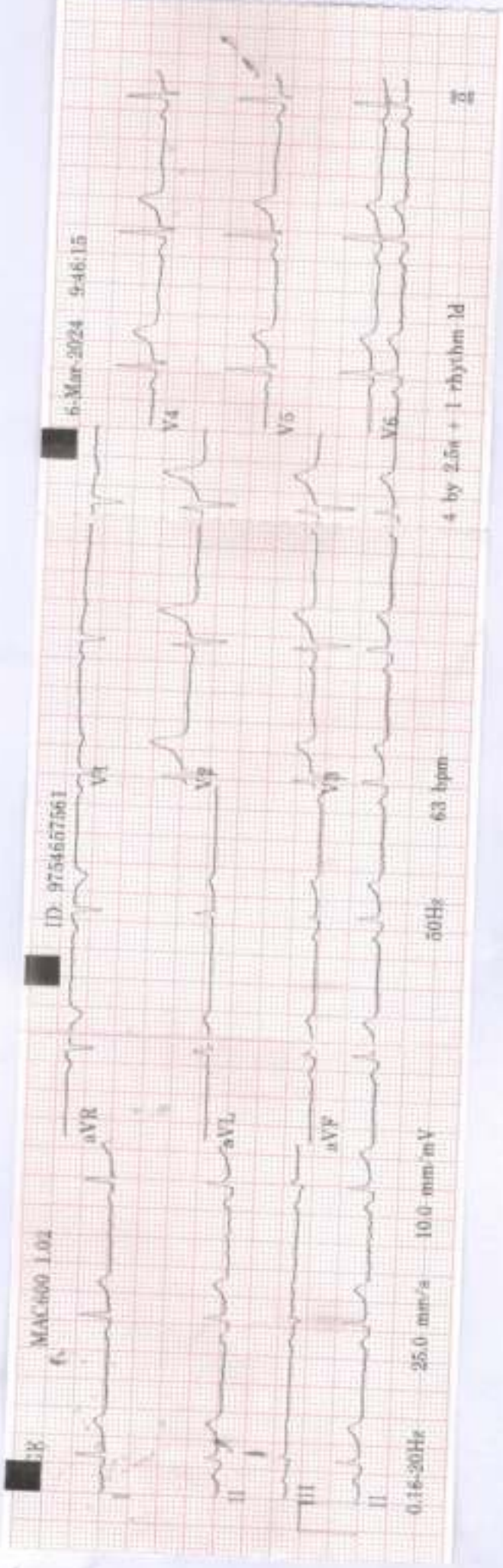
**Dr. REEJA DAHIYA**  
 DR. REEJA DAHIYA (Path)  
 M.B.B.S, M.D. Pathology  
 Malik Radix Healthcare Pvt. Ltd.  
 Checked by: [Signature]  
 Delhi-110092

**DR. MEENU AGGARWAL**  
 M.B.B.S, MD (Path.)

If test results are alarming or unexpected, patient is advised to contact the laboratory immediately for possible remedial action.

**Facilities Available**

- Multispeciality Hospital - 24 Hours Emergency - X-Ray/ ECG/ Ultrasound/ CT Scan - Dental- Fully Equipped Operation Theatre
- Fully Functional Lab - 24/7 Casualty/ ICU-Nursery 24/7 Pharmacy - Labour Room - All Speciality OPD - Laproscopic Surgery - ECHO - Plastic Surgery



ID: 9754657561 **Sanjeer Kumar Gupta**

52years Male

Heart rate	63 bpm
QRS duration	60 ms
QT/QTc	342/349 ms
PR interval	154 ms
P duration	102 ms
RR interval	952 ms
P-R-T axes	58 31 44

MAC600 1.02 1.3SL™ v239



# Malik Radix HealthCare.

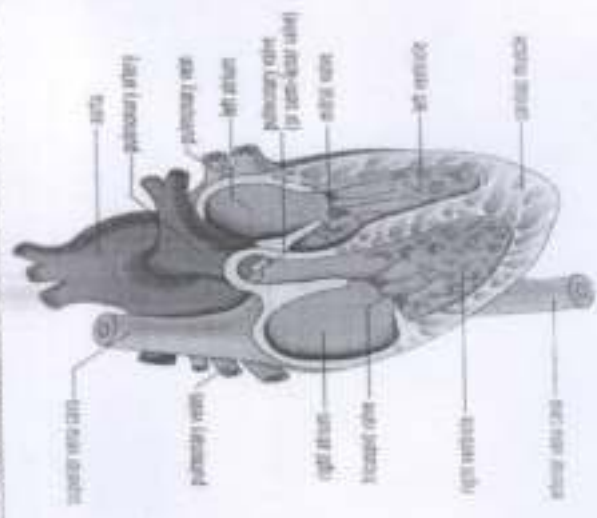
## ELECTROCARDIOGRAM

Name: MR. SANJEEV KUMAR GUPTA

Age & Sex: 52 YR/ MALE

Ref By: MED/WHEEL

Date: 06/03/2024



### ECG FINDINGS:


Rate 63 bpm Rhythm Sinus Mechanism Normal

Axis Normal P Wave Normal PR Interval 0.15/Sec

QRS Complex Normal QT Interval Normal Q Wave Normal

ST Segment Abnormal T Wave Abnormal

Conclusion Sinus Rhythm, Non specific ST & T wave changes, ST elevation in-inferior leads. To be correlate.

Doctors Signature:  DR. SHEIKH MAZIR AHMED  
M.D. Physician  
PGDCC  
DMC-46499



**CONSULTANTS ON PANEL**

- PAEDIATRICS**  
Dr. Naveen Malik (MBBS, MD)  
Dr. Neel Prasad (MBBS, MD, PhD)  
Dr. Ritu Jain (MBBS, MD)
- Gynaecology**  
Dr. Naveen Malik (MBBS, MD)  
Dr. Pooja Mahesh (MBBS, MD)  
Dr. Neel Prasad (MBBS, MD)  
Dr. Manoj Gupta (MBBS, MCh)  
Dr. Vinita Singh (MBBS, MD)  
Dr. Rajesh Arora (MBBS, MD)
- DENTAL**  
Dr. Shrutika Malik (BDS, MCh)  
Dr. Anshu Saxena (BDS, MCh)  
Dr. Rishi Thakur (BDS, MCh)  
Dr. Mohit Mangal (BDS, MCh)  
Dr. Tarun Mittal (BDS, MCh)  
Dr. Sneha Sharma (BDS)  
Dr. Shilpa Verma (BDS)
- CHILD GASTROENTEROLOGY**  
Dr. U. S. Mittal (MBBS, MD)
- Medicine**  
Dr. A. S. Talwar (MBBS, MD)  
Dr. Sunil Dhillon (MBBS, MD)  
Dr. Suresh Rajpal (MBBS, MD)
- RESPIRATORY MEDICINE/PULMONOLOGY**  
Dr. Adhish Chandra (MBBS, DNB)
- LAPAROSCOPIC SURGERY**  
Dr. Ajay Jain (MBBS, MD)  
Dr. Deepak Garg (MBBS, MD)  
Dr. Praveen Saxena (MBBS, MD)  
Dr. U. S. Gang (MBBS, MD)
- ORTHOPAEDICS**  
Dr. Vikas Shrivastava (MBBS, MD, DOrtho, DNB)  
Dr. Pradeep Aggarwal (MBBS, MD, DOrtho)  
Dr. V. S. Tewari (MBBS, MD, DOrtho)  
Dr. Deepak Kumar Arora (MBBS, MD, DOrtho)
- EYE/OPTHALMOLOGY**  
Dr. Nishi Gupta (MBBS, MD, DNB, FICO)  
Dr. Harshdeep Singh Puri (MBBS, MD)
- ENT**  
Dr. Harish Kumar Singh (MBBS, MD)  
Dr. Praveen Sharma (MBBS, MD)  
Dr. Ashish Singh (MBBS, MD)  
Dr. A. K. Lohan (MBBS, MD)
- RADIOLOGY/ULTRASOUND**  
Dr. R. K. Singh (MBBS, DNB)  
Dr. T. K. Jaiswal (MBBS, MD)  
Dr. Rajesh Mahesh (MBBS, MD)  
Dr. Ashish Kumar (MBBS, MD)
- PATHOLOGY**  
Dr. Neema Datta (MBBS, MD, FRCM)  
Dr. Manish Aggarwal (MBBS, MD, FRCM)
- ANAESTHESIA**  
Dr. Ajaykumar Dhillon (MBBS, MD)  
Dr. Naveen Arora (MBBS, MD)  
Dr. R. K. Arora (MBBS, MD)  
Dr. Saamir Gang (MBBS, MD)
- DERMATOLOGY**  
Dr. Shikha Jha (MBBS, MD)
- PLASTIC & COSMETIC SURGERY**  
Dr. Anand Jain (MBBS, MD, MCh)
- PAEDIATRIC SURGERY**  
Dr. Dharmendra Singh (MBBS, MD, MCh)  
Dr. Saksh Aggarwal (MBBS, MD, MCh)
- PAEDIATRIC NEPHROLOGY**  
Dr. A. S. Mittal (MD, Dip in Paeds)
- NEPHROLOGY**  
Dr. Jyoti (MBBS, MD, Nephro)
- CARDIOLOGY**  
Dr. Nishant Singh (MBBS, MD)
- NEUROLOGY**  
Dr. Anshu Saxena (MBBS, MD)
- GASTROENTEROLOGY**  
Dr. Deepak Lohan (MBBS, MD)  
Dr. Naveen Aggarwal (MBBS, MD)  
Dr. Ashish Gupta (MBBS, MD)  
Dr. Anil Kashyap (MBBS, MD)
- UROLOGY**  
Dr. Naveen Sharma (MBBS, MD)  
Dr. Anshu Saxena (MBBS, MD)
- PSYCHIATRY**  
Dr. Manish Sharma (MBBS, MD)
- PHYSIOTHERAPY**  
Dr. Gita Dhillon  
Dr. Neel Kumar
- NUTRITIONIST**  
Dr. Deepika Katiel  
Dr. Sakshi Bhatnagar
- CLINICAL PSYCHOLOGIST**  
Dr. Sneha Singh

## Dr. Shrutika Malik

BDS, MDS (Endodontics)  
☎ +91-9899561092

**Timings : 10:00 am. to 2:00 pm.  
6:00 pm. to 8:30 pm.**

**CLINICAL EXAMINATION:-**

1. TMJ:-

*Routine checkup*

2. DENTAL STATUS:

*M.H. - H/O Diabetes mellitus  
(on medications)*

- a. Caries Teeth :
- b. Fracture Teeth :
- c. Root Stumps :
- d. Gingivitis :
- e. Periodontitis :
- f. Impacted Teeth :
- g. Malaligned Teeth :

*- Cholecystectomy.*

*- Abdominal Tuberculosis*

*9/8 Stains +  
Calculi +*

3. ORAL LESIONS:-

*Caries  
(Initial)*



4. DIAGNOSIS:-

5. TREATMENT PLANNING:

*Adv. P-Kit*

6. FOLLOW UP:-


Referral To Other Consultant: Yes/ No

If Yes, please mention the Name: .....

Doctor's Signature *Annu*

**Facilities Available :**

- \* MULTI-SPECIALITY HOSPITAL \* MODULAR FULLY EQUIPPED OT \* NURSERY \* LAPROSCOPIC SURGERY
- \* 24X7 EMERGENCY \* OPG \* DENTAL \* 24X7 DIAGNOSTICS \* LABOUR ROOM \* ECHO \* EEG \* DIGITAL X-RAY \* CT SCAN
- \* ECG \* ULTRASOUND \* RICU/ICU \* ALL SPECIALITY OPD \* PLASTIC & COSMETIC SURGERY \* DIALYSIS \* PHARMACY





UHID	PT208149	LAB No.	XRY2310494
Name	Mr. SANJEEV KUMAR GUPTA	Regn. No.	GEN2341451
Age / Sex	52 Yrs / M	Receiving Dt/Time	06-Mar-2024 09:28
		Reporting Dt/Time	06-Mar-2024 09:51 AM



**XRAY**

**CHEST (PA)**

Both lung fields are normal.

Cp angles are clear.

Hila are normal...

Heart size appears within normal limits.

Soft tissue shadows and bony thorax are normal.

**IMP- NORMAL CHEST X-RAY**

Advised...please correlate clinically.

\*\*\*\*\* END OF REPORT \*\*\*\*\*

DR. K.K. SINHA  
 M.B.B.S. D.M.R.D.  
 SENIOR CONSULTANT  
 Reg. No. 25437 (DMC)

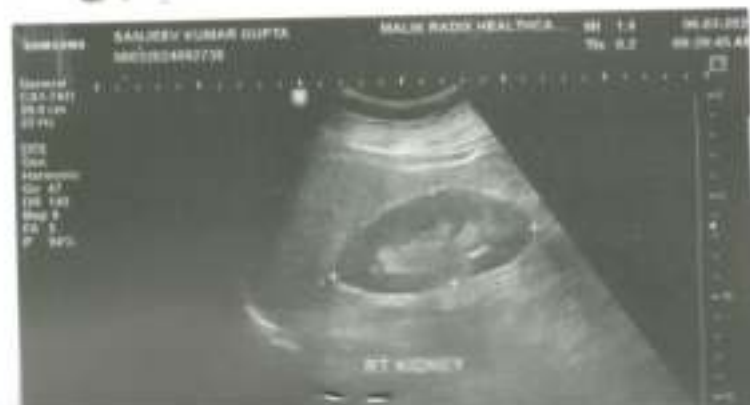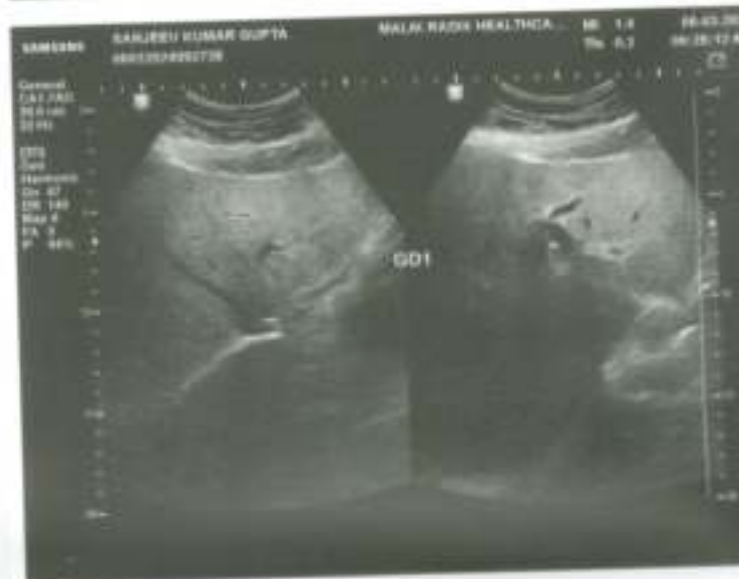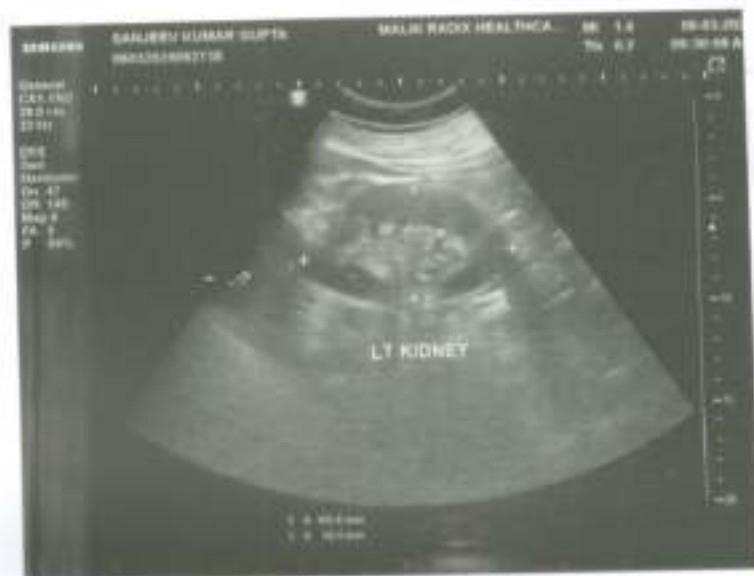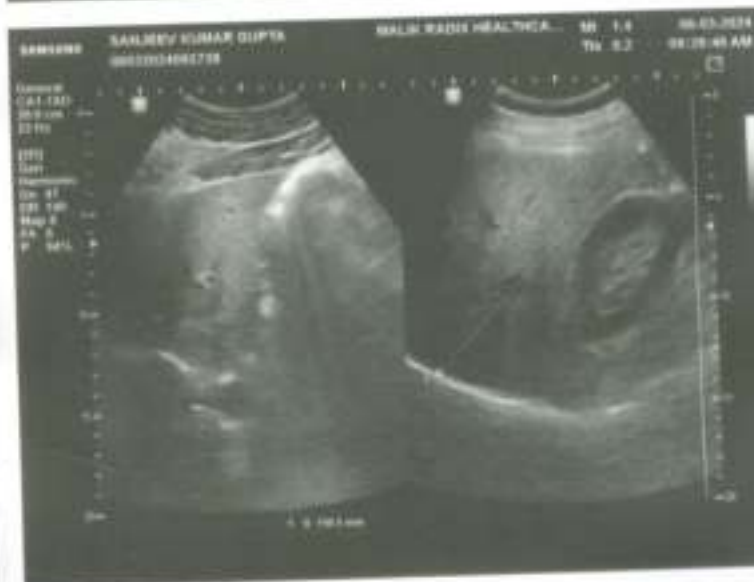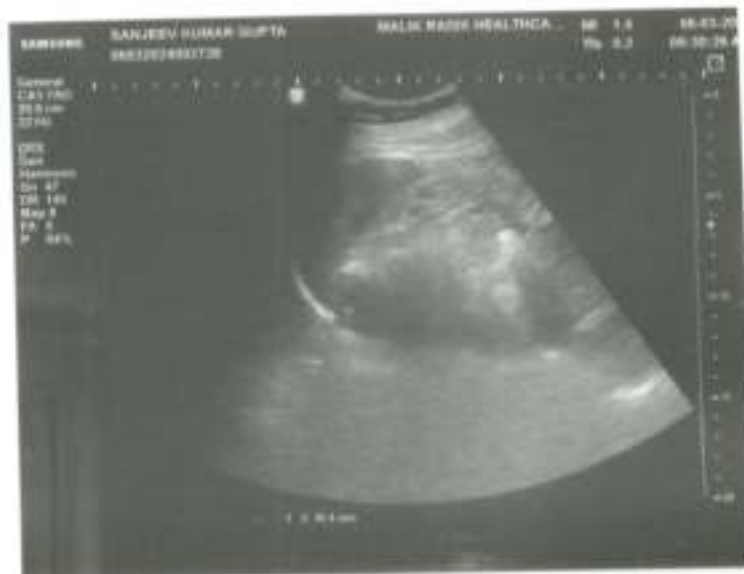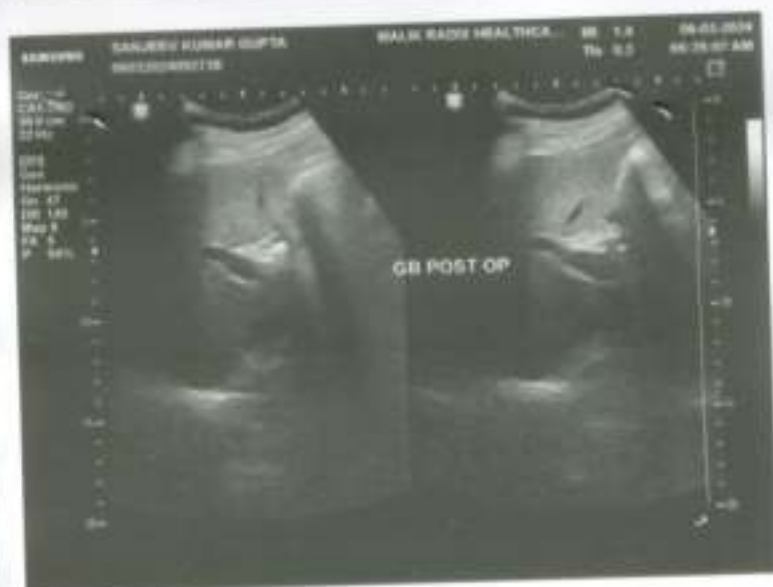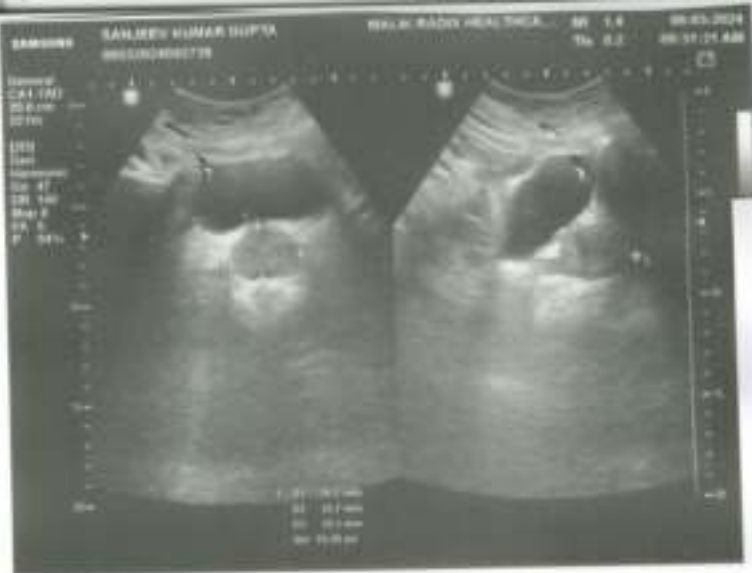DR. RAJESH MALHOTRA  
 MBBS, MD (RADIOLOGY)  
 CONSULTANT RADIOLOGY  
 Reg.No.DMC9299

DR. T. K. VOHRA  
 MD (RADIODIAGNOSIS)  
 SENIOR CONSULTANT  
 Reg. No. 3272 (DMC)

DR. MIKESH KOSHAL  
 MBBS, MD (RADIOLOGY)  
 CONSULTANT RADIOLOGY  
 Reg.No.DMC10407

DR. SHREYASH TIWARY  
 MBBS, MD (RADIOLOGY)  
 CONSULTANT RADIOLOGY  
 Reg.No.DMC85802

**Facilities Available**





NAME	MR. SANJEEV KUMAR GUPTA	AGE	52 YRS/M
REFD. BY.	HEALTH CHECK UP	DATE	06.03.24

### Ultrasound Examination of Whole Abdomen & Pelvis:

**Liver:** Liver appears normal in size (15.0 cm) with normal outlines and shows increased parenchymal echotexture. No focal SOL is seen in liver. IHBR & portal radicles are normal.

**Gallbladder:** Gallbladder is not visualized (Post-cholecystectomy)

**Pancreas:** Pancreas shows normal size, outlines & echotexture. No focal lesion is seen. MPD is not dilated.

**Spleen:** Spleen shows normal size (8.8 cm), outline & echotexture.

**Kidneys:** Kidneys show normal size, shape, position & echotexture. No calculus/ hydronephrosis or SOL is seen in kidneys. Cortico- medullary differentiation and cortical thickness is normal on both sides.

Right kidney measures -10.1 x 4.6 cm

Left kidney measures -10.2 x 5.4 cm

Great abdominal vessels are normal.

No ascites seen.

No para-aortic lymph nodes seen.

**Urinary bladder** Urinary bladder is well distended. Walls and lumen appear normal.

Prostate is normal in size (16.5 cc) with normal outline and echotexture. No focal lesion is seen.

### IMPRESSION:

Grade I Fatty Liver

Dr Shreyash Tiwary MD ( Rad- diag)

Regn. No. DMC 85802

RADIOLOGIST :

Facilities Available