



Shubham Imaging & ALC Diagnostic Center

ISO 9001:2015 Certified center

(A Unit of P.K. Arogyam Health & Wellness Center)

E-95, P.C. Colony, Near Sai Netryalaya Transformer, Kankarbagh, Patna - 20

www.pkrogyamhealthcheckup.com

7030037694, 8271706196

aldiagnostics@gmail.com

OPINION MUST BE CORRELATES WITH CLINICALLY & OTHER INVESTIGATION FOR FINAL DIAGNOSIS. NOT FOR MEDICO LEGAL PURPOSE

Pt. Name :- RADHA PRAKASHI
Ref. By :- DR./MEDHWHEEL

Date:- 25-Mar-23
Age / Sex - 38 Yrs. F.

Thanks for your kind referral

X-RAYCHEST (P.A.VIEW)

The lungs on the either side show equal translucency.

The peripheral pulmonary vasculature is normal.

No focal lung lesion is seen.

The pleural spaces are normal.

Both hila are normal in size, have equal density and bear normal relationship.

The heart and trachea are central in position and no mediastinal abnormality is visible.

The cardiac size is normal.

The domes of the diaphragms are normal in position, and show smooth outline.

IMPRESSION

- NO EVIDENCE OF PULMONARY OR CARDIAC PATHOLOGY IS NOTED.

25/3/23

Consultant Radiologist

ESTB BY:-

Dr. P. K. Tiwari
MD, M.Sc (Radio Imaging)
Ph.D (All Nuclear Medicine)
Consultant Imagnionologist & Sonologist

Dr. S. Kumar MD (Pat)
Consultant Pathologist
Dr. Abhishhek Kumar MBBS, MD
Consultant Neuropatho Physiologist

Dr. Kumari Suman MBBS, DGO, MD
Consultant (TVS & HSG specialist)
Dr. A. K. Singh MBBS, FCDDMCH
Consultant Radiologist Esoneologist

PRINTING MISTAKE SHOULD BE REPORTED BACK IMMEDIATELY/ यहाँ जन्म से पहले गृह का तिरा नहीं होता है ।





Shubham Imaging & ALC Diagnostic Center

ISO 9001:2015 Certified center
(A Unit of P. K. Arogyam Health & Wellness Center)

E-95, P. C. Colony, Near Sai Netryalaya Transformer, Kankarbagh, Patna - 20
www.pkarogyamhealthcheckup.com
7050037694, 8271206196

alcdiagnostics@gmail.com

OPINION MUST BE CORRELATES WITH CLINICALLY & OTHER INVESTIGATION FOR FINAL DIAGNOSIS. NOT FOR MEDICO LEGAL PURPOSE

Pt. Name :- **RADHA PRAKASH**
Ref. By :- **DR./MEDITHIEL**

Date:- **25-Mar-23**
Age / Sex - **38 Yrs. F**

REAL TIME U.S.G. OF WHOLE ABDOMEN
Thanks for your kind referral

(Report.)

LIVER

:- Measures 15.98 cm. Mild Enlarged in shape, size and echo texture fatty
Change seen in liver parenchyma .J.H.B.R. are not dilated.
Hepatic veins are normal. No SOL seen.

G.B.L.

:- Lumen is echo free. Wall thickness appears normal.

C.B.D.

:- Measures 3.5 mm in diameter with echo free lumen. No calculi or mass seen.

P.V.

:- Measures 7.7 mm in diameter. Appears normal. No thrombus seen.

PANCREAS

:- Normal in shape, size and echo texture. No calcification mass seen.

SPLEEN

:- Measures 12.33 cm. Mild Enlarged in shape, size and echo texture.
No SOL seen.

KIDNEY

:- Both kidney shows normal shape, size & echotexture. C.M.D.intact.
P.C.S.is not dilated. No calculi, cyst or hydronephrosis seen on either side.

Right Kidney :- Measures 10.97 X 4.37 cm.

Left Kidney :- Measures 9.74 X 4.15 cm.

URETER

:- Not dilated. No apparent calculi seen.

U.BLADDER:-

Shows normal in outline with echo free lumen. No calculi or mass seen.

Pre void - 320 ml. Post void - is in significant

UTERUS

:- Is Enlarged and bulky in size measures 9.46 X 5.63 cm and
Anteverted in Position. Echogenicity of Myometrium is increased.

No focal mass lesion seen. Cervix appear normal.

ADNEXA

:- Both ovary appears normal in size and shape.

Rt Ovary Measures - 3.10 cm L1 Ovary Measures 2.30 cm

P.O.D

:- Mild collection seen in P.O.D.

R.I.F.


:- Son graphically no appendicular mass or collection seen.

OTHERS

:- No Ascites No Lymph Adenopathy. No pleural Effusion seen on either side

IMPRESSION

- **Mild Hepatomegaly With Fatty liver G-1**
 - **Mild Splenomegaly**
 - **Enlarged Bulky Uterus With Mild Collection Seen In POD-? PID**
 - **Adv:- Further work up/ other investigation**
- Otherwise son graphically normal scan. of rest organs*


25/3/23

ESTD BY:-

Consultant Radiologist

Dr. P. K. TIWARI
MD, M.Sc (Radio Imaging)
Ph.D (All Nuclear Medicine)
Consultant Imgiologist & Sonologist

Dr. S. Kumar
MD (Pat)
Consultant Pathologist

Dr. Abhishek Kumar
MBBS, MD
Consultant Neuropatho Physiologist

Dr. Kumari Suman
MBBS, DGO, MD
Consultant (Tvs & HSG Specialist)

Dr. A. K. Singh
MBBS, PGDMCH
Consultant Radiolnater s-consultant



Shubham Imaging & ALC Diagnostic Centre

ISO 9001:2015 Certified center

(A Unit of P.K. Arogyam Health & Wellness Center)

E-95, P.C. Colony, Near Sai Netryalaya Transformer, Kankarbagh, Patna - 20

alcdiagnostics@gmail.com

www.pkarogyamhealthcheckup.com

7050037694, 8271206

OPINION MUST BE CORRELATES WITH CLINICALLY & OTHER INVESTIGATION FOR FINAL DIAGNOSIS. NOT FOR MEDICO LEGAL PURPOSE

PATIENT NAME : Mrs. RADHA PRAKASH PATIENT ID : 3455
COL DATE : 25/03/2023 REPORTING DATE: 25/03/2023 AGE SEX : 38 YRS/F
REF.BY : DR. / MEDIWHEEL

TEST NAME	RESULT	Unit	REF.RANGE
BLOOD SUGAR (F)	81.0 mg/dl		70 -110 mg/dl
BLOOD SUGAR (PP)	106.0 mg/dl		70 -140 mg/dl
LIPID PROFILE:-			
TOTAL CHOLESTROL	160.4 mg/dl		130 -250 mg/dl
TRIGLYCERIDE	148.5 mg/dl		50 -160 mg/dl
HDL CHOLESTROL	42.0 mg/dl		30 - 60 mg/dl
LDL CHOLESTROL	88.7 mg/dl		80 -130 mg/dl
VLDL CHOLESTROL	29.7 mg/dl		15 - 40 mg/dl
T.CH./HDL RATIO	3.8 :1		Upto 5 :1
LDL /HDL RATIO	2.1 :1		2 - 4:1

ESTB BY:-


Dr. P. K. Tiwari
MD, M.Sc (Radio Imaging)
Ph.D (Alt Nuclear Medicine)
Consultant Imagonologist & Sonologist

Dr. S. Kumar
MD (Pat)
Consultant Pathologist

Dr. Abhishek Kumar
MBBS, MD
Consultant Neuropatho Physiologist

Dr. Kumari Suman
MBBS, DGO, MD
Consultant (TVS & HSG Specialist)

Dr. A. K. Singh
MBBS, PGDMCH
Consultant Radiologist & Sonologist


25/03/2023
Consultant Radiologist

PRINTING MISTAKE SHOULD BE REPORTED BACK IMMEDIATELY/ यहाँ जन्म से पहले भ्रूण का लिंग जाँच नहीं होता है ।



Scanned with OKEN Scanner

Shubham Imaging & ALC Diagnostic Center

ISO 9001:2015 Certified center

(A Unit of P.K. Arogyam Health & Wellness Center)

E-95, P.C. Colony, Near Sai Netryalaya Transformer, Kankarbagh, Patna - 20

alcdiagnostics@gmail.com

www.pkarogyamhealthcheckup.com

7050037694, 8271206196

OPINION MUST BE CORRELATES WITH CLINICALLY & OTHER INVESTIGATION FOR FINAL DIAGNOSIS. NOT FOR MEDICO LEGAL PURPOSE
PATIENT ID: 3455

PATIENT NAME : Mrs. RADHA PRAKASH

COL DATE : 25/03/2023 REPORTING DATE: 25/03/2023 AGE SEX:- 38 YRS/F

REF.BY : DR. / MEDIWHEEL .

TEST NAME	RESULT	Unit	REF.RANGE
LFT:-			
SGPT	36.7	IU/L	5 - 40 IU/L
S G O T	19.2	IU/L	5 - 40 IU/L
ALKALINE PHOSPHATASE	93.2	IU/L	M - 53 - 165 IU/L F - 42 - 136 IU/L
TOTAL PROTIN	7.0	g/dl	6.0 - 8.7 g/dl
SERUM ALBUMIN	4.2	g/dl	3.5 - 5.4 g/dl
SERIUM GLUBLINE	2.8	g/dl	2.3 - 3.6 g/dl
AG RATIO	1.5 : 1		1.0 - 2.3 g/dl
BILIRUBIN			
TOTAL	0.55	mg/dl	0.1 - 1.1 mg/dl
DIRECT	0.21	mg/dl	0.0 - 0.32 mg/dl
INDIRECT	0.34	mg/dl	0.0 - 0.78 mg/dl
GGTP(GGT)	22.0	iu/L	8 - 38 iu/L
KFT/RFT			
URIC ACID	4.0	mg/dl	3.2 - 7.0 mg/dl
SERUM CREATNINE	0.8	mg/dl	0.6 - 1.5 mg/dl
BLOOD URIA	30.4	mg/dl	5 - 45 mg/dl
BLOOD URIA NITROZEN(BUN).	14.1	mg/dl	5 - 23 mg/dl

APC
25/03/2023

Consultant Radiologist

ESTB BY:-

Dr. P. K. Tiwari
MD, M.Sc (Radio Imaging)
Ph.D (Alt Nuclear Medicine)
Consultant Imagiologist & Sonologist

Dr. S. Kumar
MD (Pat)
Consultant Pathologist

Dr. Abhishek Kumar
MBBS, MD
Consultant Neuropatho Physiologist

Dr. Kumari Suman
MBBS, DGO, MD
Consultant (TVS & HSG Specialist)

Dr. A. K. Singh
MBBS, PGDMCH
Consultant Radiologist & Sonologist

PRINTING MISTAKE SHOULD BE REPORTED BACK IMMEDIATELY/



Scanned with OKEN Scanner

ID: 3455 CASE:
AGE: 38 Y M D 85K0
Cms

RADHA PRAKASH

25/03/2023 10:40:18
ALC ADVANCE IMAGING DIAGNOSTICS
E95 PC COLONY KANKARBAGH PATNA

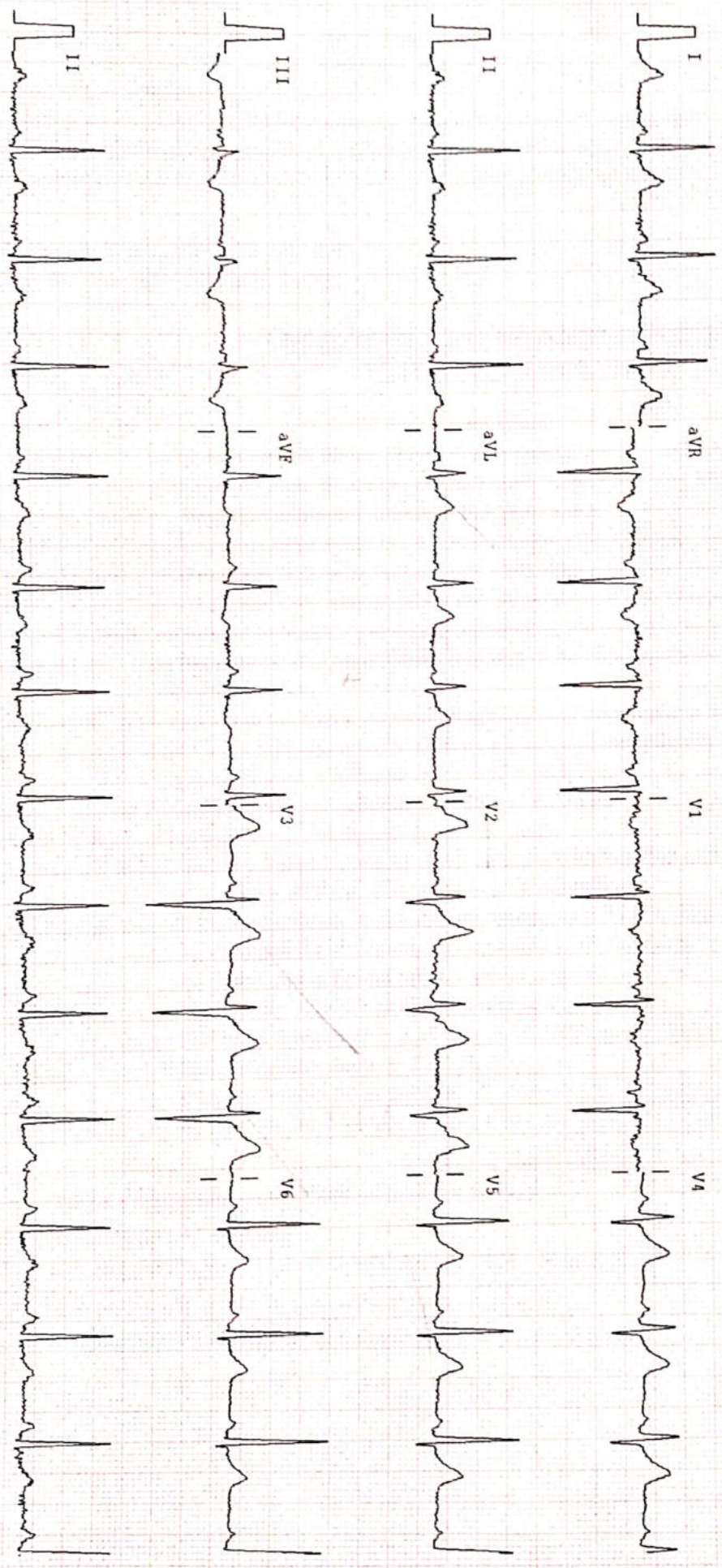
RATE : 83 bpm SINUS RHYTHM
P-R : 718 ms INFERIOR T WAVE ABNORMALITY IS NONSPECIFIC
P-R : 130 ms
QRS : 82 ms
QT : 354 ms
QTc : 394 ms

--AXIS--
P : 50°
QRS : 39°
T : -03°

12 SL: REPORT FORMAT: 3x4+1L SQ

REF: DR MEDI WHEEL

Dr. DR ABHISHEK KUMAR MD



25mm/sec 10mm/mV Notch: ON BLC: ON 0.05 35Hz ALLENGERS PISCES 1012(VER. 1.8) CLINICALLY CORRELATE THE FINDINGS.

Shubham Imaging & ALC Diagnostic Center

ISO 9001:2015 Certified center

(A Unit of P.K. Arogyam Health & Wellness Center)

E-95, P.C. Colony, Near Sai Netryalaya Transformer, Kankarbagh, Patna - 20

alcdiagnostics@gmail.com

www.pkarogayamhealthcheckup.com

7050037694, 8271206196

OPINION MUST BE CORRELATES WITH CLINICALLY & OTHER INVESTIGATION FOR FINAL DIAGNOSIS. NOT FOR MEDICO LEGAL PURPOSE

PATIENT NAME : Mrs. RADHA PRAKASH

PATIENT ID: 3455

COL DATE

: 25/03/2023

REPORTING DATE: 25/03/2023

AGE SEX : 38 YRS/F

REF.BY

: DR./ MEDIWHEEL.

GLYCOSYLATED HEMOGLOBIN

TEST NAME	RESULT	Unit	REF.RANGE
HbA1c	3.4 %		Below 5.7 % : Normal 5.7 – 6.4 % : Prediabetic > = 6.5 % : Diabetic
AVERAGE PLASMA GLUCOSE	93.0 mg/dl		90 – 120 mg/dl : Good Control 121– 150 mg/dl : Fair Control 151- 180 mg/dl: Unsatisfactory Control >180 mg/dl : Poor Control


25/03/2023
Consultant Radiologist

ESTD BY:-

Dr. P. K. Tiwari

MD, M.Sc (Radio Imaging)
Ph.D (Alt Nuclear Medicine)

Consultant Imagonologist & Sonologist

Dr. S. Kumar

MD (Pat)
Consultant Pathologist

Dr. Abhishek Kumar

MBBS, MD
Consultant Neuropatho Physiologist

Dr. Kumari Suman

MBBS, DGO, MD
Consultant (TVS & HSG Specialist)

Dr. A. K. Singh

MBBS, PGDMCH
Consultant Radiologist & Sonologist

OPINION SHOULD BE REPORTED BACK IMMEDIATELY/गठों जन्म से पहले भण का लिंग जाँच नहीं होता है ।



Scanned with OKEN Scanner

Shubham Imaging & ALC Diagnostic Center

ISO 9001:2015 Certified center

(A Unit of P.K. Arogyam Health & Wellness Center)

E-95, P.C. Colony, Near Sai Netralaya Transformer, Kankarbagh, Patna - 20

alcdiagnostics@gmail.com

www.pharogayamhealthcheckup.com

7056007694, 8771266196

OPINION MUST BE CORRELATES WITH CLINICALITY & OTHER INVESTIGATION FOR FINAL DIAGNOSIS. NOT FOR MEDICO LEGAL PURPOSE

PATIENT NAME : Mrs. RADHA PRAKASHI

COL DATE : 25/03/2023 REPORTING DATE: 25/03/2023 AGE SEX : 38 YRS/F

REF. BY : DR. / MEDIWHEEL.

Investigation	Result	Normal Range
Total Triiodothyronin T3	1.41 ng/ml	0.80 - 2.00 μ ng/ml
Total Thyroxin T4	9.31 ug/ml	5.10 - 14.10 ug/dl
Serum TSH	1.56 μ g/ml	0.27 - 4.20 μ g/ml

THYROID DISORDER (-): Increase: < Decrease: n Normal

1. T3(n) T4(n) TSH(n) : EUTHYROID STATE:
2. T3(>) T4(>) TSH(<): HYPERTHYROIDISM:
3. T3(<)T4(<) TSH(>): HYPOTHYROIDISM:
4. T3(n)T4(n) TSH(>) : SUB-CLINICAL HYPO-THYROIDISM:
5. T3(n)T4(n) TSH(<): SUB-CLINICAL HYPER-THYROIDISM:
6. T3(>) T4(n) TSH(<): T3 THYROTOXICOSIS:

Total T3/T4 level is dependent on Level:

So determination of free T3/T4is a better MARKER of Thyroid Function.

*FREE T3/T4 ESTIMATION FACILITY IS AVAILABALE ON REQUEST.:

Consultant Radiologist

ESTB BY:-

Dr. P. K. TIWARI
MD, M.Sc (Radio Imaging)
Ph.D (All Nuclear Medicine)
Consultant Imagiologist & Sonologist

Dr. S. Kumar
MD (Path)
Consultant Pathologist

Dr. Abhishek Kumar
MBBS, MD
Consultant Neuropatho Physiologist

Dr. Kumari Suman
MBBS, DGO, MD
Consultant (Tvs & HSG Specialist)

Dr. A. K. Singh
MBBS, PGDMMCH
Consultant Radiologist Esomologist

Shubham Imaging & ALC Diagnostic Center

ISO 9001:2015 Certified center

(A Unit of P.K. Arogyam Health & Wellness Center)

E-95, P.C. Colony, Near Sai Netryalaya Transformer, Kankarbagh, Patna - 20

alcdiagnostics@gmail.com

www.pkarogayamhealthcheckup.com

7050037694, 8271206196

OPINION MUST BE CORRELATES WITH CLINICALLY & OTHER INVESTIGATION FOR FINAL DIAGNOSIS. NOT FOR MEDICO LEGAL PURPOSE

PATIENT NAME : Mrs. RADHA PRAKASH

PATIENT ID: 3455

COL DATE : 25/03/2023 REPORTING DATE: 25/03/2023 AGE SEX:- 38 YRS/F

REF.BY : DR. / MEDIWHEEL.

TEST NAME	RESULT	Unit	REF.RANGE
ESR	14 mm/hr		<20 mm/hr
CBC			
Total W.B.C. Count	10,400 /cumm		4000 - 11,000 /cumm
R B C COUNT	4.01 Million/ CUmm		4 - 7 Million/ CUmm
Platelets count	1.92 Lakh/ cumm		1.5 - 5.0 Lakh/ cumm
Differential Count of W.B.C.			
Neutrophils	68 %		40 -70%
Lymphocytes	26 %		25 - 40%
Eosinophils	05 %		01 - 05%
Mnonocytes	01 %		00 - 08%
Basophiles	00 %		00 - 0 %
HAEMOGLOBIN	11.7 gm/dl (80.1 %)		14.6 gm/dl = 100%
PCV	37.6 %		35 - 47 %
MCV	83.4 fl		76 - 96 fl
MCH	28.7 pg		29 - 35 pg
MCHC	33.0 %		30 - 38 %


25/03/2023

Consultant Radiologist

ESTB BY:-

Dr. P. K. Tiwari
MD, M.Sc (Radio Imaging)
Ph.D (Art Nuclear Medicine)

Dr. S. Kumar
MD (Pat)
Consultant Pathologist

Dr. Abhishek Kumar
MBBS, MD
Consultant Neuropatho Physiologist

Dr. Kumari Suman
MBBS, DGO, MD
Consultant (TVS & HSG Specialist)

Dr. A. K. Singh
MBBS, PGDMCH
Consultant Radiologist & Sonologist



Scanned with OKEN Scanner

Leeds Imaging & ALC Diagnostic Centre

A Unit of Leeds Teaching Hospitals & Health Services

100, P.O. Centre, Headingley, Leeds LS6 3JN, West Yorkshire, LS6 3JN

Telephone: 0113 276 2000 Fax: 0113 276 2001 www.leedsimagingandalc.co.uk

RESULTS MUST BE CORRELATED WITH CLINICAL & OTHER INVESTIGATION FOR FINAL DIAGNOSIS. NOT FOR MEDICAL LEGAL PURPOSES

PATIENT NAME : Mrs. Sadna Meharan PATIENT ID: 3433
 COL DATE : 25/05/2023 REPORTING DATE: 25/05/2023 AGE SEX : 36 M/F
 REF BY : DR. / MEDHAMEL

ROUTINE EXAMINATION OF URINE

PHYSICAL EXAMINATION

Quantity ...	30 ml	Colour ...	Straw
Appearance...	Clear	Sediment ..	Nil
Specific gravity...	1.020		

CHEMICAL EXAMINATION

Reaction ...	6.0	Nitrite....	Not done
Sugar ...	Nil	Bile Pigment ...	Not done
Albumin ...	Nil	urobilinogen...	Not done
Excess of Phosphate...	Nil	Chole.....	Not done
Bile Salt	Not Done	Acetone...	Not done

MICROSCOPIC EXAMINATION

Erythrocytes...	Nil	Cells ...	Nil
Leucocytes ...	3-4 /HPF	Crystals...	Nil
Epth. Cell ...	A, few	Others ...	Nil

[Signature]
 Consultant Radiologist

Dr. P. S. Thapar Dr. C. Easton Dr. S. K. Singh Dr. S. K. Singh Dr. A. D. Singh
 100, P.O. Centre, Headingley, Leeds LS6 3JN, West Yorkshire, LS6 3JN
 Telephone: 0113 276 2000 Fax: 0113 276 2001 www.leedsimagingandalc.co.uk

PRINTING MACHINES SHOULD BE REPORTED BACK IMMEDIATELY if any of the paper is torn, etc. etc.

PATIENT NAME : Mrs. RADHA PRAKASH

PATIENT ID: 3455

COL DATE : 25/03/2023 REPORTING DATE: 25/03/2023 AGE SEX : 38 YRS/F

REF.BY : DR. / MEDIWHEEL.

TEST NAME	RESULT	Unit	REF.RANGE
-----------	--------	------	-----------

BLOOD GROUP : 'O'

Rh Typing : POSITIVE

Note: Do always cross – matching before blood transfusion

AKS
25/03/2023

Consultant Radiologist

ESTD BY:-

Dr. P. K. Tiwari
MD, M.Sc (Radio Imaging)
Ph.D (Ali Nuclear Medicine)
Consultant Interventional & Sonologist

Dr. S. Kumar
MD (Pat)
Consultant Pathologist

Dr. Abhishek Kumar
MBBS, MD
Consultant Neuropathologist

Dr. Kumari Suman
MBBS, DGO, MD
Consultant (TVS & HSG Specialist)

Dr. A. K. Singh
MBBS, PGDMCH
Consultant Radiologist & Sonologist



Shubham Imaging & ALC Diagnostic Center

ISO 9001:2015 Certified center

(A Unit of P.K. Arogyam Health & Wellness Center)

E-95, P.C. Colony, Near Sai Netryalaya Transformer, Kankarbagh, Patna - 20

alcdiagnostics@gmail.com

www.pkrogyamhealthcheckup.com

7050037694, 8271206196

OPINION MUST BE CORRELATES WITH CLINICALLY & OTHER INVESTIGATION FOR FINAL DIAGNOSIS. NOT FOR MEDICO LEGAL PURPOSE

PATIENT NAME : Mrs. RADHA PRAKASH

PATIENT ID: 3455

COL DATE : 25/03/2023

REPORTING DATE: 25/03/2023

AGE SEX : 38 YRS/F

REF.BY

: DR. / MEDIWHEEL.

TEST NAME

RESULT

Unit

REF.RANGE

BLOOD GROUP

: 'O'

Rh Typing

: POSITIVE

Note: Do always cross – matching before blood transfusion

ESTB BY:-

Dr. P. K. Tiwari
MD, M.Sc (Radio Imaging)
Ph.D (Alt Nuclear Medicine)
Consultant Imagonologist & Sonologist

Dr. S. Kumar
MD (Pat)
Consultant Pathologist

Dr. Abhishek Kumar
MBBS, MD
Consultant Neuropatho Physiologist

Dr. Kumari Suman
MBBS, DGO, MD
Consultant (TVS & HSG Specialist)

Dr. A. K. Singh
MBBS, PGDMCH
Consultant Radiologist & Sonologist


25/03/2023
Consultant Radiologist

PRINTING MISTAKE SHOULD BE REPORTED BACK IMMEDIATELY/ यहाँ जन्म से पहले भ्रुण का लिंग जाँच नहीं होता है ।



Scanned with OKEN Scanner