



डॉ. सावता क्लिनिक

34, भूतल, मोहिनी अदिति आर्केड, शाहपुरा मस्जिद के पास
भरत नगर रोड, ई-7/194, अरेरा कॉलोनी, भोपाल - 462038

Mob. : 8989649694, 9516333619

Clinic Registration : CL/5392/Jun/2017

PNDT Registration : MPPCPNDT/BPL/2017/206



Name : Mrs. Vaibhav. Age 33 YRS./F
R/B Health check-up. No. Date 30/7/2022.

WHOLE ABDOMES ULTRASOUND REPORT

Indication:

Liver appears normal in size and shape with normal outline. Normal/
increased perenchymal echogenicity is noted. No E/O focal lesion/ IHBR
dilatation is seen. Hepatic veins and portal veins appear normal. gs I

fatty liver.

No E/O subdiaphragmatic Collection.

Gall Blader is physiologically well distended. No. E/O echogenic foci in GB
lumen. GB wall is normal / thickened. No E/O pericholecystic collection.
Common duct reveals normal course and caliber.

Pancreas appear normal in size, shape and echo texture with smooth
contour. No peripancreatic pathology seen. (Not seen due to gases)

Spleen is normal in size and echo texture.

IVC and aorta appear to be normal.

No evidence of lymphadenopathy is noted.

No evidence of free fluid is noted.

Right Kidney is normal in size. size, shape and position. Corticomedullary
defferentiation (CMD) is well maintained. Normal cortical thickness is
noted. No E/O hydronephrosis or calculus is noted.

PTO

Dr. P. Savita, MD
MBBS, MD (O&G) Reg. No. 9971
स्त्री रोग विशेषज्ञ

Dr. Jayant Yadav, MD
MBBS, MD (Radiologist) Reg. No. 4166
रेडियोलॉजिस्ट

Left Kidney is normal in size, shape and position. CMD is well maintained. Normal cortical thickness is noted. No E/O hydronephrosis or calculus is noted.

Urinary Bladder is well distended (physiological). its contents are echo free. No E/O bladder wall thickening is noted. ~~Post-void residue is insignificant.~~

Prostate is normal in size. Shape and echo texture with smooth outline. No E/O focal lesion is noted.

Uterus is ante/ retro verted and normal in size, shape and echotexture with smooth outline. No E/O focal lesion is noted. Endometrial echo appear normal. Cervical and vaginal shadows appear normal.

Right Ovary appears enlarged / Normal in size, shape and echo texture.

Left Ovary appears enlarged / Normal in size, shape and echo texture.

Impression : ~~Normal study.~~ *Grade I fatty liver.*

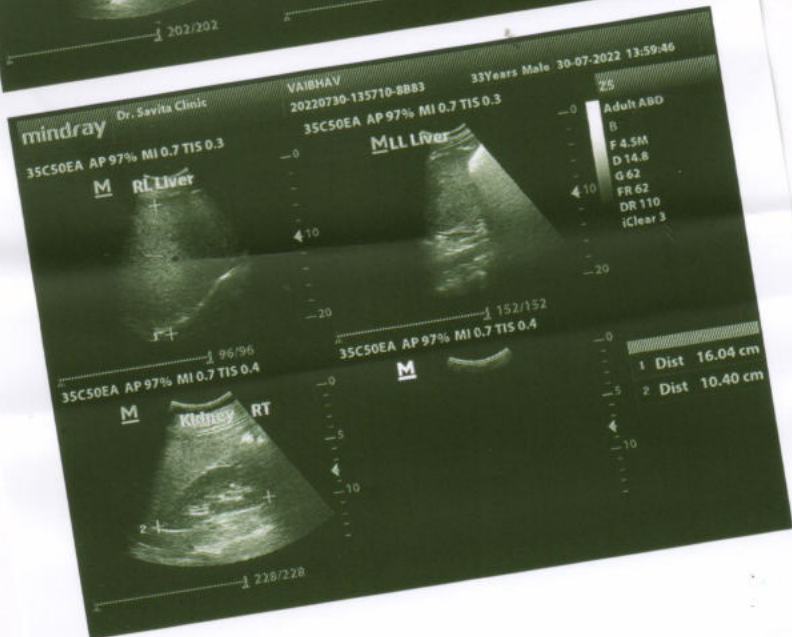
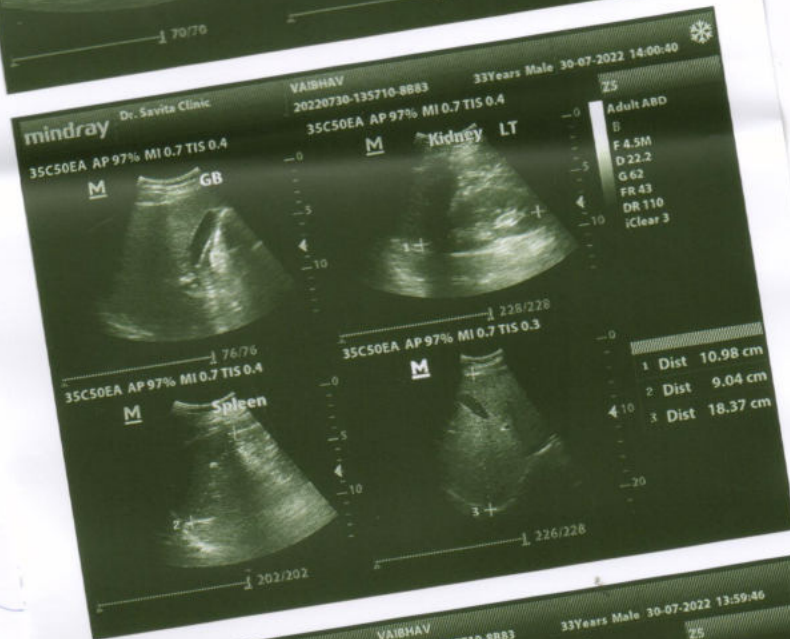
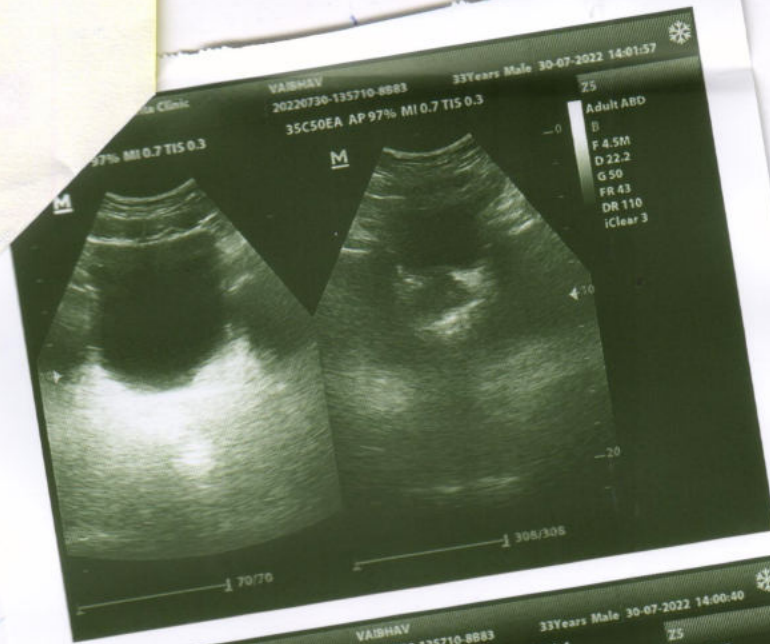
Advised clinical Correlation.



Dr. P. Savita, MD
MBBS, MD (O&G) Reg. No. 9971
स्त्री रोग विशेषज्ञ

Dr. Jayant Yadav, MD
MBBS, MD (Radiologist) Reg. No. 4166
रेडियोलॉजिस्ट

is well maintained.
osis or calculus is



INDIAN UNION DRIVING LICENCE
MADHYA PRADESH STATE

संस्कृतम् मध्यम्

Form 7

Number: MP04N-2008-0095337
Name: VAIBHAV SURANGE

S/D/W of: UDAY SURANGE
Address: LIG 32 KOTRA SULTANABAD
BHOPAL, MP

Issued on: 22-02-2008
DOB: 05-07-1988 BG: B++
is Licence to drive

Vehicle Class	MCWG	LMV-NT	
Date of Issue	22-02-2008	22-02-2008	
Valid till (Transport)			
Valid till (Non-Transport)	21-02-2028		

HOLDER'S SIGNATURE: *Vaibhav*

ISSUED BY: *Ram*

MP04N-2008

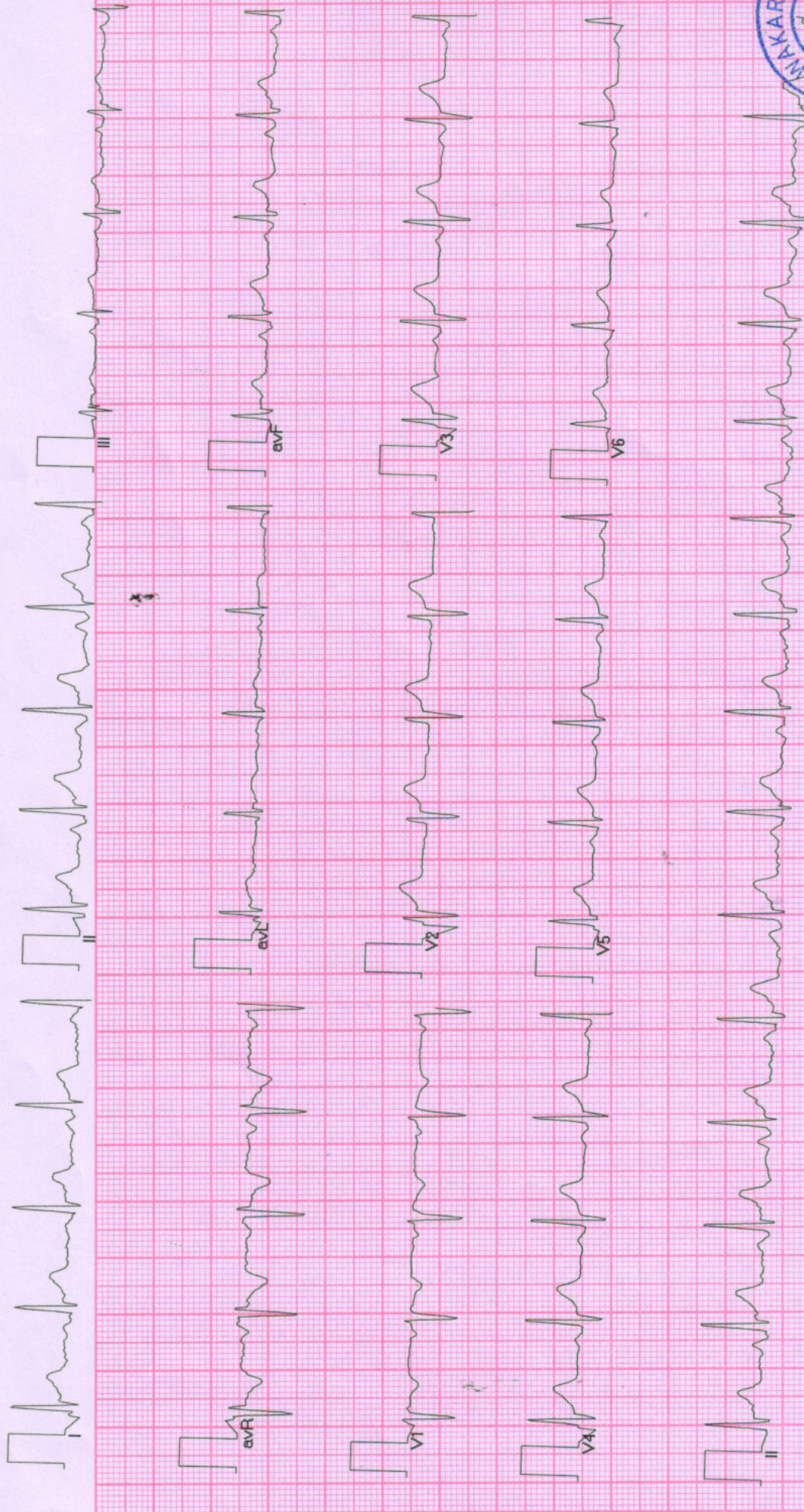
J

R
Dr. B. M. Agarwal
MBBS, DCP
Consultant Pathologist





ECG



BPL-DYNATRAC





द्विवाकर डायग्नोस्टिक सेंटर

E-7/636, पंजाब नेशनल बैंक के पास, मैन रोड, अरेरा कॉलोनी भोपाल (म.प्र.)

फोन: 0755-2465288, 0755-3520545 मो: 9826340190


Pt.Name :-	Mr.Vaibhav Surange
Age :-	33y/M
Refd. By :-	BOB
Lab.pNo.:-	289
Date :-	30/07/2022

EXAMINATION OF BLOOD

TEST	RESULT	NORMAL VALUE
Haemoglobin	14.8mgs%	Female 12-16gms%, Male 14-18gms%
Red Cell count	5.5	4.5-5.6 million /cumm
Platelet Count	3.40	1.5-5.6 Lac/cumm
Leucocytes per.cu.mm	11800/cumm	5000-11000/cumm
Neutrophils	56%	50-70%
Lymphocytes	36%	20-40%
Eosinophils	05%	0-7%
Monocytes	03%	2-8%
PCV	46.3	37-47
MCV	84.1	76-96
MCH	26.8	27-32
MCHC	31.9	31-35
ESR	06	Male 0-9, Female 0-20mm/FHR
Blood Group	"B "Positive	
S.Bilirubin(Total)	0.82	0.2-1.0mg/dl
Direct	0.30	0.0-0.25mg/dl
Indirect	0.52	
SGOT	26.2	5-35U/L
SGPT	30.8	8-40U/L
Alk Phosphatase	10.6	3-13 KA units
S. Protein(Total)	7.0	6.0-8.0mg%
Albumin	4.0	3.7-5.3mg%
Globulin	3.0	1.5 to 3.5 mg%
AG Ratio	1.23	1.-2.0
Blood Urea Nitrogen (BUN)	15.2	7-20 mg/dl
S.Creatine	0.89	0.5-1.4mg/dl
Uric Acid	6.1	4.8 to 7.5 mg/dl
Calcium	9.5	8.5-10.5 gm/dl
GGTP	33.8	5-35 UL/dl
Fasting Blood Sugar	82.6	70 to 110mg/dl
Post Prandial Blood Sugar	136.9	
Total Serum Cholesterol	178.5	100-250 mg%
Serum Triglyceride	168.3	Up to 160 mg%
Serum Cholesterol HDL	46.0	Up to 65 mg%
Serum Cholesterol LDL	98.8	Up to 125 mg%
VLDL	33.6	Up to 30 mg%
TC/HDL Ratio	3.35	Bellow 5
Glycosylated Hemoglobin HBA1c	5.5	Below - 6.0 % -Non Diabetic control 6-7 % -Excellent control Above- 8 % -Poor control

Pathologist

All test have technical limitation. Collaborative clinic pathological interpretation is mandatory. In case of disparity test may be repeated immediately. Typographical mistakes should be get correct instantly. This report is not valid for medico legal purpose.



Dr. B. M. Agarwal
MBBS, DCP
Consultant Pathologist



दिवाकर डायग्नोस्टिक सेंटर

E-7/636, पंजाब नेशनल बैंक के पास, मैन रोड, अरेरा कॉलोनी भोपाल (म.प्र.)


फोन: 0755-2465288, 0755-3520545 मो: 9826340190

Pt.Name :-	Mr.Vaibhav Surange
Age :-	33y/M
Refd. By :-	BOB
Lab.pNo.:-	289
Date :-	30/07/2022

URINE ANALYSIS

<u>A. PHYSICALEXAMINATION</u>		<u>C. MICROSCOPIEXAMINATION</u>	
1. Colour	Yellow	Pus Cells	2-4/HPF
2. Appearance	Clear	R.B.C.	Nil
3. Specific Gravity	Q.N.S.	Epithelial Cell	1-2/HPF
<u>B. CHEMICAL EXAMINATION</u>		Cast	Nil
1.Reaction	Acidic	Crystals(Cal.Oxa)	Nil
2.Albumin	Absent	Bacteria	Nil
3.Sugar	Nil	Amorphous	Nil
4.Bile Salts	Absent	T. Vaginitis	Nil

URINE COTININE	Negative	By Card method
----------------	----------	----------------



Dr. B. M. Agarwal
MBBS, DCP
Consultant Pathologist
Pathologist

All test have technical limitation. Collaborative clinic pathological interpretation is mandatory. In case of disparity test may be repeated immediately. Typographic mistakes should be get correct instantly. This report is not valid for medico legal purpose.



दिवाकर डायग्नोस्टिक सेंटर

E-7/636, पंजाब नेशनल बैंक के पास, मैन रोड, अरेरा कॉलोनी भोपाल (म.प्र.)

फोन: 0755-2465288, 0755-3520545 मो: 9826340190

Pt.Name :-	Mr.Vaibhav Surange
Age :-	33y/M
Refd. By :-	BOB
Lab.pNo.:-	289
Date :-	30/07/2022

EXAMINATION OF BLOOD

Thyroid profile


TEST	RESULT	NORMAL VALUE
T3 - TOTAL	96.5	82-213 ng/dL
T4 - TOTAL	6.89	6.09-12.23 ug/dL
THYROID STIMULATING HORMONE (TSH)	1.36	0.45-4.25 ul/mL

Interpretation:

TSH Levels will be elevated in primary hypothyroidism, TSH levels will be low in Hyperthyroidism there is decreased production of thyroid hormones by the thyroid hence the person may experience symptoms such as weight gain, constipation, cold intolerance and fatigue. Iodine deficiency and Hashimoto thyroiditis is the most common cause of hypothyroidism It makes Thyroid stimulating hormone. If TSH levels are abnormally high it could mean you have an underactive thyroid or hypothyroidism.

Dr. B. M. Agarwal
MBBS, DCP
Consultant Pathologist

All test have technical limitation. Collaborative clinic pathological interpretation is mandatory. In case of disparity test may be repeated immediately. Typographic mistakes should be get correct instantly. This report is not valid for medico legal purpose





दिवाकर डायग्नोस्टिक सेंटर

E-7/636, पंजाब नेशनल बैंक के पास, मैन रोड, अरेरा कॉलोनी भोपाल (म.प्र.)
फोन: 0755-2465288, 0755-3520545 मो: 9826340190

Pt.Name :-	Mr.Vaibhav Surange
Age :-	33y/M
Refd. By :-	BOB
Lab.pNo.:-	289
Date :-	30/07/2022
Skigram	X Ray Chest PA View
Radiologist	Dr. B.M.Agarwal MD (Radiology)

REPORT

Tricia Central

Thoracic cage normal

Both Lungs Field Clear.

Both hilers normal

Cardiac border normal

Both cp angles clear

Both domes and diaphragm normal

IMPRESSION

-NO CARDIO PULMONARY PATHOLOGY
-COORELATE WITH CLINICAL FINDINGS.



R
Dr. B. M. Agarwal
MD, Radiology
Consultant Radiologist
Radiologist



द्विवाकर डायग्नोस्टिक सेंटर

E-7/636, पंजाब नेशनल बैंक के पास, मैन रोड, अरेरा कॉलोनी भोपाल (म.प्र.)


फोन: 0755-2465288, 0755-3520545 मो: 9826340190

Pt.Name :-	Mr.Vaibhav Surange
Age :-	33y/M
Refd. By :-	BOB
Lab.pNo.:-	289
Date :-	30/07/2022

EXAMINATION OF BLOOD

<u>TEST</u>	<u>RESULT</u>	<u>NORMAL VALUE</u>
PSA	5.06 ng/ml.	0.21-6.77 ng/ml.

Dr. B. M. Aggarwal
MBBS, DCP
Consultant Pathologist
Pathologist



All test have technical limitation. Collaborative clinic pathological interpretation is mandatory. In case of disparity test may be repeated immediately. Typographic mistakes should be get correct instantly .This report is not valid for medico legal purpose

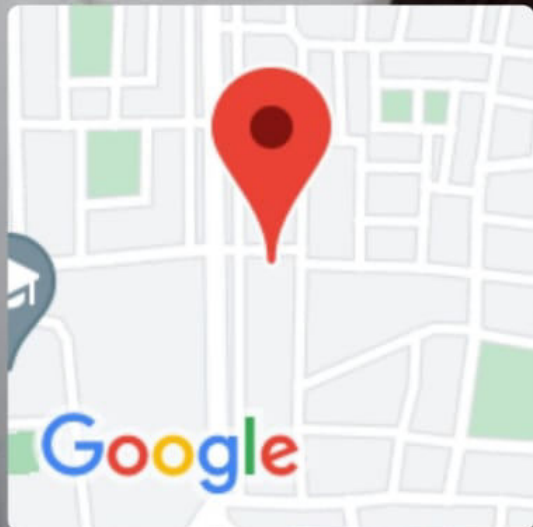


Diwaker Diagnostic Centre

पेथोलोजी | टी.सी.ए. | ई.सी.जी. | एको कार्डियो ग्राफी | सोनोग्राफी



GPS Map Camera



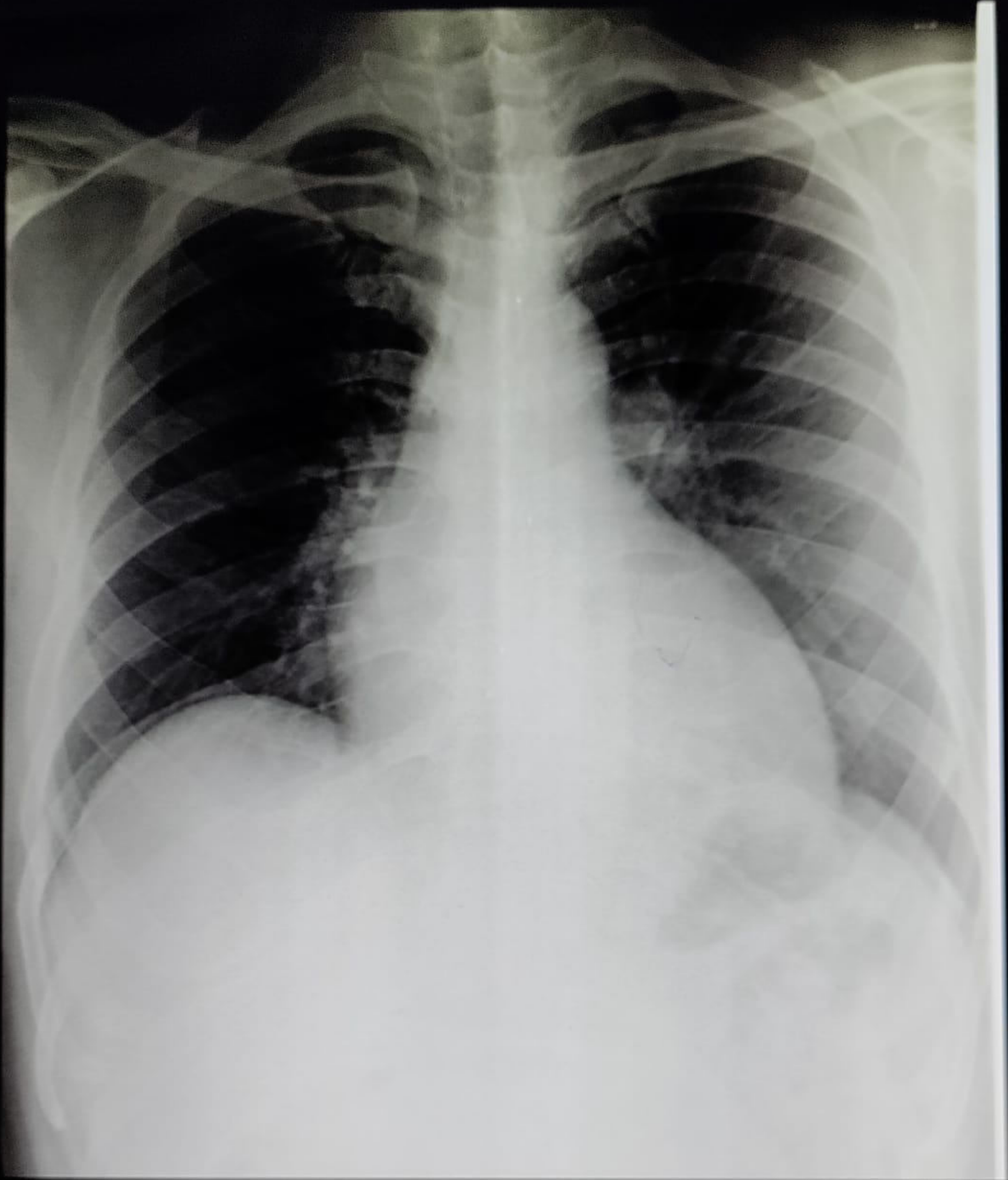
Bhopal, Madhya Pradesh, India

Dr.Vikas Kumar Malviya E-7 Arera Colony, Near Campion School Bus Stop
Infront Of Punjab National Bank Shahpura Branch, E-7, Arera Colony,
Bhopal, Madhya Pradesh 462016, India

Lat 23.205833°

Long 77.431752°

30/07/22 10:19 AM



**MR VAIBHAV SURANGE 1199 CHEST,FRN P->A 30-JULY-22
DIWAKAR DIAGNOSTIC CENTRE , ARERA COLONY ,BHOPAL**



डॉ. सावता क्लिनिक

34, भूतल, मोहिनी अदिति आर्केड, शाहपुरा मस्जिद के पास
भरत नगर रोड, ई-7/194, अरेरा कॉलोनी, भोपाल - 462038

Mob. : 8989649694, 9516333619

Clinic Registration : CL/5392/Jun/2017

PNDT Registration : MPPCPNDT/BPL/2017/206



Name : Mrs. Vaibhav. Age 33 YRS./F
R/B Health check-up. No. 30/7/2022 Date 30/7/2022

WHOLE ABDOMES ULTRASOUND REPORT

Indication:

Liver appears normal in size and shape with normal outline. Normal/
increased perenchymal echogenicity is noted. No E/O focal lesion/ IHBR
dilatation is seen. Hepatic veins and portal veins appear normal. gs I

fatty liver.

No E/O subdiaphragmatic Collection.

Gall Bladder is physiologically well distended. No. E/O echogenic foci in GB
lumen. GB wall is normal / thickened. No E/O pericholecystic collection.
Common duct reveals normal course and caliber.

Pancreas appear normal in size, shape and echo texture with smooth
contour. No peripancreatic pathology seen. (Not seen due to gases)

Spleen is normal in size and echo texture.

IVC and aorta appear to be normal.

No evidence of lymphadenopathy is noted.

No evidence of free fluid is noted.

Right Kidney is normal in size. size, shape and position. Corticomedullary
differentiation (CMD) is well maintained. Normal cortical thickness is
noted. No E/O hydronephrosis or calculus is noted.

PTO

Dr. P. Savita, MD
MBBS, MD (O&G) Reg. No. 9971
स्त्री रोग विशेषज्ञ

Dr. Jayant Yadav, MD
MBBS, MD (Radiologist) Reg. No. 4166
रेडियोलॉजिस्ट

Left Kidney is normal in size, shape and position. CMD is well maintained. Normal cortical thickness is noted. No E/O hydronephrosis or calculus is noted.

Urinary Bladder is well distended (physiological). its contents are echo free. No E/O bladder wall thickening is noted. ~~Post-void residue is insignificant.~~

Prostate is normal in size. Shape and echo texture with smooth outline. No E/O focal lesion is noted.

Uterus is ante/ retroverted and normal in size, shape and echotexture with smooth outline. No E/O focal lesion is noted. Endometrial echo appear normal. Cervical and vaginal shadows appear normal.

Right Ovary appears enlarged / Normal in size, shape and echo texture.

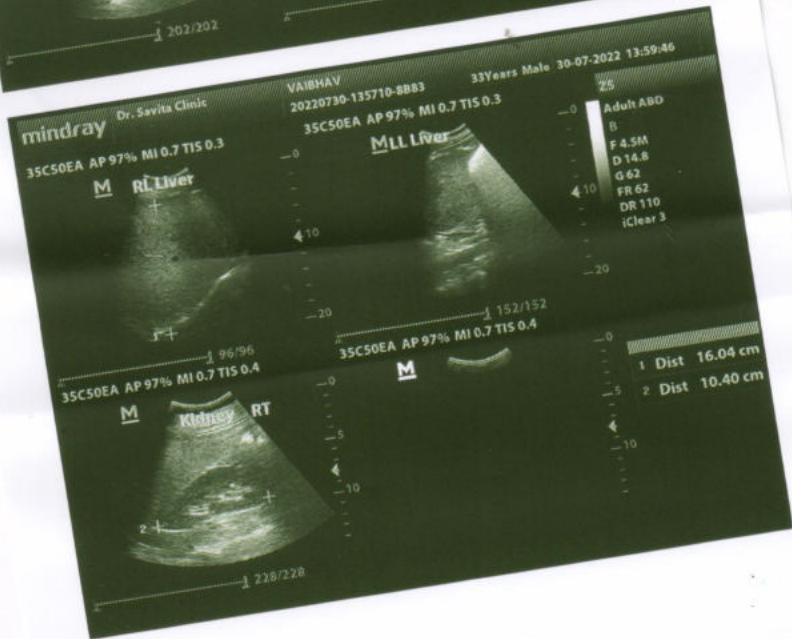
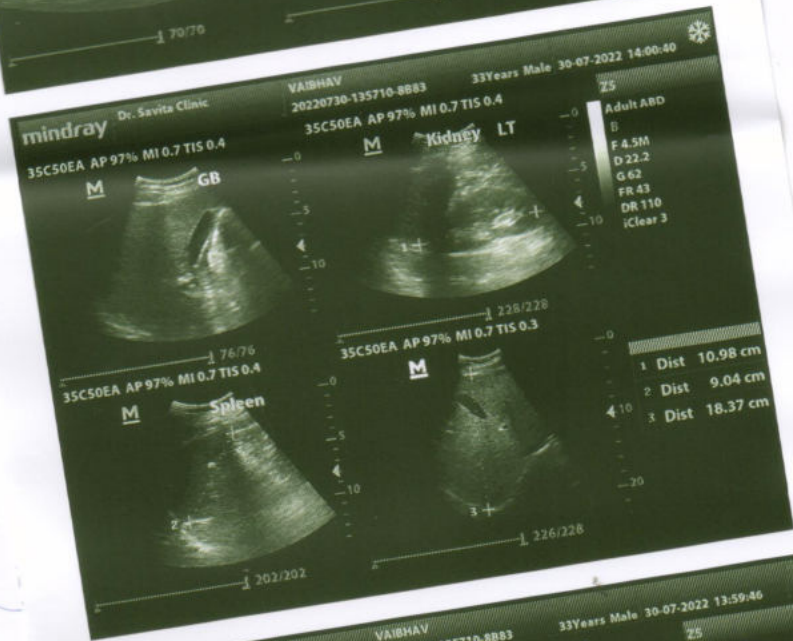
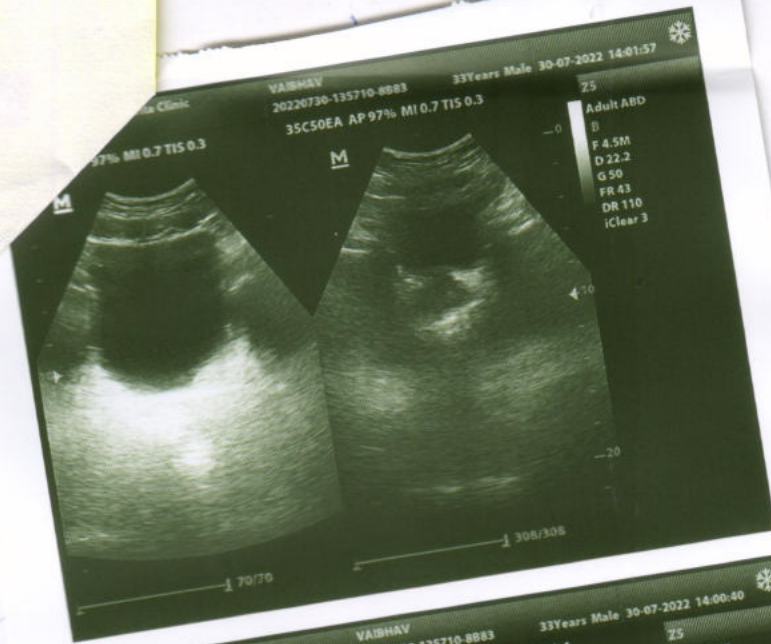
Left Ovary appears enlarged / Normal in size, shape and echo texture.

Impression : ~~Normal study.~~ *Grade I fatty liver.*

Advised clinical Correlation.



is well maintained.
osis or calculus is



INDIAN UNION DRIVING LICENCE
MADHYA PRADESH STATE

संस्कृतम् मध्य प्रदेश

Form 7

Number: MP04N-2008-0095337
Name: VAIBHAV SURANGE

S/D/W of: UDAY SURANGE
Address: LIG 32 KOTRA SULTANABAD
BHO PAL, MP

Issued on: 22-02-2008
DOB: 05-07-1988 BG: B++
is Licence to drive

Vehicle Class	MCWG	LMV-NT	
Date of Issue	22-02-2008	22-02-2008	
Valid till (Transport)			
Valid till (Non-Transport)	21-02-2028		

HOLDER'S SIGNATURE: *Vaibhav*
ISSUING OFFICER'S SIGNATURE: *Ram*

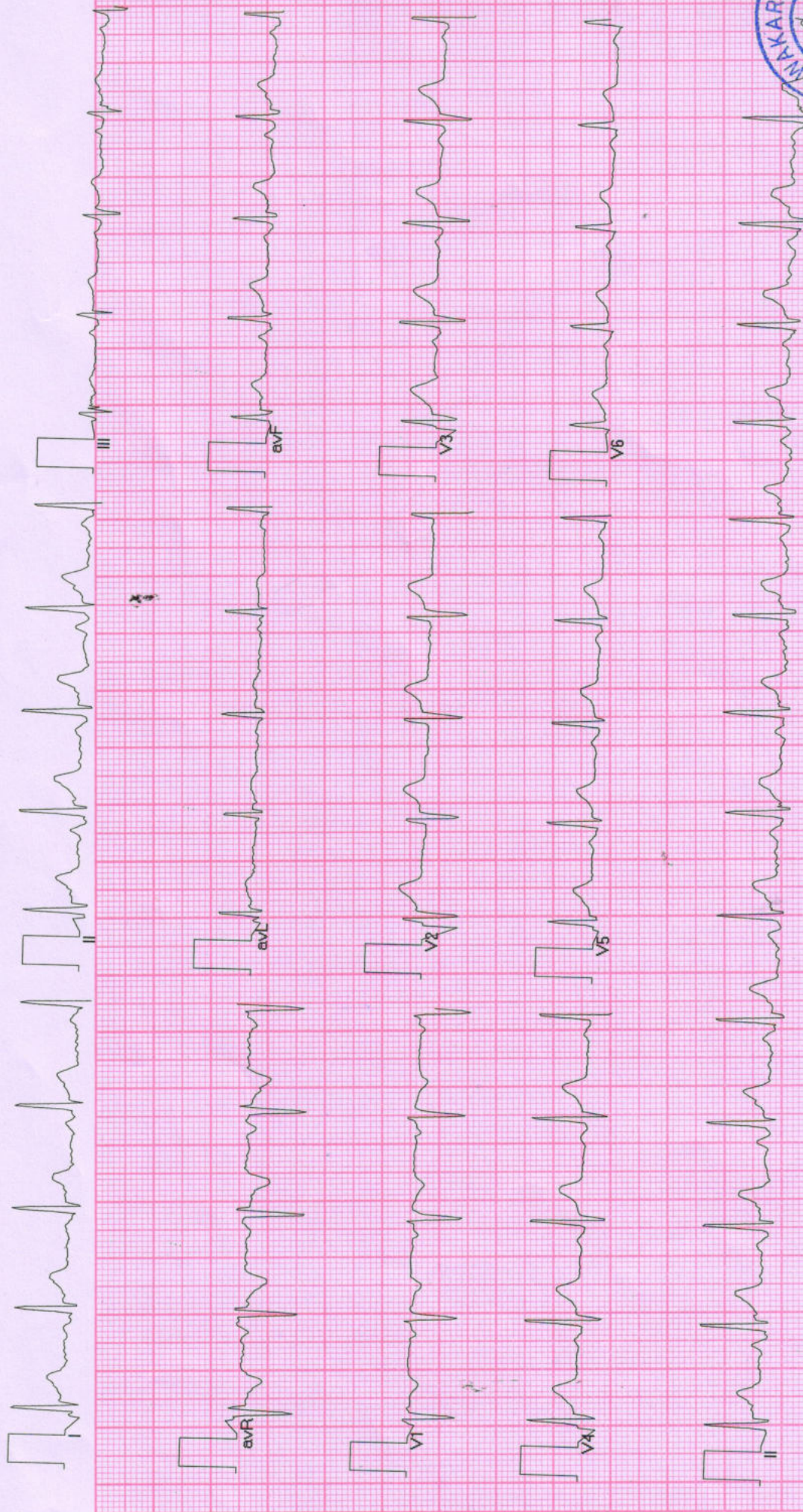
J

R
Dr. B. M. Agarwal
MBBS, DCP
Consultant Pathologist





ECG



BPL-DYNATRAC

Allengers ECG (Pisces)(PIS213180317)





द्विवाकर डायग्नोस्टिक सेंटर

E-7/636, पंजाब नेशनल बैंक के पास, मैन रोड, अरेरा कॉलोनी भोपाल (म.प्र.)

फोन: 0755-2465288, 0755-3520545 मो: 9826340190


Pt.Name :-	Mr.Vaibhav Surange
Age :-	33y/M
Refd. By :-	BOB
Lab.pNo.:-	289
Date :-	30/07/2022

EXAMINATION OF BLOOD

TEST	RESULT	NORMAL VALUE
Haemoglobin	14.8mgs%	Female 12-16gms%, Male 14-18gms%
Red Cell count	5.5	4.5-5.6 million /cumm
Platelet Count	3.40	1.5-5.6 Lac/cumm
Leucocytes per.cu.mm	11800/cumm	5000-11000/cumm
Neutrophils	56%	50-70%
Lymphocytes	36%	20-40%
Eosinophils	05%	0-7%
Monocytes	03%	2-8%
PCV	46.3	37-47
MCV	84.1	76-96
MCH	26.8	27-32
MCHC	31.9	31-35
ESR	06	Male 0-9, Female 0-20mm/FHR
Blood Group	"B" Positive	
S.Bilirubin(Total)	0.82	0.2-1.0mg/dl
Direct	0.30	0.0-0.25mg/dl
Indirect	0.52	
SGOT	26.2	5-35U/L
SGPT	30.8	8-40U/L
Alk Phosphatase	10.6	3-13 KA units
S. Protein(Total)	7.0	6.0-8.0mg%
Albumin	4.0	3.7-5.3mg%
Globulin	3.0	1.5 to 3.5 mg%
AG Ratio	1.23	1.-2.0
Blood Urea Nitrogen (BUN)	15.2	7-20 mg/dl
S.Creatine	0.89	0.5-1.4mg/dl
Uric Acid	6.1	4.8 to 7.5 mg/dl
Calcium	9.5	8.5-10.5 gm/dl
GGTP	33.8	5-35 UL/dl
Fasting Blood Sugar	82.6	70 to 110mg/dl
Post Prandial Blood Sugar	136.9	
Total Serum Cholesterol	178.5	100-250 mg%
Serum Triglyceride	168.3	Up to 160 mg%
Serum Cholesterol HDL	46.0	Up to 65 mg%
Serum Cholesterol LDL	98.8	Up to 125 mg%
VLDL	33.6	Up to 30 mg%
TC/HDL Ratio	3.35	Bellow 5
Glycosylated Hemoglobin HBA1c	5.5	Below - 6.0 % -Non Diabetic control 6-7 % -Excellent control Above- 8 % -Poor control

Pathologist

All test have technical limitation. Collaborative clinic pathological interpretation is mandatory. In case of disparity test may be repeated immediately. Typographical mistakes should be get correct instantly. This report is not valid for medico legal purpose.



Dr. B. M. Agarwal
MBBS, DCP
Consultant Pathologist



दिवाकर डायग्नोस्टिक सेंटर

E-7/636, पंजाब नेशनल बैंक के पास, मैन रोड, अरेरा कॉलोनी भोपाल (म.प्र.)


फोन: 0755-2465288, 0755-3520545 मो: 9826340190

Pt.Name :-	Mr.Vaibhav Surange
Age :-	33y/M
Refd. By :-	BOB
Lab.pNo.:-	289
Date :-	30/07/2022

URINE ANALYSIS

<u>A. PHYSICALEXAMINATION</u>		<u>C. MICROSCOPIEXAMINATION</u>	
1. Colour	Yellow	Pus Cells	2-4/HPF
2. Appearance	Clear	R.B.C.	Nil
3. Specific Gravity	Q.N.S.	Epithelial Cell	1-2/HPF
<u>B. CHEMICAL EXAMINATION</u>		Cast	Nil
1.Reaction	Acidic	Crystals(Cal.Oxa)	Nil
2.Albumin	Absent	Bacteria	Nil
3.Sugar	Nil	Amorphous	Nil
4.Bile Salts	Absent	T. Vaginitis	Nil

URINE COTININE	Negative	By Card method
----------------	----------	----------------



Dr. B. M. Agarwal
MBBS, DCP
Consultant Pathologist
Pathologist

All test have technical limitation. Collaborative clinic pathological interpretation is mandatory. In case of disparity test may be repeated immediately. Typographic mistakes should be get correct instantly. This report is not valid for medico legal purpose.



दिवाकर डायग्नोस्टिक सेंटर

E-7/636, पंजाब नेशनल बैंक के पास, मैन रोड, अरेरा कॉलोनी भोपाल (म.प्र.)

फोन: 0755-2465288, 0755-3520545 मो: 9826340190

Pt.Name :-	Mr.Vaibhav Surange
Age :-	33y/M
Refd. By :-	BOB
Lab.pNo.:-	289
Date :-	30/07/2022

EXAMINATION OF BLOOD

Thyroid profile


TEST	RESULT	NORMAL VALUE
T3 - TOTAL	96.5	82-213 ng/dL
T4 - TOTAL	6.89	6.09-12.23 ug/dL
THYROID STIMULATING HORMONE (TSH)	1.36	0.45-4.25 ul/mL

Interpretation:

TSH Levels will be elevated in primary hypothyroidism, TSH levels will be low in Hyperthyroidism there is decreased production of thyroid hormones by the thyroid hence the person may experience symptoms such as weight gain, constipation, cold intolerance and fatigue. Iodine deficiency and Hashimoto thyroiditis is the most common cause of hypothyroidism It makes Thyroid stimulating hormone. If TSH levels are abnormally high it could mean you have an underactive thyroid or hypothyroidism.

Dr. B. M. Agarwal
MBBS, DCP
Consultant Pathologist

All test have technical limitation. Collaborative clinic pathological interpretation is mandatory. In case of disparity test may be repeated immediately. Typographic mistakes should be get correct instantly. This report is not valid for medico legal purpose





दिवाकर डायग्नोस्टिक सेंटर

E-7/636, पंजाब नेशनल बैंक के पास, मैन रोड, अरेरा कॉलोनी भोपाल (म.प्र.)
फोन: 0755-2465288, 0755-3520545 मो: 9826340190

Pt.Name :-	Mr.Vaibhav Surange
Age :-	33y/M
Refd. By :-	BOB
Lab.pNo.:-	289
Date :-	30/07/2022
Skigram	X Ray Chest PA View
Radiologist	Dr. B.M.Agarwal MD (Radiology)

REPORT

Tricia Central

Thoracic cage normal

Both Lungs Field Clear.

Both hilers normal

Cardiac border normal

Both cp angles clear

Both domes and diaphragm normal

IMPRESSION

-NO CARDIO PULMONARY PATHOLOGY
-COORELATE WITH CLINICAL FINDINGS.



R
Dr. B. M. Agarwal
MD, Radiology
Consultant Radiologist
Radiologist



दिवकर डायग्नोस्टिक सेंटर

E-7/636, पंजाब नेशनल बैंक के पास, मैन रोड, अरेरा कॉलोनी भोपाल (म.प्र.)


फोन: 0755-2465288, 0755-3520545 मो: 9826340190

Pt.Name :-	Mr.Vaibhav Surange
Age :-	33y/M
Refd. By :-	BOB
Lab.pNo.:-	289
Date :-	30/07/2022

EXAMINATION OF BLOOD

<u>TEST</u>	<u>RESULT</u>	<u>NORMAL VALUE</u>
PSA	5.06 ng/ml.	0.21-6.77 ng/ml.

Dr. B. M. Aggarwal
MBBS, DCP
Consultant Pathologist
Pathologist



All test have technical limitation. Collaborative clinic pathological interpretation is mandatory. In case of disparity test may be repeated immediately. Typographic mistakes should be get correct instantly .This report is not valid for medico legal purpose

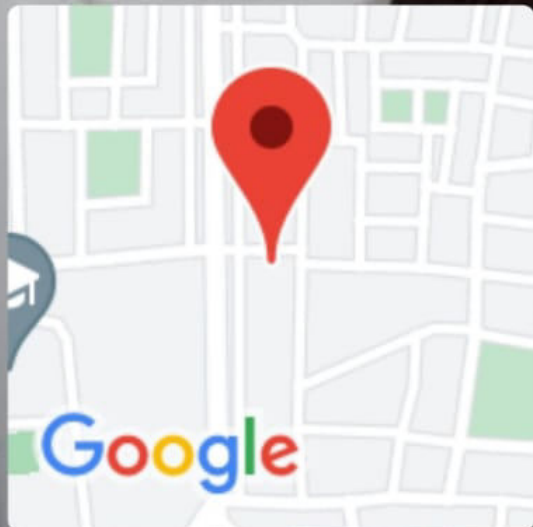


Diwaker Diagnostic Centre

पैथोलोजी | टी.सी.ए. | ई.सी.जी. | एको कार्डियो ग्राफी | सोनोग्राफी



GPS Map Camera



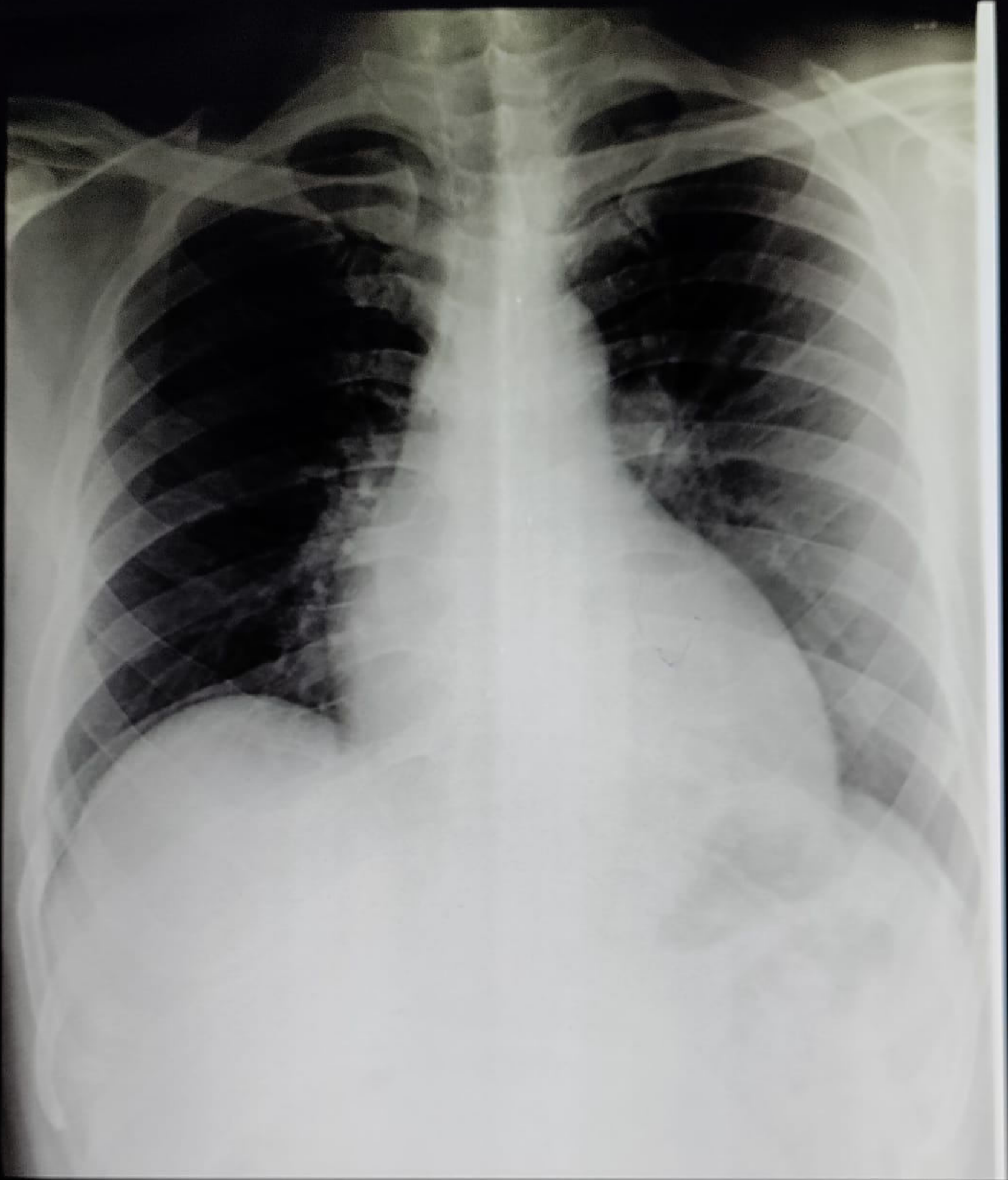
Bhopal, Madhya Pradesh, India

Dr.Vikas Kumar Malviya E-7 Arera Colony, Near Campion School Bus Stop
Infront Of Punjab National Bank Shahpura Branch, E-7, Arera Colony,
Bhopal, Madhya Pradesh 462016, India

Lat 23.205833°

Long 77.431752°

30/07/22 10:19 AM



**MR VAIBHAV SURANGE 1199 CHEST,FRN P->A 30-JULY-22
DIWAKAR DIAGNOSTIC CENTRE , ARERA COLONY ,BHOPAL**