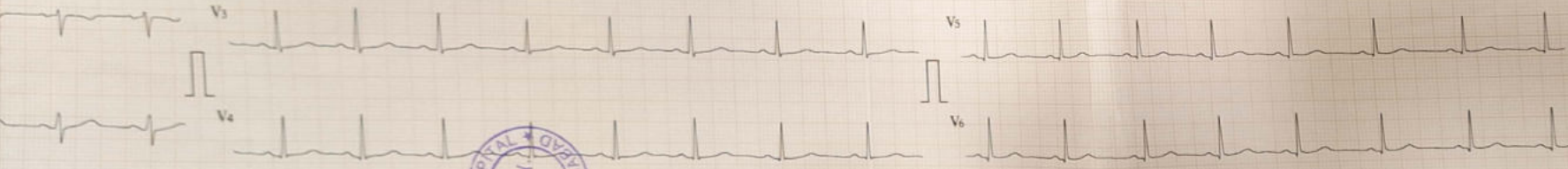


10mm/s

10mm/s

ID : 0140 HR : 79 bpm
 Name: Shivan R-R : 756 ms
 Sex : f P-R : 140 ms
 Age : QRS : 77 ms
 QT/QTc : 365/419 ms
 P/QRS/T : 46/53/26
 RV5/SV1 : 0.940/0.460 mV
 RV5+SV1 : 1.400 mV

— Sinus Rhythm
 — T Abnormality (Flat T)



Unconfirmed report Verified by: _____

E-CARDIOPRINT



ECHO REPORT

Name of the patient: Mr. SHIVANI Age: 30 Sex: Male Female

UHID No: 23996 IPD No: _____ Date: 27/02/2023

Refer By Doctor: DR R. Arora

LVEF% - 66%

2D ECHO

> Mitral Value Normal Pulmonary Value N Pulm

> Artery N

> Aortic avive N Tricuspid valve N

2D RWMA

> NO RWMA (Regional wall motion abnormality) at rest

COLD DOPPLER

> NO Significant Vavular stenosis / Regurgiation

COMMENTS AND SUMMARY

> All cardiac chambers of N size and shape NO dilatation or hypertrophy.

> NO RWMA (Regional wall motion abnormality) at rest

> NO Cloth / Vegetation/ pericardial effusion

> LV - 66% Systolic function

> NO Significant Vavular stenosis / Regurgiation

Final Impression

> EF at Rest 66%

COMMENTS

WNL
2DECO & Color Doppler study WNL

Dr. Rakesh Kumar Arora
MBBS, MD, DM (Cardiology)
Reg No. DMC - 18395
Consultant - Cardiology
Park Hospital, Faridabad

Consultant Cardiology

Doctor Name : Dr.

Date :



Signature :

Time :





DEPARTMENT OF RADIOLOGY

Patient Name	Mrs. SHIVANI	Billed Date	: 27/03/2023	10.16 AM
Reg No	23996	Reported Date	: 27/03/2023	
Age/Sex	30 Years 6 Months 28Days / Female	Req. No.	: 23005816	
Type	OPD	Consultant Doctor	: Dr. CONSULTANT	

X-RAY CHEST AP/PA

Bilateral lungs appears normal.

No focal lung lesion seen.

Both hila are normal in size, have equal density and bear normal relationship.

The heart and trachea are central in position and no mediastinal abnormality is visible.

The cardiac size is normal for patient age and view.

The domes of the diaphragms are normal in position, and show smooth outline.

To be correlated clinically



DR BINOD K. CHAUDHARY
MBBS, MD
CONSULTANT RADIOLOGIST

(This is only professional opinion and not the diagnosis, Please correlate clinically)

J-Block, Sector-10, Near Court, Faridabad - 121004, Haryana
Tel.: 0129-4200000 E-mail : parkfaridabad@gmail.com

PARK GROUP OF HOSPITALS : West Delhi • South Delhi • Gurgaon • Karnal • Panipat • Hodal • Ambala • Behror

the **health** care providers

the **health** care providers





DEPARTMENT OF RADIOLOGY

Patient Name	Mrs. SHIVANI	Billed Date	: 27/03/2023	10.16 AM
Reg No	23996	Reported Date	: 27/03/2023	
Age/Sex	30 Years 6 Months 28Days / Female	Req. No.	: 23005816	
Type	OPD	Consultant Doctor	: Dr. CONSULTANT	

USG WHOLE ABDOMEN

LIVER : The liver is normal in size, shape and echotexture. No evidence of any focal lesion. IHBR is not dilated.

GALL BLADDER : The gall bladder is well distended. No evidence any calculus or mass seen. GB wall thickness with in normal limits.No evidence of pericholecystic fluid is seen.

BILE DUCT :The common bile duct is normal in caliber. No evidence of calculus is noted in common bile duct.

SPLEEN :The spleen is normal in size and shape. Its echotexture is homogeneous.No evidence of focal lesion is noted.

PANCREAS :The pancreas is normal in size, shape, contours and echotexture.

BILATERAL KIDNEYS : The bilateral kidneys are normal in size and echotexture. Cortico-medullary differentiation is maintained. There is no evidence of obvious calculus or hydronephrosis seen.

URINARY BLADDER :The urinary bladder is well distended.Wall thickness within normal limits.No evidence of calculus is seen.No evidence of mass or diverticulum is noted.

UTERUS: The uterus is normal in size, shape and echopattern.

BILATERAL OVARIES are normal in size and echotexture. No adnexal mass lesion seen.



DR BINOD KR CHAUDHARY
MBBS, MD
CONSULTANT RADIOLOGIST

(This is only professional opinion and not the diagnosis, Please correlate clinically)

J-Block, Sector-10, Near Court, Faridabad - 121004, Haryana
Tel.: 0129-4200000 E-mail : parkfaridabad@gmail.com

PARK GROUP OF HOSPITALS : West Delhi • South Delhi • Gurgaon • Karnal • Panipat • Hodal • Ambala • Behror

the **health** care providers the **health** care providers



DEPARTMENT OF RADIOLOGY

Patient Name	Mrs. SHIVANI	Billed Date	: 27/03/2023	10.16 AM
Reg No	23996	Reported Date	: 27/03/2023	
Age/Sex	30 Years 6 Months 28Days / Female	Req. No.	: 23005816	
Type	OPD	Consultant Doctor	: Dr. CONSULTANT	

USG WHOLE ABDOMEN

No free fluid is seen in peritoneal cavity.

No evidence of obvious retroperitoneal or mesentric lymphadenopathy is seen.

IMPRESSION: USG WHOLE ABDOMEN REVEALS NO OBVIOUS ABNORMALITY.

TO BE CORRELATED CLINICALLY.


DR BINOD KB CHAUDHARY
MBBS, MD
CONSULTANT RADIOLOGIST

(This is only professional opinion and not the diagnosis, Please correlate clinically)

J-Block, Sector-10, Near Court, Faridabad - 121004, Haryana

Tel.: 0129-4200000 E-mail : parkfaridabad@gmail.com

PARK GROUP OF HOSPITALS : West Delhi • South Delhi • Gurgaon • Karnal • Panipat • Hodal • Ambala • Behror

the **health** care providers

the **health** care providers

Page No.2





DEPARTMENT OF HAEMATOLOGY

Patient Name : Mrs. SHIVANI
 MR No : 23996
 Age/Sex : 30 Years 6 Months 28 Days / Female
 Type : OPD
 TPA/Corporate : MEDIWHEEL

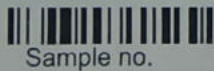Bill Date : 27/03/2023
 Reporting Date : 28/03/2023
 Sample ID : 4376
 Bill/Req. No. : 23005816
 Ref Doctor : Dr.CONSULTANT

Test	Result	Bio. Ref. Interval	Units
GLYCOSYLATED HAEMOGLOBIN			
GLYCOSYLATED HAEMOGLOBIN	5.1	0 - 6.5	%

Note : *Done on DCA Vantage
 *Results of these tests should always be interpreted in conjunction with patients medical history, clinical presentation and other findings.
 *The results of HbA1c are not influenced by recent meals , physical activity or emotional stress.

***** END OF THE REPORT *****

CUT SOURCE
PARK HOSPITAL
GGN




Sample no.

Dr. VAISHALI YADAV
PATHOLOGIST

Dr. PARDIP KUMAR
MICROBIOLOGIST & ICO

S.C.GAUR
LAB INCHARGE


USER NM SUNIL

(This is only professional opinion and not the diagnosis, Please correlate clinically)

J-Block, Sector-10, Near Court, Faridabad - 121004, Haryana
 Tel.: 0129-4200000 E-mail : parkfaridabad@gmail.com

PARK GROUP OF HOSPITALS : West Delhi • South Delhi • Gurgaon • Karnal • Panipat • Hodal • Ambala • Behror





DEPARTMENT OF IMMUNOLOGY

Patient Name : Mrs. SHIVANI

MR No : 23996

Age/Sex : 30 Years 6 Months 28 Days / Female

Type : OPD

TPA/Corporate : MEDIWHEEL

Bill Date : 27/03/2023

Reporting Date : 30/03/2023

Sample ID : 4376

Bill/Req. No. : 23005816

Ref Doctor : Dr. CONSULTANT

Test	Result	Bio. Ref. Interval	Units
THYROID PROFILE			
TRI-iodothyronine (T3)	1.32	0.60 - 1.81	ng/ml
THYROXINE (T4)	7.37	5.01 - 12.45	µg/dL
THYROID STIMULATING HORMONE	1.42	0.5-5.50	µIU/ml

***** END OF THE REPORT *****



Sample no



OUT SOURCE
PARK HOSPITAL
GGN

Dr. VAISHALI YADAV
PATHOLOGIST

Dr. PARDIP KUMAR
MICROBIOLOGIST & ICO

S.C.GAUR
LAB INCHARGE

USER NM SAMAY

(This is only professional opinion and not the diagnosis, Please correlate clinically)

J-Block, Sector-10, Near Court, Faridabad - 121004, Haryana

Tel.: 0129-4200000 E-mail : parkfaridabad@gmail.com

PARK GROUP OF HOSPITALS : West Delhi • South Delhi • Gurgaon • Karnal • Panipat • Hodal • Ambala • Behror

the health care providers

the health care providers



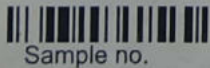

DEPARTMENT OF PATHOLOGY

Patient Name : Mrs. SHIVANI
MR No : 23996
Age/Sex : 30 Years 6 Months 28 Days / Female
Type : OPD
TPA/Corporate : MEDIWHEEL
Bill Date : 27/03/2023
Reporting Date : 27/03/2023
Sample ID : 4376
Bill/Req. No. : 23005816
Ref Doctor : Dr. CONSULTANT

Test	Result		Bio. Ref. Interval	Units
CBC				
HAEMOGLOBIN	9.9	L	12 - 15	gm/dL
PACKED CELL VOLUME	30.7	L	35.0 - 50.0	%
RED BLOOD CELL COUNT	3.45	L	3.5 - 5.5	millions/ μ L
MEAN CORPUSCULAR VOLUME	89.1		83 - 101	fL
MEAN CORPUSCULAR HAEMOGLOBIN	28.7		27 - 31	pg
MEAN CORPUSCULAR HB CONC	32.2	L	33 - 37	g/dl
RDW	13.4		11.6 - 14.5	%
TOTAL LEUCOCYTE COUNT	5440		4000-11000	/ μ L
DIFFERENTIAL COUNT				
NEUTROPHILS	60		40.0 - 80.0	%
LYMPHOCYTES	35		20 - 40	%
MONOCYTES	02		2.0 - 10.0	%
EOSINOPHILS	03		0.0 - 5.0	%
BASOPHILS	00		0.0 - 2.0	%
PLATELET COUNT	1.40	L	1.50 - 4.50	lac/cumm

***** END OF THE REPORT *****



Sample no.

Dr. VAISHALI YADAV
PATHOLOGIST

Dr. PARDIP KUMAR
MICROBIOLOGIST & ICO



S.C. GAUR
LAB INCHARGE

USER NM DEEPCHAND

(This is only professional opinion and not the diagnosis, Please correlate clinically)

J-Block, Sector-10, Near Court, Faridabad - 121004, Haryana
Tel.: 0129-4200000 E-mail : parkfaridabad@gmail.com

PARK GROUP OF HOSPITALS : West Delhi • South Delhi • Gurgaon • Karnal • Panipat • Hodal • Ambala • Behror

the health care providers

the health care providers

Page 1 of 1





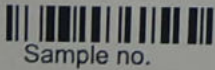DEPARTMENT OF HAEMATOLOGY

Patient Name : Mrs. SHIVANI
 MR No : 23996
 Age/Sex : 30 Years 6 Months 28 Days / Female
 Type : OPD
 TPA/Corporate : MEDIWHEEL

Bill Date : 27/03/2023
 Reporting Date : 27/03/2023
 Sample ID : 4376
 Bill/Req. No. : 23005816
 Ref Doctor : Dr.CONSULTANT

Test	Result	Bio. Ref. Interval	Units
BLOOD GROUPING AND RH FACTOR			
BLOOD GROUP	" O " RH POSITIVE		

***** END OF THE REPORT *****



Sample no.

Dr. VAISHALI YADAV
PATHOLOGIST

Dr. PARDIP KUMAR
MICROBIOLOGIST & ICO

S.C. GAUR
LAB INCHARGE

USER NM SUNIL

(This is only professional opinion and not the diagnosis, Please correlate clinically)

J-Block, Sector-10, Near Court, Faridabad - 121004, Haryana

Tel.: 0129-4200000 E-mail : parkfaridabad@gmail.com

PARK GROUP OF HOSPITALS : West Delhi • South Delhi • Gurgaon • Karnal • Panipat • Hodal • Ambala • Behror





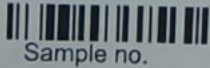DEPARTMENT OF BIOCHEMISTRY

Patient Name : Mrs. SHIVANI
MR No : 23996
Age/Sex : 30 Years 6 Months 28 Days / Female
Type : OPD
TPA/Corporate : MEDIWHEEL

Bill Date : 27/03/2023
Reporting Date : 27/03/2023
Sample ID : 4376
Bill/Req. No. : 23005816
Ref Doctor : Dr. CONSULTANT

Test	Result	Bio. Ref. Interval	Units
LIPID PROFILE			
TOTAL CHOLESTEROL	204.11	150 - 250	mg/dL
SERUM TRIGLYCERIDES	193.90 H	60 - 165	mg/dl
HDL-CHOLESTEROL	47.41	30 - 70	mg/dl
VLDL CHOLESTEROL	38.78 H	6 - 32	mg/dL
LDL	117.92	50 - 135	mg/dl
LDL CHOLESTEROL/HDL RATIO	2.49	1.0 - 3.0	mg/dL
TOTAL CHOLESTEROL/HDL RATIO	4.31	2.0 - 5.0	mg/dl

***** END OF THE REPORT *****




Sample no.

Dr. VAISHALI YADAV
PATHOLOGIST

Dr. PARDIP KUMAR
MICROBIOLOGIST & ICO



S.C. GAUR
LAB INCHARGE


USER NM SUNIL

(This is only professional opinion and not the diagnosis, Please correlate clinically)

J-Block, Sector-10, Near Court, Faridabad - 121004, Haryana

Tel.: 0129-4200000 E-mail : parkfaridabad@gmail.com

PARK GROUP OF HOSPITALS : West Delhi • South Delhi • Gurgaon • Karnal • Panipat • Hodal • Ambala • Behror

the health care providers

the health care providers





DEPARTMENT OF PATHOLOGY

Patient Name :	Mrs. SHIVANI	Bill Date :	27/03/2023
MR No :	23996	Reporting Date :	27/03/2023
Age/Sex :	30 Years 6 Months 28 Days / Female	Sample ID :	4376
Type :	OPD	Bill/Req. No. :	23005816
TPA/Corporate :	MEDIWHEEL	Ref Doctor :	Dr.CONSULTANT

Test	Result	Bio. Ref. Interval	Units
BLOOD SUGAR FASTING			
PLASMA GLUCOSE FASTING	90.70	60 - 110	mg/dl

***** END OF THE REPORT *****




Sample no.



Dr. VAISHALI YADAV
PATHOLOGIST

Dr. PARDIP KUMAR
MICROBIOLOGIST & ICO

S.C.GAUR
LAB INCHARGE


USER NM **SUNIL**

(This is only professional opinion and not the diagnosis, Please correlate clinically)

J-Block, Sector-10, Near Court, Faridabad - 121004, Haryana
Tel.: 0129-4200000 E-mail : parkfaridabad@gmail.com

PARK GROUP OF HOSPITALS : West Delhi • South Delhi • Gurgaon • Karnal • Panipat • Hodal • Ambala • Behror

the **health** care providers

the **health** care providers



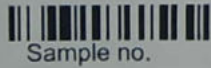

DEPARTMENT OF PATHOLOGY

Patient Name : Mrs. SHIVANI
MR No : 23996
Age/Sex : 30 Years 6 Months 28 Days / Female
Type : OPD
TPA/Corporate : MEDIWHEEL
Bill Date : 27/03/2023
Reporting Date : 27/03/2023
Sample ID : 4376
Bill/Req. No. : 23005816
Ref Doctor : Dr. CONSULTANT

Test	Result	Bio. Ref. Interval	Units
KFT (RENAL PROFILE)			
KFT			
SERUM UREA	20.03	10 - 45	mg/dL
SERUM CREATININE	0.87	0.4 - 1.4	mg/dL
SERUM URIC ACID	3.79	2.5 - 7.0	mg/dL
SERUM SODIUM	138	136 - 148	mmol/L
SERUM POTASSIUM	3.9	3.5 - 5.5	mmol/L
CHLORIDE	100	96 - 106	mmol/L

***** END OF THE REPORT *****



Dr. VAISHALI YADAV
PATHOLOGIST

Dr. PARDIP KUMAR
MICROBIOLOGIST & ICO

PARK HOSPITAL
S.C. GAUR
LAB INCHARGE

(Signature)
USER NM SUNIL

(This is only professional opinion and not the diagnosis, Please correlate clinically)

J-Block, Sector-10, Near Court, Faridabad - 121004, Haryana
Tel.: 0129-4200000 E-mail : parkfaridabad@gmail.com

PARK GROUP OF HOSPITALS : West Delhi • South Delhi • Gurgaon • Karnal • Panipat • Hodal • Ambala • Behror





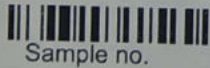DEPARTMENT OF PATHOLOGY

Patient Name : Mrs. SHIVANI
MR No : 23996
Age/Sex : 30 Years 6 Months 28 Days / Female
Type : OPD
TPA/Corporate : MEDIWHEEL

Bill Date : 27/03/2023
Reporting Date : 27/03/2023
Sample ID : 4376
Bill/Req. No. : 23005816
Ref Doctor : Dr. CONSULTANT

Test	Result	Bio. Ref. Interval	Units
LFT (LIVER FUNCTION TEST)			
LFT			
TOTAL BILIRUBIN	0.4	0 - 1.2	mg/dL
DIRECT BILIRUBIN	0.2	0 - 0.4	mg/dL
INDIRECT BILIRUBIN	0.2	0.10 - 0.6	mg/dL
SGOT (AST)	28.2	0 - 45	U/L
SGPT (ALT)	17.2	0 - 45	U/L
ALKALINE PHOSPHATASE	70.99	30 - 170	IU/L
TOTAL PROTEIN	6.6	6.4 - 8.0	g/dL
ALBUMIN	3.7	3.3 - 5.5	g/dL
GLOBULIN	2.9	2.3 - 4.5	g/dL
A/G RATIO	1.28	1.1 - 2.2	

***** END OF THE REPORT *****



Dr. VAISHALI YADAV
PATHOLOGIST

Dr. PARDIP KUMAR
MICROBIOLOGIST & ICO



[Signature]
USER NM SUNIL

(This is only professional opinion and not the diagnosis, Please correlate clinically)

J-Block, Sector-10, Near Court, Faridabad - 121004, Haryana
Tel.: 0129-4200000 E-mail : parkfaridabad@gmail.com

PARK GROUP OF HOSPITALS : West Delhi • South Delhi • Gurgaon • Karnal • Panipat • Hodal • Ambala • Behror



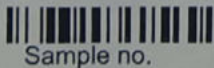DEPARTMENT OF PATHOLOGY

Patient Name : Mrs. SHIVANI
MR No : 23996
Age/Sex : 30 Years 6 Months 28 Days / Female
Type : OPD
TPA/Corporate : MEDIWHEEL

Bill Date : 27/03/2023
Reporting Date : 27/03/2023
Sample ID : 4376
Bill/Req. No. : 23005816
Ref Doctor : Dr.CONSULTANT

Test	Result	Bio. Ref. Interval	Units
URINE ROUTINE AND MICROSCOPY			
PHYSICAL CHARACTERSTICS			
QUANTITY	30ml	5 - 100	ml
COLOUR	Pale Yellow		
TURBIDITY	Clear	clear	
SPECIFIC GRAVITY	1.010	1.000-1.030	
PH	Acidic	Acidic/Alkaline	
CHEMICAL EXAMINATION-1			
URINE PROTEIN	NIL	NIL	mg/dl
GLUCOSE	NIL	NIL	
MICRO.EXAMINATION			
PUS CELL	1-2 /hpf	0-5	/HPF
RED BLOOD CELLS	Nil	0-2	cells/hpf
EPITHELIAL CELLS	2-4/HPF	0-5	cells/hpf
CASTS	NIL	NIL	/HPF
CRYSTALS	NIL	NIL	/hpf
OTHER	NIL		

***** END OF THE REPORT *****



Dr. VAISHALI YADAV
PATHOLOGIST

Dr. PARDIP KUMAR
MICROBIOLOGIST & ICO

S.C.GAUR
LAB INCHARGE

USER NM SUNIL

(This is only professional opinion and not the diagnosis, Please correlate clinically)

J-Block, Sector-10, Near Court, Faridabad - 121004, Haryana
 Tel.: 0129-4200000 E-mail : parkfaridabad@gmail.com

PARK GROUP OF HOSPITALS : West Delhi • South Delhi • Gurgaon • Karnal • Panipat • Hodal • Ambala • Behror

