

**DAKSH HOSPITAL**

396 - 397, Gandhi Nagar, Scheme No. 8, ALWAR -301001

Ref. No.

Date.....

MEDICAL EXAMINATION REPORT

Mediwheel (BOB)

Name: Mrs Rajni Garg

Age: 36 yrs Sex:Female

Date: 14/04/2023

General Physical Examination

Height	: 158 cm.	Weight	: 71 kg
Pulse	: 76/mt	BP	: 110/85 mm/hg
Temp.	: 97	Respiration	: 98 %
BMI	: 28.4		

Systemic Exam:- NORMALDental Check up :- NORMALEve check-up :- NORMALSkin Check up:- NORMALENT Check up:- NORMALGynae Check up:- NAImpression:- NORMALRecommendation:- ND

डॉ० मुकेश गुप्ता

Dr. Mukesh Kumar Gupta  
MD Gen. Medicine  
Reg. No. 5123/16262  
राज्य नं० 5A23/16262

## Results

Run Date 14/04/2023 10:22:58 AM

Operator DAKSH

Last Name

Sample ID 4

First Name MRS RAJNI

Department

Gender Female

Age

Physician DR. MUKESH GUPTA M.D

Patient ID AUTO\_PID13051

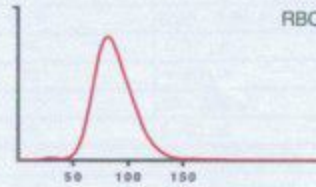
Type Woman

Date of birth

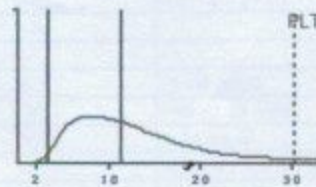
Sample comments

Susp. Pathologies  
Anisocytosis

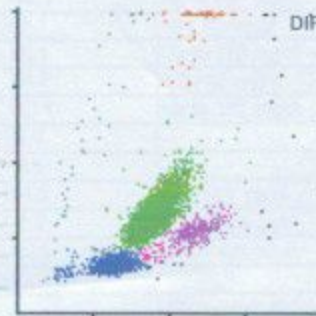
				Range
RBC	3.82	*	10 <sup>6</sup> /μL	3.80 - 5.50
HGB	10.3		g/dL	11.5 - 15.2
HCT	35.4	*	%	35.0 - 46.0
MCV	92.5	*	μm <sup>3</sup>	77.0 - 97.0
MCH	27.0		pg	26.0 - 34.0
MCHC	29.2	L	g/dL	32.0 - 35.0
RDW-CV	19.9	H	%	11.0 - 17.0
RDW-SD	67.7	H	μm <sup>3</sup>	37.0 - 49.0



				Range
PLT	242		10 <sup>3</sup> /μL	150 - 450
PCT	0.29		%	0.15 - 0.40
MPV	11.9	h	μm <sup>3</sup>	8.0 - 11.0
PDW	22.1	h	μm <sup>3</sup>	11.0 - 22.0
P-LCC	114		10 <sup>3</sup> /μL	44 - 140
P-LCR	47.2		%	18.0 - 50.0



				Range
WBC	6.52		10 <sup>3</sup> /μL	3.50 - 10.00
	#			
NEU	4.48		1.60 - 7.00	69.1
LYM	1.72		1.00 - 3.00	26.5
MON	0.13		0.20 - 0.80	2.0
EOS	0.09		0.00 - 0.50	1.4
BAS	0.07		0.00 - 0.15	1.0
LIC	0.03		0.00 - 0.10	0.5



डॉ० मुकेश गुप्ता  
M.D. F.C.C.S.  
महामरोग विशेषज्ञ  
दक्ष हॉस्पिटल, अलवर  
☎ 0144-2703340

14/04/2023 10:22:58 AM

Printed by : DAKSH

S/N 107YOXH04

TECHNOLOGIST

All investigations have their own limitations regarding the sensitivity & specificity of individual assay procedures, isolated laboratory investigations never confirm the final diagnosis of the disease. They only help in arriving at a diagnosis in conjunction with clinical presentation and other related investigations. Report is not valid for medico-legal purpose subject to ALWAR jurisdiction only.

Date :-14/04/2023

Name :- MRS. RAJNI GARG

Age & Sex :- 37Yrs female

Refd. :- Dr Mukesh Gupta M.D.

	TEST NAME	RESULT	REFERENCE RANGE
	ESR	12	00 -20 mm/hrs
	Blood Group & Rh Factor	A * POSITIVE	
	HbA1C	4.8	4 - 5.6%
	Blood Sugar (F)	78.1	< 70 - 100 mg/dl
	Blood Sugar (PP)	109	< 140 mg/dl
	Urine Sugar (F)	NIL	-
	Urine Sugar (PP)	NIL	-
<b>LIVER</b>	S.Bilirubin Total	1.00	0.30 - 1.20 mg/dl
	S.Bilirubin Direct	0.30	0.10 - 0.30 mg/dl
	S.Bilirubin Indirect	0.70	0.30 - 0.90 mg/dl
	S.G.O.T.	14	> 37 u/l
	S.G.P.T.	20	> 40 u/l
	S. Alk. Phosp.	176	80 - 306 u/l
	G.G.T.	18	5 -40 u/l
	Total Protein	6.7	6.5 - 8.5 gm/dl
	Albumin	3.7	3.8 - 5.4 gm/dl
	Globulin	3.0	2.3 - 3.5 gm/dl
	A/G Ratio	1.2	-
AST/ALT Ratio	0.7	-	
<b>KIDNEY</b>	Blood Urea	26.3	15 -45 mg/dl
	S.Creatinine	0.89	0.60 - 1.30 mg/dl
	BUN	17.0	6 -24 mg/dl
	S.Uric Acid -	5.2	M 3.1 - 7.0, F 2.5 - 5.6 mg/dl
	BUN/Creatinine Ratio	19.1	-
<b>LIPID PROFILE</b>	Total Cholesterol	145.1	Up to 200 mg/dl
	S.HDL	41.1	30 - 70 mg/dl
	S.LDL	80.1	Up to 170 mg/dl
	S.VLDL	24.1	5.0 - 40 mg/dl
	S. Triglycerides	120.1	Up to 170 mg/dl
	LDL/HDL Ratio	2.0	-
	Total Cholesterol/ HDL Ratio	3.5	-
<b>THYROID</b>	T3	94.2	40 - 181 ng/dL
	T4	7.5	4.6 - 10.5 µg/dL
	TSH	4.23	0.30 - 5.0 mIU/L

**URINE EXAMINATION**

*Microscopic Examination :*

<b>General/Chemical Examination:</b>	Colour	Pale Yellow	RBC	Absent
	Reaction	Acidic	WBC	1 - 2
	Specific Gravity	QNS	Epithelial Cells	0- 1
	Appearance	Clear	Cast	Absent
	Albumin	Nil	Crystal	Absent
	Sugar	Nil	Spermatozoa	Absent
			Amorphous Sediments	Absent
			Other	Absent

**X-RAY CHEST**

NORMAL STUDY

**STOOL EXAMINATION**

*Microscopic Examination :*

<b>General/ Chemical Examination:</b>	Colour	-	RBC	-
	Consistency	-	WBC	-
	Reducing Substances	-	Ova & Parasites	-
		-		

डॉ० मुकेश गुप्ता  
M.D. F.C.C.  
फिजिशियन एवं मधुमेह रोग विशेषज्ञ  
दक्ष हॉस्पिटल, अलवर  
फोन नं. 542316262

TECHNOLOGIST

All investigations have their own limitations regarding the sensitivity & specificity of individual assay procedures, Isolated laboratory investigations never confirm the final diagnosis of the disease. They only help in arriving at a diagnosis in conjunction with clinical presentation and other related investigations. Report is not valid for medico-legal purpose subject to ALWAR jurisdiction only.

**DAKSH HOSPITAL**

396 - 397, Gandhi Nagar, Scheme No. 8, ALWAR -301001

**Ref. No.**

Date :- 14/04/2023

**Date.....**

Name :- Mrs Rajni Garg

Age &amp; Sex :- 37Yrs/ Female

Refd. :- Dr Mukesh Gupta MD

**CYTO-PATHOLOGY****PAP SMEAR**

1. Specimen type	Received two conventional smears.
2. Specimen adequacy	Smears are satisfactory for evaluation.
3. Microscopic finding	Smears are moderately cellular comprises of predominantly intermediate with mature superficial squamous epithelial cells arranged in clusters & scattered singly.
4. Inflammation	Not seen
5. Bacilli	Not seen
6. Endocervical cells	Not seen
7. Koilocytic changes	Not seen
8. Trichomonas	Not seen
9. Dysplasia	Nil
10. Neoplasia	Nil
11. Endometrial cells	Nil

**Impression:-** Negative for intraepithelial lesion or malignancy

  
 डॉ० मुकेश गुप्ता  
 M.D. F.C.C.S.  
 फिजिशियन एवं मधुमेह रोग विशेषज्ञ  
 दक्ष हॉस्पिटल, अलवर  
 फ़ोन :- ९१२३/१६२६२



# दक्ष हॉस्पिटल

396, गाँधी नगर स्कीम नं.8, अलवर (राज०) ☎ 0144-2703340

## Sonography / 2D Echo Cardiography / Doppler Report

NAME :- MRS RAJNI/F/35 YRS  
Refd. By - Dr. MONIKA GUPTA MS

14-Apr-23

### U.S.G. OF ABDOMEN & PELVIS

#### LIVER

Liver is normal in size shape with normal echo-texture. Intra hepatic biliary radicals are not dilated. No evidence of focal or diffuse lesion.

#### GALL BLADDER

Gall bladder is normal.

#### PANCREAS

Pancreas is normal in size, shape & echo-texture. No evidence of focal or diffuse lesion. MPD not dilated.

#### SPLEEN

Normal in size with normal shape & echo-texture. Spleen vein is normal. No evidence of focal or diffuse lesion.

#### KIDNEY

Both kidneys are normal.

#### URINARY BLADDER

UB is normally **distended**, lumen appear clear.

#### UTERUS:

Uterus is normal in size (9.4x3.7x4.2cm) with homogenous echo-texture. Endometrial 7-mm in thickness & echo genicity

#### OVARIES:

Both ovaries appear normal, **lies very close to the uterus.**

Advice- follow up/ hormonal study review at higher center for confirmation

Please correlate clinically. USG accuracy is 95 % due to technical limitations as well as inaccuracies inherent in the laboratory and statistical analysis biological process.  
This report is not valid for medico-legal cases

DR. MUKESH GUPTA

Dr. Mukesh Kumar Gupta

Physician & Sonologist

RM 5423/16262



"भ्रूण लिंग परीक्षण की शिकायत  
104 टोल फ्री सेवा पर भी की  
जा सकती है"

भ्रूण लिंग परीक्षण की शिकायत 104 टोल फ्री सेवा पर भी की जा सकती है।



# दक्ष हॉस्पिटल

396, गाँधी नगर स्कीम नं.8, अलवर (राज०) ☎ 0144-2703340

## Sonography / 2D Echo Cardiography / Doppler Report

### 2D/ ECHO REPORT

Name: - Mrs Rajni

Age: - 37 Yrs

Date: - 14-Apr-23

Reg. No.: - Alw/2009/04  
BOB health checkup

PROCEDURES:

M-MODE/2D/DOPPLER/COLOR/CONTRAST B.A.S. M<sup>2</sup>

MEASUREMENT:		DOPPLER:	
AOD	22	NORMAL	NORMAL (cm/sec.)
LA	23	(20- 37mm)	MV 0.54 (0.8- 1.3) MR No
AVO	14	(19- 40mm)	AV 1.3 (1.2- 1.8) AR No
RVDd.	9	(12- 25mm)	TV 0.6 (0.3- 0.8) TR No
		(03- 09mm)	PV 0.8 (0.7- 1.1) PR No
LVDd	47	(37- 56mm)	MITRAL VALVE-
LVDs	28	(22- 40mm)	AML Normal
IVS d	6	(06- 12mm)	PML Normal
IVS s	8		
PWd	2.6	(05- 10mm)	AORTIC VALVE Normal
LV FUNCTION		TV & PV are normal.	
M- E- S Separation		<0.9cm	
Minor		24.42%	
LV Ejection Fraction	70%	65 +/- 12%	

LV WALL MOTION: NO RWMA  
ALL CARDIAC CHAMBERS ARE NORMAL  
ALL VALVES ARE NORMAL  
NO CLOT, VEGETATION, PERICARDIAL EFFUSION

FINAL DIAGNOSIS: NORMAL STUDY

Adv: - Follow up/ review at higher center for confirmation

Note:- Please Correlate clinically. Due to technical limitations as well as inaccuracies inherent in the laboratory and statistical analysis of biological process. Diagnostic accuracy of ECHO is up to 95% only.  
Report is not valid for medico-legal purpose.

  
DR. MUKESH GUPTA  
Dr. Mukesh Gupta  
Physician & Sonologist  
RM 5423/16262



"भ्रूण लिंग परीक्षण की शिकायत  
104 टोल फ्री सेवा पर भी की  
जा सकती है।"  
भ्रूण लिंग परीक्षण की शिकायत 104 टोल फ्री सेवा पर भी की जा सकती है।

ID: 604

14-04-2023 12:08:01

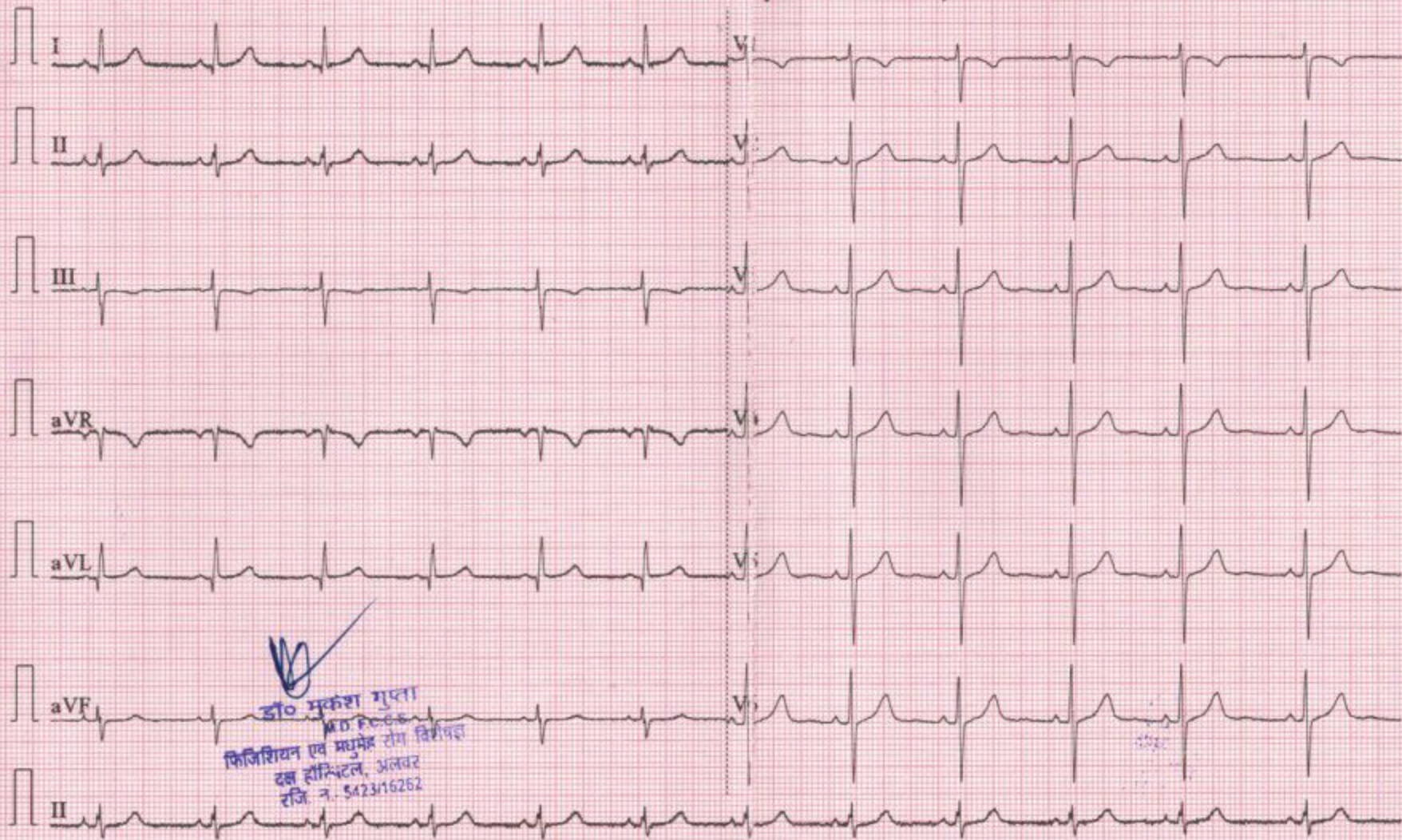
Female Years  
Req. No. :

HR : 73 bpm  
P : 74 ms  
PR : 122 ms  
QRS : 78 ms  
QT/QTcBz : 382/421 ms  
P/QRS/T : 25/-12/18 °  
RV5/SV1 : 0.914/0.736 mV

Diagnosis Information:

Sinus rhythm  
Normal ECG

Report Confirmed by:



PAT00421001 MRS RAJNI REFD BY DR MUKESH GUPTA MD CHEST 14.04.2023  
1745

R

