

To,

The Coordinator,
Mediwheel (Arcofemi Healthcare Limited)
Helpline number: 011- 41195959

Dear Sir / Madam,

Sub: Annual Health Checkup for the employees of Bank of Baroda

This is to inform you that the following spouse of our employee wishes to avail the facility of Cashless Annual Health Checkup provided by you in terms of our agreement.

PARTICULARS OF HEALTH CHECK UP BENEFICIARY	
NAME	Manjula KamleshkumarValand
DATE OF BIRTH	31-05-1975
PROPOSED DATE OF HEALTH CHECKUP FOR EMPLOYEE SPOUSE	13-08-2022
BOOKING REFERENCE NO.	22S161162100023384S
SPOUSE DETAILS	
EMPLOYEE NAME	MR. VALAND KAMLESH KUMAR
EMPLOYEE EC NO.	161162
EMPLOYEE DESIGNATION	SINGLE WINDOW OPERATOR B
EMPLOYEE PLACE OF WORK	DABHOI_DB
EMPLOYEE BIRTHDATE	04-06-1970

This letter of approval / recommendation is valid if submitted along with copy of the Bank of Baroda employee id card. This approval is valid from **11-08-2022** till **31-03-2023**. The list of medical tests to be conducted is provided in the annexure to this letter. Please note that the said health checkup is a **cashless facility** as per our tie up arrangement. We request you to attend to the health checkup requirement of our employee's spouse and accord your top priority and best resources in this regard. The EC Number and the booking reference number as given in the above table shall be mentioned in the invoice, invariably.

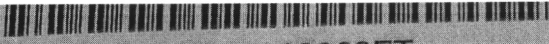
We solicit your co-operation in this regard.

Yours faithfully,


Sd/-

Chief General Manager
HRM Department
Bank of Baroda

(Note: This is a computer generated letter. No Signature required. For any clarification, please contact Mediwheel (Arcofemi Healthcare Limited))



SH625100363FT



તમારો આધાર નંબર / Your Aadhaar No. :

2170 8254 7158

આધાર - સામાન્ય માણસનો અધિકાર



ભારત સરકાર

Government of India



વાળંદ મંજુલાબેન કમલેશકુમાર
Valand Manjulaben Kamleshkumar

જન્મ તારીખ / DOB : 01/05/1975

સ્ત્રી / Female



2170 8254 7158

આધાર - સામાન્ય માણસનો અધિકાર



Patient ID : 20220803666
Age/Sex : 48y / M
Patient Name : MANJULA KAMLESHKUMAR VALAND
Dr. Name : DR HIREN PATEL
Referred By : self
SAC : 9993 "Service covered under healthcare services"
Class : Contract
PAN Card : AAQCS5566G

Visit No. : OPD20220810225(OPD)
Bill No. : OPD20220810225
Bill Date : N/A
Speciality : Intensivist
Company Name : Mediwheel Health Check Up
GSTIN : 24AAQCS5566G2ZW
City/Village : Vadodara

Expense Details	Qty	Rate	Gross Amount	Waive	Net Amount
Visit Charge					
13-Aug-2022 Physician First Consultation OPD	1.0	0.00	0.0	0.0	0.00
Ophthalmologist First Consultation OPD	1.0	0.00	0.0	0.0	0.00
Dentist First Consultation OPD	1.0	0.00	0.0	0.0	0.00
Ob & Gy Surgeon First Consultation OPD	1.0	0.00	0.0	0.0	0.00
Visit Charge (Subtotal)			0.0	0.0	0.00
PATHOLOGY					
13-Aug-2022 CBC, ESR	1.0			0.0	
Urine R/M	1.0			0.0	
STOOL EXAMINATION	1.0			0.0	
Blood Group	1.0			0.0	
HBA1C	1.0			0.0	
FBS & PPBS	1.0			0.0	
TFT (Thyroid Function Test)	1.0			0.0	
Lipid Profile	1.0			0.0	
RENAL FUNCTION TEST	1.0			0.0	
LFT (Liver Function Test)	1.0			0.0	
MediWheel Full Body Health Check-Up(Female Above 40)	1.0	3000.00	3000.0	0.0	3000.00
PATHOLOGY (Subtotal)			3000.0	0.0	3000.00
Radiology					
13-Aug-2022 X-RAY CHEST PA	1.0			0.0	
USG WHOLE ABDOMEN SCREENING	1.0			0.0	
Memography	1.0	0.00	0.0	0.0	0.00
X-RAY CHEST PA	1.0	0.00	0.0	0.0	0.00
USG WHOLE ABDOMEN SCREENING	1.0	0.00	0.0	0.0	0.00
Radiology (Subtotal)			0.0	0.0	0.00
Non Invasive Cardiology					
13-Aug-2022 ECHO COLOUR DOPPLER SCREENING	1.0	0.00	0.0	0.0	0.00
ECG Charge(OPD Base)	1.0	0.00	0.0	0.0	0.00
Non Invasive Cardiology (Subtotal)			0.0	0.0	0.00

Total Bill Amount 3000.00
Net payable amount 3000.00
Bill Outstanding 3000.00

Received With Thanks From MANJULA KAMLESHKUMAR VALAND of Rs 0.0 /-
(Rs Zero Only)

Printed By: (Vaishali Salunke)
For, Savita Hospital-Live





PHYSICIAN EXAMINATION

Name:- MANJULA K VALAND
Reg.No: 20220803666

Age: 48/FEMALE
DOE: 13/08/2022

Physical Examination:

Height: 155CM Weight: 60KG PULSE: 70 Temperature: NORMAL
BMI: 25 BP: 140/90 SPO2- 97%

Chief Complaint: NAD

Past History: NAD

General Examination: NAD

Systemic Examination: NAD

INVESTIGATION :

ADVICE:

- LIFE STYLE MODIFICATION
- TAB-NEUROBLESS 1__0__0 (15 DAYS)
- TAB VITD3 60K ONCE A WEEK __06
- TAB SHELICAL (500) __0_0_1 (15 DAYS)

DR HIREN PATEL.





Examination By Ophthalmologist

Name:- MANJULA K VALAND
Reg.No: 20220803666

Age:48/FEMALE
DOE: 13/08/2022

Present Complaints: NAD

Medical History: NAD

Examination Of Eye:	<u>Right</u>	<u>Left</u>
External Examination :	NAD	NAD
Ati Seg Examination:	A/S WNL	NAD
Schiotz Tonometry IOP:	RRRL	NAD

Fundus: NILL

Without Glass Distant Vision: 6/6 _____ 6/6

Near Vision: _____

With Glass Distant Vision: 6/6 +1.DSPH _____ 6/6 +1.0DSPH

Near Vision: N6C+2.0DSPH _____ N6C+2.0DSPH

Colour Vision (With Ishihara Chart): WNL

Advice: NAD

DR CHETAN CHAUHAN



CANON RK-F2
13/AUG/2022 13:04
No. : 003107
NAME: _____ M/F

<RIGHT >
[REF] VD: 0.0
SPH CYL AX
+1.25 +0.50 176
+1.25 +0.25 2
+1.00 +0.25 177
[+1.00 +0.25 176]

<LEFT >
[REF]
+0.75 +1.25 171
+1.00 +0.75 175
+1.25 +0.50 175
[+1.25 +0.50 174]



EXAMINATION BY DENTAL

Name:- MANJULA K VALAND

Reg.No: 20220803666

AGE:48/FEMALE

DOE: 13/08/2022

Presenting Complaint: ROUTINE CHEAK UP

Medical History : NAD

Examination: ROOT SHUMP IN8

Impression: NAD

Advice: EXTRACTION IN 8

DR. RUSHDA MALEK





Patient Name : MANJULA KAMLESHKUMAR VALAND

Sample No. : 20220806056



Patient ID : 20220803666

Visit No. : OPD20220810225

Age/Sex : 48y/Female

Call. Date : 13-Aug-2022 09:02

Consultant : DR HIREN PATEL

S. Coll. Date : 13-Aug-2022 10:54

Ward : -


Report Date : 13-Aug-2022 13:42

CBC, ESR

Investigation	Result	Normal Value
Hemoglobin :	12.8 gm/dl	12.5 to 16.0 gm/dl
P.C.V. :	40.2 %	37.0 to 47.0 %
M.C.V. :	79.3 fL	78 to 100 fL
M.C.H. :	25.2 pg [L]	27 to 31 pg
M.C.H.C. :	31.8 g/dl [L]	32 to 36 g/dl
RDW :	11.9 %	11.5 to 14.0 %
RBC Count :	5.07 X 10 ⁶ / cumm	4.2 to 5.4 X 10 ⁶ / cumm
Polymorphs :	68 %	38 to 70 %
Lymphocytes :	27 %	15 to 48 %
Eosinophils :	03 %	0 to 6 %
Monocytes :	02 % [L]	3 to 11 %
Basophils :	00 %	0.0 to 1.0 %
Total :	100	< 100 > 100
WBC Count :	9800 /cmm	4000 to 10000 /cmm
Platelets Count :	275000 /cmm	1,50,000 to 4,50,000 /cmm
ESR - After One Hour :	17 mm/hr	1 to 20 mm/hr
P/S :		

Dr. Mehul Desai
G-9521



Patient Name :	MANJULA KAMLESHKUMAR VALAND	Sample No. :	20220806056 
Patient ID :	20220803666	Visit No. :	OPD20220810225
Age/Sex :	48y/Female	Call. Date :	13-Aug-2022 09:02
Consultant :	DR HIREN PATEL	S. Coll. Date :	13-Aug-2022 10:54
Ward :	-	Report Date :	13-Aug-2022 13:42

Blood Group

Investigation	Result	Normal Value
BLOOD GROUP :		
ABO	A	
Rh	Positive	
HBA1C		

Investigation	Result	Normal Value
Glycosylated Hb :	6.5 % [H]	Near Normal Glycemia : 6 to 7 Excellent Control : 7 to 8 Good Control : 8 to 9 Fair Control : 9 to 10 Poor Control : > 10
Average Plasma Glucose of Last 3 Months :	139.85	

FBS & PPBS

Investigation	Result	Normal Value
Blood Sugar (FBS) :	100 mg/dl	74 - 100 mg/dl
Urine Sugar (FUS) :	Nil	
Blood Sugar (PP2BS) :	154 mg/dl [H]	70 to 120 mg/dl
Urine Sugar (PP2US) :	Nil	



Dr. Mehul Desai
G-9521



Patient Name : MANJULA KAMLESHKUMAR VALAND

Sample No. : 20220806056



Patient ID : 20220803666

Visit No. : OPD20220810225

Age/Sex : 48y/Female

Call. Date : 13-Aug-2022 09:02

Consultant : DR HIREN PATEL

S. Coll. Date : 13-Aug-2022 10:54

Ward : -


Report Date : 13-Aug-2022 13:42

RENAL FUNCTION TEST

Investigation	Result	Normal Value
Creatinine :	0.8 mg/dl	0.6 - 1.4 mg/dl
Urea :	19 mg/ dl	13 - 45 mg/dl
Uric Acid :	3.6 mg/dl	3.5 - 7.2 mg/dl
Calcium :	8.4 mg/dl	8.5 - 10.5
Phosphorus :	3.6 mg/dl	1.5 - 6.8


Dr. Mehul Desai
G-9521



Patient Name :	MANJULA KAMLESHKUMAR VALAND	Sample No. :	20220806056 
Patient ID :	20220803666	Visit No. :	OPD20220810225
Age/Sex :	48y/Female	Call. Date :	13-Aug-2022 09:02
Consultant :	DR HIREN PATEL	S. Coll. Date :	13-Aug-2022 10:54
Ward :	-	Report Date :	13-Aug-2022 13:42

LFT (Liver Function Test)

Investigation	Result	Normal Value
Total Bilirubin :	0.7 mg/dl	0.2 to 1.0 mg/dl
Direct Bilirubin :	0.3 mg/dl	0.0 to 0.2 mg/dl
Indirect Bilirubin :	0.4 mg/dl	0.0 to 0.8 mg/dl
AST (SGOT) :	40 U/L [H]	5 to 34 U/L
ALT (SGPT) :	37 U/L	0 to 55 U/L
Total Protein (TP) :	7.3 g/dL	6.4 to 8.3, g/dl
Albumin (ALB) :	3.6 g/dl	3.5 to 5.2 g/dl
Globulin :	3.7 g/dl [H]	2.3 to 3.5 g/dl
A/G Ratio :	0.97	
Alkaline Phosphatase (ALP) :	94 U/L	40 to 150 U/L
GAMMA GT. :	19 U/L	7 to 35 U/L



Dr. Mehul Desai
G-9521




Savita

Superspeciality Hospital
(A Unit of Solace Healthcare Pvt. Ltd.)

Parivar Char Rasta, Waghodia-Dabhoi Ring Road, Vadodara-390019

☎ 0265-2578844 / 2578849 ✉ mh@savitahospital.com 🌐 savitahospital.com

Patient Name :	MANJULA KAMLESHKUMAR VALAND	Sample No. :	20220806056 
Patient ID :	20220803666	Visit No. :	OPD20220810225
Age/Sex :	48y/Female	Call. Date :	13-Aug-2022 09:02
Consultant :	DR HIREN PATEL	S. Coll. Date :	13-Aug-2022 10:54
Ward :	-	Report Date :	13-Aug-2022 13:42

Lipid Profile

Investigation	Result	Normal Value
Sample :	Fasting	
Sample Type :	Normal	
Cholesterol (Chol) :	140 mg/dl	Low risk : < 200 Moderate risk : 200 - 239 High risk : > or = 240
Triglyceride :	85 mg/dl	Normal : < 200.0 High : 200 - 499 Very High : > or = 500
HDL Cholesterol :	48 mg/dl	Low risk : > or = 60 mg/dL High risk : Up to 35 mg/dL
LDL :	75 mg/dl [L]	131.0 to 159.0(N) < 130.0(L) > 159.0(H)
VLDL :	17 mg/dl	Up to 0 to 34 mg/dl
LDL/HDL Ratio :	1.56	Low risk : 0.5 to 3.0 Moderate risk : 3.0 to 6.0 Elevted level high > 6.0
Total Chol / HDL Ratio :	2.92	Low Risk : 3.3 to 4.4 Average Risk : 4.4 to 7.1 Moderate Risk : 7.1 to 11.0 High Risk : > 11.0
Total Lipids :	573 mg/dl	400 to 700 mg/dl

Note :- Lipemic samples give high triglyceride value and falsely low LDL value.

Dr. Mehul Desai
G-9521



Patient Name :	MANJULA KAMLESHKUMAR VALAND	Sample No. :	20220806056 
Patient ID :	20220803666	Visit No. :	OPD20220810225
Age/Sex :	48y/Female	Call. Date :	13-Aug-2022 09:02
Consultant :	DR HIREN PATEL	S. Coll. Date :	13-Aug-2022 10:54
Ward :	-	Report Date :	13-Aug-2022 13:42

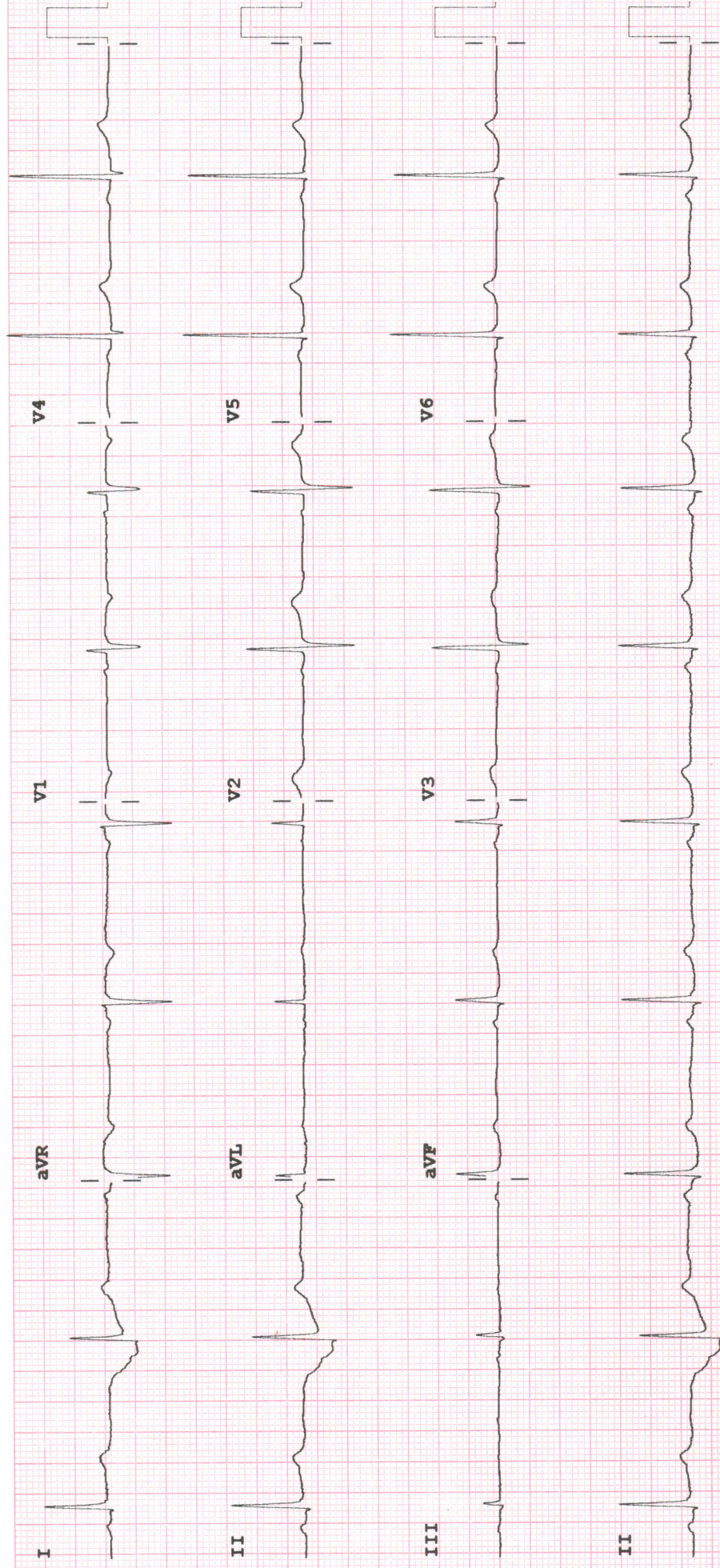
Urine R/M

Investigation	Result	Normal Value
Quantity - :	10 ml	
Colour - :	Yellow	
Reaction (pH) :	6.5	4.6-8.0
Turbidity :	Clear	
Deposit :	Absent	Absent
Sp.Gravity :	1.020	1.005-1.010
Protein :	Absent	Absent
Glucose :	Absent	Absent
Bile Salts :	Absent	Absent
Bile pigments :	Absent	Absent
Ketones :	Absent	Absent
Urobilinogen :	Absent	
Blood :	Absent	Absent
Pus Cells :	1-2 /hpf	0-5/hpf
Red Blood Cells :	0-1 /hpf	Absent
Epithelial Cells :	1-2 /hpf	

Dr. Mehul Desai
G-9521

Rate 55
 PR 152
 QRSd 80
 QT 436
 QTc 417
 --AXIS--
 P 48
 QRS 42
 T 41

12 Lead; Standard Placement



Device:

Speed: 25 mm/sec

Limb: 10 mm/mV

Chest: 10.0 mm/mV

F 50~ 0.50-150 Hz W

PH09

P?



2D-ECHOCARDIOGRAPHY AND COLOR DOPPLER REPORT

NAME: MANJULA VALAND

DATE : 13/08/2022

AGE/SEX: 48YRS/FEMALE

REF BY: DR. HIREN PATEL

OBSERVATION:

- NORMAL LV SIZE AND NORMAL LV SYSTOLIC FUNCTION. LVEF = 60% (VISUAL).
- GRADE II LV DIASTOLIC DYSFUNCTION.
- NO RWMA AT REST.
- TRIVIAL MR. NO MS.
- NO AR. NO AS.
- TRIVIAL TR. NO PAH.
- NORMAL SIZED LA, RA & RV WITH NORMAL RV SYSTOLIC FUNCTION.
- NORMAL SIZED MPA, RPA & LPA.
- INTACT IAS AND IVS.
- NO E/O INTRACARDIAC CLOT/VEGETATION/ PE.
- NORMAL IVC.

CONCLUSION:

- NORMAL LV/RV SIZE AND SYSTOLIC FUNCTION.
- NO RWMA AT REST.
- LVEF = 60% (VISUAL).

DR.NIRAV BHALANI
[CARDIOLOGIST]

DR.ARVID SHARMA
[CARDIOLOGIST]

DR. CHIRAG SHETH
[CARDIOLOGIST]

Handwritten signature/initials in blue ink, possibly reading 'H.P.' and 'A.M.P.'



Saturday, August 13, 2022

MANJULA VALAND

48 YEARS/FEMALE

ULTRASONOGRAPHY OF ABDOMEN AND PELVIS SCREENING

Liver shows normal size and echogenicity. No mass lesion detected.

PV, CBD and intrahepatic biliary radicals shows no dilatation.

The gall bladder is distended and show normal gall bladder wall thickness. There is no evidence of gallstones.

Spleen appears normal in size and echotexture. No evidence of focal lesion.

Pancreas appears normal in size and echotexture. No focal lesion.

Both kidneys show normal size, position and cortical echogenicity.

Tiny concretions are noted in both kidneys.

Corticomedullary differentiation is preserved bilaterally.

No hydronephrosis on either side.

The urinary bladder distended and appears normal. No calculus or mass lesion is noted.

No evidence of Lymphadenopathy or ascites seen.

No e/o dilated bowel loops seen.

CONCLUSION:

BILATERAL TINY RENAL CONCRETIONS.

DR SARJAN VASAVA, DMRD



Saturday, August 13, 2022

MANJULA VALAND

48 YEARS/FEMALE

CHEST X RAY PA VIEW

Both the lung fields appear normal.

Both costophrenic angles appear clear.

Cardiac silhouette appear normal.

Both hila appears normal.

Mediastinum and aorta appear normal.

Bony thorax appears normal.

No evidence of free gas seen under dome of diaphragm.

COMMENTS:

- **NORMAL BOTH LUNG FIELDS.**
- **NORMAL CARDIAC SIZE.**

Dr. Sarjan Vasava
DMRD