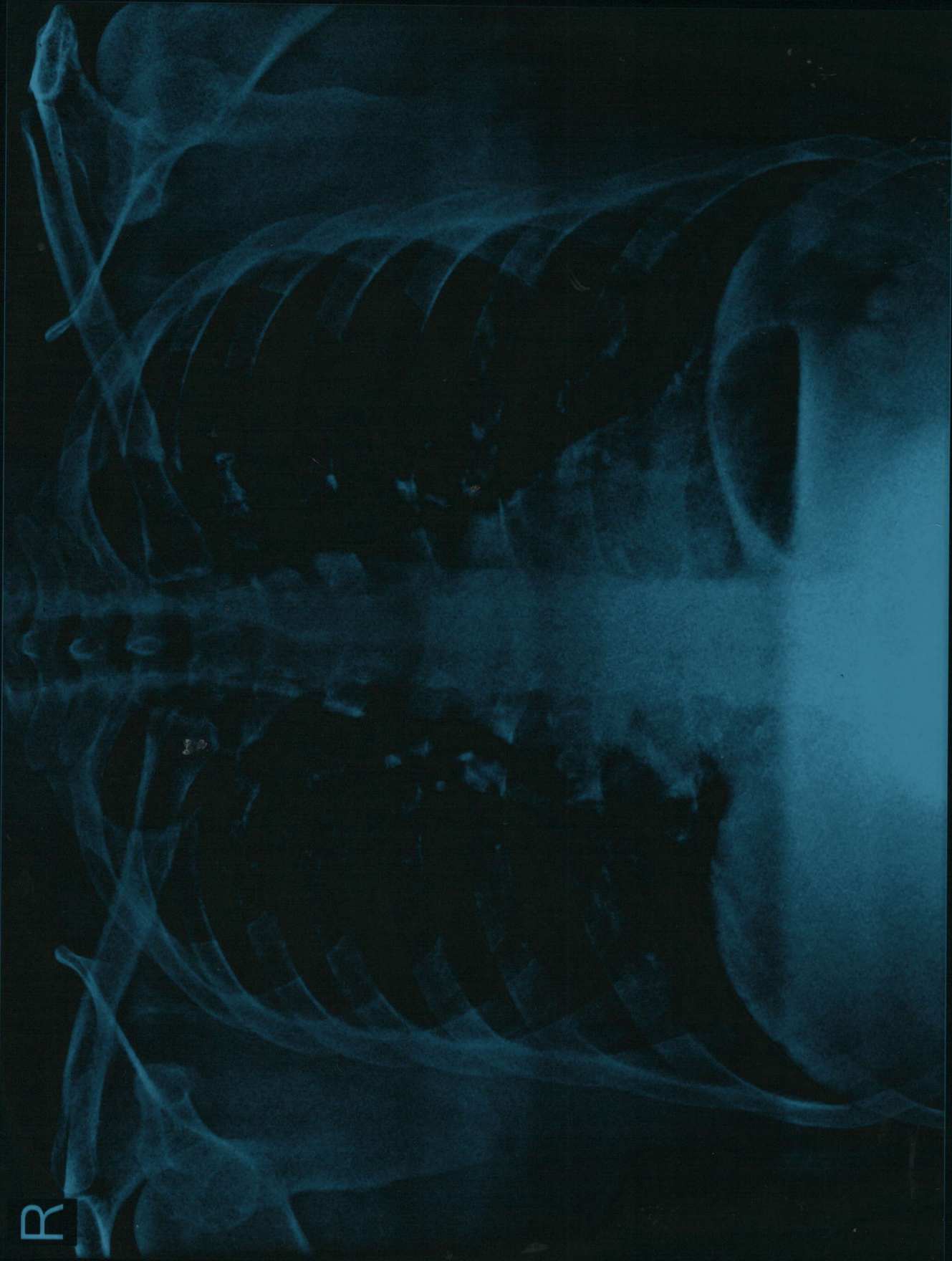
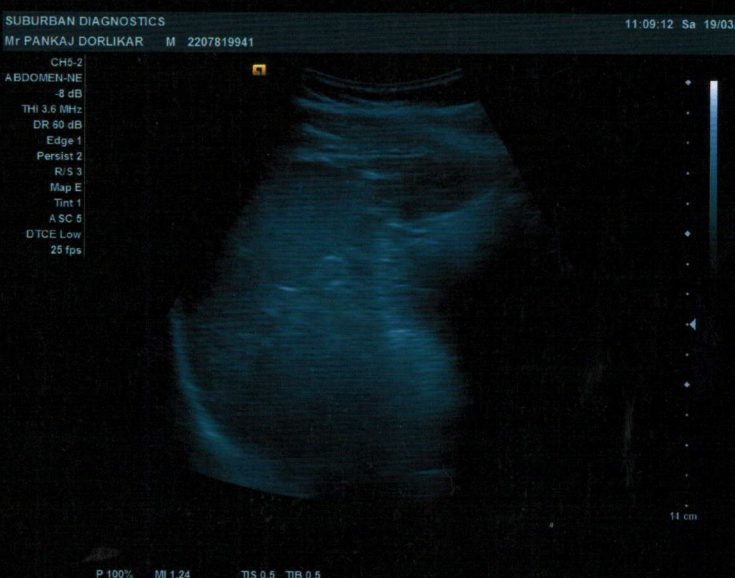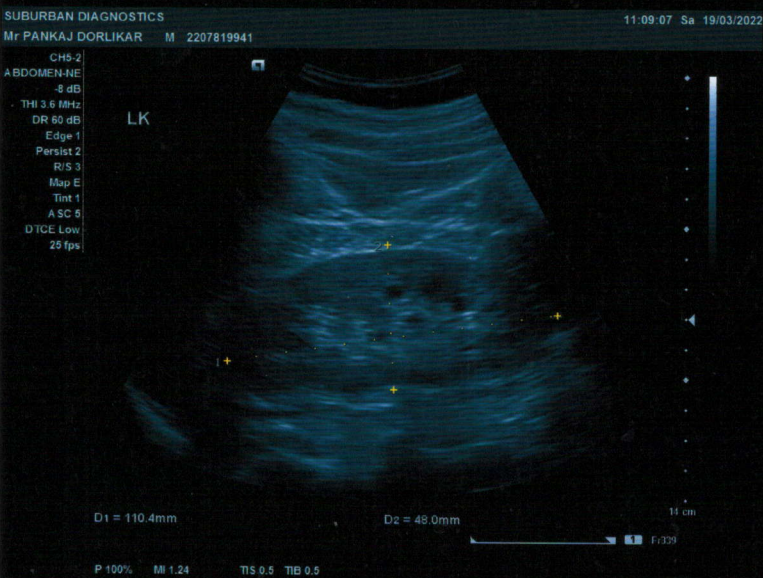
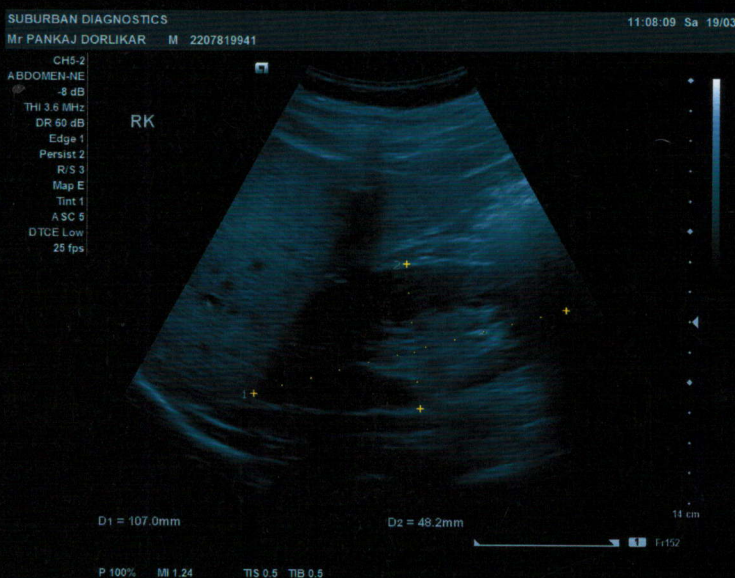
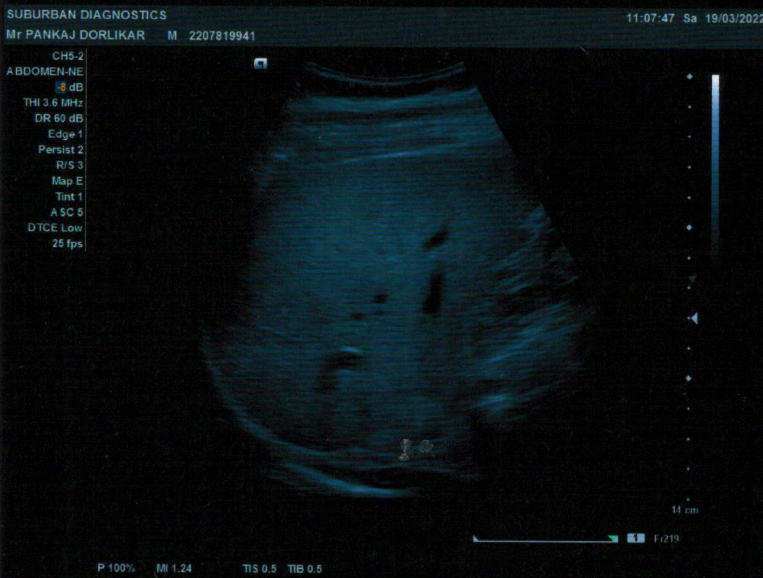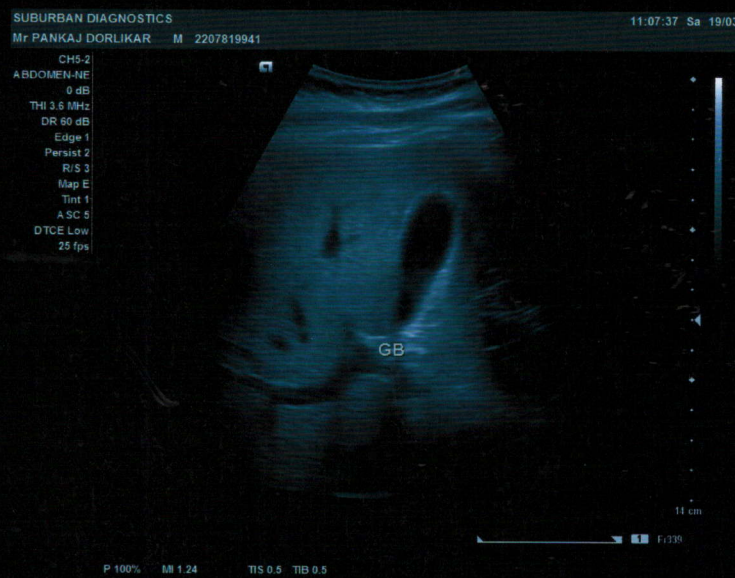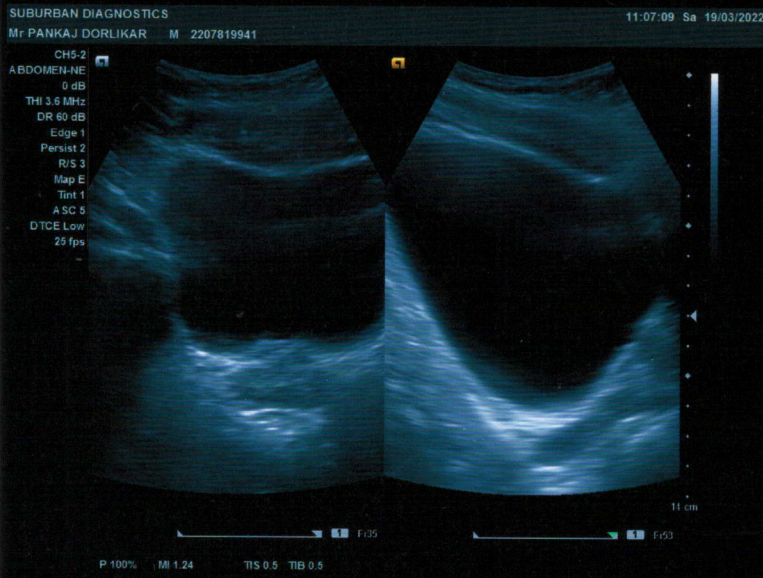


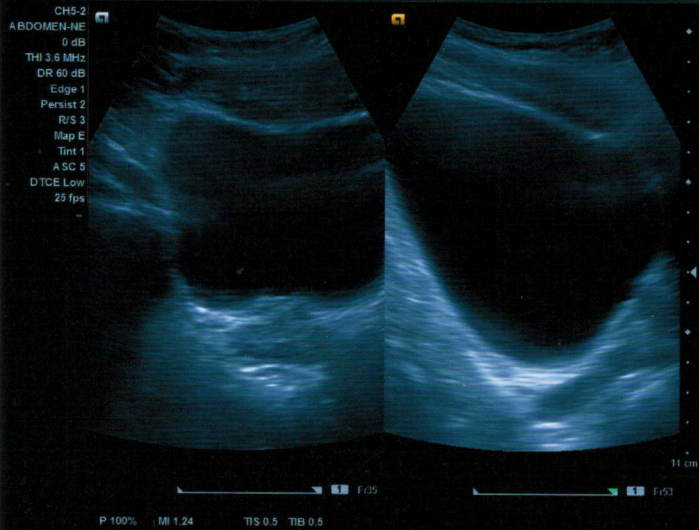
R



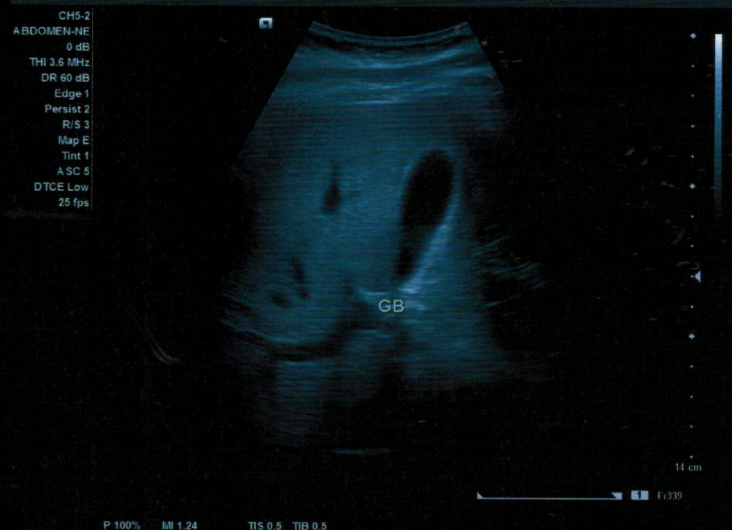Mr PANKAJ DORLIKAR M 37 YRS 2207819941 CHEST PA 3/19/2022



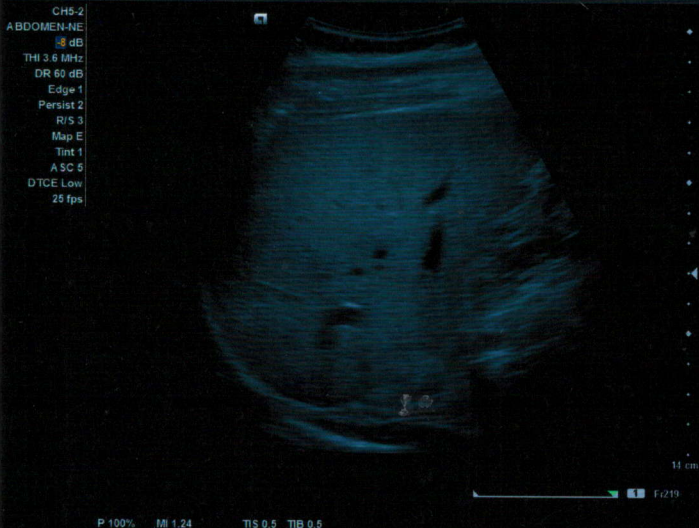SUBURBAN DIAGNOSTICS
Mr PANKAJ DORLIKAR M 2207819941 11-07:09 Sa 19/03/2022



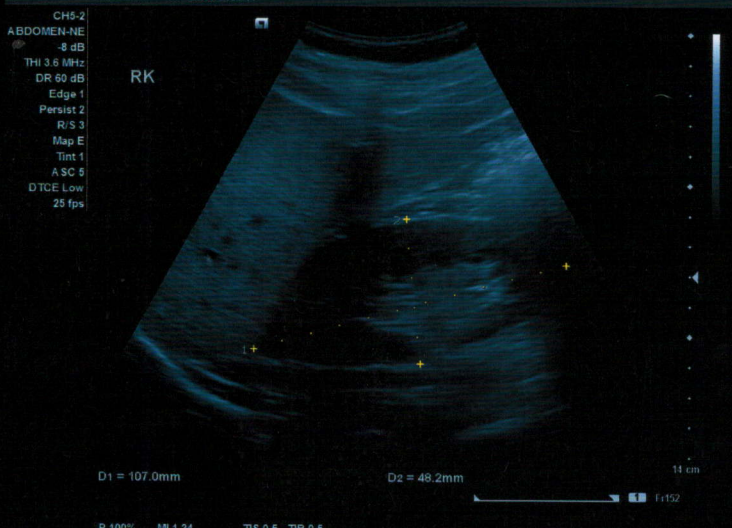
SUBURBAN DIAGNOSTICS
Mr PANKAJ DORLIKAR M 2207819941 11-07:37 Sa 19/03/2022



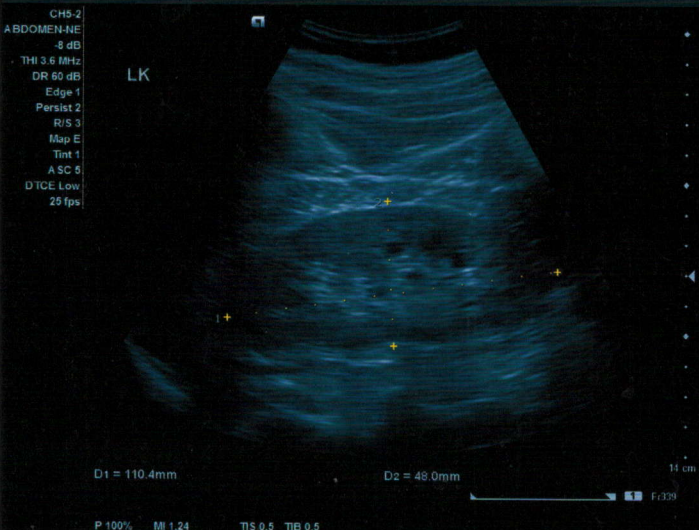
SUBURBAN DIAGNOSTICS
Mr PANKAJ DORLIKAR M 2207819941 11-07:47 Sa 19/03/2022



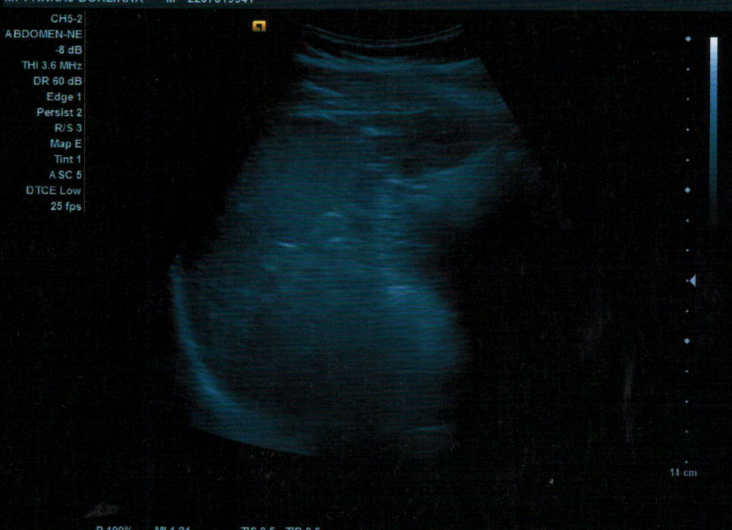SUBURBAN DIAGNOSTICS
Mr PANKAJ DORLIKAR M 2207819941 11-08:09 Sa 19/03/2022



SUBURBAN DIAGNOSTICS
Mr PANKAJ DORLIKAR M 2207819941 11-09:07 Sa 19/03/2022



SUBURBAN DIAGNOSTICS
Mr PANKAJ DORLIKAR M 2207819941 11-09:12 Sa 19/03/2022



Pankaj Dorlikar
37/M

19.3.22

PHY2.

History and Complaints:

nil

EXAMINATION FINDINGS:

Height (cms):	179	Weight (kg):	87	BMI	27.2
Temp (0c):	Afebrile	Skin:	Normal	} Mas	
Blood Pressure (mm/hg):	110/80	Nails:	Healthy		
Pulse:	82	Lymph Node:	Not Palpable		

Systems

Cardiovascular: S1,S2 Normal No Murmurs

Respiratory: Air Entry Bilaterally Equal

Genitourinary: Normal

GI System: Soft non tender No Organomegaly

CNS: Normal

IMPRESSION:

F2T
↓ vit B12, D3
othw WNL

ADVICE:

- 1) C. Nav up OD, daily x 60 DS
- 2) C. upst D3 60x weekly x 12 weeks

CHIEF COMPLAINTS:

1)	Hypertension:	} nil
2)	IHD:	
3)	Arrhythmia:	
4)	Diabetes Mellitus :	
5)	Tuberculosis :	
6)	Asthama:	
7)	Pulmonary Disease :	

PUNE LAB ADDRESS: Seraph Centre, Opp. BSNL Exchange, Shahu College Road, Off Pune-Satara Road, Behind Panchami Hotel, Pune - 411009

CENTRAL PROCESSING LAB: 2nd Floor, Aston, Sundervan Complex, Above Mercedes Showroom, Andheri West, Mumbai - 400053

HEALTHLINE - MUMBAI: 022-6170-0000 | OTHER CITIES: 1800-266-4343 | For Feedback - customerservice@suburbandiagnosics.com | www.suburbandiagnosics.com

8)	Thyroid/ Endocrine disorders :	
9)	Nervous disorders :	
10)	GI system :	
11)	Genital urinary disorder :	
12)	Rheumatic joint diseases or symptoms :	
13)	Blood disease or disorder :	nm,
14)	Cancer/lump growth/cyst :	
15)	Congenital disease :	
16)	Surgeries :	
PERSONAL HISTORY:		
1)	Alcohol	Yes
2)	Smoking	
3)	Diet	veg
4)	Medication	nil

Krutika Ingle

Dr. KRUTIKA INGLE
MBBS, D.DM, PG in Diabetology (USA)
MMC Regd - 2012 103018

Preventive Health Check-up | Pathology | Digital X-Ray | Sonography | Colour Doppler | Mammography | BMD (DXA Scan) | OCS | Stress Test/TMT | 2D Echo | Spirometry | Eye Examination | Dental Examination | Diet Consultation | Audiometry | OT Sterility | Water Sterility | Clinical Res

O
R
T

Date:-

CID:

Name:-

Sex / Age: /

EYE CHECK UP

Chief complaints:

Systemic Diseases:

Past history:

Unaided Vision:

Aided Vision:

Refraction:

2 mL

NA

	(Right Eye)				(Left Eye)				
	Sph	Cyl	Axis	Vn	Sph	Cyl	Axis	Vn	
Distance	<i>---</i>				<i>(N)</i>	<i>---</i>			<i>(N)</i>
Near	<i>---</i>					<i>---</i>			

Colour Vision: Normal / Abnormal →

Remark:

NIL

Krutika Ingle

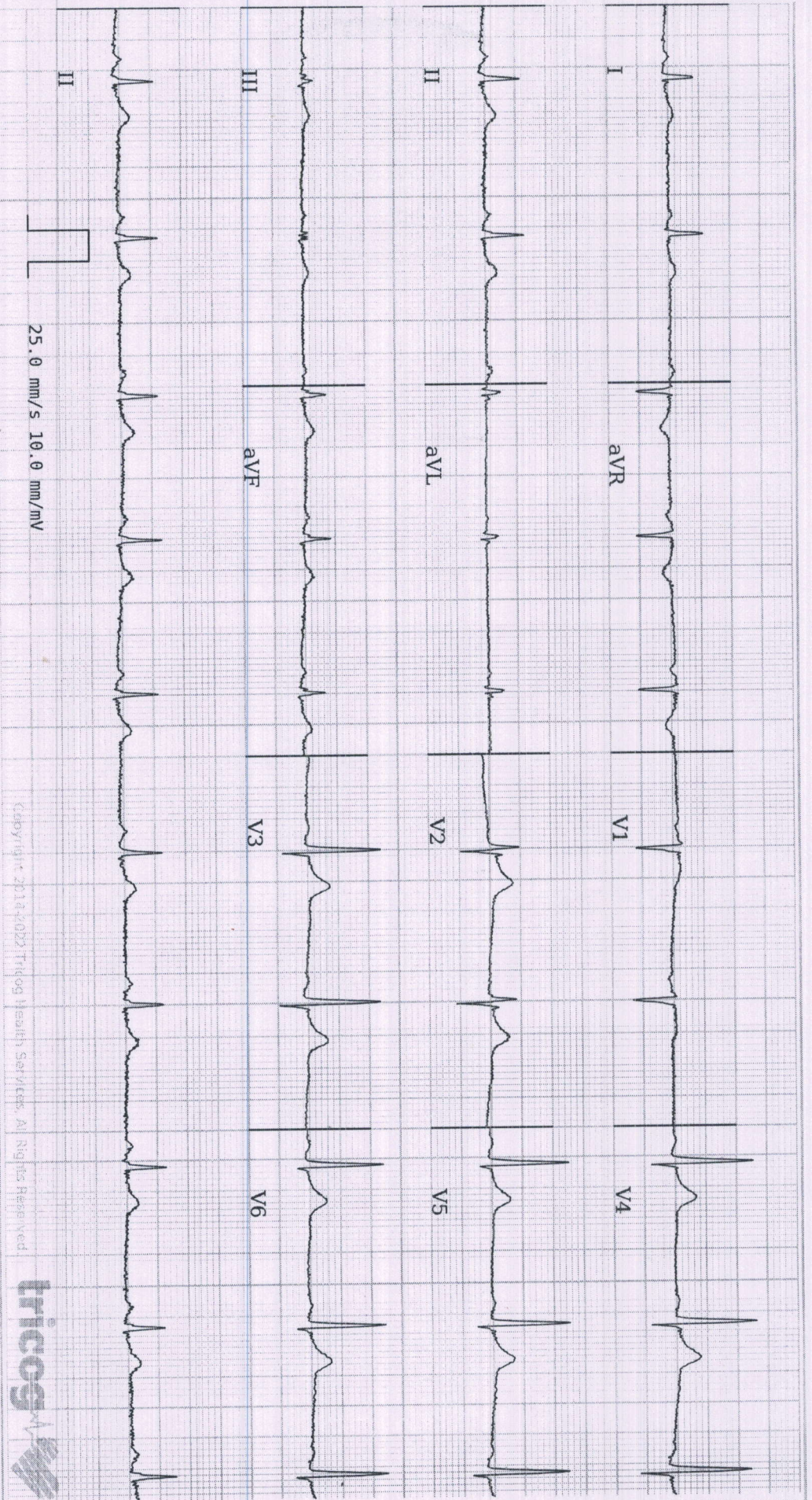
Dr. KRUTIKA INGLE

MBBS, D.DM, PG in Diabetology (USA)
MMC Regd - 2012 103018

Patient Name: PANKAJ DORLIKAR

Date and Time: 19th Mar 22 10:24 AM

Patient ID: 2207819941



Age **37** 8 14
years months days

Gender **Male**

Heart Rate **60bpm**

Patient Vitals

BP: 110/80 mmHg

Weight: 87 kg

Height: 179 cm

Pulse: 82 bpm

Spo2: NA

Resp: NA

Others:

Measurements

QS RD: 92ms

QT: 374ms

QTc: 374ms

PR: 140ms

P-R-T: 46° 40° 55°

REPORTED BY

Dr. Krutika Ingle

MBBS, D.DM, PG in Diabetology (USA)

2012103018

ECG Within Normal Limits: Sinus Rhythm, Normal Axis. Please correlate clinically.

Disclaimer: 1) Analysis in this report is based on ECG alone and should be used as an adjunct to clinical history, symptoms, and results of other invasive and non-invasive tests and must be interpreted by a qualified physician. 2) Patient vitals are entered by the clinician and not derived from the ECG.



CID : 2207819941
Name : Mr PANKAJ DORLIKAR
Age / Sex : 37 Years/Male
Ref. Dr :
Reg. Location : Pimple Saudagar, Pune Main Centre

Reg. Date : 19-Mar-2022 / 11:01
Reported : 19-Mar-2022 / 11:50

Use a QR Code Scanner
Application To Scan the Code

USG WHOLE ABDOMEN

LIVER:

Liver is normal in size, shape and shows raised echopattern. It shows normal parenchymal echo pattern. The intra hepatic biliary and portal radical appear normal. No evidence of any intra hepatic cystic or solid lesion seen. The main portal vein and CBD appears normal.

GALL BLADDER:

The gall bladder is physiologically distended and appears normal. No evidence of gall stones or mass lesions seen.

PANCREAS:

The pancreas is well visualised and appears normal. No evidence of solid or cystic mass lesion.

KIDNEYS:

Both the kidneys are normal in size shape and echotexture.
No evidence of any calculus, hydronephrosis or mass lesion seen.
Right kidney measures- 10.7x 4.8 cm. Left kidney measures- 11.0 x 4.8cm.

SPLEEN:

The spleen is normal in size and echotexture. No evidence of focal lesion is noted.
There is no evidence of any lymphadenopathy or ascites.

URINARY BLADDER:

The urinary bladder is well distended and reveal no intraluminal abnormality.

PROSTATE:

Prostate is normal in size, shape and echopattern. No focal lesion seen.

IMPRESSION:-

FATTY INFILTRATION OF LIVER.
NO OTHER SIGNIFICANT ABNORMALITY DETECTED.

-----End of Report-----

This report is prepared and physically checked by DR RUJUTA before dispatch.

DR. RUJUTA SAWANT
MBBS DMRE
Regd. No. 2011/11/3329
Consultant Radiologist

Click here to view images <http://202.143.96.162/Suburban/Viewer?ViewerType=3&AccessionNo=2022031909300768>



CID : 2207819941
Name : Mr PANKAJ DORLIKAR
Age / Sex : 37 Years/Male
Ref. Dr :
Reg. Location : Pimple Saudagar, Pune Main Centre

Reg. Date : 19-Mar-2022 / 11:00
Reported : 19-Mar-2022 / 13:06

X-RAY CHEST PA VIEW

Both lung fields are clear.

Both costo-phrenic angles are clear.

The cardiac size and shape are within normal limits.

The domes of diaphragm are normal in position and outlines.

The skeleton under review appears normal.

IMPRESSION:

NO SIGNIFICANT ABNORMALITY IS DETECTED.

-----End of Report-----

This report is prepared and physically checked by DR RUJUTA before dispatch.

DR. RUJUTA SAWANT
MBBS DMRE
Regd. No. 2011/1/3329
Consultant Radiologist

Click here to view images <http://202.143.96.162/Suburban/Viewer?ViewerType=3&AccessionNo=2022031909300776>



सत्यमेव जयते

भारत सरकार

GOVERNMENT OF INDIA



Pankaj Vijay Dorlikar

पंकज विजय डोरलीकर

जन्म तिथि/DOB:

05-07-1984

पुरुष / MALE



6530 0176 2825

आधार - सामान्य माणसाचा अधिकार

SUBURBAN DIAGNOSTIC (I) PVT. LTD.
"Fortuna" Ground Floor, Near Shivar
Garden Chowk, Next to Radha Krishna
Hotel, Pimple Saddagar, Pune-411 027.