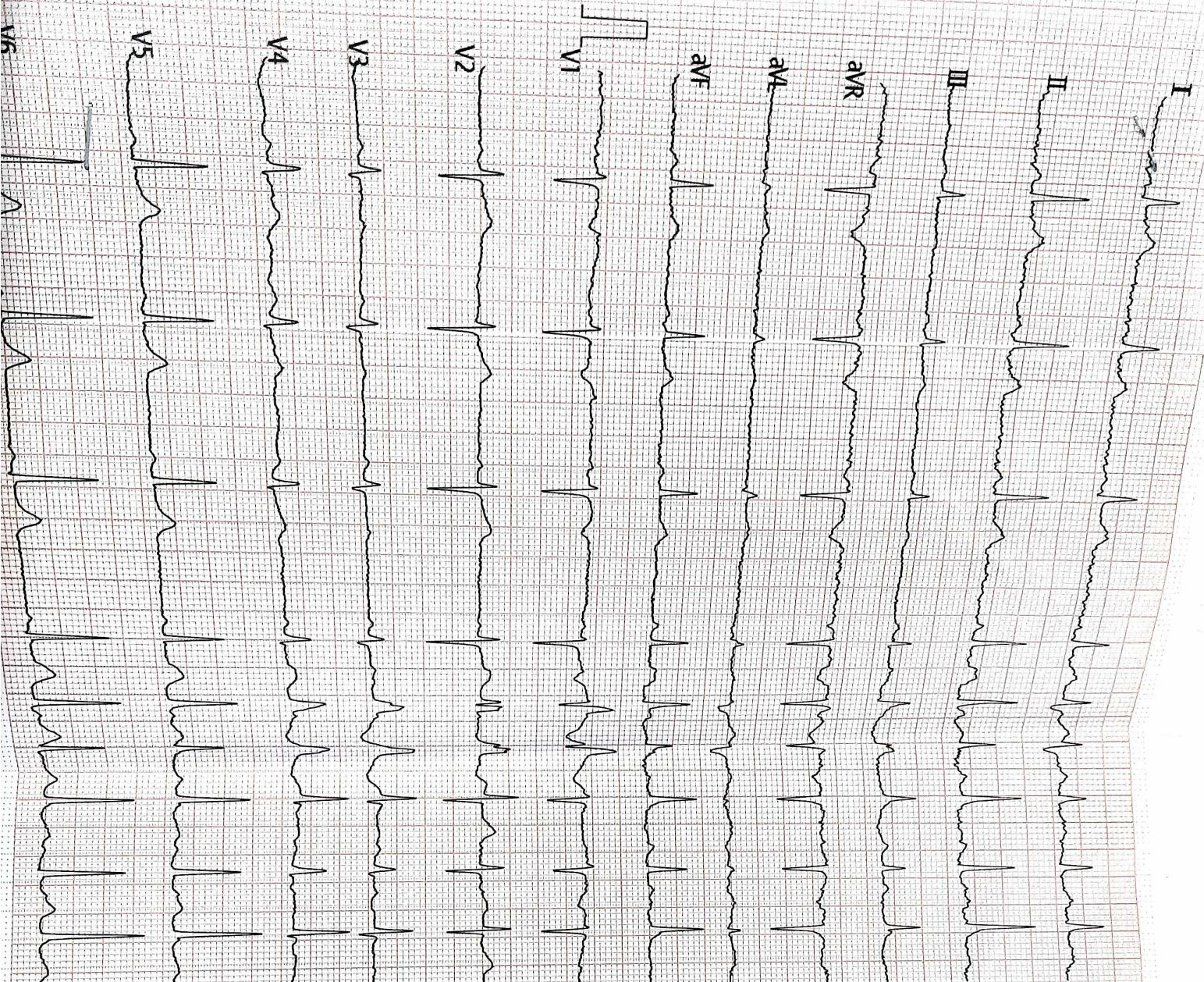

Vent. Rate(BPM) : 65

PR Int.(ms) : 163

P/QRS/T Int.(ms) : 123 88 194

QT/QTc Int.(ms) : 400 416

P/QRS/T Axis(Deg.) : 90 48 38

RV1/SV5 Amp.(mV) : 0.14 0.00

RV5/SV1 Amp.(mV) : 0.99 0.75

<ECG Analysis Result>:

803 Sinus Arrhythmia

851 Premature Atrial Complex

*** Abnormal ECG ***

V2:33 Technician :

Note : Unconfirmed Report Need

ST LEVEL(mV)

	I	II	III	aVR	aVL	aVF
	+0.01	+0.01	+0.00	-0.01	+0.00	+0.00
	V1	V2	V3	V4	V5	V6
	+0.00	+0.03	-0.00	+0.00	+0.00	+0.01



Name	: Surochi Bhandari	Age	: 33 Yrs. / F
Thanks To	: Self	Date	: 11.03.2022

ULTRASOUND STUDY OF WHOLE ABDOMEN

LIVER:

Liver is normal in size, shape & echotexture. No focal mass lesion is seen. Intra hepatic biliary radicles are normal. Portal vein is normal in caliber.

GALL BLADDER :

Gall bladder is well distended. The wall thickness appears normal. No evidence of calculus or mass lesion is seen. C.B.D. appears normal.

PANCREAS :

Pancreas is normal in size, shape & echotexture. No focal mass lesion is seen.

SPLEEN :

Spleen is normal in size, shape & echotexture. No focal mass lesion is seen.

BOTH KIDNEYS :

Both kidneys are normal in size, shape & echotexture. Renal parenchyma appears normal. No evidence of hydronephrosis, calculus or cortical scarring is seen in either kidney.

Right kidney measures : 9.8 x 4.3 cms.

Left kidney measures : 10.5 x 3.7 cms.

URINARY BLADDER :

Urinary bladder is well distended and appears normal in contour. The wall thickness appears normal.

UTERUS :

Uterus is AVAF, normal in size, shape and echotexture. It measures 8.7 x 4.9 x 3.7 cms. Endometrial appears normal and measures 8 mm.

BOTH OVARIES :

A well defined echofree cyst measuring 30 x 25 mm is seen in right ovary.

Left ovary is normal in size, shape and echotexture.

Left ovary measures: 2.2 x 1.7 cms.

No obvious abdominal lymphadenopathy is seen.

No free fluid is seen in peritoneal cavity.

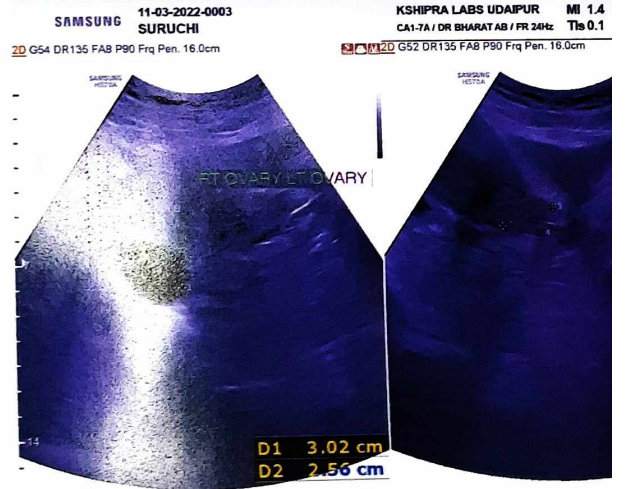
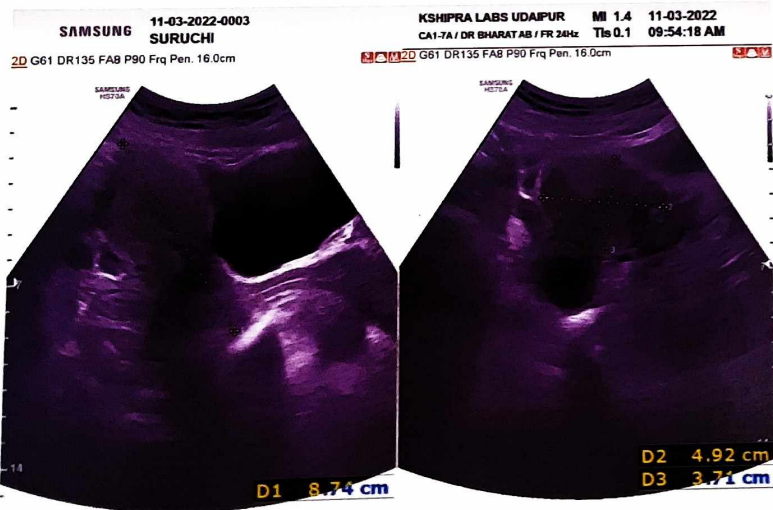
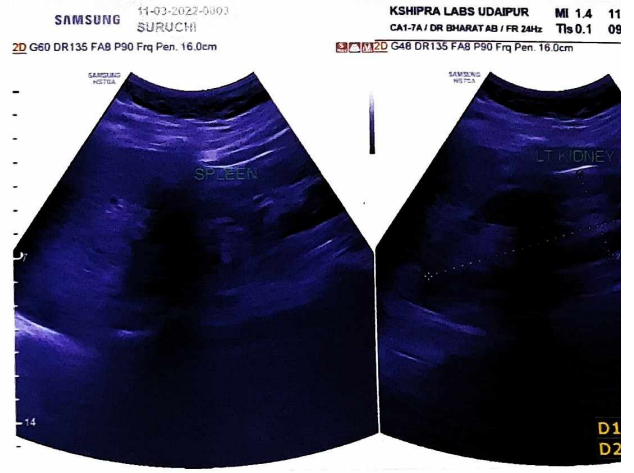
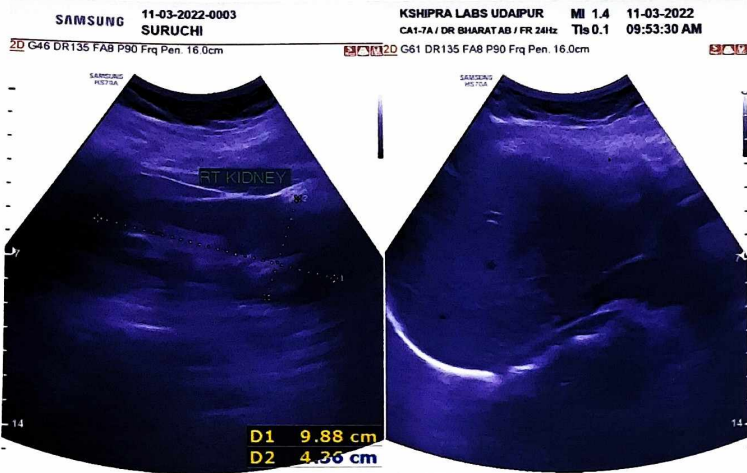
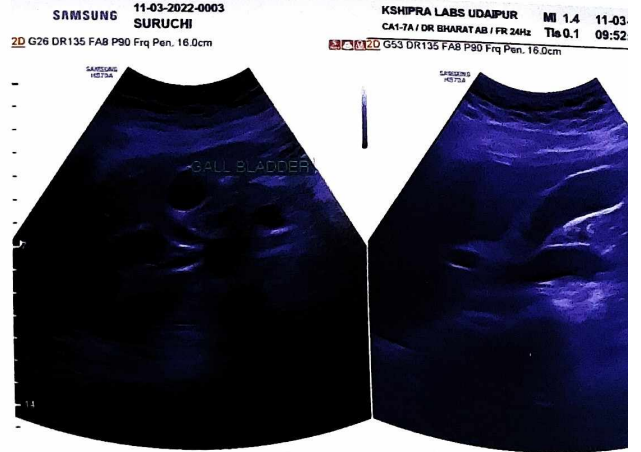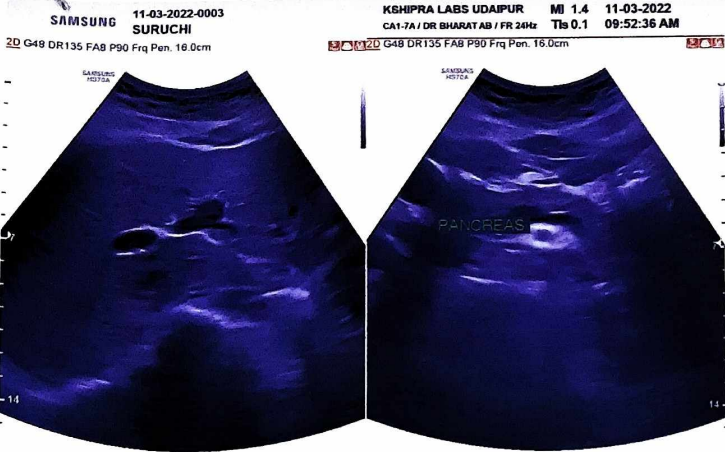
OPINION:

- Right ovarian follicular cyst.


Dr Ravi Soni
MD (Radio-Diagnosis)
Consultant Radiologist

(This report is not valid for any Medico-legal purpose)

ENCL:- PCPNDT Registration Certificate is printed on the back side of this report.





Summary

KSHIPRA SCANS & LABS
2B COURT CHOURAHA UDAIPUR
 89756164/MRS SURUCHI BHANDARI

33 Yrs/Female 0 Kg/0 Cms

Ref. By :
 Medication :
 Objective :

Protocol : BRUCE
 History :

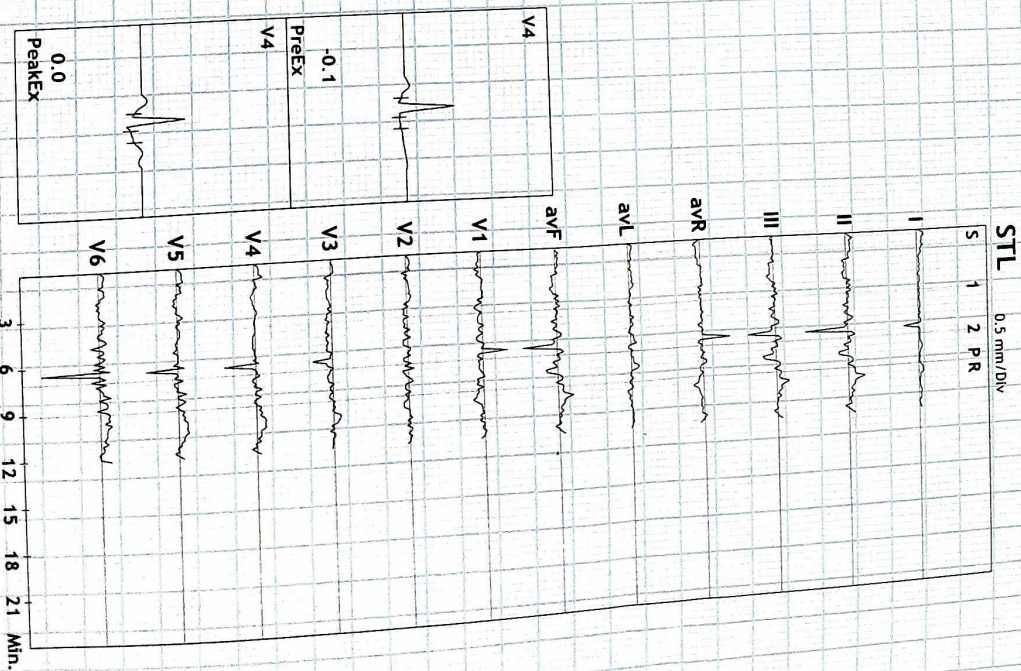
Date: 11-Mar-2022 12:54:50 PM

Stage	Stage Time (Min:Sec)	Phase Time (Min:Sec)	Speed (mph)	Grade (%)	METs	H.R. (bpm)	B.P. (mmHg)	R.P.P. (x100)	PVC	Comments
Supine					1.0	68	120/80	81	-	
Standing					1.0	68	120/80	81	-	
ExStart					1.0	111	120/80	133	-	
Stage 1	3:00	3:01	1.7	10.0	4.7	124	120/80	148	-	
Stage 2	3:00	6:01	2.5	12.0	7.1	139	130/80	180	-	
PeakEx	2:03	8:04	3.4	14.0	9.2	155	130/90	201	-	
Recovery	1:00		0.0	0.0	1.2	95	130/90	123	-	
Recovery	3:00		0.0	0.0	1.0	94	120/80	112	-	

Findings :

Exercise Time : 8:04 minutes
 Max HR attained : 155 bpm 83% of Max Predictable HR 187
 Max BP : 130/90(mmHg)
 Workload attained : 9.2 (Good Effort Tolerance)
 No significant ST segment changes noted during exercise or recovery.
 No Angina/Arrhythmia/S3/murmur
 Final Impression : Test is negative for inducible ischaemia.
 Maximum Depression: 5:29

Advice/Comments:





12 Lead + Median


89756164/MRS SURUCHI HARWANI
33 Yrs/Female
0 Kg/0 Cms
Date: 11-Mar-2022 12:54:59 PM

MPHR: 36% of 187
Speed: 0.0 mph
Grade: 0.0%

Raw ECG
BRUCE
(1.0-100)Hz

Ex Time 00:30
BLG: On
Notch: On

Supine
10.0 mm/mV
25 mm/Sec.



Signature

KSHIPRA SCANS & LABS

KSHIPRA SCANS & LABS
2B COURT CHOURAHA UDAIPUR



12 Lead + Median

89756164/MRS SURUCHI
33 Yrs/Female
0 Kg/0 Cms
Date: 11-Mar-2022 12:54:59 PM

MPPR: 36% of 187
Speed: 0.0 mph
Grade: 0.0%

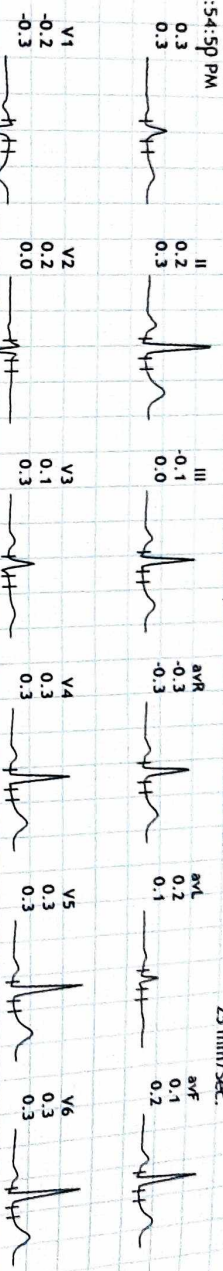KSHIPRA SCANS & LABS
2B COURT CHOURAHA UDAIPUR

Raw ECG
BRUCE
(1.0-100)Hz

Ex Time 00:36
BLC: On
Notch: On

Standing
10.0 mm/mv
25 mm/Sec.

4X 80 ms Post J





12 Lead + Median

KSHIPRA SCANS & LABS

2B COURT CHOURAHA UDALPUR

4X 80 MS Post J

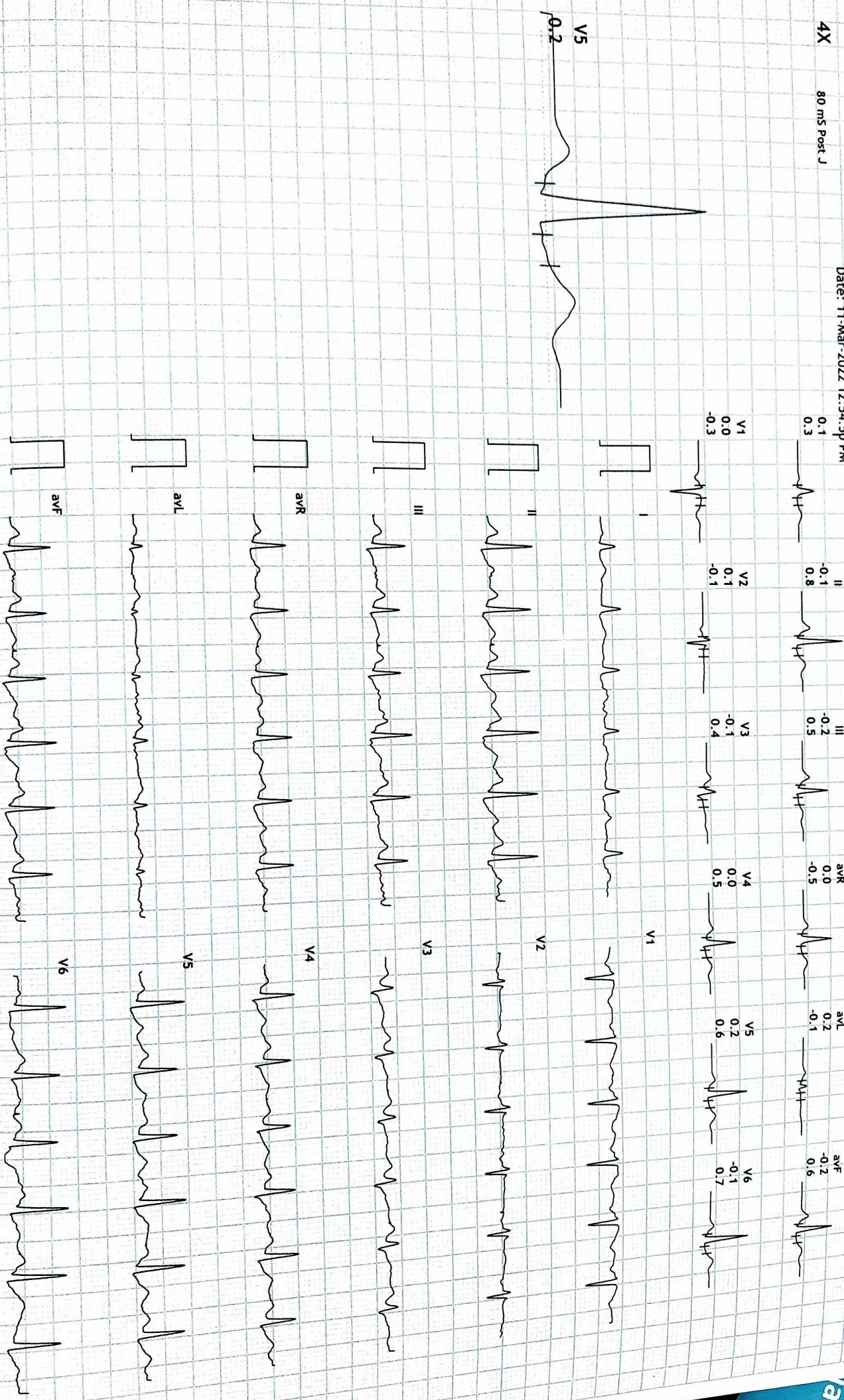
89756164/MRS SURUCHI
33 Yrs/Female
0 Kg/0 Cms
Date: 11-Mar-2022 12:54:59 PM

MPHR: 66% of 187
Speed: 1.7 mph
Grade: 10.0%

Raw ECG
BRUCE
(1.0-100)Hz

Ex Time 03:00
BLC: On
Notch: On

BRUCE: Stage 1 (3:00)
10.0 mm/mV
25 mm/Sec.



2900

10/11/22

asth



12 Lead + Median

KSHIPRA SCANS & LABS

2B COURT CHOURAHA UDAIPUR

89756164/MRS SURUCHI KHARA UDPA Rpbm
33 Yrs/Female
0 Kg/0 Cms
Date: 11-Mar-2022 12:54:50 PM

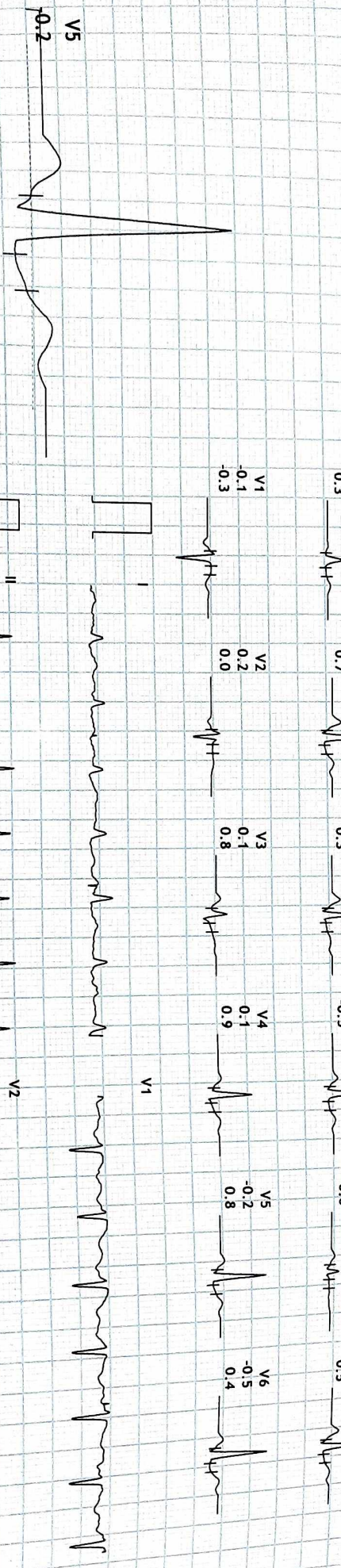
MPHR: 74% of 187
Speed: 2.5 mph
Grade: 12.0%

Raw ECG
BRUCE
(1.0-100)Hz

Ex Time 06:00
BLC : On
Notch : On

BRUCE: Stage 2(3:00)
10.0 mm/mV
25 mm/Sec.

4X 80 ms Post J



99N
रक्षा

ajasth



12 Lead + Median

89756164/MRS SURUCHI HARSA KEDIA Bhopm
33 Yrs/Female
0 Kg/0 Cms
Date: 11-Mar-2022 12:54:50 PM

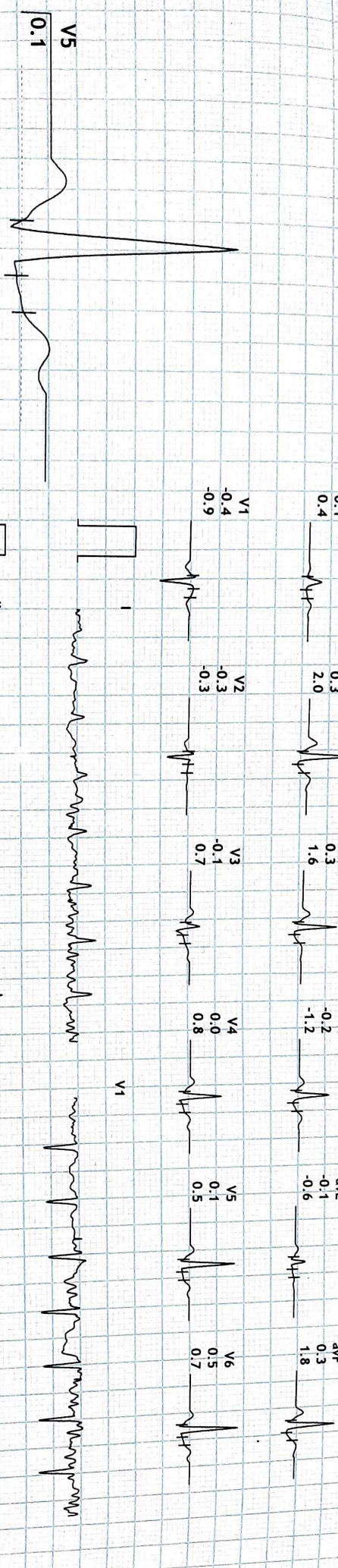
MPHR: 82% of 187
Speed: 3.4 mph
Grade: 14.0%

Raw ECG
BRUCE
(1.0-100)Hz

Ex Time 08:03
BLC : On
Notch : On

BRUCE: PeakEx(2:03)
10.0 mm/mV
25 mm/Sec.

4X 80 ms Post J



12 Lead + Median

89756164/MRS SURUCHI
33 Yrs/Female
0 Kg/0 Cms
Date: 11-Mar-2022 12:54:50 PM

MPHR: 50% of 187
Speed: 0.0 mph
Grade: 0.0%

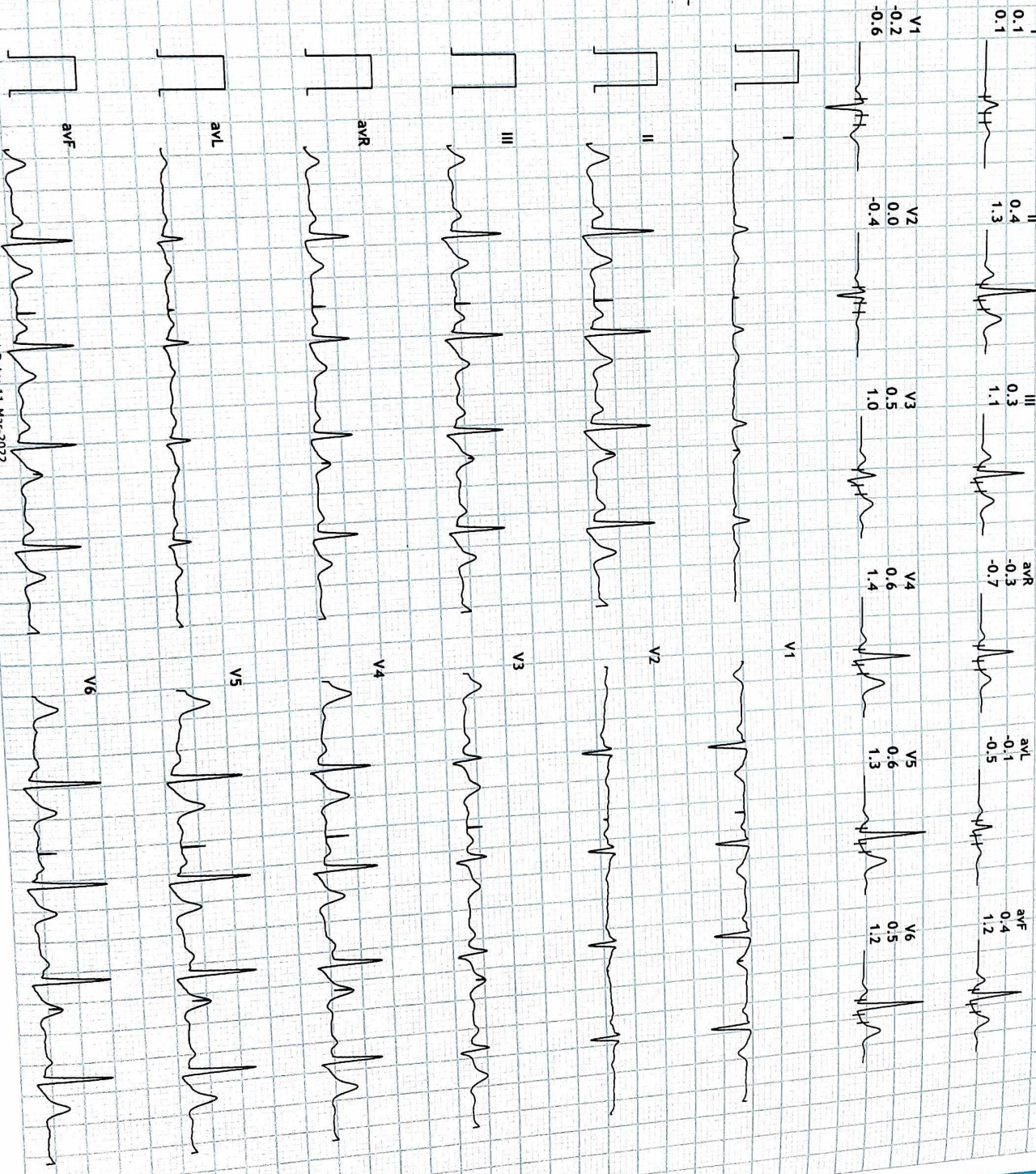
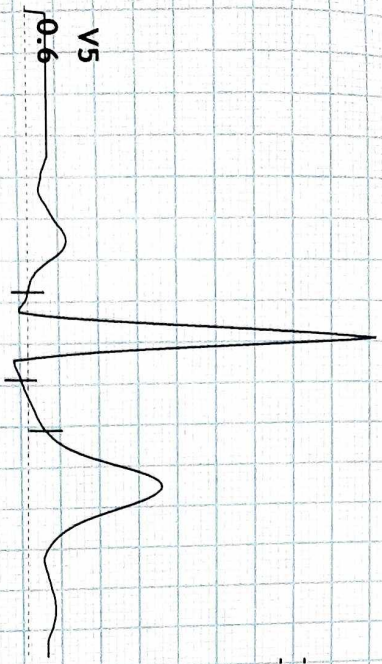
KSHIPRA SCANS & LABS
2B COURT CHOURAHA UDAIPUR

Raw ECG
BRUCE
(1.0-100)Hz

Ex Time 08:04
BLC : On
Notch : On

Recovery(1:00)
10.0 mm/mV
25 mm/Sec.

4X 80 ms Post J



12 Lead + Median

89756164/MRS SURUCHI BIRBAWA Dashm
33 Yrs/Female
0 Kg/0 Cms
Date: 11-Mar-2022 12:54:59 PM

MPHR: 50% of 187
Speed: 0.0 mph
Grade: 0.0%

KSHIPRA SCANS & LABS
2B COURT CHOURAHA UDAPUR

Raw ECG
BRUCE
(1.0-100)Hz
Ex Time 08:04
BLC : On
Notch : On

Recovery(3:00)
10.0 mm/mV
25 mm/Sec

4X 80 mS Post J

