

CERTIFICATE OF MEDICAL FITNESS

Height: <u>162</u> Cm	Weight: <u>70</u> kg	BMI: <u>26.7</u>	BP: <u>110 / 80</u> mmHg
OPHTHAL CHECK : Right Eye: <u>6/6</u> .		Left Eye: <u>6/6</u> .	Colour vision: <u>⊙</u>

This is to certify that I have conducted the clinical examination
 of Mrs. Rajalakshmi Rengasamy on 13/1/24
 After reviewing the medical history and on clinical examination it has been found that he/she is

- Medically Fit via A
- FIT FOR WORK THOUGH FIT
 Fit with restrictions/recommendations use of Med even. Opn

Though following restrictions have been revealed, in my opinion, these are not impediments to the job.

- 1.....
- 2.....
- 3.....

However the employee should follow the advice/medication that has been communicated to him/her.

Review after _____

- Currently Unfit.
 Review after NIL _____ recommended
- Unfit NIL.


 Dr. _____
 Medical officer
 Apollo clinic(Location)

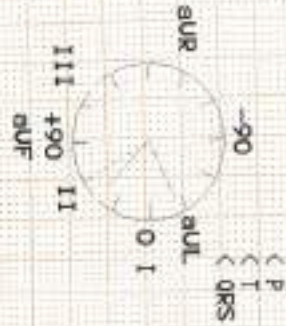This certificate is not meant for medico-legal purposes



Dr. YASODH REDDY
 M.B.B.S., F.sp Diabetology
 CLIN - Cardiology
 Reg. No: 93787
 Apollo Family Physician

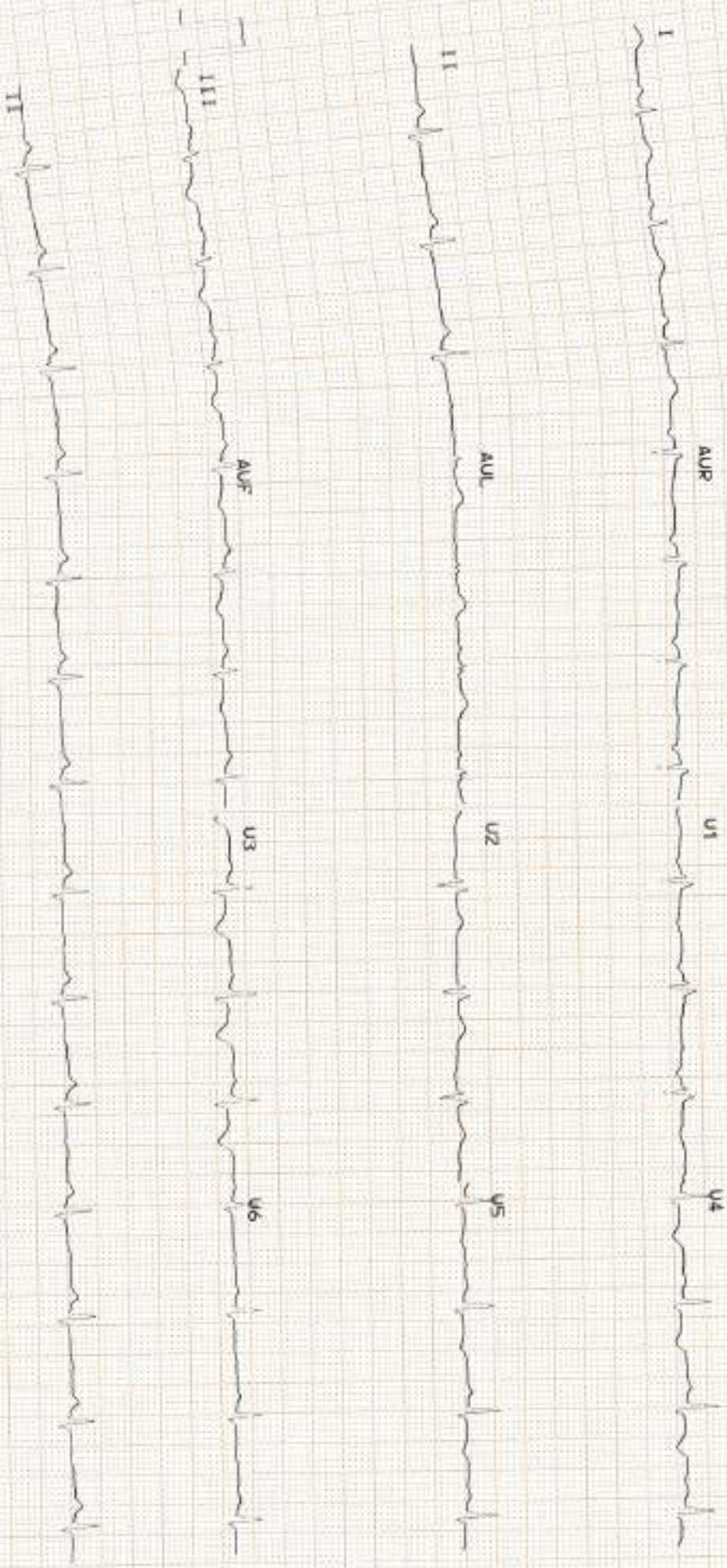
Measurement Results:

RR/PP	706 /	700 ms
P/QRS/T	60 / 45 /	-25 degrees
QT/QTcB	404 /	150 ms
QT/QTcBD	60 /	71 ms
Sokolow		0.8 mV
NK		12



Interpretation:

Unconfirmed report.



GYNAECOLOGY CONSULT

Name: Mrs Rajakshi -	UHID: CVIM. 57410	Date: 13-1-24
Age: 36	Consultant Gynaecologist: Dr. Pawar	

DRUG ALLERGIES

Complaints (related to Gynaec) - NIL SPECIFIC / YES

Known to have Diabetes / Hypertension / IHD / Asthma / Thyroid / Others

Kelelo Hypothyroidism 100mcg 12yrs

Past Medical / Surgical History: *MUD*

Family History :

OTHER SYSTEMS:

GYNAEC HISTORY :

Marital Status - S/M/Others

Children - *Mdx 9yrs*

Deliveries -

L.C.B. -

Abortion -

Contraception -

Periods -

L.M.P. -

Menopause -

*2/2 MUD
LCB - 2yrs
Last - 01/01/24
Rmf.*

Present Medication :

GENERAL EXAMINATION :

Height :

Weight :

BMI :

General Condition :

Blood Pressure:

Thyroid :

Others :

GYNAEC EXAMINATION:

PIA *safe*

S/E

PN

P/R

*on vagina - healthy
cystocele ⊕ / Rectocele ⊕*

PAP SMEAR : Taken / Not Taken (Reason)

OPINION & ADVICE :

Signature with Date & Time :

BREASTS : *sl soft*

REVIEW DETAILS : (with date)
With Patient / With reports only

Name: <i>Mrs. Rajalakshmi, Rengasamy</i>	Date: <i>13/01/2024</i>
Age: <i>36 yrs</i>	UHID No. <i>057410</i>
Sex: <input type="checkbox"/> Male <input checked="" type="checkbox"/> Female	

OPHTHAL FITNESS CERTIFICATE

H/O Thyroid 10/24/23 (treated)

	RE	LE
DV-UCVA :	<i>6/6⁺</i>	<i>6/6⁺ (BE) 6/6</i>
DV-BCVA :		
NEAR VISION :	<i>N₆</i>	<i>N₆</i>
ANTERIOR SEGMENT :		
IOP :		
FIELDS OF VISION :	<i>(N)</i>	<i>(N)</i>
E O M :		
COLOUR VISION :	<i>Normal</i>	<i>Normal</i>
FUNDUS :		
IMPRESSION :		
ADVICE :	<i>fit for work / R/A - 6 months -</i>	

[Signature]
13/1/2024


Established Patient: No

Vitals

Date	Pulse (Beats/min)	B.P (mmHg)	Resp (Rate/min)	Temp (F)	Height (cms)	Weight (Kgs)	Body Fat Percentage (%)	Visceral Fat Level (%)	Body Age (Years)	BMI	Waist Circum (cms)	Hip (cms)	Waist (cms)	Waist & Hip Ratio	User
13-01-2024 13:21	Beats/min	110/80 mmHg	18 Rate/min	98.4 F	162 cms	70.2 Kgs	%	%	Years	26.75	cms	cms	cms		AHLL05400

Your appointment is confirmed

noreply@apolloclinics.info <noreply@apolloclinics.info>



To: customercare@mediwheel.in <customercare@mediwheel.in>

Cc: Velachery Apollo Clinic <velachery@apolloclinics.com> Martin Amalraj [H] <martin.amalraj@apolloclinics.com>

Syamsunder M <syamsunderm@apolloclinics.com>

Dear MRS. RENCASAMY RAJALAKSHMI ..

Greetings from Apollo Clinics.

Your corporate health check appointment is confirmed at **VELACHERY** clinic on 2024-01-13 at **08:15-08:30**

Payment
Vcode

Corporate
Name **ARCOFEMI HEALTHCARE LIMITED**

Agreement
Name **[ARCOFEMI MEDIWHEEL FEMALE AHC CREDIT PAN INDIA OP AGREEMENT]**

Package
Name **[ARCOFEMI - MEDIWHEEL - FULL BODY HEALTH ANNUAL PLUS CHECK - FEMALE - 2D ECHO - PAN INDIA - FY2324]**

"Kindly carry with you relevant documents such as HR issued authorization letter and or appointment confirmation mail and or valid government ID proof and or company ID card and or voucher as per our agreement with your company or sponsor."

Note: Video recording or taking photos inside the clinic premises or during camps is not allowed and would attract legal consequences.

Note: Also once appointment is booked, based on availability of doctors at clinics tests will happen, any pending test will happen based on doctor availability and clinics will be updating the same to customers.

Instructions to be followed for a health check:

1. Please ensure you are on complete fasting for 10-12-Hours prior to check
2. During fasting time do not take any kind of alcohol, cigarettes, tobacco or any other liquids (except Water) in the morning. If any medications taken, pls inform our staff before health check.
3. Please bring all your medical prescriptions and previous health/medical records with you.
4. Kindly inform our staff, if you have a history of diabetes and cardiac problems.

For Women:

1. Pregnant women or those suspecting are advised not to undergo any X-Ray test.

Name: Mrs. RAJALAKSHMI RENGASAMY
Age/Gender: 36 Y/F
Address: a8 204 2nd floor kumar primveera apts sainath nag
Location: PUNE, MAHARASHTRA
Doctor:
Department: GENERAL
Rate Plan: VELACHERY_03122022
Sponsor: ARCOFEMI HEALTHCARE LIMITED
Consulting Doctor: Dr. YASODHA KUMARA REDDY MOKKALA

MR No: CVIM.0000057410
Visit ID: CVELOPV196861
Visit Date: 13-01-2024 08:55
Discharge Date:
Referred By: SELF

HT-CHIEF COMPLAINTS AND PRESENT KNOWN ILLNESS

SYSTEMIC REVIEW

HT-HISTORY

PHYSICAL EXAMINATION

SYSTEMIC EXAMINATION

IMPRESSION

RECOMMENDATION

Doctor's Signature

Established Patient: No

Vitals

Date	Pulse (Beats/min)	B.P (mmHg)	Resp (Rate/min)	Temp (F)	Height (cms)	Weight (Kgs)	Body Fat Percentage (%)	Visceral Fat Level (%)	Body Age (Years)	BMI	Waist Circum (cms)	Hip (cms)	Waist (cms)	Waist & Hip Ratio	User
13-01-2024 13:21	Beats/min	110/80 mmHg	18 Rate/min	98.4 F	162 cms	70.2 Kgs	%	%	Years	26.75	cms	cms	cms		AHLL05400

Established Patient: No

Vitals

Date	Pulse (Beats/min)	B.P (mmHg)	Resp (Rate/min)	Temp (F)	Height (cms)	Weight (Kgs)	Body Fat Percentage (%)	Visceral Fat Level (%)	Body Age (Years)	BMI	Waist Circum (cms)	Hip (cms)	Waist (cms)	Waist & Hip Ratio	User
13-01-2024 13:21	Beats/min	110/80 mmHg	18 Rate/min	98.4 F	162 cms	70.2 Kgs	%	%	Years	26.75	cms	cms	cms		AHLL05400

Established Patient: No

Vitals

Date	Pulse (Beats/min)	B.P (mmHg)	Resp (Rate/min)	Temp (F)	Height (cms)	Weight (Kgs)	Body Fat Percentage (%)	Visceral Fat Level (%)	Body Age (Years)	BMI	Waist Circum (cms)	Hip (cms)	Waist (cms)	Waist & Hip Ratio	User
13-01-2024 13:21	Beats/min	110/80 mmHg	18 Rate/min	98.4 F	162 cms	70.2 Kgs	%	%	Years	26.75	cms	cms	cms		AHLL05400

Name: Mrs. RAJALAKSHMI RENGASAMY
Age/Gender: 36 Y/F
Address: a8 204 2nd floor kumar primveera apts sainath nag
Location: PUNE, MAHARASHTRA
Doctor:
Department: GENERAL
Rate Plan: VELACHERY_03122022
Sponsor: ARCOFEMI HEALTHCARE LIMITED
Consulting Doctor: Dr. V J NIRANJANA BHARATHI

MR No: CVIM.0000057410
Visit ID: CVELOPV196861
Visit Date: 13-01-2024 08:55
Discharge Date:
Referred By: SELF

Doctor's Signature

Established Patient: No

Vitals

Date	Pulse (Beats/min)	B.P (mmHg)	Resp (Rate/min)	Temp (F)	Height (cms)	Weight (Kgs)	Body Fat Percentage (%)	Visceral Fat Level (%)	Body Age (Years)	BMI	Waist Circum (cms)	Hip (cms)	Waist (cms)	Waist & Hip Ratio	User
13-01-2024 13:21	Beats/min	110/80 mmHg	18 Rate/min	98.4 F	162 cms	70.2 Kgs	%	%	Years	26.75	cms	cms	cms		AHLL05400

Patient Name : Mrs. RAJALAKSHMI RENGASAMY Age : 36 Y/F
UHID : CVIM.0000057410 OP Visit No : CVELOPV196861
Conducted By: : Dr. SHANMUGA SUNDARAM D Conducted Date : 13-01-2024 13:32
Referred By : SELF

2D-ECHO WITH COLOUR DOPPLER

Dimensions:

Ao (ed)	2.9 CM
LA (es)	2.9 CM
LVID (ed)	4.3 CM
LVID (es)	2.5 CM
IVS (Ed)	1.1 CM
LVPW (Ed)	1.1 CM
EF	71.00%
%FD	31.00%
MITRAL VALVE :	NORMAL
AML	NORMAL
PML	NORMAL
AORTIC VALVE	NORMAL
TRICUSPID VALVE	NORMAL
RIGHT VENTRICLE	NORMAL
INTER ATRIAL SEPTUM	INTACT
INTER VENTRICULAR SEPTUM	INTACT
AORTA	NORMAL
RIGHT ATRIUM	NORMAL
LEFT ATRIUM	NORMAL
Pulmonary Valve	NORMAL
PERICARDIUM	NORMAL
LEFT VENTRICLE:	

Patient Name	: Mrs. RAJALAKSHMI RENGASAMY	Age	: 36 Y/F
UHID	: CVIM.0000057410	OP Visit No	: CVELOPV196861
Conducted By:	: Dr. SHANMUGA SUNDARAM D	Conducted Date	: 13-01-2024 13:32
Referred By	: SELF		

NO REGIONAL WALL MOTION ABNORMALITY;

COLOUR AND DOPPLER STUDIES

AV max 1.1 m/s; PG 4.5 mmHg;

PV max 1.1 m/s; PG 4.1 mmHg;

MV E 0.8 m/s ; MV A 0.4 m/s;

TV E 0.5 m/s; TV A 0.4 m/s.

Impression;

*NO REGIONAL WALL MOTION ABNORMALITY;

*NORMAL LEFT VENTRICULAR IN SIZE & SYSTOLIC

FUNCTION;

*NO PERICARDIAL EFFUSION/ PULMONARY ARTERY

HYPERTENSION.

Patient Name : Mrs. RAJALAKSHMI RENGASAMY Age : 36 Y/F
UHID : CVIM.0000057410 OP Visit No : CVELOPV196861
Conducted By: : Dr. SHANMUGA SUNDARAM D Conducted Date : 13-01-2024 13:32
Referred By : SELF



DR SHANMUGASUNDARAM
CONSULTANT CARDIOLOGIST

Name: Mrs. RAJALAKSHMI RENGASAMY
Age/Gender: 36 Y/F
Address: a8 204 2nd floor kumar primveera apts sainath nag
Location: PUNE, MAHARASHTRA
Doctor:
Department: GENERAL
Rate Plan: VELACHERY_03122022
Sponsor: ARCOFEMI HEALTHCARE LIMITED
Consulting Doctor: Dr. SHILFA NIGAR N

MR No: CVIM.0000057410
Visit ID: CVELOPV196861
Visit Date: 13-01-2024 08:55
Discharge Date:
Referred By: SELF

HT-CHIEF COMPLAINTS AND PRESENT KNOWN ILLNESS

SYSTEMIC REVIEW

HT-HISTORY

PHYSICAL EXAMINATION

SYSTEMIC EXAMINATION

IMPRESSION

RECOMMENDATION

Doctor's Signature

Name: Mrs. RAJALAKSHMI RENGASAMY
Age/Gender: 36 Y/F
Address: a8 204 2nd floor kumar primveera apts sainath nag
Location: PUNE, MAHARASHTRA
Doctor:
Department: GENERAL
Rate Plan: VELACHERY_03122022
Sponsor: ARCOFEMI HEALTHCARE LIMITED
Consulting Doctor: Dr. YASODHA KUMARA REDDY MOKKALA

MR No: CVIM.0000057410
Visit ID: CVELOPV196861
Visit Date: 13-01-2024 08:55
Discharge Date:
Referred By: SELF

HT-CHIEF COMPLAINTS AND PRESENT KNOWN ILLNESS

SYSTEMIC REVIEW

HT-HISTORY

PHYSICAL EXAMINATION

SYSTEMIC EXAMINATION

IMPRESSION

RECOMMENDATION

Doctor's Signature

Name: Mrs. RAJALAKSHMI RENGASAMY
Age/Gender: 36 Y/F
Address: a8 204 2nd floor kumar primveera apts sainath nag
Location: PUNE, MAHARASHTRA
Doctor:
Department: GENERAL
Rate Plan: VELACHERY_03122022
Sponsor: ARCOFEMI HEALTHCARE LIMITED
Consulting Doctor: Dr. PAVITHRA RAMAKRISHNAN

MR No: CVIM.0000057410
Visit ID: CVELOPV196861
Visit Date: 13-01-2024 08:55
Discharge Date:
Referred By: SELF

HT-CHIEF COMPLAINTS AND PRESENT KNOWN ILLNESS

SYSTEMIC REVIEW

HT-HISTORY

PHYSICAL EXAMINATION

SYSTEMIC EXAMINATION

IMPRESSION

RECOMMENDATION

Doctor's Signature

Patient Name	: Mrs. RAJALAKSHMI RENGASAMY	Age/Gender	: 36 Y/F
UHID/MR No.	: CVIM.0000057410	OP Visit No	: CVELOPV196861
Sample Collected on	:	Reported on	: 13-01-2024 15:24
LRN#	: RAD2207363	Specimen	:
Ref Doctor	: SELF		
Emp/Auth/TPA ID	: 733816334324		

DEPARTMENT OF RADIOLOGY

ULTRASOUND - WHOLE ABDOMEN

Liver is enlarged in size (16.6 cms) with increased echogenicity. No focal lesion is seen. No dilatation of the intrahepatic biliary radicals.

Gall bladder is well distended. No evidence of calculus. Wall thickness appears normal. No evidence of periGB collection. No evidence of focal lesion is seen. PV and CBD normal. Phrygian cap variant.

Spleen appears normal (9.3 cm). No focal lesion seen. Splenic vein appears normal.

Pancreas appears normal in echopattern. No focal/mass lesion/calcification.

No evidence of peripancreatic free fluid or collection. Pancreatic duct appears normal.

Both the kidneys appear normal in size, shape and echopattern. Cortical thickness and CM differentiation are maintained. No calculus / hydronephrosis seen on either side.

Right kidney - 10.3 x 3.8 cms. **Left kidney** - 11.0 x 4.5 cms.

Urinary Bladder is well distended and appears normal. No evidence of any wall thickening or abnormality. No evidence of any intrinsic or extrinsic bladder abnormality detected.

Uterus appears normal in size 7.3 x 3.8 x 3.9 cms. It shows normal shape & echo pattern.

Endometrium appears thickened and measuring 11 mm.

Both ovaries are polycystic.

Right ovary - 3.6 x 2.1 x 3.3 cms. (Vol 16.1 ml)

Left ovary - 3.9 x 2.2 x 3.7 cms. (Vol 17.1 ml)

No evidence of any adnexal pathology noted.

IMPRESSION:-

* **HEPATOMEGALY WITH GRADE I FATTY CHANGES.**

* **BILATERAL POLYCYSTIC OVARIES.**

* **THICKENED ENDOMETRIUM.**

(The sonography findings should always be considered in correlation with the clinical and other investigation finding where applicable.) It is only a professional opinion, Not valid for medico legal purpose.

Patient Name : Mrs. RAJALAKSHMI RENGASAMY

Age/Gender : 36 Y/F



Dr. PASUPULETI SANTOSH KUMAR
M.B.B.S., DNB (RADIODIAGNOSIS)
Radiology

Patient Name : Mrs. RAJALAKSHMI RENGASAMY

Age/Gender : 36 Y/F

UHID/MR No. : CVIM.0000057410

OP Visit No : CVELOPV196861

Sample Collected on :

Reported on : 13-01-2024 16:34

LRN# : RAD2207363

Specimen :

Ref Doctor : SELF

Emp/Auth/TPA ID : 733816334324

DEPARTMENT OF RADIOLOGY

X-RAY CHEST PA

Both lung fields and hila are normal .

No obvious active pleuro-parenchymal lesion seen .

Both costophrenic and cardiophrenic angles are clear .

Both diaphragms are normal in position and contour .

Thoracic wall and soft tissues appear normal.

CONCLUSION :

No obvious abnormality seen



Dr. PASUPULETI SANTOSH KUMAR
M.B.B.S., DNB (RADIODIAGNOSIS)

Radiology

Patient Name	: Mrs. RAJALAKSHMI RENGASAMY	Age/Gender	: 36 Y/F
UHID/MR No.	: CVIM.0000057410	OP Visit No	: CVELOPV196861
Sample Collected on	:	Reported on	: 13-01-2024 15:02
LRN#	: RAD2207363	Specimen	:
Ref Doctor	: SELF		
Emp/Auth/TPA ID	: 733816334324		

DEPARTMENT OF RADIOLOGY

SONO MAMOGRAPHY - SCREENING

RIGHT BREAST

All the four quadrants show normal fibro fatty and glandular tissue echoreflective pattern.

No focal or diffuse lesion can be made out.

Retroareolar portion, Skin and subcutaneous plane appear normal.

Retromammary space appears normal.

Mammary ducts are appearing normal. No abnormal dilatation seen.

No evidence of mass lesions. No evidence of cystic lesions.

Axillary tail region normal. No evidence of lymphadenopathy.

AXILLA:Axillary veins and artery appear normal with normal flow pattern. No abnormal enlarged lymph node can be made out.

LEFT BREAST

All the four quadrants show normal fibro fatty and glandular tissue echoreflective pattern.

Fat globule lesion measuring 0.4 x 0.3 cms in outer quadrant at 5 clock position.

Retroareolar portion, Skin and subcutaneous plane appear normal.

Retromammary space appears normal.

Mammary ducts are appearing normal. No abnormal dilatation seen.

No evidence of mass lesions. No evidence of cystic lesions.

Axillary tail region normal.No evidence of lymphadenopathy.

AXILLA:Axillary veins and artery appear normal with normal flow pattern. No abnormal enlarged lymph node can be made out.

IMPRESSION: * NORMAL STUDY.

Dr. Pavithra

Consultant obstetrics and Gynecology.

Fellowship in sonology.

Fellowship in gynec endoscopy.

Patient Name : Mrs. RAJALAKSHMI RENGASAMY

Age/Gender : 36 Y/F



Dr. PASUPULETI SANTOSH KUMAR
M.B.B.S., DNB (RADIODIAGNOSIS)
Radiology

Patient Name : Mrs.RAJALAKSHMI RENGASAMY	Collected : 13/Jan/2024 09:09AM
Age/Gender : 36 Y 0 M 5 D/F	Received : 13/Jan/2024 01:41PM
UHID/MR No : CVIM.0000057410	Reported : 13/Jan/2024 05:07PM
Visit ID : CVELOPV196861	Status : Final Report
Ref Doctor : Dr.SELF	Sponsor Name : ARCOFEMI HEALTHCARE LIMITED
Emp/Auth/TPA ID : 733816334324	

DEPARTMENT OF HAEMATOLOGY

PERIPHERAL SMEAR , WHOLE BLOOD EDTA

METHODOLOGY	: Microscopic.
RBC MORPHOLOGY	: Predominantly normocytic normochromic RBC's noted.
WBC MORPHOLOGY	: Normal in number, morphology and distribution. No abnormal cells seen.
PLATELETS	: Adequate in number.
PARASITES	: No haemoparasites seen.
IMPRESSION	: Normocytic normochromic blood picture.
NOTE/ COMMENT	: Please correlate clinically.



Dr. MARQUESS RAJ
M.D, DipRCPath, D.N.B(PATH)
Consultant Pathologist

SIN No:BED240009254

This test has been performed at Apollo Health and Lifestyle Ltd., Chennai, Diagnostics Laboratory.



Patient Name : Mrs.RAJALAKSHMI RENGASAMY	Collected : 13/Jan/2024 09:09AM
Age/Gender : 36 Y 0 M 5 D/F	Received : 13/Jan/2024 01:41PM
UHID/MR No : CVIM.0000057410	Reported : 13/Jan/2024 05:07PM
Visit ID : CVELOPV196861	Status : Final Report
Ref Doctor : Dr.SELF	Sponsor Name : ARCOFEMI HEALTHCARE LIMITED
Emp/Auth/TPA ID : 733816334324	

DEPARTMENT OF HAEMATOLOGY

ARCOFEMI - MEDIWHEEL - FULL BODY ANNUAL PLUS CHECK ADVANCED - FEMALE - 2D ECHO - PAN INDIA - FY2324

Test Name	Result	Unit	Bio. Ref. Range	Method
HEMOGRAM , WHOLE BLOOD EDTA				
HAEMOGLOBIN	11.3	g/dL	12-15	Spectrophotometer
PCV	34.00	%	36-46	Electronic pulse & Calculation
RBC COUNT	4.13	Million/cu.mm	3.8-4.8	Electrical Impedance
MCV	82.2	fL	83-101	Calculated
MCH	27.3	pg	27-32	Calculated
MCHC	33.3	g/dL	31.5-34.5	Calculated
R.D.W	13.5	%	11.6-14	Calculated
TOTAL LEUCOCYTE COUNT (TLC)	8,600	cells/cu.mm	4000-10000	Electrical Impedance
DIFFERENTIAL LEUCOCYTIC COUNT (DLC)				
NEUTROPHILS	57.7	%	40-80	Electrical Impedance
LYMPHOCYTES	30.1	%	20-40	Electrical Impedance
EOSINOPHILS	5.4	%	1-6	Electrical Impedance
MONOCYTES	5.8	%	2-10	Electrical Impedance
BASOPHILS	1.0	%	<1-2	Electrical Impedance
ABSOLUTE LEUCOCYTE COUNT				
NEUTROPHILS	4962.2	Cells/cu.mm	2000-7000	Calculated
LYMPHOCYTES	2588.6	Cells/cu.mm	1000-3000	Calculated
EOSINOPHILS	464.4	Cells/cu.mm	20-500	Calculated
MONOCYTES	498.8	Cells/cu.mm	200-1000	Calculated
BASOPHILS	86	Cells/cu.mm	0-100	Calculated
PLATELET COUNT	308000	cells/cu.mm	150000-410000	Electrical impedance
ERYTHROCYTE SEDIMENTATION RATE (ESR)	40	mm at the end of 1 hour	0-20	Modified Westergren
PERIPHERAL SMEAR				

METHODOLOGY : Microscopic.

RBC MORPHOLOGY : Predominantly normocytic normochromic RBC's noted.



Dr.MARQUESS RAJ
M.D,DipRCPATH,D.N.B(PATH)
Consultant Pathologist

SIN No:BED240009254

This test has been performed at Apollo Health and Lifestyle Ltd - Chennai, Diagnostics Laboratory.



Patient Name : Mrs.RAJALAKSHMI RENGASAMY	Collected : 13/Jan/2024 09:09AM
Age/Gender : 36 Y 0 M 5 D/F	Received : 13/Jan/2024 01:41PM
UHID/MR No : CVIM.0000057410	Reported : 13/Jan/2024 05:07PM
Visit ID : CVELOPV196861	Status : Final Report
Ref Doctor : Dr.SELF	Sponsor Name : ARCOFEMI HEALTHCARE LIMITED
Emp/Auth/TPA ID : 733816334324	

DEPARTMENT OF HAEMATOLOGY

ARCOFEMI - MEDIWHEEL - FULL BODY ANNUAL PLUS CHECK ADVANCED - FEMALE - 2D ECHO - PAN INDIA - FY2324

WBC MORPHOLOGY : Normal in number, morphology and distribution. No abnormal cells seen.

PLATELETS : Adequate in number.

PARASITES : No haemoparasites seen.

IMPRESSION : Normocytic normochromic blood picture.

NOTE/ COMMENT : Please correlate clinically.



Dr. MARQUESS RAJ
M.D, DipRCPATH, D.N.B(PATH)
Consultant Pathologist

SIN No:BED240009254

This test has been performed at Apollo Health and Lifestyle Ltd., Chennai, Diagnostics Laboratory.




Patient Name : Mrs.RAJALAKSHMI RENGASAMY	Collected : 13/Jan/2024 09:09AM
Age/Gender : 36 Y 0 M 5 D/F	Received : 13/Jan/2024 01:41PM
UHID/MR No : CVIM.0000057410	Reported : 13/Jan/2024 07:33PM
Visit ID : CVELOPV196861	Status : Final Report
Ref Doctor : Dr.SELF	Sponsor Name : ARCOFEMI HEALTHCARE LIMITED
Emp/Auth/TPA ID : 733816334324	

DEPARTMENT OF HAEMATOLOGY

ARCOFEMI - MEDIWHEEL - FULL BODY ANNUAL PLUS CHECK ADVANCED - FEMALE - 2D ECHO - PAN INDIA - FY2324

Test Name	Result	Unit	Bio. Ref. Range	Method
BLOOD GROUP ABO AND RH FACTOR , WHOLE BLOOD EDTA				
BLOOD GROUP TYPE	A			Microplate Hemagglutination
Rh TYPE	Positive			Microplate Hemagglutination

PLEASE NOTE THIS SAMPLE HAS BEEN TESTED ONLY FOR ABO MAJOR GROUPING AND ANTI D ONLY



Dr THILAGA
M.B.B.S,M.D(Pathology)
Consultant Pathologist

SIN No:BED240009254

This test has been performed at Apollo Health and Lifestyle Ltd - Chennai, Diagnostics Laboratory.

This test has been performed at Apollo Health and Lifestyle Ltd - RRL ASHOK NAGAR

Apollo Health and Lifestyle Limited (CIN - U85110TG2006PLC115819)
Regd. Office: 1-11-60/52, Ashoka Baghupathi Chambers, 5th Floor, Begumpet, Hyderabad, Telangana - 500 018 |
www.apollohli.com | Email ID: enquiry@apollohli.com, Ph No: 844-8904 7272, Fax No: 8854 7244

ADDRESS:
B No.70, F - Block, 2nd Avenue, Ashok Nagar ERM, Chennai 600 102,
Phone - 844 2628004 / 95


1860 500 7788
www.apolloclinic.com

APOLLO CLINICS NETWORK

Telangana: Hyderabad | AS Ashok Nagar | Chandu Nagar | Kothapuri | Walibanda | Nizampet | Marikonda | Uppal | Analka Pradesh | Vijay (Sethurama Prasad) Karnataka: Bangalore (Kannanagalli) | Bellandur | Electronic City | Frazer Town | HSR Layout | Indira Nagar | JP Nagar | Koramangala | Sarjapur Road. Mysore (VV Bellur) Tamil Nadu: Chennai | Anna Nagar | Kottapattinam | Mogappair | T Nagar | Velamannaikam | Velachery | Mahabalipuram. Pune (Aundh) | Pimpri Chinchwad. Uttar Pradesh: Ghaziabad (Indraprastha) Gujarat: Ahmedabad (Satellite) Punjab: Amritsar (Canton Road) Haripur | Faridkot (Railway Station Road)



Patient Name : Mrs.RAJALAKSHMI RENGASAMY	Collected : 13/Jan/2024 09:10AM
Age/Gender : 36 Y 0 M 5 D/F	Received : 13/Jan/2024 04:46PM
UHID/MR No : CVIM.0000057410	Reported : 13/Jan/2024 05:18PM
Visit ID : CVELOPV196861	Status : Final Report
Ref Doctor : Dr.SELF	Sponsor Name : ARCOFEMI HEALTHCARE LIMITED
Emp/Auth/TPA ID : 733816334324	

DEPARTMENT OF BIOCHEMISTRY

ARCOFEMI - MEDIWHEEL - FULL BODY ANNUAL PLUS CHECK ADVANCED - FEMALE - 2D ECHO - PAN INDIA - FY2324

Test Name	Result	Unit	Bio. Ref. Range	Method
GLUCOSE, FASTING , NAF PLASMA	88	mg/dL	70-100	HEXOKINASE

Comment:

As per American Diabetes Guidelines, 2023

Fasting Glucose Values in mg/dL	Interpretation
70-100 mg/dL	Normal
100-125 mg/dL	Prediabetes
≥126 mg/dL	Diabetes
<70 mg/dL	Hypoglycemia

Note:

- The diagnosis of Diabetes requires a fasting plasma glucose of $>$ or $=$ 126 mg/dL and/or a random / 2 hr post glucose value of $>$ or $=$ 200 mg/dL on at least 2 occasions.
- Very high glucose levels ($>$ 450 mg/dL in adults) may result in Diabetic Ketoacidosis & is considered critical.

Test Name	Result	Unit	Bio. Ref. Range	Method
GLUCOSE, POST PRANDIAL (PP), 2 HOURS , SODIUM FLUORIDE PLASMA (2 HR)	91	mg/dL	70-140	HEXOKINASE

Comment:

It is recommended that FBS and PPBS should be interpreted with respect to their Biological reference ranges and not with each other.

Conditions which may lead to lower postprandial glucose levels as compared to fasting glucose levels may be due to reactive hypoglycemia, dietary meal content, duration or timing of sampling after food digestion and absorption, medications such as insulin preparations, sulfonylureas, amylin analogues, or conditions such as overproduction of insulin.



DR. R. SRIVATSAN
M.D.(Biochemistry)



SIN No:PLP1407956

This test has been performed at Apollo Health and Lifestyle Ltd - Chennai, Diagnostics Laboratory.

This test has been performed at Apollo Health and Lifestyle Ltd - RRL ASHOK NAGAR

Apollo Health and Lifestyle Limited (CIN - U85110TG2006PLC115819)
Regd. Office: 1-19-60/52, Ashoka Baghupathi Chambers, 5th Floor, Begumpet, Hyderabad, Telangana - 500 018 |
www.apolloh.com | Email ID:enquiry@apolloh.com, Ph No: 844-8904 7272, Fax No: 8864 7244

ADDRESS:
B No.70, F - Block, 2nd Avenue, Ashok Nagar ERM, Chennai 600 102,
Phone - 844 2628004 / 95

1860 500 7788
www.apolloclinic.com

APOLLO CLINICS NETWORK
Telangana: Hyderabad | AS Rao Nagar | Chandu Nagar | Kothapuri | Malibanda | Nizampet | Marikonda | Uppal | Andhra Pradesh: Vijay (Sethurama Prasad) | Karnataka: Bangalore (Kannuragalli) | Kerala: Thiruvananthapuram | Electronics City | Feroz Khan | HSR Layout | Indira Nagar | JP Nagar | Karamcheddi | Koramangala | Sarjapur Road | Mysore (VV Bellur) | Tamil Nadu: Chennai | Anna Nagar | Kottapattinam | Mogappair | T Nagar | Velamannaikam | Velachery | Maharashtra: Pune (Aundh) | Higd Pradhikaran | Viman Nagar | Warananthi | Uttar Pradesh: Ghaziabad (Indraprastha) | Gujarat: Ahmedabad (Satellite) | Punjab: Amritsar (Canton Road) | Haryana: Faridkot (Railway Station Road)

Patient Name : Mrs.RAJALAKSHMI RENGASAMY	Collected : 13/Jan/2024 09:09AM
Age/Gender : 36 Y 0 M 5 D/F	Received : 13/Jan/2024 01:42PM
UHID/MR No : CVIM.0000057410	Reported : 13/Jan/2024 03:23PM
Visit ID : CVELOPV196861	Status : Final Report
Ref Doctor : Dr.SELF	Sponsor Name : ARCOFEMI HEALTHCARE LIMITED
Emp/Auth/TPA ID : 733816334324	

DEPARTMENT OF BIOCHEMISTRY

ARCOFEMI - MEDIWHEEL - FULL BODY ANNUAL PLUS CHECK ADVANCED - FEMALE - 2D ECHO - PAN INDIA - FY2324

Test Name	Result	Unit	Bio. Ref. Range	Method
HBA1C (GLYCATED HEMOGLOBIN) , WHOLE BLOOD EDTA				
HBA1C, GLYCATED HEMOGLOBIN	5.5	%		HPLC
ESTIMATED AVERAGE GLUCOSE (eAG)	111	mg/dL		Calculated

Comment:

Reference Range as per American Diabetes Association (ADA) 2023 Guidelines:

REFERENCE GROUP	HBA1C %
NON DIABETIC	<5.7
PREDIABETES	5.7 – 6.4
DIABETES	≥ 6.5
DIABETICS	
EXCELLENT CONTROL	6 – 7
FAIR TO GOOD CONTROL	7 – 8
UNSATISFACTORY CONTROL	8 – 10
POOR CONTROL	>10

Note: Dietary preparation or fasting is not required.

- HbA1C is recommended by American Diabetes Association for Diagnosing Diabetes and monitoring Glycemic Control by American Diabetes Association guidelines 2023.
- Trends in HbA1C values is a better indicator of Glycemic control than a single test.
- Low HbA1C in Non-Diabetic patients are associated with Anemia (Iron Deficiency/Hemolytic), Liver Disorders, Chronic Kidney Disease. Clinical Correlation is advised in interpretation of low Values.
- Falsely low HbA1c (below 4%) may be observed in patients with clinical conditions that shorten erythrocyte life span or decrease mean erythrocyte age. HbA1c may not accurately reflect glycemic control when clinical conditions that affect erythrocyte survival are present.
- In cases of Interference of Hemoglobin variants in HbA1C, alternative methods (Fructosamine) estimation is recommended for Glycemic Control
 - A: HbF >25%
 - B: Homozygous Hemoglobinopathy.
 (Hb Electrophoresis is recommended method for detection of Hemoglobinopathy)



DR. R. SRIVATSAN
M.D.(Biochemistry)



SIN No:EDT240003921

This test has been performed at Apollo Health and Lifestyle Ltd - Chennai, Diagnostics Laboratory.

This test has been performed at Apollo Health and Lifestyle Ltd - RRL ASHOK NAGAR

Apollo Health and Lifestyle Limited (CIN - U85110TG2006PLC115819)
 Regd. Office: 1-19-00/52, Ashoka Baghupathi Chambers, 5th Floor, Begumpet, Hyderabad, Telangana - 500 018 |
 www.apolloh.com | Email ID: enquiry@apolloh.com, Ph No: 040-4904 7272, Fax No: 4864 7244

ADDRESS:
 B No.70, F - Block, 2nd Avenue, Ashok Nagar ERM, Chennai 600 032.
 Phone - 044-2622804-05

1860 500 7788
 www.apolloclinic.com

APOLLO CLINICS NETWORK
 Telangana: Hyderabad | AS Pao Nagar | Charandi Nagar | Koodapuri | Walibanda | Nizampet | Marikonda | Uppal | Analka Pradesh | Vidyut (Senthanna Peta) Karnataka: Bangalore (Kannanagalli) | Bellandur | Electronic City | Frazer Town | HSR Layout | Indira Nagar | JP Nagar | Koramangala | Koramangala | Sarjapur Road. Mysore (VV Bellur) Tamil Nadu: Chennai | Anna Nagar | Kottapattinam | Mogappair | T Nagar | Velamannaikam | Velachery | Mahabalipuram (Aurthi) | Nigdi Pradhikaran | Vinnar Nagar | Warconeri Uttar Pradesh: Ghaziabad (Indraprastha) Gujarat: Ahmedabad (Satellite) Punjab: Amritsar (Court Road) Haridwar: Faridabad (Railway Station Road)

Patient Name : Mrs.RAJALAKSHMI RENGASAMY	Collected : 13/Jan/2024 09:10AM
Age/Gender : 36 Y 0 M 5 D/F	Received : 13/Jan/2024 01:36PM
UHID/MR No : CVIM.0000057410	Reported : 13/Jan/2024 03:01PM
Visit ID : CVELOPV196861	Status : Final Report
Ref Doctor : Dr.SELF	Sponsor Name : ARCOFEMI HEALTHCARE LIMITED
Emp/Auth/TPA ID : 733816334324	

DEPARTMENT OF BIOCHEMISTRY

ARCOFEMI - MEDIWHEEL - FULL BODY ANNUAL PLUS CHECK ADVANCED - FEMALE - 2D ECHO - PAN INDIA - FY2324


Test Name	Result	Unit	Bio. Ref. Range	Method
LIPID PROFILE , SERUM				
TOTAL CHOLESTEROL	244	mg/dL	<200	CHO-POD
TRIGLYCERIDES	147	mg/dL	<150	GPO-POD
HDL CHOLESTEROL	58	mg/dL	40-60	Enzymatic Immunoinhibition
NON-HDL CHOLESTEROL	186	mg/dL	<130	Calculated
LDL CHOLESTEROL	156.6	mg/dL	<100	Calculated
VLDL CHOLESTEROL	29.4	mg/dL	<30	Calculated
CHOL / HDL RATIO	4.21		0-4.97	Calculated

Comment:

Reference Interval as per National Cholesterol Education Program (NCEP) Adult Treatment Panel III Report.

	Desirable	Borderline High	High	Very High
TOTAL CHOLESTEROL	< 200	200 - 239	≥ 240	
TRIGLYCERIDES	<150	150 - 199	200 - 499	≥ 500
LDL	Optimal < 100 Near Optimal 100-129	130 - 159	160 - 189	≥ 190
HDL	≥ 60			
NON-HDL CHOLESTEROL	Optimal <130; Above Optimal 130-159	160-189	190-219	>220

1. Measurements in the same patient on different days can show physiological and analytical variations.
2. NCEP ATP III identifies non-HDL cholesterol as a secondary target of therapy in persons with high triglycerides.
3. Primary prevention algorithm now includes absolute risk estimation and lower LDL Cholesterol target levels to determine eligibility of drug therapy.
4. Low HDL levels are associated with Coronary Heart Disease due to insufficient HDL being available to participate in reverse cholesterol transport, the process by which cholesterol is eliminated from peripheral tissues.
5. As per NCEP guidelines, all adults above the age of 20 years should be screened for lipid status. Selective screening of children above the age of 2 years with a family history of premature cardiovascular disease or those with at least one parent with high total cholesterol is recommended.
6. VLDL, LDL Cholesterol Non HDL Cholesterol, CHOL/HDL RATIO, LDL/HDL RATIO are calculated parameters when Triglycerides are below 350mg/dl. When Triglycerides are more than 350 mg/dl LDL cholesterol is a direct measurement.



DR. R. SRIVATSAN
M.D.(Biochemistry)



SIN No:SE04599822

This test has been performed at Apollo Health and Lifestyle Ltd - Chennai, Diagnostics Laboratory.

This test has been performed at Apollo Health and Lifestyle Ltd - RRL ASHOK NAGAR

Apollo Health and Lifestyle Limited | CHN - UBS1107G200(PLC)1158119
 Regd. Office: 1-11-60/52, Ashoka Baghupathi Chambers, 5th Floor, Begumpet, Hyderabad, Telangana - 500 018 |
 www.apolloh.com | Email ID: enquiry@apolloh.com, Ph No: 040-4904 7272, Fax No: 4864 7244

ADDRESS:
 B No.70, F - Block, 2nd Avenue, Ashok Nagar East, Chennai 600 192,
 Phone - 044-2622804/05

1860 500 7788
 www.apolloclinic.com

APOLLO CLINICS NETWORK
 Telangana: Hyderabad | AS Rao Nagar | Charani Nagar | Koodigar | Malibanda | Nizampet | Marikonda | Uppal | Andhra Pradesh: Vijay (Sethurama Prasad) | Karnataka: Bangalore (Kannanagalli) | Kerala: Electronic City | Frisco Town | HSR Layout | India
 Nagar | JP Nagar | Kanchi | Karimnagar | Sarajpur Road | Mysore (VV Bellur) | Tamil Nadu: Chennai | Ansanagar | Kottapattinam | Mogappair | T Nagar | Yelamanchili | Kerala: Velachery | Maharashtra: Pune (Aundh) | Higd Pradhikaran | Viman Nagar | Warananthi
 Uttar Pradesh: Ghaziabad (Indraprastha) | Gujarat: Ahmedabad (Satellite) | Punjab: Amritsar (Civil Road) | Harappa | Faridkot (Railway Station Road)

Patient Name : Mrs.RAJALAKSHMI RENGASAMY	Collected : 13/Jan/2024 09:10AM
Age/Gender : 36 Y 0 M 5 D/F	Received : 13/Jan/2024 01:36PM
UHID/MR No : CVIM.0000057410	Reported : 13/Jan/2024 03:01PM
Visit ID : CVELOPV196861	Status : Final Report
Ref Doctor : Dr.SELF	Sponsor Name : ARCOFEMI HEALTHCARE LIMITED
Emp/Auth/TPA ID : 733816334324	

DEPARTMENT OF BIOCHEMISTRY

ARCOFEMI - MEDIWHEEL - FULL BODY ANNUAL PLUS CHECK ADVANCED - FEMALE - 2D ECHO - PAN INDIA - FY2324

Test Name	Result	Unit	Bio. Ref. Range	Method
LIVER FUNCTION TEST (LFT) , SERUM				
BILIRUBIN, TOTAL	0.74	mg/dL	0.3-1.2	DPD
BILIRUBIN CONJUGATED (DIRECT)	0.12	mg/dL	<0.2	DPD
BILIRUBIN (INDIRECT)	0.62	mg/dL	0.0-1.1	Dual Wavelength
ALANINE AMINOTRANSFERASE (ALT/SGPT)	18	U/L	<35	IFCC
ASPARTATE AMINOTRANSFERASE (AST/SGOT)	19.0	U/L	<35	IFCC
ALKALINE PHOSPHATASE	52.00	U/L	30-120	IFCC
PROTEIN, TOTAL	8.10	g/dL	6.6-8.3	Biuret
ALBUMIN	4.40	g/dL	3.5-5.2	BROMO CRESOL GREEN
GLOBULIN	3.70	g/dL	2.0-3.5	Calculated
A/G RATIO	1.19		0.9-2.0	Calculated

Comment:

LFT results reflect different aspects of the health of the liver, i.e., hepatocyte integrity (AST & ALT), synthesis and secretion of bile (Bilirubin, ALP), cholestasis (ALP, GGT), protein synthesis (Albumin)

Common patterns seen:

1. Hepatocellular Injury:

- AST – Elevated levels can be seen. However, it is not specific to liver and can be raised in cardiac and skeletal injuries.
- ALT – Elevated levels indicate hepatocellular damage. It is considered to be most specific lab test for hepatocellular injury. Values also correlate well with increasing BMI.
- Disproportionate increase in AST, ALT compared with ALP.
- Bilirubin may be elevated.
- AST: ALT (ratio) – In case of hepatocellular injury AST: ALT > 1 In Alcoholic Liver Disease AST: ALT usually >2. This ratio is also seen to be increased in NAFLD, Wilson's diseases, Cirrhosis, but the increase is usually not >2.

2. Cholestatic Pattern:

- ALP – Disproportionate increase in ALP compared with AST, ALT.
- Bilirubin may be elevated.
- ALP elevation also seen in pregnancy, impacted by age and sex.
- To establish the hepatic origin correlation with GGT helps. If GGT elevated indicates hepatic cause of increased ALP.

3. Synthetic function impairment:

- Albumin- Liver disease reduces albumin levels.
- Correlation with PT (Prothrombin Time) helps.



DR. R. SRIVATSAN
M.D.(Biochemistry)



SIN No:SE04599822

This test has been performed at Apollo Health and Lifestyle Ltd - Chennai, Diagnostics Laboratory.

This test has been performed at Apollo Health and Lifestyle Ltd - RRL ASHOK NAGAR

Apollo Health and Lifestyle Limited (CIN - U85110TG2006PLC115819)
Regd. Office: 1-19-60/52, Ashoka Baghupatti Chambers, 5th Floor, Begumpet, Hyderabad, Telangana - 500 018 |
www.apolloh.com | Email ID: enquiry@apolloh.com, Ph No: 040-4904 7272, Fax No: 4864 7244

ADDRESS:
B No.70, F - Block, 2nd Avenue, Ashok Nagar East, Chennai-600 192.
Phone - 044-2622804-05

1860 500 7788
www.apolloclinic.com

APOLLO CLINICS NETWORK
Telangana: Hyderabad | AS Rao Nagar | Charandi Nagar | Koodigar | Walibanda | Nizampet | Marikonda | Uppal | Anaparthi | Pradiwadi | Madag (Sethurama Pet) | Karnataka: Bangalore (Koramangala) | Bengaluru | Electronic City | Frisco Town | HSR Layout | Indira Nagar | JP Nagar | Koralahalli | Koramangala | Sarjapur Road | Mysore (VV Bellur) | Tamil Nadu: Chennai | Anna Nagar | Kottapattinam | Mogappair | T Nagar | Velamannaikam | Velachery | Maharashtra: Pune (Aundh) | Higd Pradhikaran | Viman Nagar | Warananthi | Uttar Pradesh: Ghaziabad (Indraprastha) | Gujarat: Ahmedabad (Satellite) | Punjab: Amritsar (Civil Road) | Haridwar: Faridabad (Railway Station Road)

Patient Name	: Mrs.RAJALAKSHMI RENGASAMY	Collected	: 13/Jan/2024 09:10AM
Age/Gender	: 36 Y 0 M 5 D/F	Received	: 13/Jan/2024 01:36PM
UHID/MR No	: CVIM.0000057410	Reported	: 13/Jan/2024 03:01PM
Visit ID	: CVELOPV196861	Status	: Final Report
Ref Doctor	: Dr.SELF	Sponsor Name	: ARCOFEMI HEALTHCARE LIMITED
Emp/Auth/TPA ID	: 733816334324		

DEPARTMENT OF BIOCHEMISTRY

ARCOFEMI - MEDIWHEEL - FULL BODY ANNUAL PLUS CHECK ADVANCED - FEMALE - 2D ECHO - PAN INDIA - FY2324



DR. R. SRIVATSAN
M.D.(Biochemistry)



SIN No:SE04599822

This test has been performed at Apollo Health and Lifestyle Ltd - Chennai, Diagnostics Laboratory.

This test has been performed at Apollo Health and Lifestyle Ltd - RRL ASHOK NAGAR

Apollo Health and Lifestyle Limited (CIN - U85110TG2006PLC115819)

Regd. Office: 1-10-00/52, Ashoka Baghupathi Chambers, 5th Floor, Begumpet, Hyderabad, Telangana - 500 018 |
www.apollohli.com | Email ID: enquiry@apollohli.com, Ph No: 040-4904 7272, Fax No: 0404 7244

ADDRESS:
B No.70, F - Block, 2nd Avenue, Ashok Nagar ERM, Chennai 600 102,
Phone - 044-2624804 / 95

 **1860 500 7788**
www.apolloclinic.com

APOLLO CLINICS NETWORK

Telangana: Hyderabad | AS Pao Nagar | Charadi Nagar | Koostapur | Walibanda | Nizampet | Marikonda | Uppal | Analka Pradesh | Vijay (Sethurama Prasad) Karnataka: Bangalore (Kannanagalli) | Bellandur | Electronic City | Frazer Town | HSR Layout | Indira Nagar | JP Nagar | Kandralehalli | Koramangala | Sarjapur Road. Mysore (VV Bellur) Tamil Nadu: Chennai | Anna Nagar | Kottapattinam | Mogappair | T Nagar | Velamannaikam | Velachery | Mahabalipuram. Andhra Pradesh: Rajahmundry | Rajamahendravaram | Rajampet | Rajamahendravaram (Satellite) Punjab: Amritsar | Canal Road Harjinder. Kerala: Fortified (Railway Station Road)

Patient Name : Mrs.RAJALAKSHMI RENGASAMY	Collected : 13/Jan/2024 09:10AM
Age/Gender : 36 Y 0 M 5 D/F	Received : 13/Jan/2024 01:36PM
UHID/MR No : CVIM.0000057410	Reported : 13/Jan/2024 03:01PM
Visit ID : CVELOPV196861	Status : Final Report
Ref Doctor : Dr.SELF	Sponsor Name : ARCOFEMI HEALTHCARE LIMITED
Emp/Auth/TPA ID : 733816334324	

DEPARTMENT OF BIOCHEMISTRY

ARCOFEMI - MEDIWHEEL - FULL BODY ANNUAL PLUS CHECK ADVANCED - FEMALE - 2D ECHO - PAN INDIA - FY2324

Test Name	Result	Unit	Bio. Ref. Range	Method
RENAL PROFILE/KIDNEY FUNCTION TEST (RFT/KFT) , SERUM				
CREATININE	0.58	mg/dL	0.72 – 1.18	JAFFE METHOD
UREA	14.00	mg/dL	17-43	GLDH, Kinetic Assay
BLOOD UREA NITROGEN	6.5	mg/dL	8.0 - 23.0	Calculated
URIC ACID	3.80	mg/dL	2.6-6.0	Uricase PAP
CALCIUM	9.20	mg/dL	8.8-10.6	Arsenazo III
PHOSPHORUS, INORGANIC	3.30	mg/dL	2.5-4.5	Phosphomolybdate Complex
SODIUM	134	mmol/L	136–146	ISE (Indirect)
POTASSIUM	4.5	mmol/L	3.5–5.1	ISE (Indirect)
CHLORIDE	105	mmol/L	101–109	ISE (Indirect)



DR. R. SRIVATSAN
M.D.(Biochemistry)



SIN No:SE04599822

This test has been performed at Apollo Health and Lifestyle Ltd - Chennai, Diagnostics Laboratory.

This test has been performed at Apollo Health and Lifestyle Ltd - RRL ASHOK NAGAR

Apollo Health and Lifestyle Limited (DN - UBS110TG2000PLC115819)

Regd. Office: 1-11-60/52, Ashoka Baghupathi Chambers, 5th Floor, Begumpet, Hyderabad, Telangana - 500 018 |
www.apollohli.com | Email ID: enquiry@apollohli.com, Ph No: 844-4904 7272, Fax No: 8864 7244

ADDRESS:
B No.70, F - Block, 2nd Avenue, Ashok Nagar ERM, Chennai 600 102,
Phone - 844 2628004 / 95

1860 500 7788
www.apolloclinic.com

APOLLO CLINICS NETWORK

Telangana: Hyderabad | AS Pao Nagar | Chandu Nagar | Koodapur | Walibanda | Nizampet | Manikonda | Ujjal | Analka Pradesh | Vijay (Sethurama Peta) Karnataka: Bangalore (Kausarbagh) | Belgaum | Electronic City | Frisco Town | HSR Layout | Indira Nagar | JP Nagar | Karamchahalli | Koramangala | Sarjapur Road. Mysore (VV Bellur) Tamil Nadu: Chennai | Anna Nagar | Kottapattinam | Mogappair | T Nagar | Velamannaikam | Velachery | Mahanagar. Pune (Aundh) | Nigdi Pradhikaran | Viman Nagar | Warananthi Uttar Pradesh: Ghaziabad (Indraprastha) Gujarat: Ahmedabad (Satellite) Punjab: Amritsar (Convent Road) Harjpur, Faridkot (Railway Station Road)

Patient Name : Mrs.RAJALAKSHMI RENGASAMY	Collected : 13/Jan/2024 09:10AM
Age/Gender : 36 Y 0 M 5 D/F	Received : 13/Jan/2024 01:36PM
UHID/MR No : CVIM.0000057410	Reported : 13/Jan/2024 02:44PM
Visit ID : CVELOPV196861	Status : Final Report
Ref Doctor : Dr.SELF	Sponsor Name : ARCOFEMI HEALTHCARE LIMITED
Emp/Auth/TPA ID : 733816334324	

DEPARTMENT OF BIOCHEMISTRY

ARCOFEMI - MEDIWHEEL - FULL BODY ANNUAL PLUS CHECK ADVANCED - FEMALE - 2D ECHO - PAN INDIA - FY2324

Test Name	Result	Unit	Bio. Ref. Range	Method
GAMMA GLUTAMYL TRANSPEPTIDASE (GGT) , SERUM	22.00	U/L	<38	IFCC



DR. R. SRIVATSAN
M.D.(Biochemistry)



SIN No:SE04599822

This test has been performed at Apollo Health and Lifestyle Ltd - Chennai, Diagnostics Laboratory.

This test has been performed at Apollo Health and Lifestyle Ltd - RRL ASHOK NAGAR

Apollo Health and Lifestyle Limited (CIN - U85110TG2006PLC115819)
 Regd. Office: 1-10-60/52, Ashoka Baghupatti Chambers, 5th Floor, Begumpet, Hyderabad, Telangana - 500 018 |
 www.apollohsl.com | Email ID: enquiry@apollohsl.com, Ph No: 844-4904 7777, Fax No: 8854 7244

ADDRESS:
 B No.70, F - Block, 2nd Avenue, Ashok Nagar ERM, Chennai 600 032,
 Phone - 844 3624804 / 95

 **1860 500 7788**
 www.apolloclinic.com

APOLLO CLINICS NETWORK
 Telangana: Hyderabad | AS Pao Nagar | Charadi Nagar | Kothapuri | Malibundra | Nizampet | Marikonda | Uppal | Andhra Pradesh: Vijay (Sethurama Prasad) | Karnataka: Bangalore (Kannuragudi) | Kerala: Electronic City | Frisco Town | HSR Layout | Indira Nagar | JP Nagar | Karambala | Koramangala | Sarjapur Road | Mysore (VV Bellur) | Tamil Nadu: Chennai | Anna Nagar | Kottapattinam | Mogappair | T Nagar | Velamannaikam | Velachery | Maharashtra: Pune (Aundh) | Higd Pradhikaran | Viman Nagar | Warananthi | Uttar Pradesh: Ghaziabad (Indraprastha) | Gujarat: Ahmedabad (Satellite) | Punjab: Amritsar (Cantt Road) | Haryana: Faridabad (Railway Station Road)

Patient Name : Mrs.RAJALAKSHMI RENGASAMY	Collected : 13/Jan/2024 09:10AM
Age/Gender : 36 Y 0 M 5 D/F	Received : 13/Jan/2024 01:38PM
UHID/MR No : CVIM.0000057410	Reported : 13/Jan/2024 07:44PM
Visit ID : CVELOPV196861	Status : Final Report
Ref Doctor : Dr.SELF	Sponsor Name : ARCOFEMI HEALTHCARE LIMITED
Emp/Auth/TPA ID : 733816334324	

DEPARTMENT OF IMMUNOLOGY

ARCOFEMI - MEDIWHEEL - FULL BODY ANNUAL PLUS CHECK ADVANCED - FEMALE - 2D ECHO - PAN INDIA - FY2324

Test Name	Result	Unit	Bio. Ref. Range	Method
THYROID PROFILE TOTAL (T3, T4, TSH) , SERUM				
TRI-IODOTHYRONINE (T3, TOTAL)	1.07	ng/mL	0.7-2.04	CLIA
THYROXINE (T4, TOTAL)	11.00	µg/dL	5.48-14.28	CLIA
THYROID STIMULATING HORMONE (TSH)	18.660	µIU/mL	0.34-5.60	CLIA

Result is rechecked. Kindly correlate clinically

Comment:

For pregnant females	Bio Ref Range for TSH in uIU/ml (As per American Thyroid Association)
First trimester	0.1 - 2.5
Second trimester	0.2 - 3.0
Third trimester	0.3 - 3.0

- TSH is a glycoprotein hormone secreted by the anterior pituitary. TSH activates production of T3 (Triiodothyronine) and its prohormone T4 (Thyroxine). Increased blood level of T3 and T4 inhibit production of TSH.
- TSH is elevated in primary hypothyroidism and will be low in primary hyperthyroidism. Elevated or low TSH in the context of normal free thyroxine is often referred to as sub-clinical hypo- or hyperthyroidism respectively.
- Both T4 & T3 provides limited clinical information as both are highly bound to proteins in circulation and reflects mostly inactive hormone. Only a very small fraction of circulating hormone is free and biologically active.
- Significant variations in TSH can occur with circadian rhythm, hormonal status, stress, sleep deprivation, medication & circulating antibodies.

TSH	T3	T4	FT4	Conditions
High	Low	Low	Low	Primary Hypothyroidism, Post Thyroidectomy, Chronic Autoimmune Thyroiditis
High	N	N	N	Subclinical Hypothyroidism, Autoimmune Thyroiditis, Insufficient Hormone Replacement Therapy.
N/Low	Low	Low	Low	Secondary and Tertiary Hypothyroidism
Low	High	High	High	Primary Hyperthyroidism, Goitre, Thyroiditis, Drug effects, Early Pregnancy
Low	N	N	N	Subclinical Hyperthyroidism
Low	Low	Low	Low	Central Hypothyroidism, Treatment with Hyperthyroidism
Low	N	High	High	Thyroiditis, Interfering Antibodies
N/Low	High	N	N	T3 Thyrotoxicosis, Non thyroidal causes
High	High	High	High	Pituitary Adenoma; TSHoma/Thyrotropinoma



DR. R. SRIVATSAN
M.D.(Biochemistry)



SIN No: SPL24006171

This test has been performed at Apollo Health and Lifestyle Ltd - Chennai, Diagnostics Laboratory.

This test has been performed at Apollo Health and Lifestyle Ltd - RRL ASHOK NAGAR

Apollo Health and Lifestyle Limited | CHN - UBS1107G200(PLC)15819
Regd. Office: 1-18-60/52, Ashoka Baghupatti Chambers, 5th Floor, Begumpet, Hyderabad, Telangana - 500 018 |
www.apolloclinic.com | Email: info@apolloclinic.com, Ph No: 844-8904 7777, Fax No: 8864 7744

ADDRESS:
B No.70, F - Block, 2nd Avenue, Ashok Nagar ERM, Chennai 600 032,
Phone - 844 2628004 / 95

1860 500 7788
www.apolloclinic.com

APOLLO CLINICS NETWORK

Telangana: Hyderabad | AS Ashok Nagar | Chandu Nagar | Koodigar | Walibanda | Nizampet | Marikonda | Uppal | Andhra Pradesh: Vizag (Sethurama Peta) | Karnataka: Bangalore (Kannanagalli) | Andhra: Electronics City | Feroz Town | HGR Layout | India Nagar | JP Nagar | Karimnagar | Karimnagar | Sarajpur Road | Mysore (VV Bellur) | Tamil Nadu: Chennai | Anantapur | Kottapalem | Mogappair | T Nagar | Yelamanchili | Kerala: Velachery | Maharashtra: Pune (Aundh) | Higd Pradikoon | Viman Nagar | Warananthi Uttar Pradesh: Ghaziabad (Indraprastha) | Gujarat: Ahmedabad (Satellite) | Punjab: Amritsar | Chand Road | Harjpur | Faridkot (Railway Station Road)

Patient Name : Mrs.RAJALAKSHMI RENGASAMY	Collected : 13/Jan/2024 09:10AM
Age/Gender : 36 Y 0 M 5 D/F	Received : 13/Jan/2024 01:38PM
UHID/MR No : CVIM.0000057410	Reported : 13/Jan/2024 07:44PM
Visit ID : CVELOPV196861	Status : Final Report
Ref Doctor : Dr.SELF	Sponsor Name : ARCOFEMI HEALTHCARE LIMITED
Emp/Auth/TPA ID : 733816334324	

DEPARTMENT OF IMMUNOLOGY

ARCOFEMI - MEDIWHEEL - FULL BODY ANNUAL PLUS CHECK ADVANCED - FEMALE - 2D ECHO - PAN INDIA - FY2324



DR. R. SRIVATSAN
M.D.(Biochemistry)



SIN No:SPL24006171

This test has been performed at Apollo Health and Lifestyle Ltd - Chennai, Diagnostics Laboratory.

This test has been performed at Apollo Health and Lifestyle Ltd - RRL ASHOK NAGAR

Apollo Health and Lifestyle Limited (CIN - U85110TG2006PLC115819)
 Regd. Office: 1-10-00/52, Ashoka Baghupathi Chambers, 5th Floor, Begumpet, Hyderabad, Telangana - 500 018 |
 www.apollohli.com | Email ID: enquiry@apollohli.com, Ph No: 040-4904 7272, Fax No: 0404 7244

ADDRESS:
 B No.70, F - Block, 2nd Avenue, Ashok Nagar ERM, Chennai 600 102,
 Phone - 044-2624804/05


 1860 500 7788
 www.apolloclinic.com

APOLLO CLINICS NETWORK
 Telangana: Hyderabad | AS Pao Nagar | Charadi Nagar | Koodapur | Walibanda | Nizampet | Manikonda | Uppal | Analka Pradesh | Vijay (Senthama Peta) Karnataka: Bangalore (Koramangala) | Bellandur | Electronic City | Frazer Town | HSR Layout | Indira Nagar | JP Nagar | Kirti Nagar | Koramangala | Sarjapur Road. Mysore (V V Bellur) Tamil Nadu: Chennai | Anna Nagar | Kottapattinam | Mogappair | T Nagar | Velamannaikam | Velachery | Mahabalipuram. Andhra Pradesh: Rajahmundry | Rajamahendravaram | Rajamahendravaram (Satellite) Punjab: Amritsar | Canal Road Harjinder | Faridkot (Railway Station Road)

Patient Name : Mrs.RAJALAKSHMI RENGASAMY	Collected : 13/Jan/2024 09:09AM
Age/Gender : 36 Y 0 M 5 D/F	Received : 13/Jan/2024 01:20PM
UHID/MR No : CVIM.0000057410	Reported : 13/Jan/2024 02:58PM
Visit ID : CVELOPV196861	Status : Final Report
Ref Doctor : Dr.SELF	Sponsor Name : ARCOFEMI HEALTHCARE LIMITED
Emp/Auth/TPA ID : 733816334324	

DEPARTMENT OF CLINICAL PATHOLOGY

ARCOFEMI - MEDIWHEEL - FULL BODY ANNUAL PLUS CHECK ADVANCED - FEMALE - 2D ECHO - PAN INDIA - FY2324

Test Name	Result	Unit	Bio. Ref. Range	Method
COMPLETE URINE EXAMINATION (CUE) , URINE				
PHYSICAL EXAMINATION				
COLOUR	PALE STRAW		PALE YELLOW	Visual
TRANSPARENCY	CLEAR		CLEAR	Visual
pH	8.0		5-7.5	DOUBLE INDICATOR
SP. GRAVITY	1.015		1.002-1.030	Bromothymol Blue
BIOCHEMICAL EXAMINATION				
URINE PROTEIN	NEGATIVE		NEGATIVE	PROTEIN ERROR OF INDICATOR
GLUCOSE	NEGATIVE		NEGATIVE	GLUCOSE OXIDASE
URINE BILIRUBIN	NEGATIVE		NEGATIVE	AZO COUPLING REACTION
URINE KETONES (RANDOM)	NEGATIVE		NEGATIVE	SODIUM NITRO PRUSSIDE
UROBILINOGEN	NORMAL		NORMAL	MODIFIED EHRlich REACTION
BLOOD	NEGATIVE		NEGATIVE	Peroxidase
NITRITE	NEGATIVE		NEGATIVE	Diazotization
LEUCOCYTE ESTERASE	NEGATIVE		NEGATIVE	LEUCOCYTE ESTERASE
CENTRIFUGED SEDIMENT WET MOUNT AND MICROSCOPY				
PUS CELLS	1-2	/hpf	0-5	Microscopy
EPITHELIAL CELLS	1-3	/hpf	<10	MICROSCOPY
RBC	NIL	/hpf	0-2	MICROSCOPY
CASTS	ABSENT		0-2 Hyaline Cast	MICROSCOPY
CRYSTALS	ABSENT		ABSENT	MICROSCOPY



Dr THILAGA
M.B.B.S,M.D(Pathology)
Consultant Pathologist

SIN No:UR2261984

This test has been performed at Apollo Health and Lifestyle Ltd - Chennai, Diagnostics Laboratory.

This test has been performed at Apollo Health and Lifestyle Ltd - RRL ASHOK NAGAR

Apollo Health and Lifestyle Limited (CIN - U85110TG2006PLC115819)

Regd. Office: 1-18-60/62, Ashoka Baghupatti Chambers, 5th Floor, Begumpet, Hyderabad, Telangana - 500 018 | www.apollohlt.com | Email ID: enquiry@apollohlt.com, Ph No: 848-8904 7272, Fax No: 8864 7244

APOLLO CLINICS NETWORK

Telangana: Hyderabad | AS Rao Nagar | Chandu Nagar | Keesapur | Malaburga | Nizampet | Marikonda | Usajil | Anilika Pradeesh, Muzg (Senthama Peta) Karnataka: Bangalore (Kannanagali) | Belasdar | Electronic City | Frazer Town | HSR Layout | Indira Nagar | JP Nagar | Koralehalli | Koramangala | Sarjapur Road. Mysore: (Vijaybhalla) Tamil Nadu: Chennai | Annapuram | Kottapattinam | Mogappair | T Nagar | Velamannaikam | Velachery | Mahanadi: Pune (Aundh) | Higd Pradikoon | Vilas Nagar | Warananthi Uttar Pradesh: Ghaziabad (Indrapuram) Gujarat: Ahmedabad (Satellite) Punjab: Amritsar (Court Road) Harjpur, Faridabad (Railway Station Road)

ADDRESS:
B No.70, F - Block, 2nd Avenue, Ashok Nagar ERM, Chennai 600 032.
Phone - 844 2628004 / 95



1860 500 7788
www.apolloclinic.com

Patient Name : Mrs.RAJALAKSHMI RENGASAMY	Collected : 13/Jan/2024 09:09AM
Age/Gender : 36 Y 0 M 5 D/F	Received : 13/Jan/2024 01:22PM
UHID/MR No : CVIM.0000057410	Reported : 13/Jan/2024 02:58PM
Visit ID : CVELOPV196861	Status : Final Report
Ref Doctor : Dr.SELF	Sponsor Name : ARCOFEMI HEALTHCARE LIMITED
Emp/Auth/TPA ID : 733816334324	

DEPARTMENT OF CLINICAL PATHOLOGY

ARCOFEMI - MEDIWHEEL - FULL BODY ANNUAL PLUS CHECK ADVANCED - FEMALE - 2D ECHO - PAN INDIA - FY2324

Test Name	Result	Unit	Bio. Ref. Range	Method
URINE GLUCOSE(POST PRANDIAL)	NEGATIVE		NEGATIVE	Dipstick

Test Name	Result	Unit	Bio. Ref. Range	Method
URINE GLUCOSE(FASTING)	NEGATIVE		NEGATIVE	Dipstick



Dr THILAGA
M.B.B.S.,M.D(Pathology)
Consultant Pathologist

SIN No:UF010169

This test has been performed at Apollo Health and Lifestyle Ltd - Chennai, Diagnostics Laboratory.

This test has been performed at Apollo Health and Lifestyle Ltd - RRL ASHOK NAGAR

Apollo Health and Lifestyle Limited (CIN - U85110TG2000PLC115819)
Regd. Office: 1-11-60/52, Ashoka Baghupathi Chambers, 5th Floor, Begumpet, Hyderabad, Telangana - 500 018 |
www.apollohli.com | Email ID: enquiry@apollohli.com, Ph No: 844-8904 7272, Fax No: 8854 7244

ADDRESS:
B No.70, F - Block, 2nd Avenue, Ashok Nagar ERM, Chennai 600 102,
Phone - 844 2624804 / 95

 **1860 500 7788**
www.apolloclinic.com

APOLLO CLINICS NETWORK
Telangana: Hyderabad | AS Rao Nagar | Charandi Nagar | Koodigar | Walibanda | Nizampet | Manikonda | Uppal | Anaparthi Pradivhi, Vijay (Sethurama Prasa) Karnataka: Bangalore (Koramangala) | Bellandur | Electronic City | Frazer Town | HSR Layout | Indira Nagar | JP Nagar | Kirti Nagar | Karamangala | Sarjapur Road. Mysore (V V Bellur) Tamil Nadu: Chennai | Anna Nagar | Kottapattinam | Mogappair | T Nagar | Velamannaikam | Velachery | Mahabalipuram. Pune (Aundh) | Pimpri Chinchwad. Vizag: Vengal Rao Nagar | Warangal. Uttar Pradesh: Ghaziabad (Indraprastha) | Gurgaon | Ghaziabad (Satellite) Punjab: Amritsar | Chandigarh Harjinder Park. Kerala: Fort Kochi (Railway Station Road)



Patient Name : Mrs.RAJALAKSHMI RENGASAMY	Collected : 13/Jan/2024 09:09AM
Age/Gender : 36 Y 0 M 5 D/F	Received : 14/Jan/2024 12:15PM
UHID/MR No : CVIM.0000057410	Reported : 16/Jan/2024 01:19PM
Visit ID : CVELOPV196861	Status : Final Report
Ref Doctor : Dr.SELF	Sponsor Name : ARCOFEMI HEALTHCARE LIMITED
Emp/Auth/TPA ID : 733816334324	


DEPARTMENT OF CYTOLOGY

LBC PAP TEST (PAPSURE) , CERVICAL SAMPLE

	CYTOLOGY NO.	786/24
I	SPECIMEN	
a	SPECIMEN ADEQUACY	ADEQUATE
b	SPECIMEN TYPE	LIQUID-BASED PREPARATION (LBC)
	SPECIMEN NATURE/SOURCE	CERVICAL SMEAR
c	ENDOCERVICAL-TRANSFORMATION ZONE	ABSENT
d	COMMENTS	SATISFACTORY FOR EVALUATION
II	MICROSCOPY	Superficial and intermediate squamous epithelial cells with benign morphology. Inflammatory cells, predominantly neutrophils. Negative for intraepithelial lesion/ malignancy.
III	RESULT	
a	EPITHELIAL CELL	
	SQUAMOUS CELL ABNORMALITIES	NOT SEEN
	GLANDULAR CELL ABNORMALITIES	NOT SEEN
b	ORGANISM	NIL
IV	INTERPRETATION	NEGATIVE FOR INTRAEPITHELIAL LESION OR MALIGNANCY

Pap Test is a screening test for cervical cancer with inherent false negative results. Regular screening and follow-up is recommended (Bethesda-TBS-2014) revised

*** End Of Report ***



Dr. Reshma Stanly
M.B.B.S,DNB(Pathology)
Consultant Pathologist

SIN No:CS073000

This test has been performed at Apollo Health & Lifestyle Ltd, Global Reference Laboratory,Hyderabad

