

SARDA

CENTRE FOR DIABETES & SELF CARE

NAME: MR. YOGESH DHALE

SEX : Male

REF. BY : MEDIWHEEL

DATE:26/02/2022

BLOOD SUGAR EXAMINATION

TEST	RESULT
Fasting Blood Sugar:	90 mg/dl
Post Meal Blood Sugar Level:	109 mg/dl

REFERANCE RANGE :	NON DIABETIC	IGT	DIABETIC
FASTING	≤ 90 MG	90-126 mg %	≥ 126 mg %
POSTMEAL	≤ 140 mg	140-200mg%	≥ 200 mg

GYCOCYTED HAEMOGLOBIN

TEST	RESULT	NORMAL
HbA1C:	5.3 %	4.7-5.9 %
M.B.G	98.89% mg	70 - 120 mg

INTERPRETATION:

FOR DIABETIC PATIENT

Good Control: 6.0 - 7.0 %

Fair Diabetic Control: 7.0 - 8.0 %

Unsatisfactory control: 8.0 - 10 %

Poor Diabetic Control: Above 10 %

Dr.S R. SARDA

M.D Reg. No.50462

SARDA CENTRE FOR DIABETES & SELF CARE
4, Vyanktesh Nagar, Jalna Road, Aurangabad
M.D.(Pathology)
Phone No. 2333851, 2334858

SARDA

CENTRE FOR DIABETES & SELF CARE

NAME: MR. YOGESH DHALE

SEX : Male

REF. BY : MEDIWHEEL

DATE:26/02/2022

BLOOD PROFILE

TEST	RESULT	NORMAL
BLOOD UREA N2	15 mg%	5-25 mg %
CREATININE	1.0mg%	0.6-1.4 mg %
BILIRUBIN TOTAL	0.69mg%	0.2-1.0 mg
DIRECT	0.24	0.0-0.3
INDIRECT	0.45	0.3-0.7
S.G.O.T	37 IU/L	15-40 IU/L
S.G.P.T	33 IU/L	15-40 IU/L
ALK PHOSPHATASE	119 IU/L	70-306 IUL
S.PROTEIN TOTAL	7.2gm%	6.0-8.0 gm%
ALBUMIN	4.2gm%	3.2-4.4 gm%
GLOBULINS	3.0gm%	2.3-3.5 gm%
ALB/GLO RATIO	1.4	
G.G.T.P	31	upto50IU
SR.URIC ACID	5.1	3.5-7.0 mg % ^{uric-}

BLOOD GROUP

BLOOD GROUP	:	"B"
R.H.FACTOR	:	TO BE CONFIRMED BY AT THE TIME OF CROSS MATCH

Dr.S R. SARDA
M.D Reg. No.50462
SARDA CENTER FOR DIABETES & SELF CARE
4, Vyanktesh Nagar, Jalna Road, Aurangabad
M.D.(Pathology) 2333851, 2334858

SARDA

CENTRE FOR DIABETES & SELF CARE

NAME: MR. YOGESH DHALE

SEX : Male

REF. BY : MEDIWHEEL

DATE:26/02/2022

LIPID PROFILE

Serum Cholesterol :	147 mg/dl	130 - 250 mg/dl
HDL Cholesterol:	41 mg/dl	30 - 95 mg/dl
Serum Triglyceride:	100 mg/dl	up to 165 mg/dl
LDL Cholesterol:	86 mg/dl	up to 165 mg/dl
VLDL Cholesterol:	20 mg/dl	up to 40 mg/dl
LDL. / HDL Cholesterol Ratio:	2.1	Low risk : 0.5 - 3.0 Moderate risk: 3.0 - 6.0 High risk: > 6.0
CHOL./HDL Cholesterol Ratio:	3.59	Low risk : 3.3 - 4.4 Average risk: 4.4 - 7.1 Moderate risk: 7.0 - 11.0 High risk: > 11

Dr. S R. SARDA
M.D. Reg. No. 56462
Dr. Sampat Sarda
M.D. (Pathology)
SARDA CENTRE FOR DIABETES & SELF CARE
4, Vyanktesh Nagar, Jalna Road, Aurangabad
Phone No. 2333851, 2334858

SARDA
CENTRE FOR DIABETES & SELF CARE

4, Vyankatesh Nagar, Jalna Road, Aurangabad. Ph. : (0240) 2333851, 2334858.

Name : Mr. Yygesh Shale Age : 28yr
BOB

CLINICAL SUMMARY :

Weight : _____ Height (Cms) : _____ Blood Pressure : _____

ECG FINDINGS :

Rate : 72/min ORS. Complex : N

Rhythm : N ST Segment : N

Mechanism : N T. Wave : N

Axis : N QT Interval : N

P. Wave : N PR Interval : N

Recommendation : Wan

Dr. A. S. SARDA
M.D. Reg. No. 13570

SARDA CENTER FOR DIABETES & SELF CARE
4, Vyankateshnagar, Jalna Road, A.
Phone No. 2333851, 2334858

Date : 26/2/22 Dr. _____

SARDA

CENTRE FOR DIABETES & SELF CARE

NAME: MR. YOGESH DHALE

SEX : Male

REF. BY : MEDIWHEEL

DATE:26/02/2022

Urine Routine Examination

Physical Examination

Colour:	Pale Yellow
Appearance:	Clear
Reaction:	Acidic
Deposit	Absent

Chemical Examination:

Specific Gravity	1.010
Albumin	Absent
Sugar:	Absent
Acetone:	----
Bile Salts	----
Bile Pigment:	----

Microscopic Examination

RBC :	Absent
Pus Cells:	OCASSIONAL/HPF
Epihtelial cells:	Absent
Crystals:	Absent
Casts:	Absent

Dr.S R. SARDA

M.D Reg. No.50462

SARDA CENTER FOR DIABETES & SELF CARE

4, Vyanktesh Nagar, Jalna Road, Aurangabad

Ph.: 2333851, 2334858

Dr.Sampat Sarda

M.D.(Pathology)

SARDA

CENTRE FOR DIABETES & SELF CARE

Mr Yogesh Dhale

28/07/22

BUB, A'und 29 yrs male

0

Ophthalmic Exam Report

	(R)	(L)
<u>W/field</u>	6/6 to 10/30/90	6/6 to 1.25/1.0/85°
<u>Ant Seg</u>	NAD	NAD
<u>Lens</u>	clear	clear
<u>Fundus</u>	myopic disc CABZ RET	myopic disc 4203 RET
<u>Retinels</u>	normal	normal

Imp. (BE) vitritis normal limits



Ajay

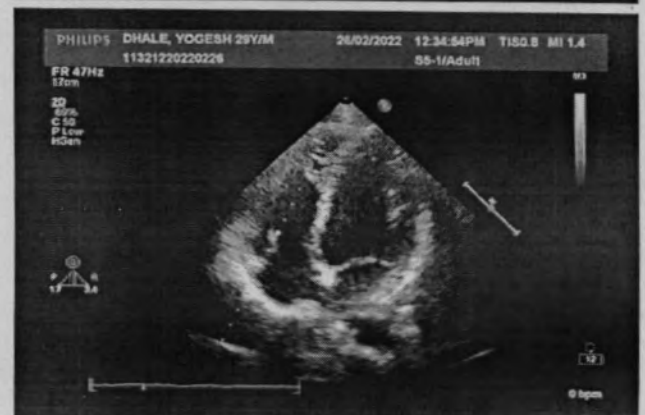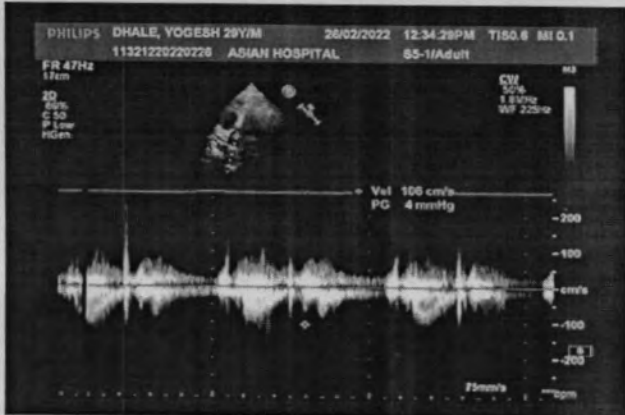
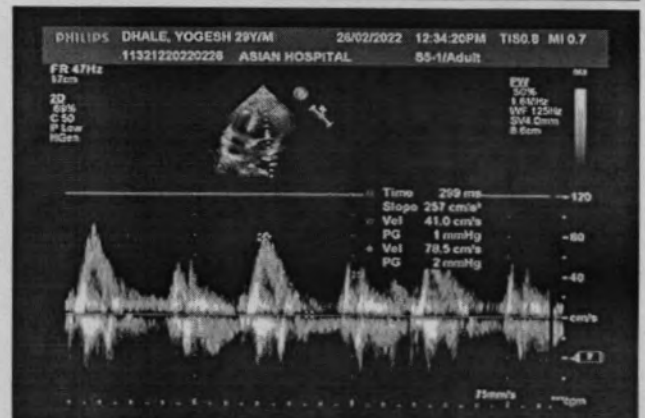
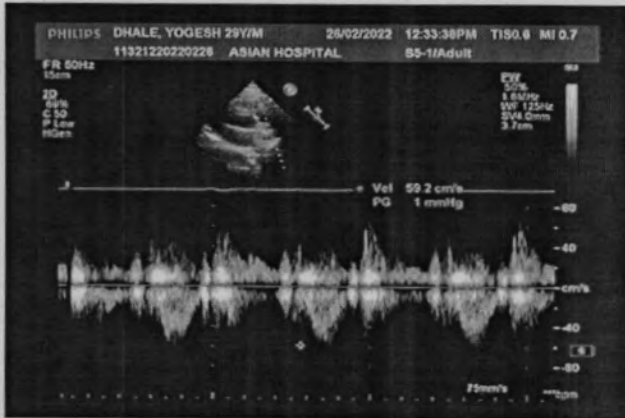
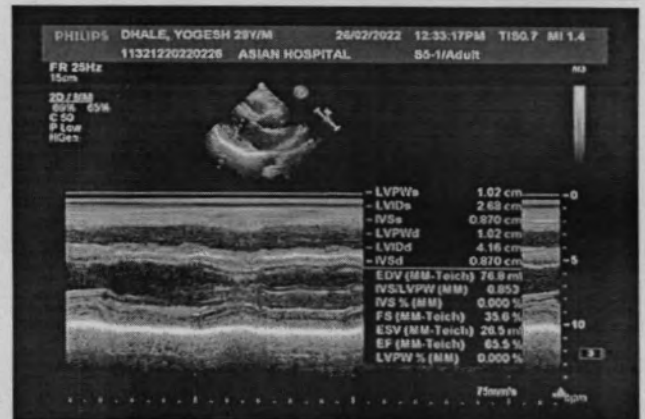
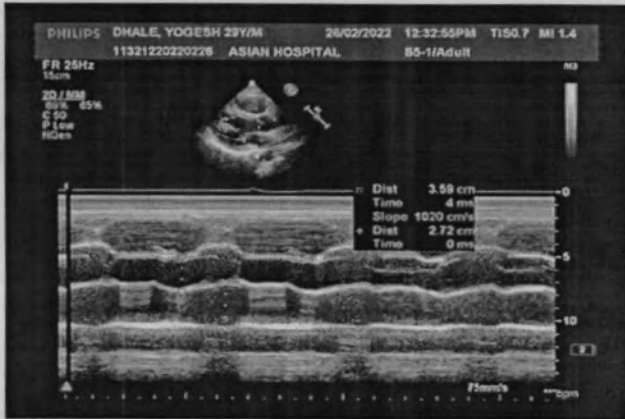
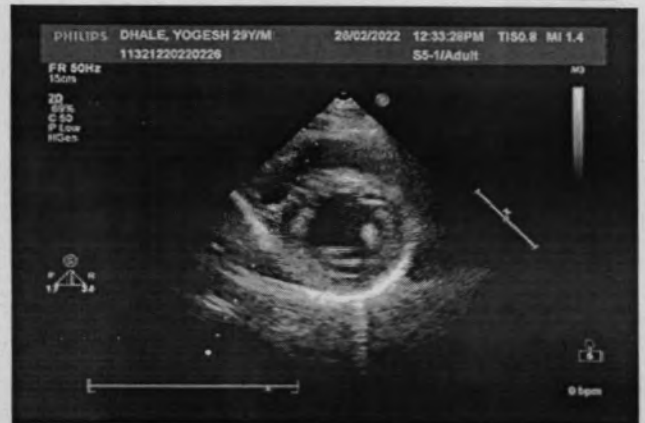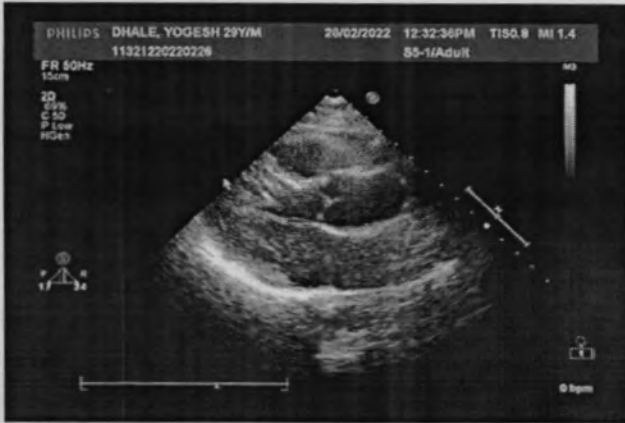DR. AJAY LOHIYA
M.B.B.S., D.O., (B.O.M) D.N.B.F.C.P.S.
REC. NO. 86436
THIRUPATI NETRALAYA & DENTAL CLINIC
AURANGABAD.

Asian Superspeciality Hospital

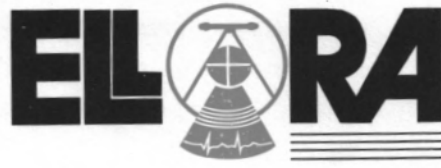Motiwala Square Akashwani Signal Jalna Road
Aurangabad - 431003

Name: Mr. Yogesh Dhale
Age: 29 Y
Sex: M
Date: 26-Feb-2022

Ref By: Dr. Sarada Sir
Study: 2 D ECHO
Examined By: Dr. Deorao Thenge
M.D.,D.N.B.,(Cardiology)



DIGITAL X-RAY
INTERVENTIONAL RADIOLOGY
3D/4D SONOGRAPHY & COLOR DOPPLER
2-D ECHOCARDIOGRAPHY
PERIPHERAL COLOR DOPPLER
HI-SPEED HELICAL C.T. SCAN
C.T. ANGIOGRAPHY
PATHOLOGY LAB. SERVICES



DIAGNOSTIC CENTRE
X-RAY, IMAGING & PATHOLOGY

1, VYANKATESH NAGAR, OPP. SFS
HIGH SCHOOL, JALNA ROAD,
AURANGABAD - 431005
☎ : 0240-2353182, 2325282, 8446100111

YOGESH DAHALE

26-02-2022

Ref. by:

CHEST PA VIEW

Trachea central.

Apices are clear.

Both lung fields appeared well pneuamtised and appeared normal.

Both cp angles are clear.

Cardiac silhoutte appeared normal.

IMPRESSION :

NORMAL CHEST.

DR. P. A. BARJATYA
M.B.B.S., M.D.
9823344449



DR. G. S. LAHOTI
M.B.B.S., D.M.R.D.
9850171587



VIGHNAHARTA HEALTH VISIONARIES PRIVATE LIMITED'S

ASIAN SUPERSPECIALITY HOSPITAL

CITICARE

CIN No. : U85100MH2013PTC245579

Reg. Office : CTS No. 15184/3, Asian Hospital, Motiwala Square, Akashwani Chowk, Jalna Road, Aurangabad - 431 001. (MH) India
E-mail : asianciticarehospital@gmail.com Ph. 0240 - 6610801 / 6610807

CONCLUSION:

Normal Sized Cardiac Chambers.

No LV RWMA.

Good LV Systolic function with LVEF- 65%.

Normal LV Filling Pattern.

No MR/AR/TR.

No PE/LV Clot.



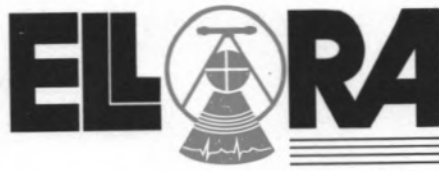DR. DEORAO THENGE
M.D., D.N.B. (CARDIOLOGY)

Jr. Devrao Thenge
MD, DNB (Cardiology)
Reg. No. 2001/02/491

Dr. Deorao Thenge
M.D., D.N.B., (Cardiology)

Dr. Mukund Bajaj
M.D., D.M., (Cardiology)

DIGITAL X-RAY
INTERVENTIONAL RADIOLOGY
3D/4D SONOGRAPHY & COLOR DOPPLER
2-D ECHOCARDIOGRAPHY
PERIPHERAL COLOR DOPPLER
HI-SPEED HELICAL C.T. SCAN
C.T. ANGIOGRAPHY
PATHOLOGY LAB. SERVICES



DIAGNOSTIC CENTRE
X-RAY, IMAGING & PATHOLOGY

1, VYANKATESH NAGAR, OPP. SFS
HIGH SCHOOL, JALNA ROAD,
AURANGABAD - 431005
☎ : 0240-2353182, 2325282, 8446100111

YOGESH DHALE

26-02-2022

Ref. by:

USG ABDOMEN

Liver is normal in size, shape and revealed normal echotexture.
Intrahepatic biliary radicles and portovenous echocomplex appeared normal.
No e/o any focal solid, cystic, or diffuse parenchymal pathology seen.
Normal cbd and portal vein.
Gallbladder is physiologically distended and appeared normal, no e/o any gallbladder calculus.
Normal gb wall thickness.
Spleen is normal in size & echogenicity. no e/o focal lesion seen.
Pancreas is normal in size, shape and echotexture. Normal peripancreatic fat planes.
No e/o pancreatic calcification/calculi. normal pancreatic duct.
Both kidneys are normal in size, shape, position and revealed normal cortical & medullary echopattern,
No e/o any calculus seen, No e/o hydronephrosis.
No e/o ascitis. no e/o any paraaortic adenopathy.
Normal bowel loop peristalsis & caliber.
Urinary bladder is well distended and appeared normal, no e/o any vesical calculus or mass lesion.
E/o mild cystitis.
Normal prostate.

IMPRESSION :

**NORMAL LIVER, GALL BLADDER, SPLEEN, PANCREAS, BOTH KIDNEYS, .
NORMAL UR BLADDER. MILD CYSTITIS.
NORMAL PROSTATE.**

DR. P. A. BARJATYA
M.B.B.S., M.D.
9823344449



DR. G. S. LAHOTI
M.B.B.S., D.M.R.D.
9850171587



VIGHNAHARTA HEALTH VISIONARIES PRIVATE LIMITED'S

ASIAN SUPERSPECIALITY HOSPITAL

CITICARE

CIN No. : U85100MH2013PTC245579

Reg. Office : CTS No. 15184/3, Asian Hospital, Motiwala Square, Akashwani Chowk, Jalna Road, Aurangabad - 431 001. (MH) India
E-mail : asianciticarehospital@gmail.com Ph. 0240 - 6610801 / 6610807

Name of Patient: Mr. Yogesh Dhale

Date:26/02/2022

Age/Sex : 29Yrs/Male

2-D ECHOCARDIOGRAPHY REPORT

Mitral Valve : Normal
Aortic Valve : Normal
Tricuspid Valve : Normal
Pulmonary Valve : Normal
Right Atrium : Normal
Right Ventricle : Normal
Left Atrium : 3.59Cm
Left Ventricle : Normal
IVS(S):0.92Cm LV(S):2.68Cm PW(S):0.98Cm LVEF- 65%
IVS(D):0.87Cm LV (D):4.16Cm PW(D):1.02Cm FS- 35%
IVS : 0.95Cm
IAS : Intact
Aorta : 2.72Cm
Pulmonary Artery : Normal
Pericardium : Normal
IVC : Normal

DOPPLER STUDY

Mitral Flow : E- 0.78m/sec A- 0.41m/sec DT- 299m/sec E/A-1.08
Aortic Flow : 1.06m/sec
Pulmonary Flow : 0.59m/sec
Tricuspid Flow : m/sec RVSP- mm Hg

COLOR DOPPLER

MR : No
AR : No
TR : No
PR : No
Shunts : Nil

Dr. Deorao Thenge
M.D.,D.N.B., (Cardiology)

Dr. Mukund Bajaj
M.D.,D.M., (Cardiology)

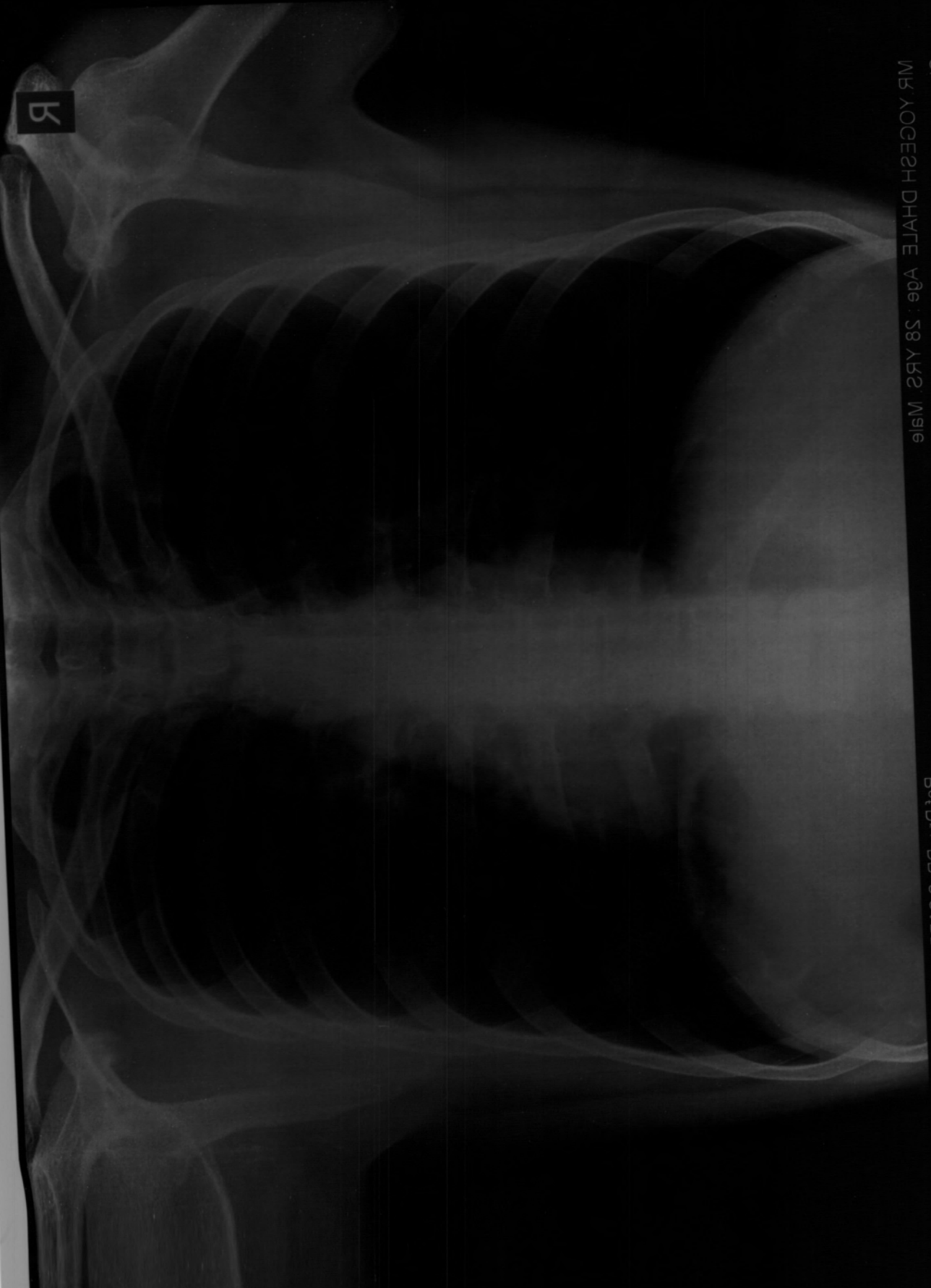
Ellora Diagnostic Centre, Aurangabad (0540) 5323185

Chest : PA Patient ID :

MR.YOGESH DHALE Age : 58 YRS Male

Ref Dr. : DR. S.SARDA

Date : 26-05-2025 PM 15:25:02



R

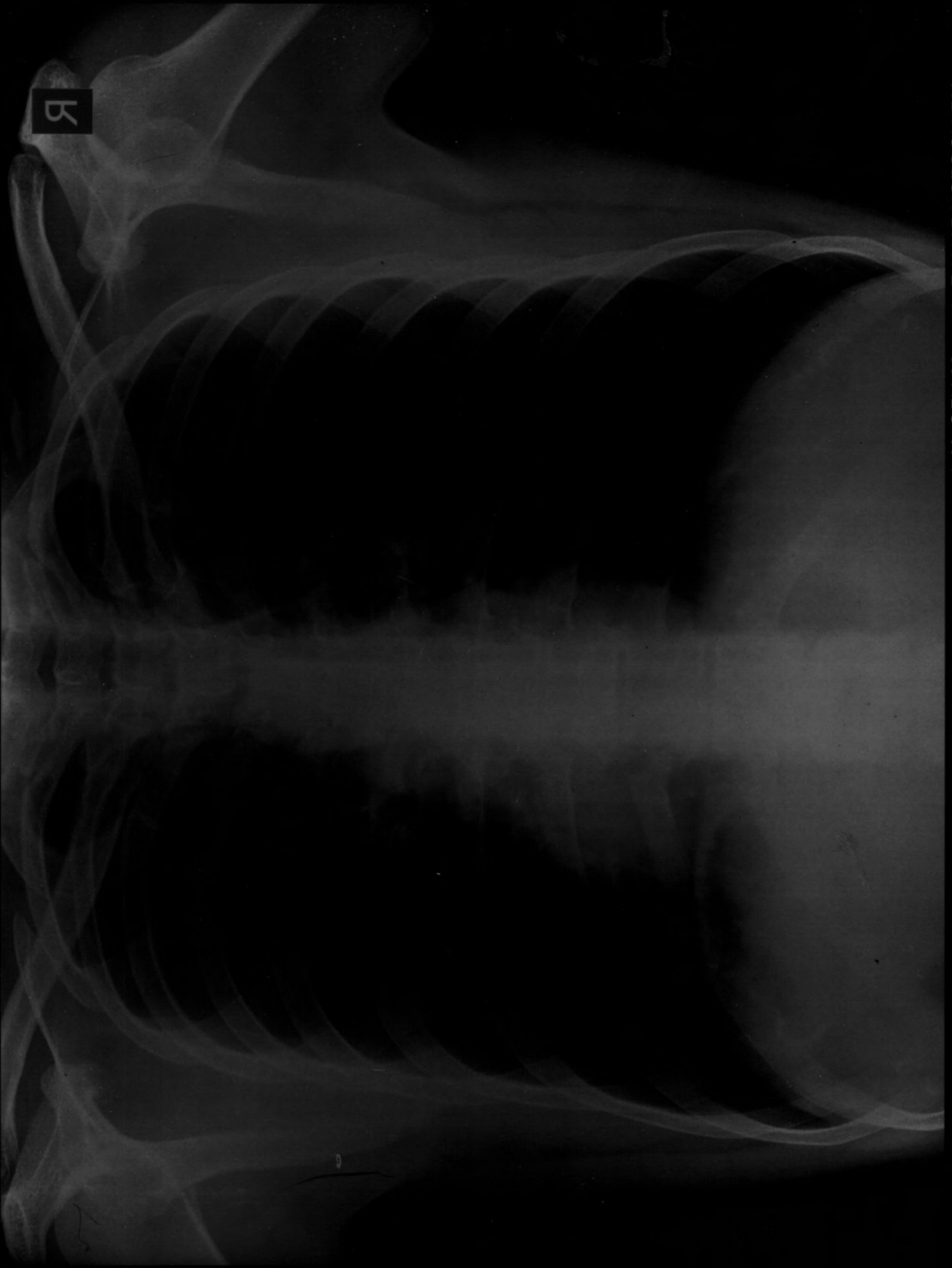
Ellora Diagnostic Centre, Anisudaspur (0540) 3323185

Client : PA Patient ID :

MR. YOGESH DHALE Age : 58 YRS. Male

Date : 26-05-2025 PM 15:25:02

Ref Dr. : DR. S. SARDAR



R