



REVIVAL DIAGNOSTICS

HEALTH CHECK-UP SUMMARY

Name: Shilpa Kumari

Date: 25/02/2023

Email ID :

Sex: F Age: 32 Years Contact No: 9955025809 Remarks :

Under-weight

Normal

i> BMI

Height (in Cm) : 141 Weight (in Kg) : 63 BMI: 31.7 Over-weight

ii> Blood Pressure & Pulse

110/70 mm/Hg
78/min.

If high or low, whether the person is on medication : YES / NO

iii> Blood Tests & Lung Function Remarks

RS } @
CVS } @
CNS } @

If abnormal, whether the person is on medication : YES / NO

iv> Eye Test Remarks

Eye Test : (R) G/G (L) G/G
Color Vision: 2

v> Heart Disease

Whether any specific heart ailment detected (ECG findings) :
normal

vi> Any other problems needing attention / Overall Assessment :

Hypothyroidism - last 3 years

Dr. Chirag Patel
M.B.B.S. G-49432

Signature of the Doctor

Shilpa Kumari

Revival Diagnostic

401, Aqua Corridor,
B/s. Star Bazar, Surat-395009
Mo. 91062-28601

0261 2747788, 9825947712

revivaldiagnostics.surat@gmail.com

4TH Floor, Aqua Corridor, Hazira Road, Adajan Pal, Surat-395009.

www.revivaldiagnostics.com



REVIVAL DIAGNOSTICS

Name	SHILPA KUMARI	Age/Gender	32Yrs/Female
Reg No.	1758/23	Receipt No	6125
Referred By	BOB - MEDI WHEEL(PKG1000241)	Mode of Payment	CREDIT
Collection Type	CENTER	Collection DateTime	25-Feb-2023 09:49 AM

BLOOD GROUP - 250223113 Released at 25-Feb-2023 12:14 PM

Parameter	Result	Biological Ref.Range	Method
-Blood Group	"B"		
-Rh Factor	POSITIVE		

CBC - 250223111 Released at 25-Feb-2023 01:18 PM

Parameter	Result	Biological Ref.Range	Method
-Haemoglobin	10.4 gm/dL	L (12 - 16 gm/dL)	Auto
-RBC Count	3.85 mill/cumm	L (4.2 - 5.4 mill/cumm)	Auto
-Total WBC Count	7700 /cumm	(4000 - 10000 /cumm)	Auto
-Platelet Count	1.85 lakh/cumm	(1.5 - 4.5 lakh/cumm)	Auto

Blood Indices

-HCT	33.7 %	L (40 - 55 %)	Auto
-MCV	87.4 fl	(80 - 92 fl)	Auto
-MCH	27.0 pg	(27 - 31 pg)	Auto
-MCHC	30.9 gm/dL	L (32 - 36 gm/dL)	Auto
-RDW	14.6 %	(11 - 15 %)	Auto

Diff WBC Count

-Polymorphs	62 %	(40 - 80 %)	Microscopically
-Lymphocytes	33 %	(20 - 40 %)	Microscopically
-Eosinophils	03 %	(1 - 6 %)	Microscopically
-Monocytes	02 %	(2 - 7 %)	Microscopically
-Basophils	00 %	(0 - 1 %)	Microscopically
-PLATELET ON SMEAR	Adequate		Microscopically
-MALARIAL PARASITES	Malarial Parasites Not Detected		Microscopically

[Test performed on Fully Automated Hematology Analyzer ERBA H-360]

Revival Diagnostics
401-Aqua Corridor,
Beside Star Bazar, Adajan,
Surat-395009. Mo. 9825947712

Dr. Shivangi Gandhi

M.B.B.S., M.D. (Pathology)



0261 2747788, 9825947712



4TH Floor, Aqua Corridor, Hazira Road, Adajan Pal, Surat-395009.



revivaldiagnostics.surat@gmail.com



www.revivaldiagnostics.com

This Medical Report Is Not Intended For Medico-legal Purposes.
Laboratory Test Results Are Subject To Technical Limitation And Should
Be Clinically Correlate For Final Diagnosis



REVIVAL DIAGNOSTICS

Name	SHILPA KUMARI	Age/Gender	32Yrs/Female
Reg No.	1758/23	Receipt No	6125
Referred By	BOB - MEDI WHEEL(PKG10000241)	Mode of Payment	CREDIT
Collection Type	CENTER	Collection DateTime	25-Feb-2023 09:49 AM

FBS & PPBS - 250223112 Released at 25-Feb-2023 03:45 PM

Parameter	Result	Biological Ref.Range	Method
-Fasting Blood Sugar (FBS)	99 mg/dL	70-100 mg/dl Impaired Tolerance:100-125 Diabetes Mellitus:>=126 (On more than one occasion) (American diabetes association guidelines 2022)	
-Fasting Urine Sugar	Absent		
-Fasting Urine Acetone	Absent		
-PPBS	127 mg/dL	(90 - 140 mg/dL)	
-PP2BS URINE SUGAR	Absent		
-PP2BS URINE ACETONE	Absent		

HBA1C - 250223111 Released at 25-Feb-2023 03:45 PM

Parameter	Result	Biological Ref.Range	Method
-HBA1C	5.4 %	HbA1C Degree of Glucose Control <5.6 % Non Diabetics 5.7 - 6.4 % Prediabetics > =6.5 % Diabetics (REF:Wallace, 11th Edition) REMARKS: 6 - 7 % Excellent Control 7 - 8 % Good Control 8 - 10 % Unsatisfactory Control >10 % Poor Control	Boronate Affinity

-Method[] High Performance Liquid Chromatography (HPLC)

Revival Diagnostics
401-Aqua Corridor,
Beside Star Bazar, Adajan,
Surat-395009. Mo. 9825947712



0261 2747788, 9825947712



4TH Floor, Aqua Corridor, Hazira Road, Adajan Pal, Surat-395009.



revivaldiagnostics.surat@gmail.com



www.revivaldiagnostics.com

Dr. Shivangi Gandhi

M.B.B.S, M.D (Pathology)

This Medical Report Is Not Intended For Medico-legal Purposes.
Laboratory Test Results Are Subject To Technical Limitation And Should
Be Clinically Correlate For Final Diagnosis



REVIVAL DIAGNOSTICS

Name	SHILPA KUMARI	Age/Gender	32Yrs/Female
Reg No.	1758/23	Receipt No	6125
Referred By	BOB - MEDI WHEEL(PKG1000241)	Mode of Payment	CREDIT
Collection Type	CENTER	Collection DateTime	25-Feb-2023 09:49 AM

ESR - 250223111 Released at 25-Feb-2023 01:11 PM

Parameter	Result	Biological Ref.Range	Method
-E.S.R	12 mm/hr	(3 - 15 mm/hr)	



Revival Diagnostics

401-Aqua Corridor,
Beside Star Bazar, Adajan,
Surat-395009. Mo. 9825947712

Dr. Shivangi Gandhi

M.B.B.S, M.D (Pathology)



0261 2747788, 9825947712



4TH Floor, Aqua Corridor, Hazira Road, Adajan Pal, Surat-395009.



revivaldiagnostics.surat@gmail.com



www.revivaldiagnostics.com

This Medical Report Is Not Intended For Medico-legal Purposes.
Laboratory Test Results Are Subject To Technical Limitation And Should
Be Clinically Correlate For Final Diagnosis



REVIVAL DIAGNOSTICS

Name	SHILPA KUMARI	Age/Gender	32Yrs/Female
Reg No.	1758/23	Receipt No	6125
Referred By	BOB - MEDI WHEEL(PKG10000241)	Mode of Payment	CREDIT
Collection Type	CENTER	Collection DateTime	25-Feb-2023 09:49 AM

LIVER FUNCTION TEST (LFT) - 250223113 Released at 25-Feb-2023 02:13 PM

Parameter	Result	Biological Ref.Range	Method
-Serum Total Bilirubin	0.5 mg/dL	(0 - 1.3 mg/dL)	Diazo
-Serum Direct Bilirubin	0.1 mg/dL	(0 - 0.4 mg/dL)	Diazo
-Serum InDirect Bilirubin	0.4 mg/dL	(0.1 - 1.3 mg/dL)	Calculated
-Total Protein (TP)	6.7 gm/dL	(6.4 - 8.3 gm/dL)	Biuret
-Albumin (ALB)	4.2 gm/dL	(3.5 - 5.2 gm/dL)	BCG
-Globulin	2.5 gm/dL	(2.3 - 3.6 gm/dL)	Calculated
-A/G Ratio	1.68 gm/dL	(1 - 2.3 gm/dL)	Calculated
-SGPT(ALT)	26 U/L	(5 - 45 U/L)	IFCC, Kinetic without Pyridoxal Phosphate
-SGOT (AST)	21 U/L	(0 - 35 U/L)	IFCC, Without Pyridoxal Phosphate
-Alkaline Phosph.	85 U/L	(42 - 128 U/L)	ALP-AMP
-GGT	23 U/L	(5 - 50 U/L)	Glupa-C

[Test performed on Fully Automated Biochemistry Analyzer ERBA EM200]

REVIVAL
DIAGNOSTICS

Revival Diagnostics
401-Aqua Corridor,
Beside Star Bazar, Adajan,
Surat-395009. Mo. 9825947712

Dr. Shivangi Gandhi

M.B.B.S., M.D (Pathology)

revivaldiagnostics.surat@gmail.com



0261 2747788, 9825947712



4th Floor, Aqua Corridor, Hazira Road, Adajan Pal, Surat-395009.



revivaldiagnostics.surat@gmail.com



www.revivaldiagnostics.com

This Medical Report Is Not Intended For Medico-legal Purposes.
Laboratory Test Results Are Subject To Technical Limitation And Should
Be Clinically Correlate For Final Diagnosis



REVIVAL DIAGNOSTICS

Name	SHILPA KUMARI	Age/Gender	32Yrs/Female
Reg No.	1758/23	Receipt No	6125
Referred By	BOB - MEDI WHEEL(PKG1000241)	Mode of Payment	CREDIT
Collection Type	CENTER	Collection DateTime	25-Feb-2023 09:49 AM

Creatinine - 250223113 Released at 25-Feb-2023 02:13 PM

Parameter	Result	Biological Ref.Range	Method
-Creatinine	0.6 mg/dL	(0.6 - 1.14 mg/dL)	ENZYMATIC

BUN - 250223113 Released at 25-Feb-2023 11:40 AM

Parameter	Result	Biological Ref.Range	Method
-Blood Urea Nitrogen (BUN)	10 mg/dL	(6 - 20 mg/dL)	Calculated

Uric Acid - 250223110 Released at 25-Feb-2023 02:13 PM

Parameter	Result	Biological Ref.Range	Method
-Uric Acid	6.3 mg/dL	(3.5 - 7.2 mg/dL)	Uricase-POD

REVIVAL
DIAGNOSTICS

Revival Diagnostics

401-Aqua Corridor,
Beside Star Bazar, Adajan,
Surat-395009. Mo. 9825947712

Dr. Shivangi Gandhi

M.B.B.S., M.D (Pathology)



0261 2747788, 9825947712



4TH Floor, Aqua Corridor, Hazira Road, Adajan Pal, Surat-395009.



revivaldiagnostics.surat@gmail.com



www.revivaldiagnostics.com

This Medical Report Is Not Intended For Medico-legal Purposes.
Laboratory Test Results Are Subject To Technical Limitation And Should
Be Clinically Correlate For Final Diagnosis



REVIVAL DIAGNOSTICS

Name	SHILPA KUMARI	Age/Gender	32Yrs/Female
Reg No.	1758/23	Receipt No	6125
Referred By	BOB - MEDI WHEEL(PKG10000241)	Mode of Payment	CREDIT
Collection Type	CENTER	Collection DateTime	25-Feb-2023 09:49 AM

Lipid Profile - 250223113 Released at 25-Feb-2023 02:13 PM

Parameter	Result	Biological Ref.Range	Method
-Serum Cholesterol	216 mg/dL	Desirable < 200 mg/dl Borderline High : 200-239 mg/dl High : > 240 mg/dl	CHOD-PAP
-Serum Triglyceride	134 mg/dL	Normal < 150 mg/dl Borderline High : 150 - 159 mg/dl High : 200 - 499 mg/dl Very High : 500 mg/dl	GPO-POD Method
-Serum HDLD(Direct)	63 mg/dL	Normal :> 55 mg/dl Borderline : 35-55 mg/dl Undesirable: < 35 mg/dl	PVS-PEGME Precipitation with CHOD-POD
-Serum VLDL	27 mg/dL	(5 - 30 mg/dL)	Calculated
-Serum LDLD(Direct)	126 mg/dL	Optimal:< 100 mg/dl Above Optimal : 100- 129 mg/dl Borderline High : 130-159 mg/dl High : > 160-189mg/dl Very High : >190 mg/dl	Calculated
-Chol/HDL	3.43	Low risk: <3.8 Medium Risk: 3.8 to 5.9 High Risk: > 6	Calculated
-LDL/Chol	1.71	Low risk: <3.55 Medium Risk: 3.55 to 4.0 High Risk: > 6	Calculated

[Test performed on Fully Automated Biochemistry Analyzer ERBA EM200]

Revival Diagnostics
401-Aqua Corridor,
Beside Star Bazar, Adajan,
Surat-395009. Mo. 9825947712

Dr. Shivangi Gandhi

M.B.B.S, M.D (Pathology)



0261 2747788, 9825947712



4TH Floor, Aqua Corridor, Hazira Road, Adajan Pal, Surat-395009.



revivaldiagnostics.surat@gmail.com



www.revivaldiagnostics.com

This Medical Report Is Not Intended For Medico-legal Purposes.
Laboratory Test Results Are Subject To Technical Limitation And Should
Be Clinically Correlate For Final Diagnosis



Name	SHILPA KUMARI	Age/Gender	32Yrs/Female
Reg No.	1758/23	Receipt No	6125
Referred By	BOB - MEDI WHEEL(PKG1000241)	Mode of Payment	CREDIT
Collection Type	CENTER	Collection DateTime	25-Feb-2023 09:49 AM

Urine Routine & Micro Examination - 250223115 Released at 25-Feb-2023 01:27 PM

Parameter	Result	Biological Ref.Range	Method
<u>Physical Examination</u>			
-Quantity	20		Manual
-Colour	Pale Yellow	Pale Yellow	Manual
-Appearance	Clear	Clear	Manual
-Reaction (pH)	Acidic		Dipstick
-Specific Gravity	1.030		Dipstick
<u>Chemical Examination</u>			
-Proteins.	Absent		Dipstick
-Sugar	Absent		Dipstick
-Acetone.	Absent		Dipstick
-Bile Salts	Absent	Absent	Dipstick
-Bile Pigments	Absent	Absent	Dipstick
-Occult Blood Test (OBT).	Negative		Dipstick
<u>Microscopic Examination</u>			
-Pus Cells	1-2		Microscopically
-Red Blood Cells	Absent		Microscopically
-Epithelial Cells	1-2		Microscopically
-Bacteria.	Absent		Microscopically
-Crystals	Absent	Absent	Microscopically
-Others	NIL	Absent	Microscopic Examination

Revival Diagnostics
401-Aqua Corridor,
Beside Star Bazar, Adajan,
Surat-395009. Mo. 9825947712

Dr. Shivangi Gandhi

M.B.B.S, M.D (Pathology)



0261 2747788, 9825947712



4TH Floor, Aqua Corridor, Hazira Road, Adajan Pal, Surat-395009.




revivaldiagnostics.surat@gmail.com



www.revivaldiagnostics.com



REVIVAL DIAGNOSTICS



Name	SHILPA KUMARI	Age/Gender	32Yrs/Female
Reg No.	1758/23	Receipt No	6125
Referred By	BOB - MEDI WHEEL(PKG10000241)	Mode of Payment	CREDIT
Collection Type	CENTER	Collection DateTime	25-Feb-2023 09:49 AM

Total T3 T4 TSH - 250223113 Released at 25-Feb-2023 01:24 PM

Parameter	Result	Biological Ref.Range	Method
-Total T3	1.03 ng/ml	(0.87 - 1.78 ng/ml)	Fluorescence Enzyme Immunoassay
-Total T4	5.23 ug/dl	(4.6 - 11 ug/dl)	Fluorescence Enzyme Immunoassay
-TSH	3.62 uIU/ml	0.50 - 5.50 uIU/ml 5.5 to 15 ul U/ml - Suggested Clinical co-relation or Repeat test with new sample as physiological factors can give falsley high TSH Above 15uIU/ml Hypothyroid PREGNANT WOMEN normal ranges for TSH: 1st Trimester : 0.0878 - 2.8293 uIU/ml 2nd Trimester : 0.1998 - 2.7915 uIU/ml 3rd Trimester : 0.307 - 2.9028 uIU/ml Ref: TIETZ Fundamentals of Clinical Chemistry	Fluorescence Enzyme Immunoassay

[Test performed on Fully Automated Immunology Analyzer Maglumi-600]

Revival Diagnostics
401-Aqua Corridor,
Beside Star Bazar, Adajan,
Surat-395009. No. 9825947712

Dr. Shivangi Gandhi

M.B.B.S, M.D (Pathology)



0261 2747788, 9825947712



4TH Floor, Aqua Corridor, Hazira Road, Adajan Pal, Surat-395009.



revivaldiagnostics.surat@gmail.com



www.revivaldiagnostics.com

This Medical Report Is Not Intended For Medico-legal Purposes.
Laboratory Test Results Are Subject To Technical Limitation And Should
Be Clinically Correlate For Final Diagnosis



NAME: Shilpa Kumari SEX: F
BIRTHDATE: 12/12/1990 AGE: 32

DEPARTMENT OF OPHTHALMOLOGY

EYE TEST:

1. VISION:

RIGHT EYE - 6/6

LEFT EYE - 6/6

2. COLOR VISION:

RIGHT EYE - 12

LEFT EYE - 12

3. FUNDUS:

RIGHT EYE - 12

LEFT EYE - 12

REMARKS:

① Shilpa Kumari

Revival Diagnostic
401, Aqua Corridor,
B/s. Star Bazar, Surat-395009
Ophthalmologist/Optometrist



0261 2747788, 9825947712



4TH Floor, Aqua Corridor, Hazira Road, Adajan Pal, Surat-395009.



revivaldiagnostics.surat@gmail.com



www.revivaldiagnostics.com



Name	SHILPA KUMARI	Age/Gender	32Yrs/Female
Reg No.	1758/23	Receipt No	6125
Referred By	BOB - MEDI WHEEL(PKG10000241)	Mode of Payment	CREDIT
Collection Type	CENTER	Collection DateTime	25-Feb-2023 09:49 AM

USG OF ABDOMEN & PELVIS

LIVER:

Liver is normal in size, shape and increased echotexture.

No evidence of focal SOL or dilatation of IHBR seen.

Portahepatis appear normal.

GALLBLADDER:

Gallbladder is distended and appears normal.

No e/o calculus, mass lesion or changes of cholecystitis seen.

PANCREAS:

Pancreas appears normal in size, shape and echotexture.

No e/o focal lesion, mass or changes of pancreatitis seen.

SPLEEN:

Spleen appears normal in size, shape and echotexture.

PARAAORTIC REGION:

Aorta grossly appears normal. No e/o paraaortic lymphnodes seen.

KIDNEYS:

Both kidneys appear normal in size, shape, position and echotexture.

Cortex and collecting system of both kidneys appear normal.

No evidence of calculus or obstructive uropathy on either side.

URINARY BLADDER:

Bladder is distended and appears normal.

No calculus, mass lesion or changes of cystitis is seen.

UTERUS:

Retroverted, Normal in size, shape and echotexture with empty central uterine cavity.

Cervix appears normal.

No e/o focal SOL. Endometrial thickness is normal.

OVARIES:

Both adnexal region appear normal.

No e/o adnexal mass lesion seen on either side.

No evidence of free fluid seen in pelvis.

COMMENTS:

fatty liver



0261 2747788, 9825947712



4th Floor, Aqua Corridor, Hazira Road, Adajan Pal, Surat-395009.

Dr. Chirag K. Patel

MBBS-DMPD

Reg. No. G-23509

Revival Diagnostic

4th Floor, Aqua Corridor,
Star Bazar, Hazira Main Road,




Revival Diagnostics, Surat@gmail.com



Mo. 97266 726683

www.revivaldiagnostics.com



2D-ECHOCARDIOGRAPHY & COLOR DOPPLER REPORT

Name:	SHILPA KUMARI	Age/Gender	33 Yrs /Female
Referred by.	MEDI WHEEL	Date	25 /02/2023

INDICATION: Preventive Health check up


- **CARDIAC CHAMBERS:** Left Ventricle: Normal size, Left Atrium: Normal size.
- No e/o thrombus in LA/LV.
- **Right Atrium:** Normal size. **Right Ventricle:** Normal size,
- **Normal Right Ventricular function.** (TAPSE=20mm)
- **Normal Left Ventricular systolic function. LVEF = 60% ,**
No regional wall abnormality. No thinning / scarring / dyskinesia of LV wall.
- **No Concentric Left Ventricular Hypertrophy.** (IVSd= 10 mm),
- **LV Compliance :**
NO Left Ventricular Diastolic Dysfunction [LVDD].
- **VALVES:**
- Structurally Normal Mitral valve/ Aortic valve/Tricuspid valve/ Pulmonary valve .
No significant Valvular Stenosis.
- **Doppler findings:** AV max = 1.22 m/s, PV max = 0.91 m/s.
Trivial MR, Trivial Tricuspid regurgitation.
- **No Pulmonary Arterial Hypertension.** PASP by TRjet vel.method = 23 mmHg.
- **SEPTAE:** IAS / IVS Appear Intact.
- **IVC :** Normal in dimension and shows good inspiratory 13mm collapse.
- **OTHERS:** No e/o Pericardial effusion / vegetation.

IMPRESSION:

**NORMAL LV SYSTOLIC FUNCTION, LVEF= 60 %, NO RWMA,
NO LVH , NO LVDD , NO PAH.**

Revival Diagnostic

401, Aqua Corridor,
B/s. Star Bazar, Surat-395009
Mo. 91062-28601


DR. ADITYA BORA
MBBS,DNB,PGDCC
PHYSICIAN & CLINICAL
CARDIOLOGIST



0261 2747788, 9825947712



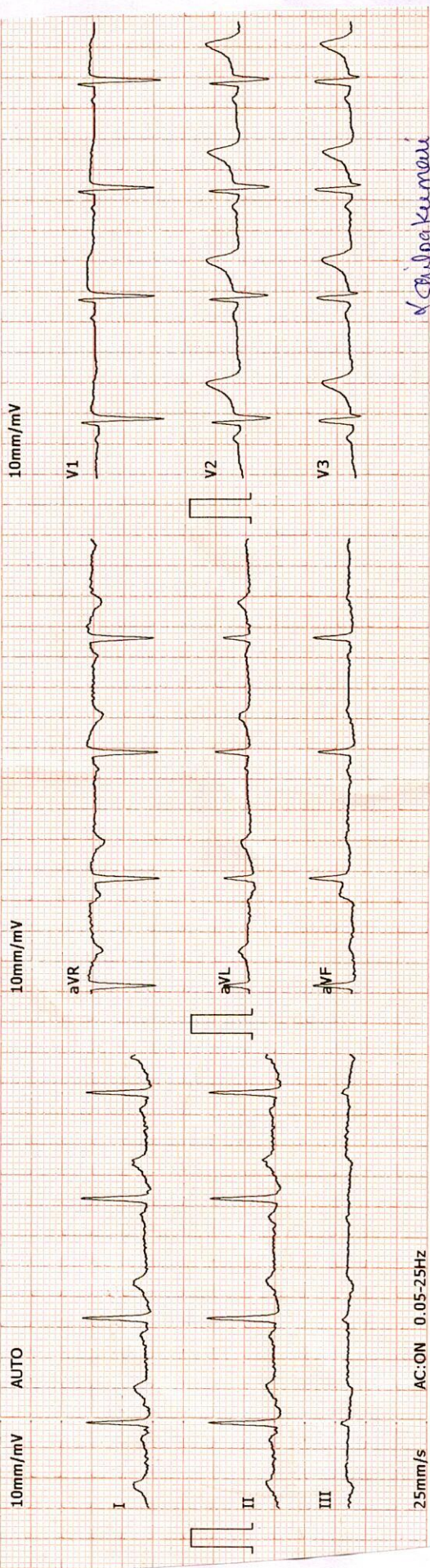
4TH Floor, Aqua Corridor, Hazira Road, Adajan Pal, Surat-395009.



revivaldiagnostics.surat@gmail.com



www.revivaldiagnostics.com



V. S. Shilpa Kumari

2023-2-25 10:28:59 ID:00004694

ID Card: _____ Name: SHILPA KUMARI Gender: Female
 Height(cm): 141
 Age: 32 BP(mmHg): /
 Weight(kg): 63

HR..... bpm 82
 P-R..... ms 106
 Q-R-S..... ms 86
 QT/QTc..... ms 366/426
 P/QRS/T AXES..... deg 43/34/43
 RV5/SV1..... mV 1.32/1.00
 RV5+SV1..... mV 2.32

*The result must be confirmed by doctor!
 Report Confirmed by: _____

10mm/mV
10mm/mV
25mm/s

I
II
III
aVR
aVL
aVF
V1
V2
V3
V4
V5
V6

AS
DR. ADITYA S. BORA
 MBBS, DNB, P.DCC
 PHYSICIAN & CLINICAL CARDIOLOGIST
 G-54906

Revival Diagnostic
 401, Aque Corridor,
 B/s. Star Bazar, Surat-395009
 Mo. 91062-28601



REVIVAL DIAGNOSTICS

Name	SHILPA KUMARI	Age/Gender	32Yrs/Female
Reg No.	1758/23	Receipt No	6125
Referred By	BOB - MEDI WHEEL(PKG10000241)	Mode of Payment	CREDIT
Collection Type	CENTER	Collection DateTime	25-Feb-2023 09:49 AM


ECG

- REPORT :

1. The rhythm is sinus.
2. Heart rate is 82 beats per minute.
3. Normal P,QRS,T wave axis.
4. Normal PR,QRS,Q.T. Duration.
5. No pathological q wave or ST-T changes seen.
6. No evidence of chamber hypertrophy or enlargement seen.

IMPRESSION : ECG WITHIN NORMAL LIMITS

Revival Diagnostic
401, Aqua Corridor,
B/s. Star Bazar, Surat-395009
Mo. 91062-28601


DR. ADITYA S. BORA
MBBS, DNB, PGDCC
PHYSICIAN & CLINICAL CARDIOLOGIST
G-54906

REVIVAL
DIAGNOSTICS



0261 2747788, 9825947712



4TH Floor, Aqua Corridor, Hazira Road, Adajan Pal, Surat-395009.



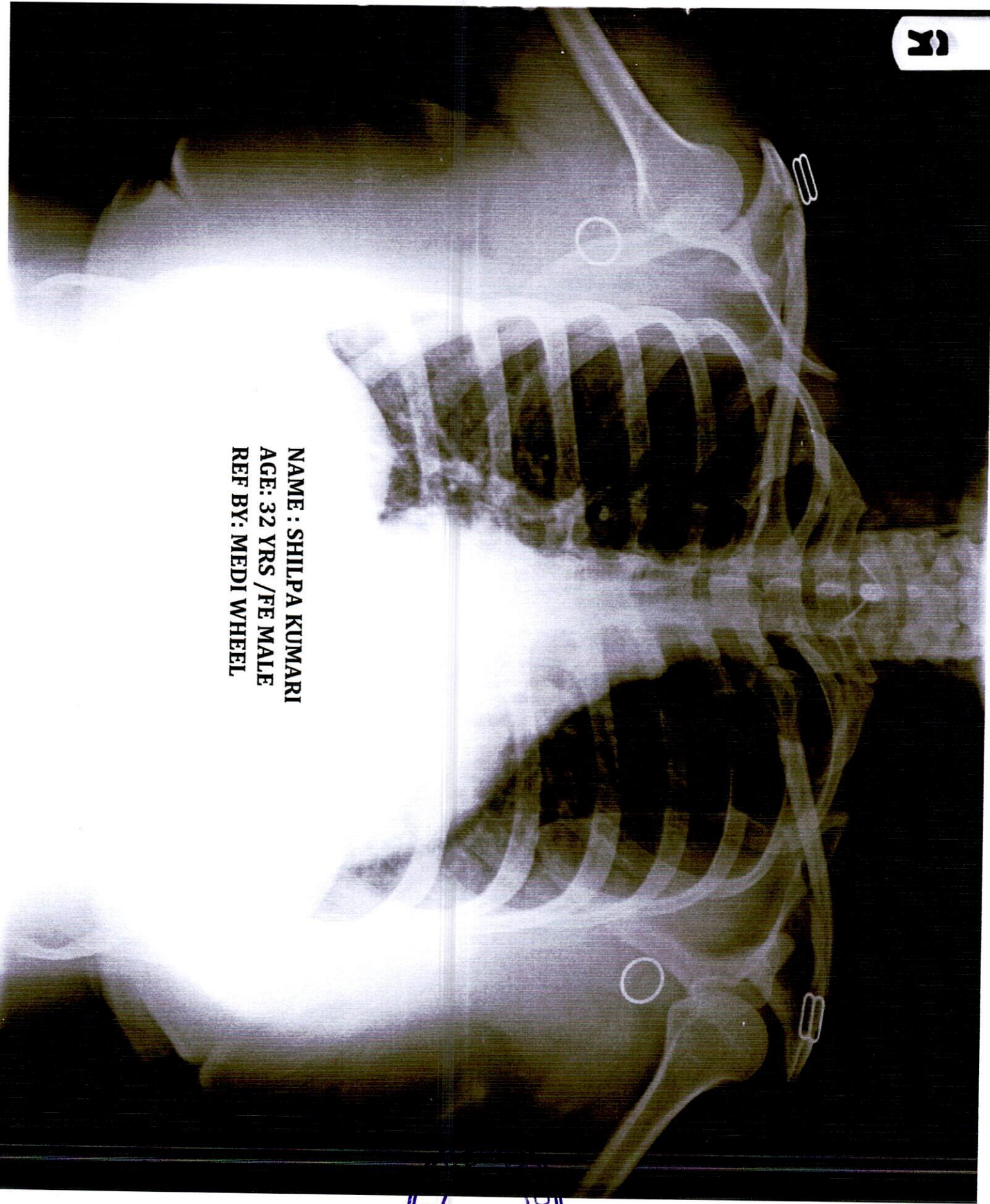
revivaldiagnostics.surat@gmail.com



www.revivaldiagnostics.com

This Medical Report Is Not Intended For Medico-legal Purposes.
Laboratory Test Results Are Subject To Technical Limitation And Should
Be Clinically Correlate For Final Diagnosis

R



NAME : SHILPA KUMARI
AGE: 32 YRS /FE MALE
REF BY: MEDI WHEEL





Name	SHILPA KUMARI	Age/Gender	32Yrs/Female
Reg No.	1758/23	Receipt No	6125
Referred By	BOB - MEDI WHEEL(PKG10000241)	Mode of Payment	CREDIT
Collection Type	CENTER	Collection DateTime	25-Feb-2023 09:49 AM

CHEST RADIOGRAPH (PA VIEW)

- Hilar shadows are within normal limits.
- Pulmonary vasculature appears normal.
- Cardiac appears normal in size.
- Both domeh of the diaphragm are smooth.
- Both costophrenic recesses are clear.
- Both lung fields appear normal.
- Visualized bones and soft tissue shadows appear normal.

IMPRESSION: NORMAL STUDY.

DR. CHIRAG K PATEL
RADIOLOGIST

Dr. Chirag K. Patel
MBBS-DMPD
Reg. No. G-23509
Revival Diagnostic
Signature
4th Floor, Aqua Corridor,
Nr. Star Bazar, Hazira Main Road,
Adajan, Surat-395009.
Mo. 97266 726683



0261 2747788, 9825947712



4TH Floor, Aqua Corridor, Hazira Road, Adajan Pal, Surat-395009.



revivaldiagnostics.surat@gmail.com



www.revivaldiagnostics.com