




Download Date: 10/01/2020
 Issue Date: 18/12/2012



**சிவா நடுசன்**  
**Siva Natesan**  
**பிறந்த நாள்/DOB: 05/06/1991**  
**ஆண்/ MALE**

**3696 0539 4593**  
**VID : 9180 3958 9153 0611**

**எனது ஆதார். எனது அடையாளம்**

N. Ho




**முகவரி:**  
**S/O நடுசன், க.எண் 2/468, கந்தினர்**  
**பிழை, சங்கரத்தலு, வைகுந்தம், சேலம்,**  
**தமிழ்நாடு - 637103**

**Address:**  
**S/O Natesan, NO 2/468, GANTHINAGAR**  
**EAST, SANKARITALUK, Vaikuntam, Salem,**  
**Tamil Nadu - 637103**



**3696 0539 4593**  
**VID : 9180 3958 9153 0611**

1947 | help@uidai.gov.in | www.uidai.gov.in



**LAB REPORT**

Patient Name : Mr. SIVAN  
Age / Gender : 32-Years / Male  
UHID ID : MH20230052211  
Doctor Name : Dr. ARUN PRAKASH

OP Report No. : INVA2112371  
Bill No. : INV2306493  
Sample Date : 09/12/2023 - 09:00 AM  
Report Date : 09/12/2023 - 09:04 PM

Test Name	Result	Units	Reference Interval
<b>HAEMATOLOGY</b>			
<b>COMPLETE BLOOD CELL COUNT(CBC)</b>			
HAEMOGLOBIN	15.5	gms/dl	male :13.0 - 17.0 female :12.0 - 15.0
PACKED CELL VOLUME	46.1	%	male : 40 - 50 female : 36 - 46
RBC COUNT	5.21	millions cells/cu.mm	female: 3.8 - 4.8 male : 4.5 - 5.5
TOTAL WBC	7,360	Cells/Cumm	4,000 - 11,000
<b>Differential Count</b>			
NEUTROPHILS	45.4	%	40 - 65
LYMPHOCYTES	45.8	%	30-50
EOSINOPHILS	2.6	%	01-06
MONOCYTES	6.2	%	1-10
BASOPHILS	0.0	%	0-2
ESR 60 MTS	05	mm	5 - 20
PLATELET COUNT	2.78	Lakhs/cumm	1.5 - 4.5
MCV	88.5	fL	76 - 96
MCH	29.7	pg	27 - 32
MCHC	33.6	gms/dl	30 - 36
<b>BLOOD GROUPING &amp; RH TYPING</b>	* O * Positive		

**Healing Hearts and Lives**



# MURUGAN HOSPITALS

HEALING HANDS



## LAB REPORT

Patient Name : Mr. SIVAN  
Age / Gender : 32-Years / Male  
UHID ID : MH20230052211  
Doctor Name : Dr. ARUN PRAKASH

OP Report No. : INVA2112371  
Bill No. : INV2306493  
Sample Date : 09/12/2023 - 09:00 AM  
Report Date : 09/12/2023 - 09:04 PM

Test Name	Result	Units	Reference Interval
<b>BIO CHEMISTRY</b>			
BLOOD SUGAR FASTING	79	mg/dl	70-110
BLOOD SUGAR POST PRANDIAL	<u>161</u>	mg/dl	80- 160
SERUM URIC ACID	5.6	mg/dl	male 3.1-7.0 , female 2.5-5.6
SERUM CREATININE	0.9	mg/dl	0.6-1.4
<b>LIPID PROFILE</b>			
TOTALCHOLESTEROL	<u>225</u>	mg/dl	< 200
TRIGLYCERIDE	148	mg/dl	< 150
HDL	48	mg/dl	35 - 80
VLDL	29	mg/dl	2 to 30
LDL	<u>148</u>	mg/dl	<130
CHOLESTEROL/ HDL RATIO	4.6	mg/dl	

### Healing Hearts and Lives





# MURUGAN HOSPITALS

HEALING HANDS



## LAB REPORT

Patient Name : Mr. SIVA.N  
Age / Gender : 32-Years / Male  
UHID ID : MH20230052211  
Doctor Name : Dr. ARUN PRAKASH

OP Report No. : INVA2112371  
Bill No. : INV2306493  
Sample Date : 09/12/2023 - 09:00 AM  
Report Date : 09/12/2023 - 09:04 PM

Test Name	Result	Units	Reference Interval
<b>LIVER FUNCTION TEST</b>			
BILLIRUBIN(TOTAL)	0.8	mg/dl	0.0 -1.0
BILLIRUBIN(DIRECT)	0.2	mg/dl	0.1- 0.30
BILLIRUBIN(INDIRECT)	0.6	mg/dl	0.2-0.8
SGOT	36	IU/L	0-38
SGPT	<u>44</u>	IU/L	0.0-40
ALKALINE PHOSPHATASE	97	IU/L	40-140 4-6Years 93-309 13-15Years 74-390
TOTAL PROTEIN	7.6	gm/dl	6.6-8.7
ALBUMIN	4.5	gm/dl	3.5 - 5.5
GLOBULIN	3.1	gm/dl	2.0-3.5
AG RATIO	1.4		
GAMMA G T	41	U/L	< 55 U/L
HBA1C	5.5	%	normal: <6.0 good control: 6.1-7.0 fair control: 7.1- 8.0 poor control:8.1 -10.0 unsatisfactory: >10.0



# MURUGAN HOSPITALS

HEALING HANDS



## LAB REPORT

Patient Name : Mr. SIVAN  
Age / Gender : 32-Years / Male  
UHID ID : MH20230052211  
Doctor Name : Dr. ARUN PRAKASH

OP Report No. : INVA2112371  
Bill No. : INV2306493  
Sample Date : 09/12/2023 - 09:00 AM  
Report Date : 09/12/2023 - 09:04 PM

Test Name	Result	Units	Reference Interval
<b>CLINICAL PATHOLOGY</b>			
URINE SUGAR (F)	Nil		
URINE SUGAR (PP)	Nil		
<b>URINE ROUTINE</b>			
COLOUR	Yellow		
APPEARANCE	Clear		
REACTION	Acidic		
SUGAR	Nil		
ALBUMIN	Nil		
<b>DEPOSITES</b>			
PUS CELLS	1 - 2	/ HPF	
EPI CELLS	2 - 3	/ HPF	
RBC COUNT	Nil	/ HPF	
CAST	Nil		
CRYSTALS	Nil		
OTHERS	Nil		

KAVIYARASAN

Verified by

\*\*\* End of Report \*\*\*



**Healing Hearts and Lives**



# MURUGAN HOSPITALS

HEALING HANDS



## LAB REPORT

NAME : MR. SIVA N  
PIN : AND23380186192  
AGE/GENDER : 32 Year(s)/Male  
REFERRED BY : Dr. ARUN PRAKASH  
CLIENT NAME : MURUGAN HOSPITAL

SAMPLE NO : 3823131401  
COLLECTED ON : 09/12/2023 03:10 PM  
RECEIVED ON : 09/12/2023 03:10 PM  
REPORTED ON : 09/12/2023 05:05 PM  
REPRINT DATE : 09/12/2023 05:05 PM

Test	Obtained Value	Units	Bio.Ref.Intervals
<b>IMMUNOASSAY</b>			
PSA(Prostate Specific Antigen) - Total, Serum (SERUM,ECLIA)	0.469	ng/mL	<= 1.4



  
DR. P. SENTHIL SELVAN, M.D.,  
BIOCHEMIST

**Healing Hearts and Lives**

264/125, Kilpauk Garden Road, Kilpauk, Chennai - 600 010.  
Phone : +91 44 4644 8989 / 75500 53335 | Email : muruganhosp@gmail.com  
Website : www.muruganhospitals.in





# MURUGAN HOSPITALS

HEALING HANDS



## LAB REPORT

NAME : MR. SIVA N  
PIN : AND23380186192  
AGE/GENDER : 32 Year(s)/Male  
REFERRED BY : Dr. ARUN PRAKASH  
CLIENT NAME : MURUGAN HOSPITAL

SAMPLE NO : 3823131401  
COLLECTED ON : 09/12/2023 03:10 PM  
RECEIVED ON : 09/12/2023 03:10 PM  
REPORTED ON : 09/12/2023 05:05 PM  
REPRINT DATE : 09/12/2023 05:05 PM

Test	Obtained Value	Units	Bio.Ref.Intervals
------	----------------	-------	-------------------

### CLINICAL PATHOLOGY

#### Stool Routine

##### General Examination (Stool)

Colour	Brownish yellow		Yellow to Brown
Form & Consistency	Semi solid		Semi solid
Mucus	Absent		Absent
Blood	Absent		Absent

##### Chemical Examination (Stool)

pH( pH strip test)	Acidic		Variable depending on food
--------------------	--------	--	----------------------------

##### Microscopy (Saline and Iodine mount) (Stool)

Cyst	Not Present		Absent
Ova	Not Present		Absent
Trophozoites	Not Present		
Red Blood Cells	Not Present	/hpf	Absent
Pus Cells	1 -2	/hpf	0-5
Epithelial Cells	Not Present	/hpf	0-4
OTHER	Not present		

-- End of Report --

G. Prayanka  
Dr. G. PRIYANKA M.D.  
CONSULTANT PATHOLOGIST  
REG. NO. | 53258

### Healing Hearts and Lives

264/125, Kilpauk Garden Road, Kilpauk, Chennai - 600 010.  
Phone : +91 44 4644 8989 / 75500 53335 | Email : muruganhosp@gmail.com  
Website : www.muruganhospitals.in



# MURUGAN HOSPITALS


HEALING HANDS



## LAB REPORT

Patient Name : Mr. SIVAN  
Age / Gender : 32-Years / Male  
UHID ID : MH20230052211  
Doctor Name : Dr. ARUN PRAKASH

OP Report No. : INVA2112371  
Bill No. : INV2306493  
Sample Date : 09/12/2023 - 09:00 AM  
Report Date : 10/12/2023 - 10:53 AM

Test Name	Result	Units	Reference Interval
<b>ENDOCRINOLOGY</b>			
T3	1.278	ng/ml	0.52-1.85
T4	10.490	ug/dl	5.0 -13.0 ug/dl
TSH	0.479	uIU/ml	0.39 - 6.16 uiu/ml
KAVIYARASAN	*** End of Report ***		
Verified by			

**Healing Hearts and Lives**

264/125, Kilpauk Garden Road, Kilpauk, Chennai - 600 010.  
Phone : +91 44 4644 8989 / 75500 53335 | Email : muruganhosp@gmail.com  
Website : www.muruganhospitals.in





# MURUGAN HOSPITALS


HEALING HANDS



## LAB REPORT

Patient Name : Mr. SIVAN  
Age / Gender : 32-Years / Male  
UHID ID : MH20230052211  
Doctor Name : Dr. ARUN PRAKASH

OP Report No. : INVA2112371  
Bill No. : INV2306493  
Sample Date : 09/12/2023 - 09:00 AM  
Report Date : 10/12/2023 - 10:49 AM

Test Name	Result	Units	Reference Interval
<b><u>BIO CHEMISTRY</u></b>			
BLOOD UREA NITROGEN	8.4	mg/dl	7-21
KAVIYARASAN	*** End of Report ***		
Verified by			

Authorized Signature  
  
**PAVITHRA**  
Pathologist  
Reg. No. - 78258

**Healing Hearts and Lives**

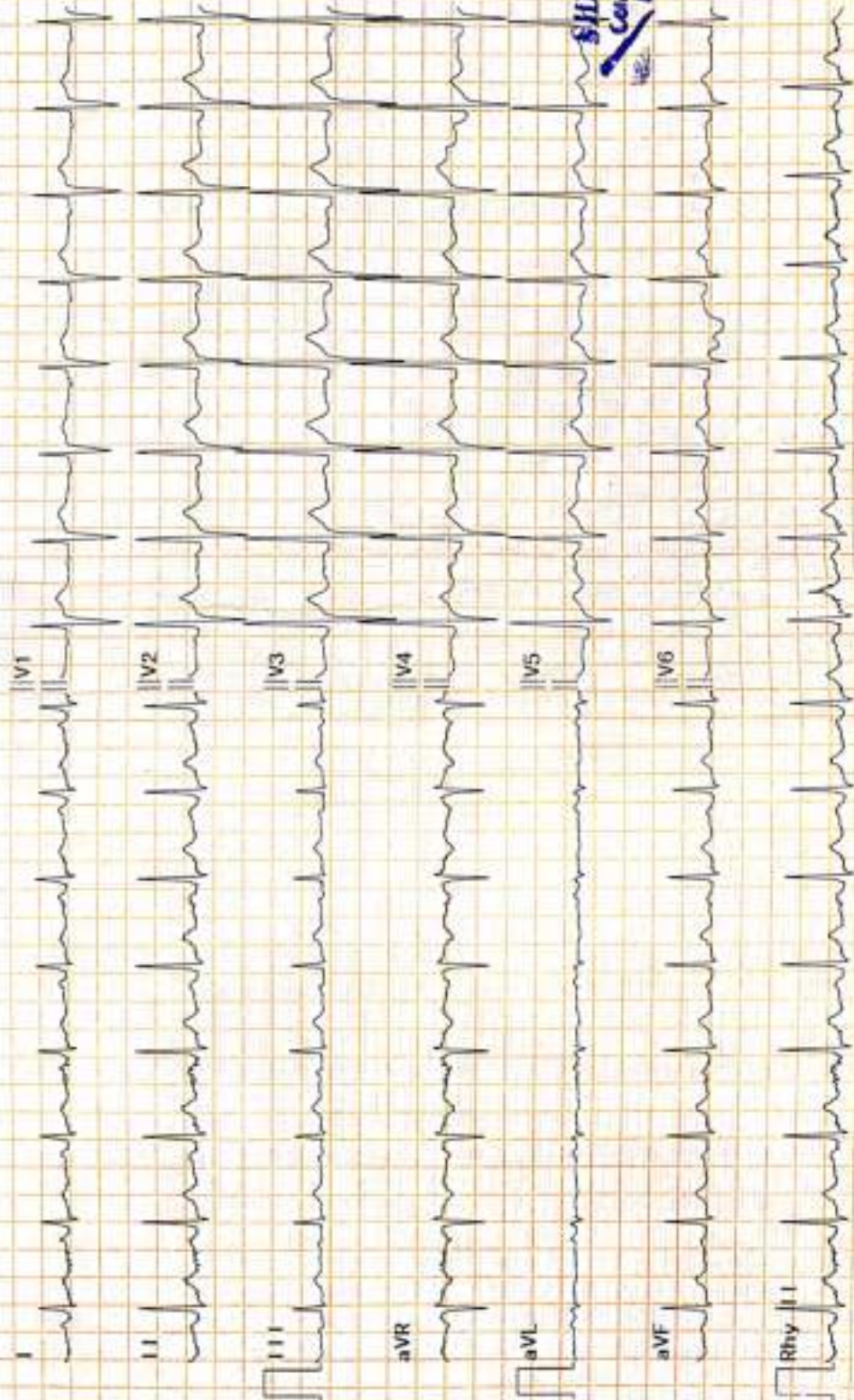
264/125, Kilpauk Garden Road, Kilpauk, Chennai - 600 010.  
Phone : +91 44 4644 8989 / 75500 53335 | Email : muruganhosp@gmail.com  
Website : www.muruganhospitals.in

ID : 2312090003  
 Name: MR. SIVA N  
 Sex : Male  
 Divisions:

Date/Time: 2023-12-09 09:46  
 Patient ID: 68091  
 Age : 32  
 Height : 171 cm  
 BP : 130/90 mmHg  
 Weight : 81 kg  
 Hospital No. :  
 Minnesota Code  
 9-4-1 (V3)

Hospital: MURUGAN HOSPITALS  
 Diagnosis Info  
 800: Sinus Rhythm  
 \*\*\*Normal ECG\*\*\*

HR : 95 bpm  
 P Dur/PR int 90/134ms  
 QRS Dur 93 ms  
 QT/QTc int 325/411 ms  
 P-QRS/T axis 45/60/64°



*Sidharthan*  
**SIDHARTHAN MD**  
 Consultant Cardiologist  
 Reg No. 62979

Diagnosis for reference, ask your doctor to confirm  
 AUTO PRINT 6X2+1R 95bpm 10 mm/mV 0.50Hz-35Hz AC 50Hz 25 mm/sec Confirmed By: *[Signature]*





# MURUGAN HOSPITALS

HEALING HANDS



## ECHO CARDIOGRAM REPORT

NAME : Mr. SIVA .N  
AGE/SEX : 32- Years / Male  
CONSULTANT : Dr. ARUN PRAKASH  
PATIENT ID : MH20230052211  
IP / OP NO : OP  
DATE : 09/ 12 /2023

### 2D PLAX (mm)

RV - 31 mm  
AO - 34 mm  
LA - 38 mm

### M-Mode (mm)

IVS - 10 mm  
PW - 08 mm  
LVD - 58 mm  
LVS - 36 mm  
EF - 64 %  
FS - 39 %

### IMPRESSION:

No Regional wall motion abnormality  
Normal LV Systolic function  
Grade I left ventricular diastolic dysfunction  
Normal RV function  
No pulmonary hypertension  
No pericardial effusion  
No obvious clot/ Vegetation.

### COLOR DOPPLER

Normal

### DOPPLER (m/sec)

MITRAL E - 0.7 m/s  
MITRAL A - 0.9 m/s  
PULMONARY - 0.8 m/s  
AORTIC - 1.0 m/s  
TRICUSPID - 0.4 m/s

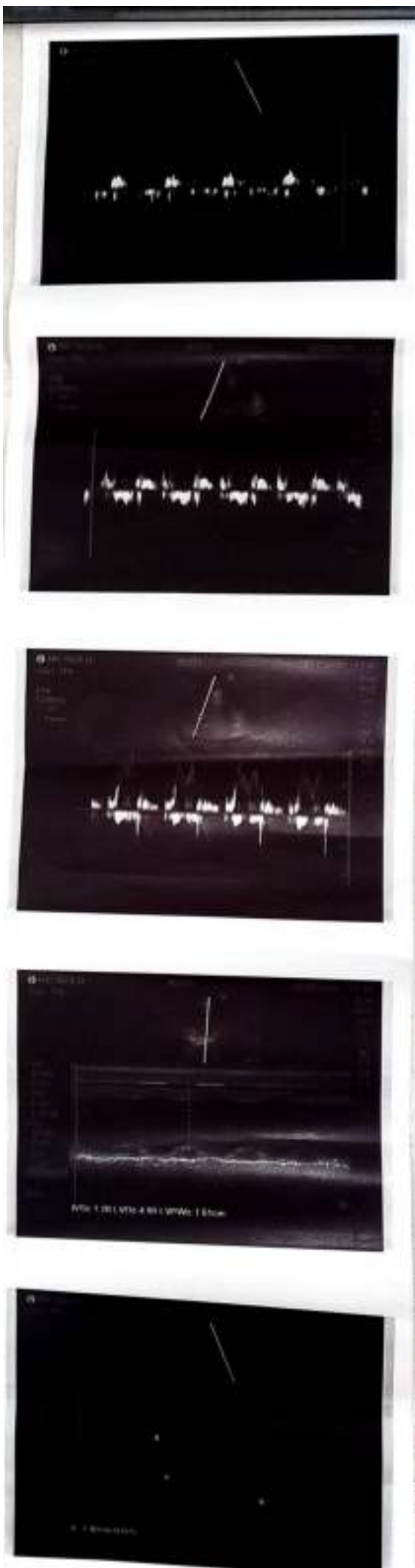

CONSULTANT CARDIOLOGIST

Healing Hearts and Lives

264/125, Kilpauk Garden Road, Kilpauk, Chennai - 600 010.  
Phone : +91 44 4644 8989 / 75500 53335 | Email : muruganhosp@gmail.com  
Website : www.muruganhospitals.in







# MURUGAN HOSPITALS

HEALING HANDS



## SCAN REPORT

NAME	: MR. SIVA.N	PATIENT ID	:MH20230052211
AGE/SEX	:32- Years / Male	IP / OP NO	:OP21066091
CONSULTANT	:DR.ARUN PRAKASH	DATE	:09/12/2023

### ULTRA SOUND SCAN OF ABDOMEN

**LIVER:** Normal in size and normal in echotexture measures 8.2 cm. No focal lesions are seen. No dilatation of intra-hepatic biliary radicals present. Hepatic veins and IVC appear normal. Portal vein is normal in caliber. Common bile duct is normal in caliber.

**GALL BLADDER:** Normal in size and wall thickness. No evidence of any calculus or mass present. No evidence of pericholecystic collections.

**PANCREAS:** Normal in size and echotexture. No focal lesions are seen. No evidence of calculi or calcifications. No evidence of pancreatic duct dilation.

**PARA AORTIC AREAS:** Aorta and IVC appear normal. No evidence of para aortic lymphadenopathy.

**SPLEEN:** Normal in size and measures-7.9cm. Normal in echotexture. No evidence of focal lesions.

**RIGHT KIDNEY:** Measures 5.5X 9.8 cm and is normal in size and echotexture. Cortico medullary differentiation is well maintained. There is no hydronephrosis or mass.

**LEFT KIDNEY:** Measures 5.5 x 8.6 cm and is normal in size and echotexture. Cortico medullary differentiation is well maintained. There is no calculus or hydronephrosis or mass.

**URINARY BLADDER:** Normal in size, contour and wall thickness. There is no evidence of calculus or mass. No vesical diverticulum present.

**PROSTATE:** Normal in size and measures- 2.4 x 3.1 x 2.6 cm echotexture. Volume- 10.8 cc.

Seminal vesicles appear normal

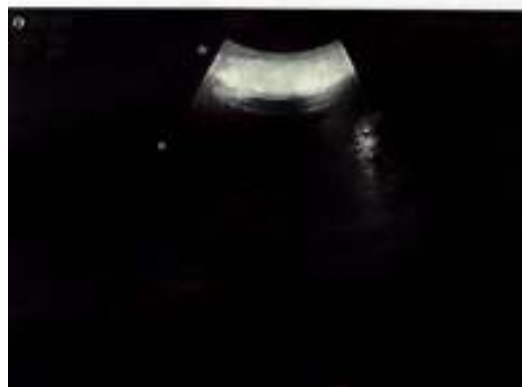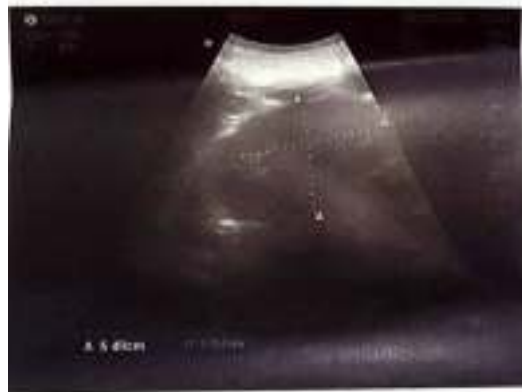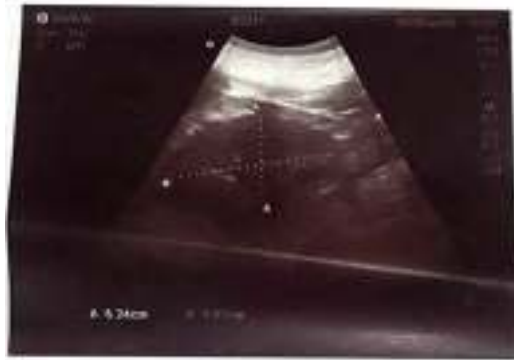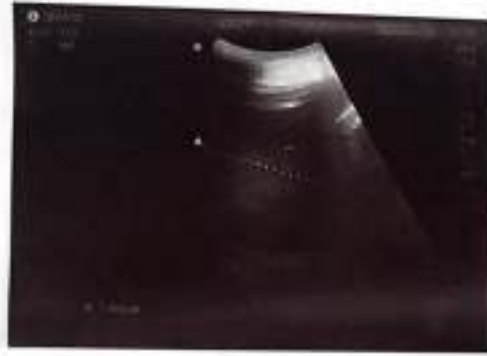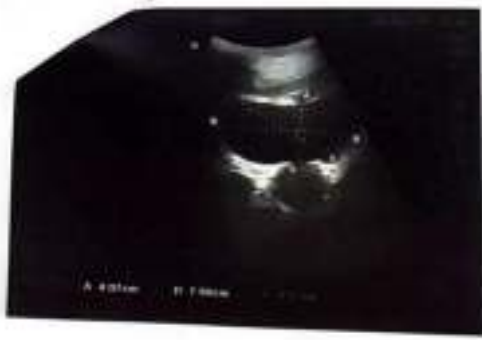No ascites present. No retroperitoneal lymphadenopathy present.

**IMPRESSION:**

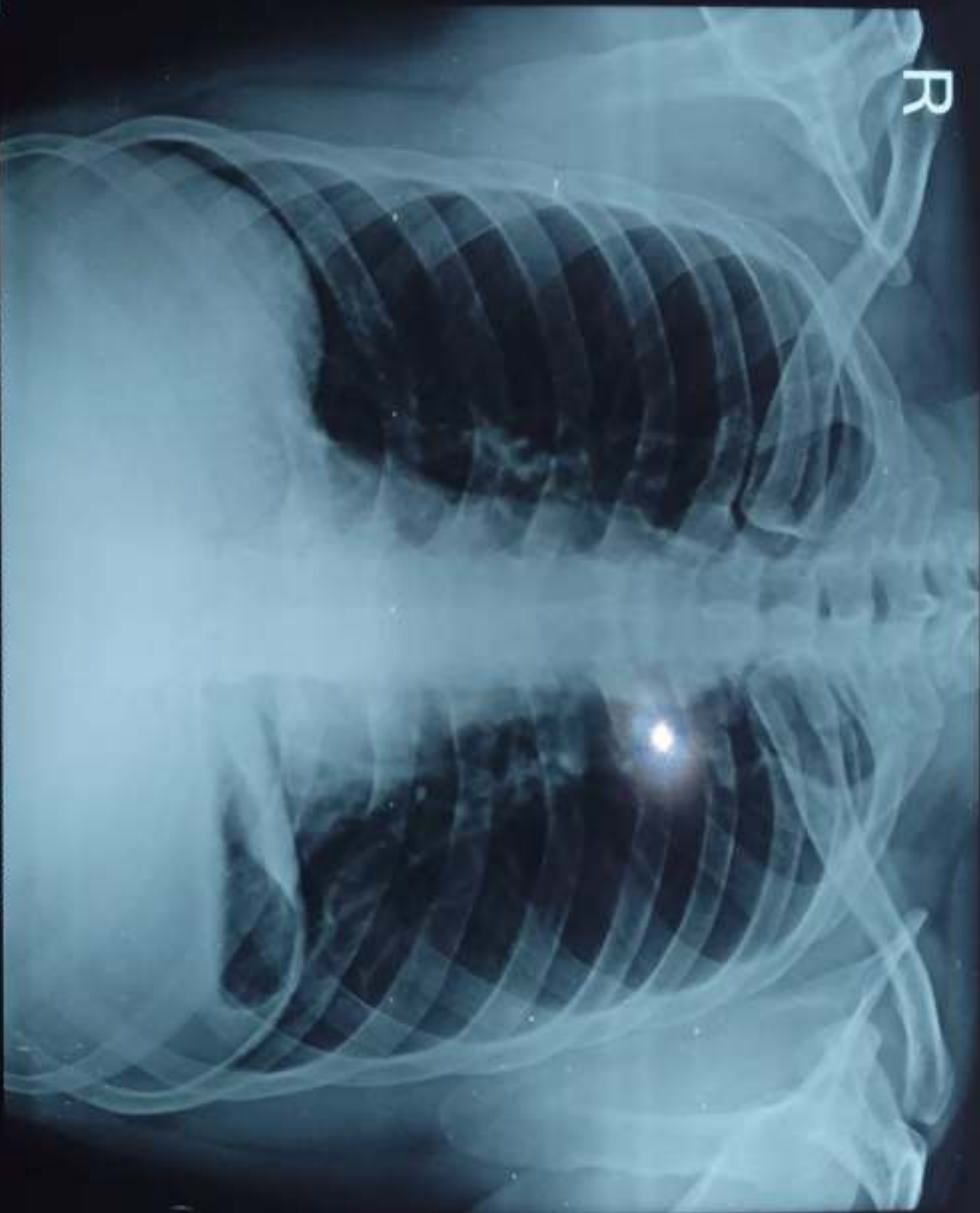
*No significant abnormality detected in the visualized abdominal organs.*

  
CONSULTANT RADIOLOGIST,





R



MR.SIVA.N 32YRS 52211 CHEST-PA 09-12-2023  
MURUGAN HOSPITALS, KILPAUK, CHENNAI-10 PH NO: 7550053335 / 46448989