

## RUBY HALL CLINIC PIMPLE SAUDAGAR

**Name: MHASKE KALAWATI .**

**Date: 04-04-2023 Time: 12:13**

**Age: 51 Gender: F Height: 147 cms Weight: 52 Kg ID: PS004831**

**Clinical History: NIL**

**Medications: NIL**

### Test Details:

**Protocol: Bruce Predicted Max HR: 169 Target HR: 143**  
**Exercise Time: 0:03:57 Achieved Max HR: 153 (91% of Predicted MHR)**  
**Max BP: 160/90 Max BP x HR: 24480 Max Mets: 4.7**

**Test Termination Criteria:**

### Protocol Details:

Stage Name	Stage Time	METS	Speed kmph	Grade %	Heart Rate bpm	BP mmHg	RPP	Max ST Level mm	Max ST Slope mV/s
Supine	00:16	1	0	0	130	120/80	15600	-2 V6	-0.6 aVR
Standing	00:06	1	0	0	121	120/80	14520	1.9 aVR	0.9 V6
HyperVentilation	00:06	1	0	0	129	120/80	15480	1.5 aVR	-0.7 aVR
PreTest	00:07	1	1.6	0	129	120/80	15480	-0.9 II	0.8 V1
Stage: 1	03:00	4.7	2.7	10	148	160/90	23680	2.3 V6	-2.4 aVR
Peak Exercise	00:57	4.6	4	12	153	160/90	24480	-5.6 V6	-2 aVR
Recovery1	01:00	1	0	0	144	160/90	23040	-2.5 V4	1.3 V6
Recovery2	01:00	1	0	0	137	160/90	21920	-2 aVR	-1.9 aVR

### Interpretation

The Patient Exercised according to Bruce Protocol for 0:03:57 achieving a work level of 4.7 METS.  
 Resting Heart Rate, initially 130 bpm rose to a max. heart rate of 153bpm (91% of Predicted Maximum Heart Rate).  
 Resting Blood Pressure of 120/80 mmHg, rose to a maximum Blood Pressure of 160/90 mmHg  
 Poor Effort Tolerance  
 Normal HR & BP Response  
 No Angina or Arrhythmias  
 No Significant ST-T Changes Noted During Exercise  
 Negative Stress Test



Ref. Doctor: ----

Doctor: DR.KEDAR KULKARNI

**SCHILLER**  
The Art of Diagnostics

( Summary Report edited by User )  
Spandan CS 10 Version:2.12.0

Name:	MHASKE KALAWATI B.	Exam Date :	04-Apr-2023 09:02
Age :	051Y	Accession:	94657090634
Gender:	F	Exam:	ABDOMEN AND PELVIS
PID:	P00000503751	Physician:	HOSPITAL CASE^^^^
OPD :			

### ULTRASOUND OF ABDOMEN AND PELVIS

Liver is enlarged in size 15.5 cm and shows increased echogenicity suggestive of grade I fatty changes. No focal lesion is seen. No intrahepatic biliary radicle dilatation seen. The portal vein and CBD appear normal.

Gall bladder is not seen (H/o Cholecystectomy).

Pancreas appears normal in size and echotexture. No focal lesion is seen.  
Spleen appears normal in size and echotexture. No focal lesion is seen.

Right kidney measures 10.3 x 4.8 cms. Left kidney measures 10.2 x 5.1 cms. Both kidneys appear normal in size, shape & echotexture. They show good cortico-medullary differentiation. There is no hydronephrosis, hydroureter or calculus seen on either side.

The urinary bladder is well distended. Wall thickness is normal. No mass lesion or calculus is seen.

Uterus not visualized ( H/o Hysterctomy) .

Visualised bowel loops are non-dilated and show normal peristalsis.  
There is no ascites or significant lymphadenopathy seen.

### IMPRESSION :

**Hepatomegaly with Grade I fatty liver.**

**Suggest : Clinical Correlation.**



DR. YATIN R. VISAVE  
CONSULTANT RADIOLOGIST  
MBBS, DMRD  
Regd. No. 090812

Date: 04-Apr-2023 15:10:58



Grant Medical Foundation  
**Ruby Hall Clinic**  
Hinjawadi

---

<b>Name:</b> MHASKE KALAWATI B .	<b>Exam Date :</b> 04-Apr-2023 09:14
<b>Age :</b> 054 Years	<b>Accession:</b> 94720143636
<b>Gender:</b> F	<b>Exam:</b> CHEST X RAY
<b>PID:</b> P00000503751	<b>Physician:</b> HOSPITAL CASE^^^^
<b>OPD :</b>	

---

Health Check

**Radiograph Chest PA View :**

Both lung fields normal.

Both costo-phrenic angles are clear.

Cardiac silhouette and aortic knuckle are normal.

Both hilar shadows and the diaphragmatic contours are normal.

Thoracic soft tissues and the rib cage normal.

**Impression :**

No significant abnormality noted.

---

**DR. YATIN R. VISAVE**  
**CONSULTANT RADIOLOGIST**  
MBBS, DMRD  
Regd. No. 090812

---

Date: 04-Apr-2023 15:06:39



Grant Medical Foundation  
**Ruby Hall Clinic**  
 Hinjawadi

Rajeev Gandhi Infotech Park, MIDC, Phase No. 1, Plot No P-33, Hinjawadi, Pune - 411057.

• Ph: 020 66999999 • Email : hinjawadi@rubyhall.com • 24 hrs Helpline - 8554802253 • Website : www.rubyhall.com

**OPHTHALMOLOGY**

NAME : **MAASKE KALAWATI B.**

AGE : **54 / R**

**R - 0.5 X 90.**

**L - 0.50 X 90.**

**Add +2.00**

1) Vision  $\left\{ \begin{array}{l} \text{unaided} \text{ --- } 6/6 \\ \text{w glasses} \text{ --- } -1 \end{array} \right.$

2) Near Vision  $\left\{ \begin{array}{l} \text{unaided} \text{ --- } 6/6 \\ \text{w glasses} \text{ --- } -1 \end{array} \right.$

3) Binocular Vision \_\_\_\_\_

4) Colour Vision **NAD**

5) Tension \_\_\_\_\_

6) Anterior Segment \_\_\_\_\_

7) Pupils \_\_\_\_\_

8) Lens \_\_\_\_\_

9) Media & Fundus \_\_\_\_\_

\_\_\_\_\_

10) Remarks \_\_\_\_\_

\_\_\_\_\_

\_\_\_\_\_

\_\_\_\_\_

\_\_\_\_\_

Date : **4/4/20**

  
 (Signature)



Grant Medical Foundation

**Ruby Hall Clinic**

Hinjawadi

Mrs. Kalawati Mhaske

54/F.

4/4/23

- Kldo DM+

C Metformin + Glimepiride 2  
(500/2)

          
FH  
          
Father - Asthma +

• No complaint

conscious oriented

BP - 142/82

P.R - a2h

S/E wds

ECA WTM



Sex: F Birth date: / / mmHg 51 years

cm kg Medication: Symptoms: History: Vent. rate 85 bpm

PR int 116 ms QRS dur 72 ms QT/QTc(E) int 374/ 417 ms

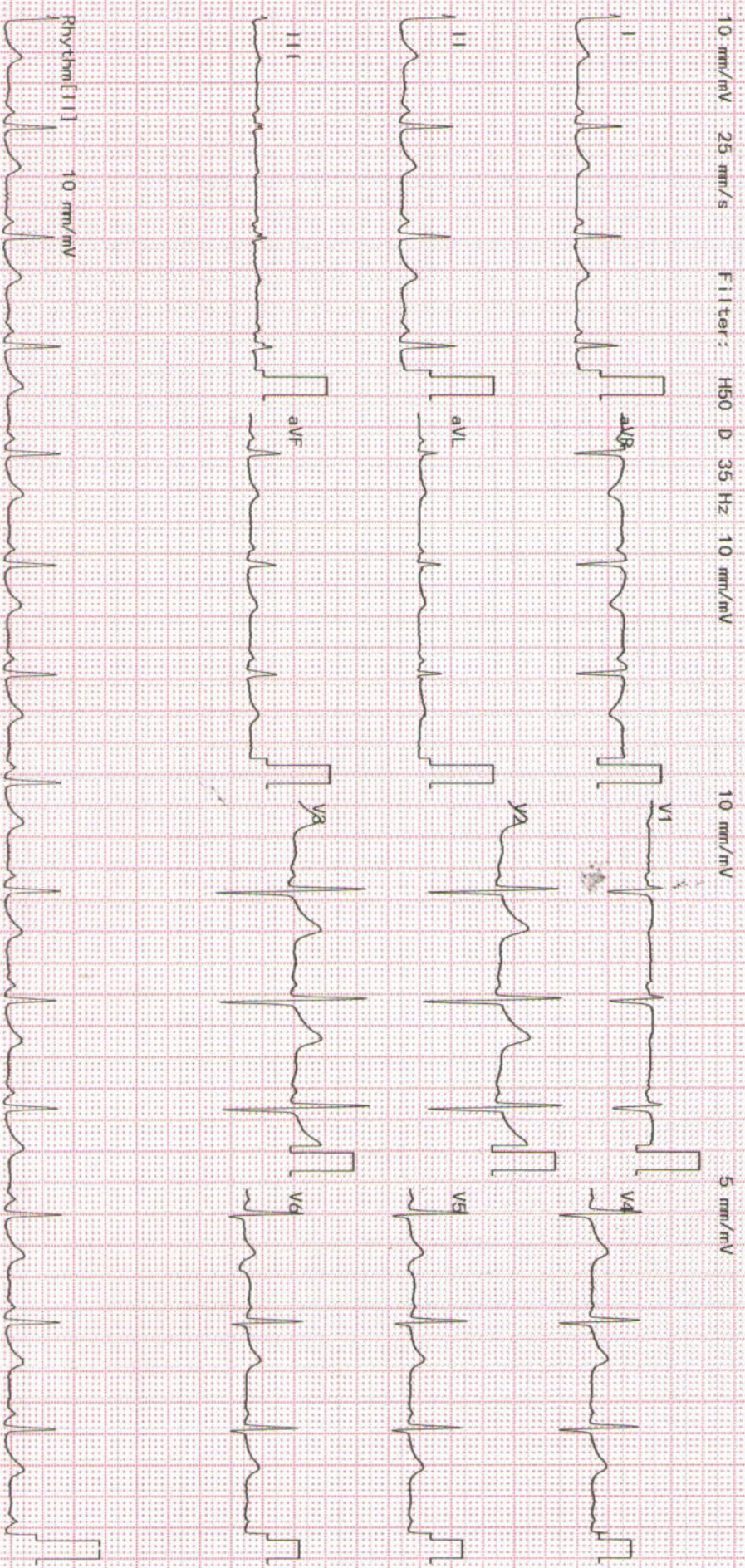
P/ORS/T axis 34/ 37/ 40 ° RV5/SV1 amp 1.90/ 0.64 mV

RV5+SV1 amp 2.54 mV

10 mm/mV 25 mm/s Filter: H50 D 35 Hz 10 mm/mV

1100 Sinus rhythm 2210 Short PR interval 9150 \*\* abnormal ECG \*\*

Unconfirmed Report Reviewed by:



2350K 02-03 04-05 Dept.:

Exam: RUBY HALL CLINIC HINJEWADI

04/04/2023-HOSPITAL CASE (00001)  
 MIHASKI KALAWATTI B  
 P00000503751 OPS00003628  
 51.11.1F-NH



Mrs. Kalawati Mhaske

Age: 54/f.

4/4/23

- H/o Hysterectomy 20 years back
- H/o gall bladder surgery 15 back.
- H/o Hernia repair 34 years back.

P/S L5

H/o TL done

PH : k/c/o DM. - 2011

o/s : A/E/B/E.

• pale - 80/m.

• P/A - soft.

P/S - Well healthy

PAP CUSE taken.