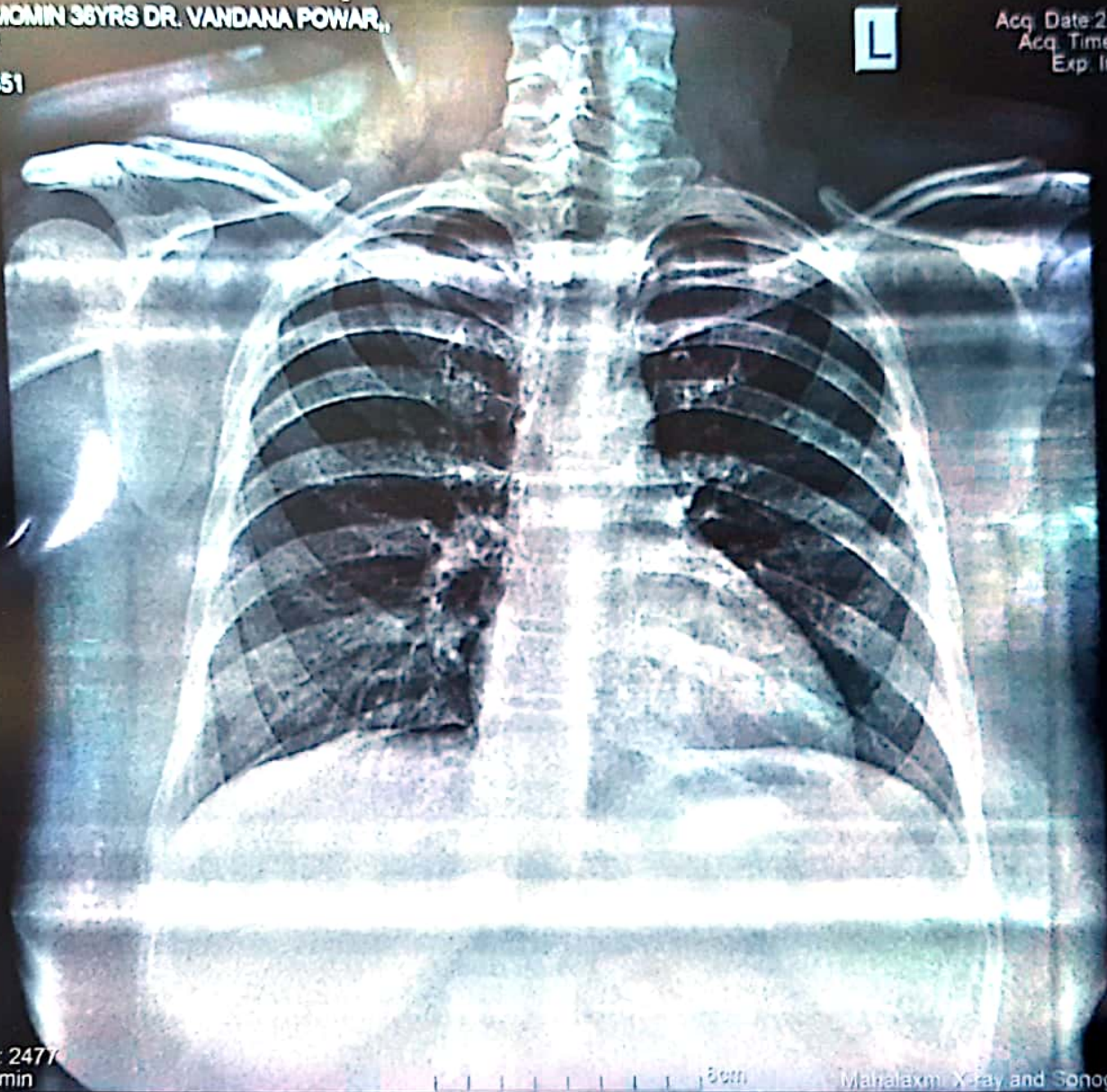


SUMAYYA MOMIN 38YRS DR. VANDANA POWAR.,  
Sex:Female  
DOB:  
ID:PAT000651

Acq. Date:25/06/2022  
Acq. Time:12:19:52  
Exp. Index:1644



8cm

CHEST  
PA  
W: 2289, L: 2477  
Tech ID:admin

8cm

Scale 0.60  
Mahalaxmi X-Ray and Sonography Clinic

MAHALAXMI X-RAY AND SONOGRAPHY CLINIC  
Eagle Pride, Below Shamrao Vitthal Bank, Mirajkar Tikti, Kolhapur. Ph. : 2542012

---

---

June 25, 2002

Name : Sumayya Mujaffar Momin  
Ref.by : Dr. Vandana Powar

F / 36 yrs


**X-Ray Chest, P.A. view :**

The lung fields are normal. The lung markings are normal.

The hilar shadows are normal. The mediastinum and the pulmonary vascularity are normal.

The domes and angles of diaphragm show no abnormality.

**Impression :** No significant abnormality is detected.

  
Vishram Mehta

June 25, 2002

Name : Sumayya Mujaffar Momin F / 36 yrs  
Ref.by : Dr. Vandana Powar

**Ultrasonography of Abdomen and pelvis : [documented ]**

**LIVER:** is mildly enlarged in size with diffuse fatty changes. The biliary radicles are normal.

**GALL BLADDER:** *cholecystectomy noted.*

**PORTA HEPATIS:** The portal vein and the common ducts are normal in caliber.

**PANCREAS:** The size, echotexture and contour of pancreas is normal.

**SPLEEN:** shows normal in size with normal texture.

**KIDNEYS:** show normal position, contour & echotexture with no hydronephrosis or calculi.

The right kidney measures 108 x 40 mm and the left measures 123 x 51 mm.

The ureters are not dilated.

The abdominal aorta, the I.V.C. and the pre and para aortic regions appear normal.

There is no ascites.

*There is an umbilical hernia; the hernial opening is 22 mm.*


**URINARY BLADDER** shows normal wall and lumen.

The uterus is anteverted and measures 59 x 31 x 44 mm. The shape, contour and textures are normal. The endometrial thickness is 4 mm.

Both ovaries are normal. There is no adnexal mass.

There is no fluid in the pouch of Douglas.

**Impression :** umbilical hernia; fatty changes in the liver.



Vishram Mehta.



