

Patient Name : Mr.SURAKARAM ANJANEYULU	Collected : 22/Oct/2024 10:17AM
Age/Gender : 37 Y 4 M 17 D/M	Received : 22/Oct/2024 02:19PM
UHID/MR No : CUPP.0000092218	Reported : 22/Oct/2024 04:45PM
Visit ID : CUPPOPV140813	Status : Final Report
Ref Doctor : Self	Sponsor Name : ARCOFEMI HEALTHCARE LIMITED
Emp/Auth/TPA ID : 22E35868	

DEPARTMENT OF BIOCHEMISTRY

ARCOFEMI - MEDIWHEEL - FULL BODY ANNUAL PLUS MALE - 2D ECHO - PAN INDIA - FY2324

Test Name	Result	Unit	Bio. Ref. Interval	Method
LIPID PROFILE , SERUM				
TOTAL CHOLESTEROL	230	mg/dL	<200	CHO-POD
TRIGLYCERIDES	115	mg/dL	<150	GPO-POD
HDL CHOLESTEROL	43	mg/dL	40-60	Enzymatic Immunoinhibition
NON-HDL CHOLESTEROL	187	mg/dL	<130	Calculated
LDL CHOLESTEROL	164	mg/dL	<100	Calculated
VLDL CHOLESTEROL	23	mg/dL	<30	Calculated
CHOL / HDL RATIO	5.35		0-4.97	Calculated
ATHEROGENIC INDEX (AIP)	0.07		<0.11	Calculated

Comment:

Reference Interval as per National Cholesterol Education Program (NCEP) Adult Treatment Panel III Report.

	Desirable	Borderline High	High	Very High
TOTAL CHOLESTEROL	< 200	200 - 239	≥ 240	
TRIGLYCERIDES	<150	150 - 199	200 - 499	≥ 500
LDL	Optimal < 100 Near Optimal 100-129	130 - 159	160 - 189	≥ 190
HDL	≥ 60			
NON-HDL CHOLESTEROL	Optimal <130; Above Optimal 130-159	160-189	190-219	>220

Dr. RAJESH BATTINA
PhD.(Biochemistry)
Consultant Biochemist

Dr. Matta Sujana Reddy
M.B.B.S.,M.D(Biochemistry)
Consultant Biochemist



SIN No:UPP241002111

This test has been performed at Apollo Health & Lifestyle Ltd, Global Reference Laboratory,Hyderabad

Patient Name : Mr.SURAKARAM ANJANEYULU	Collected : 22/Oct/2024 10:17AM
Age/Gender : 37 Y 4 M 17 D/M	Received : 22/Oct/2024 02:19PM
UHID/MR No : CUPP.0000092218	Reported : 22/Oct/2024 04:45PM
Visit ID : CUPPOPV140813	Status : Final Report
Ref Doctor : Self	Sponsor Name : ARCOFEMI HEALTHCARE LIMITED
Emp/Auth/TPA ID : 22E35868	

DEPARTMENT OF BIOCHEMISTRY

ARCOFEMI - MEDIWHEEL - FULL BODY ANNUAL PLUS MALE - 2D ECHO - PAN INDIA - FY2324

4. Associated tests for assessment of liver fibrosis - Fibrosis-4 and APRI Index.

Dr. RAJESH BATTINA
PhD.(Biochemistry)
Consultant Biochemist

Dr. Matta Sujana Reddy
M.B.B.S.,M.D(Biochemistry)
Consultant Biochemist



SIN No:UPP241002111

This test has been performed at Apollo Health & Lifestyle Ltd, Global Reference Laboratory,Hyderabad

Patient Name : Mr.SURAKARAM ANJANEYULU	Collected : 22/Oct/2024 10:17AM
Age/Gender : 37 Y 4 M 17 D/M	Received : 22/Oct/2024 02:19PM
UHID/MR No : CUPP.0000092218	Reported : 22/Oct/2024 04:45PM
Visit ID : CUPPOPV140813	Status : Final Report
Ref Doctor : Self	Sponsor Name : ARCOFEMI HEALTHCARE LIMITED
Emp/Auth/TPA ID : 22E35868	

DEPARTMENT OF BIOCHEMISTRY

ARCOFEMI - MEDIWHEEL - FULL BODY ANNUAL PLUS MALE - 2D ECHO - PAN INDIA - FY2324

Test Name	Result	Unit	Bio. Ref. Interval	Method
RENAL PROFILE/KIDNEY FUNCTION TEST (RFT/KFT) , SERUM				
CREATININE	0.70	mg/dL	0.84 - 1.25	Modified Jaffe, Kinetic
UREA	25.10	mg/dL	17-43	GLDH, Kinetic Assay
BLOOD UREA NITROGEN	11.7	mg/dL	8.0 - 23.0	Calculated
URIC ACID	4.27	mg/dL	3.5-7.2	Uricase PAP
CALCIUM	9.24	mg/dL	8.8-10.6	Arsenazo III
PHOSPHORUS, INORGANIC	3.12	mg/dL	2.5-4.5	Phosphomolybdate Complex
SODIUM	135	mmol/L	136-146	ISE (Indirect)
POTASSIUM	4.1	mmol/L	3.5-5.1	ISE (Indirect)
CHLORIDE	100	mmol/L	101-109	ISE (Indirect)
PROTEIN, TOTAL	7.06	g/dL	6.6-8.3	Biuret
ALBUMIN	4.32	g/dL	3.5-5.2	BROMO CRESOL GREEN
GLOBULIN	2.74	g/dL	2.0-3.5	Calculated
A/G RATIO	1.58		0.9-2.0	Calculated

Dr. RAJESH BATTINA
PhD.(Biochemistry)
Consultant Biochemist

Dr. Matta Sujana Reddy
M.B.B.S.,M.D(Biochemistry)
Consultant Biochemist



SIN No:UPP241002111

This test has been performed at Apollo Health & Lifestyle Ltd, Global Reference Laboratory,Hyderabad

Patient Name : Mr.SURAKARAM ANJANEYULU
 Age/Gender : 37 Y 4 M 17 D/M
 UHID/MR No : CUPP.0000092218
 Visit ID : CUPPOPV140813
 Ref Doctor : Self
 Emp/Auth/TPA ID : 22E35868

Collected : 22/Oct/2024 10:17AM
 Received : 22/Oct/2024 02:30PM
 Reported : 22/Oct/2024 03:31PM
 Status : Final Report
 Sponsor Name : ARCOFEMI HEALTHCARE LIMITED

DEPARTMENT OF CLINICAL PATHOLOGY

ARCOFEMI - MEDIWHEEL - FULL BODY ANNUAL PLUS MALE - 2D ECHO - PAN INDIA - FY2324


M. Muttavarapu Viswanath

Dr. Muttavarapu Viswanath
M.B.B.S.,M.D(Pathology)
Consultant Pathologist

SIN No:UPP241002118

This test has been performed at Apollo Health & Lifestyle Ltd, Global Reference Laboratory,Hyderabad

Page 16 of 18



Patient Name : Mr.SURAKARAM ANJANEYULU	Collected : 22/Oct/2024 10:17AM
Age/Gender : 37 Y 4 M 17 D/M	Received : 22/Oct/2024 02:30PM
UHID/MR No : CUPP.0000092218	Reported : 22/Oct/2024 04:52PM
Visit ID : CUPPOPV140813	Status : Final Report
Ref Doctor : Self	Sponsor Name : ARCOFEMI HEALTHCARE LIMITED
Emp/Auth/TPA ID : 22E35868	

DEPARTMENT OF CLINICAL PATHOLOGY

ARCOFEMI - MEDIWHEEL - FULL BODY ANNUAL PLUS MALE - 2D ECHO - PAN INDIA - FY2324

Test Name	Result	Unit	Bio. Ref. Interval	Method
URINE GLUCOSE(FASTING)	NEGATIVE		NEGATIVE	Dipstick

*** End Of Report ***

Result/s to Follow:
PERIPHERAL SMEAR

M. Muttavarapu Viswanath

Dr. Muttavarapu Viswanath
M.B.B.S.,M.D(Pathology)
Consultant Pathologist

SIN No:UPP241002112

This test has been performed at Apollo Health & Lifestyle Ltd, Global Reference Laboratory,Hyderabad

Page 18 of 18



Patient Name	: Mr. SURAKARAM ANJANEYULU	Age	: 37Yrs 4Mths 18Days
UHID	: CUPP.0000092218	OP Visit No.	: CUPPOPV140813
Printed On	: 22-10-2024 05:14 AM	Advised/Pres Doctor	: --
Department	: Radiology	Qualification	: --
Referred By	: Self	Registration No.	: --
Employer Id	: 22E35868		

DEPARTMENT OF RADIOLOGY

Liver appears normal in size 147 mm and **increased echotexture**. No focal lesion is seen. PV and CBD normal. No dilatation of the intrahepatic biliary radicals.

Gall bladder is well distended. No evidence of calculus. Wall thickness appears normal. No evidence of peri GB collection. No evidence of focal lesion is seen.

Spleen appears normal in size 93 mm. No focal lesion seen. Splenic vein appears normal.

Pancreas appears normal in echo pattern. No focal/mass lesion/calcification. No evidence of peripancreatic free fluid or collection. Pancreatic duct appears normal.

Right kidney : 107 x 52 mm appear normal in size, shape and echo pattern. CM differentiation are maintained. No calculus / hydro nephrosis seen. **Evidence of upper pole cyst measuring 16 mm.**

Left kidney : 109 x 55 mm appear normal in size, shape and echo pattern. Cortical thickness and CM differentiation are maintained. No calculus / hydro nephrosis seen.

Urinary Bladder is well distended and appears normal. No evidence of any wall thickening or abnormality. No evidence of any intrinsic or extrinsic bladder abnormality detected.

Prostate is normal in size 31 x 28 x 30 mm and echo texture. Volume measure 14 cc. No evidence of necrosis/calcification seen.

IMPRESSION :

Fatty liver.

Simple right renal cortical cyst.

Suggest – clinical correlation.

(The sonography findings should always be considered in correlation with the clinical and other investigation finding where applicable.) It is only a professional opinion, Not valid for medico legal purpose.

---End Of The Report---



Dr. K BHAGHEERATHI
MBBS,DNB Radiodiagnosis
APMC/FMR/89662
Radiology

Patient Name	: Mr. SURAKARAM ANJANEYULU	Age	: 37Yrs 4Mths 18Days
UHID	: CUPP.0000092218	OP Visit No.	: CUPPOPV140813
Printed On	: 22-10-2024 01:09 PM	Advised/Pres Doctor	: --
Department	: Radiology	Qualification	: --
Referred By	: Self	Registration No.	: --
Employer Id	: 22E35868		

DEPARTMENT OF RADIOLOGY

X-RAY CHEST PA VIEW

Both lung fields and hila are normal .

No obvious active pleuro-parenchymal lesion seen .

Both costophrenic and cardiophrenic angles are clear .

Both diaphragms are normal in position and contour .


Thoracic wall and soft tissues appear normal.

CONCLUSION :

No obvious abnormality seen

For clinical correlation.

---End Of The Report---



Dr. MATTA JYOTHIRMAI
MBBS, MDRD
APMC/FMR/74706
Radiology

Patient Name	: Mr. SURAKARAM ANJANEYULU	Age	: 37Yrs 4Mths 18Days
UHID	: CUPP.0000092218	OP Visit No.	: CUPPOPV140813
Printed On	: 22-10-2024 07:14 AM	Advised/Pres Doctor	: --
Department	: Cardiology	Qualification	: --
Referred By	: Self	Registration No.	: --
Employeer Id	: 22E35868		

DEPARTMENT OF CARDIOLOGY

Ao (ed)	3.2 CM
LA (es)	3.5 CM
LVID (ed)	4.5 CM
LVID (es)	2.8 CM
IVS (Ed)	1.0 CM
LVPW (Ed)	1.0 CM
EF	67.00%
%FD	33.00%
MITRAL VALVE :	NORMAL
AML	NORMAL
PML	NORMAL
AORTIC VALVE	NORMAL
TRICUSPID VALVE	NORMAL
RIGHT VENTRICLE	NORMAL
INTER ATRIAL SEPTUM	INTACT
INTER VENTRICULAR SEPTUM	INTACT
AORTA	NORMAL
RIGHT ATRIUM	NORMAL
LEFT ATRIUM	NORMAL
Pulmonary Valve	NORMAL
PERICARDIUM	NORMAL

COLOUR AND DOPPLER STUDIES:

PJV: 0.9

AJV: 1.3

E: 0.9 m/s

A: 0.7 m/s

IMPRESSION:-

NORMAL CARDIAC CHAMBERS.

NO RWMA.

GOOD LV/ RV FUNCTION.

NO MR/ AR/ TR/ PAH.

NO CLOT.

NO PERICARDIAL EFFUSION.

---End Of The Report---



Dr. CH VENKATESHAM
MBBS, PGDCC
41992
Cardiology



భారత ప్రభుత్వం

Government of India



సూరకారం అంజనేయులు
Surakaram Anjaneyulu

పుట్టిన సంవత్సరం / Year of Birth: 1987
పురుషుడు / Male



5414 7189 7328

ఆధార్ - సామాన్యుని హక్కు

Apollo Clinic Uppal

From: Anjaneyulu Surakaram <anji.surakaram@gmail.com>
Sent: Tuesday, October 22, 2024 09:40 AM
To: Apollo Clinic Uppal
Subject: Fwd: Your appointment is confirmed

----- Forwarded message -----

From: <noreply@apolloclinics.info>
Date: Mon, 21 Oct 2024, 4:28 pm
Subject: Your appointment is confirmed
To: <anji.surakaram@gmail.com>
Cc: <uppal@apolloclinic.com>, <nishanth.reddy@apolloclinic.com>, <syamsunder.m@apollohl.com>



Dear MR. SURAKARAM ANJANEYULU,

Greetings from Apollo Clinics,

Your corporate health check appointment is confirmed at **UPPAL clinic** on **2024-10-22** at **07:45-08:00**.

Payment Mode	
Corporate Name	ARCOFEMI HEALTHCARE LIMITED
Agreement Name	[ARCOFEMI MEDIWHEEL MALE AHC CREDIT PAN INDIA OP AGREEMENT]
Package Name	[ARCOFEMI - MEDIWHEEL - FULL BODY ANNUAL PLUS MALE - 2D ECHO - PAN INDIA - FY2324]

"Kindly carry with you relevant documents such as HR issued authorization letter and or appointment confirmation mail and or valid government ID proof and or company ID card and or voucher as per our agreement with your company or sponsor."

Note: Video recording or taking photos inside the clinic premises or during camps is not allowed and would attract legal consequences.

Note: Also once appointment is booked, based on availability of doctors at clinics tests will happen, any pending test will happen based on doctor availability and clinics will be updating the same to customers.

Instructions to be followed for a health check:

1. Please ensure you are on complete fasting for 10-To-12-Hours prior to check.
2. During fasting time do not take any kind of alcohol, cigarettes, tobacco or any other liquids (except Water) in the morning. If any medications taken, pls inform our staff before health check.
3. Please bring all your medical prescriptions and previous health medical records with you.
4. Kindly inform our staff, if you have a history of diabetes and cardiac problems.

For Women:

1. Pregnant women or those suspecting are advised not to undergo any X-Ray test.
2. It is advisable not to undergo any health check during menstrual cycle.

For further assistance, please call us on our Help Line #: 1860 500 7788.

Clinic Address: APOLLO CLINIC NEAR PILLAR NO 91, BESIDE RAMRAJ COTTON SHOWROOM,CANARA NAGAR BUS STOP, WARANGAL HIGHWAY,.

Contact No: (040) 49503373 -74/.

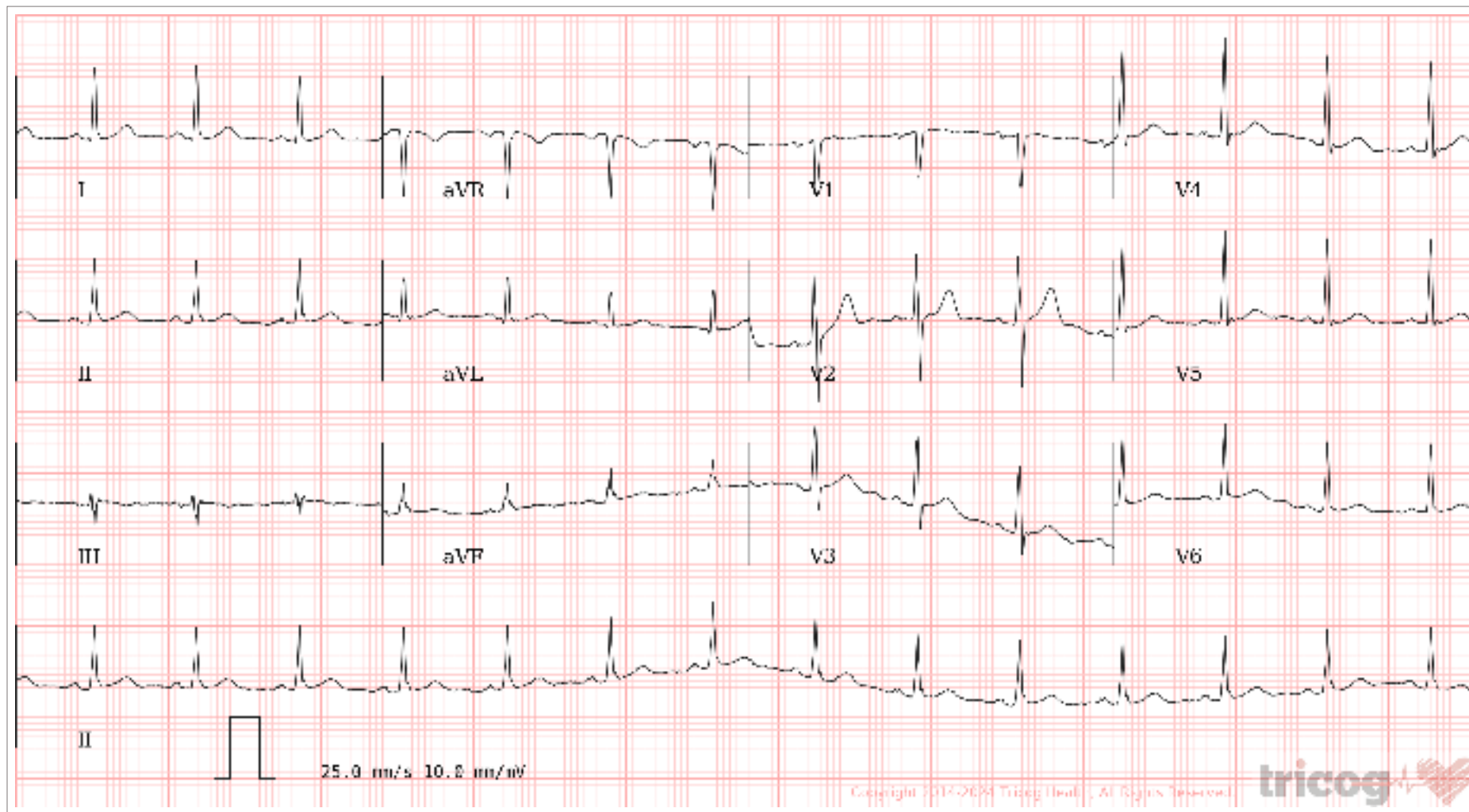

P.S: Health Check-Up may take 4 - 5hrs for completion on week days & 5 - 6hrs on Saturdays, kindly plan accordingly, Doctor Consultation will be completed after all the Reports are ready.

Warm Regards,
Apollo Clinic



Age / Gender: 37/Male
Patient ID: 0000092218
Patient Name: Mr Anjaneyulu

Date and Time: 22nd Oct 24 11:03 AM



AR: 89bpm VR: 89bpm QRSD: 78ms QT: 344ms QTcB: 418ms PRI: 138ms P-R-T: 29° 23° 21°

ECG Within Normal Limits: Sinus Rhythm, Normal ECG, correlate clinically. Please correlate clinically.

Disclaimer: Analysis in this report is based on ECG alone and should only be used as an adjunct to clinical history, symptoms and results of other invasive and non-invasive tests and must be interpreted by a qualified physician.

REPORTED BY



DR VINAY

72045

Patient Name	: Mr. SURAKARAM ANJANEYULU	Age	: 37Yrs 4Mths 17Days
UHID	: CUPP.0000092218	OP Visit No.	: CUPPOPVI40813
Printed On	: 22-10-2024 12:44 PM	Advised/Pres Doctor	: --
Department	: Cardiology	Qualification	: --
Referred By	: Self	Registration No.	: --
Employer Id	: 22E35868		

DEPARTMENT OF CARDIOLOGY

Ao (ed)	3.2 CM
LA (es)	3.5 CM
LVID (ed)	4.5 CM
LVID (es)	2.8 CM
IVS (Ed)	1.0 CM
LVPW (Ed)	1.0 CM
EF	67.00%
%FD	33.00%
MITRAL VALVE :	NORMAL
AML	NORMAL
PML	NORMAL
AORTIC VALVE	NORMAL
TRICUSPID VALVE	NORMAL
RIGHT VENTRICLE	NORMAL
INTER ATRIAL SEPTUM	INTACT
INTER VENTRICULAR SEPTUM	INTACT
AORTA	NORMAL
RIGHT ATRIUM	NORMAL
LEFT ATRIUM	NORMAL
Pulmonary Valve	NORMAL
PERICARDIUM	NORMAL

COLOUR AND DOPPLER STUDIES:

PJV: 0.9

AJV: 1.3

E: 0.9 m/s

A: 0.7 m/s

IMPRESSION:-

NORMAL CARDIAC CHAMBERS.

NO RWMA.

GOOD LV/ RV FUNCTION.

NO MR/ AR/ TR/ PAH.

NO CLOT.

NO PERICARDIAL EFFUSION.

---End Of The Report---



Dr. CH VENKATESHAM
MBBS,PGDCC
41992
Cardiology

PHYSICAL EXAMINATION FORM

Name	Mr. SURAKARAM ANJANEYULU	Age & Gender	37 Y /M
UHID	CUPP.0000092218	DATE	22.10.2024

Vitals	
Height (CM)	162
Weight (KG)	83
BMI	31
BP	140/80
Pulse	93
SPO2 (%)	NA
Temperature	NA

Kondapur | Manikonda | Nallakunta | Nizampet | Uppal)

Online appointments: www.apolloclinic.com

CERTIFICATE OF MEDICAL FITNESS

This is to certify that I have conducted the clinical examination

of Mr. S. Anjanayulu on 23/10/24.

After reviewing the medical history and on clinical examination it has been found that he/she is

	Tick
<ul style="list-style-type: none"> • Medically Fit 	<input type="checkbox"/>
<ul style="list-style-type: none"> • Fit with restrictions/recommendations <p>Though following restrictions have been revealed, in my opinion, these are not impediments to the job.</p> <p>1. <u>High Sugars.</u></p> <p>2. _____</p> <p>3. _____</p> <p>However the employee should follow the advice/medication that has been communicated to him/her.</p> <p>Review after _____</p>	<input checked="" type="checkbox"/>
<ul style="list-style-type: none"> • Currently Unfit. Review after _____ recommended 	<input type="checkbox"/>
<ul style="list-style-type: none"> • Unfit 	<input type="checkbox"/>


DR. KOPPULA TRIVENI
M.B.B.S.
 Dr. T.S.M.C. FMR/05078
 Medical Officer (Family Physician)

This certificate is not meant for medico-legal purposes

Apollo Health and Lifestyle Limited

ICW - UBS110TG200PLC046080 | Regd. Office: 7-1-617/A, 7th Floor, Hospital Towers, Amravati, Hyderabad-500016, Telangana. | Email: icw@apollohospitals.com

APOLLO CLINICS NETWORK TELANGANA @ AP

Hyderabad (AS Rao Nagar) | Chanda Nagar | Jubilee Hills | Kondapur | Menikonda | Narthala | Nizampet | Uppal | Vizag (Svethamika Pet)

Online appointments: www.apolloclinic.com

TO BOOK AN APPOINTMENT

1860 500 7788

POWER PRESCRIPTION

NAME: S. Anjaneyulu

GENDER: M/F

DATE: 22/10/24

AGE: 34

UHID: 92218

RIGHT EYE

LEFT EYE

	SPH	CYL	AXIS	VISION
DISTANCE	0.75	—	—	6/6
NEAR				N6

	SPH	CYL	AXIS	VISION
DISTANCE	0.50	—	—	6/6
NEAR				N6

COLOUR VISION : BC: normal

DIAGNOSIS :

OTHER FINDINGS :

INSTRUCTIONS :


SIGNATURE