

MYSORE-BALLAL CIRCLE



--- A MEDALL COMPANY ---

Date 11-Jun-2022 9:26 AM

Customer Name : **MR.SADASHIVAMURTHY**DOB : **16 Jul 1955**Ref Dr Name : **MediWheel**Age : **66Y/MALE**Customer Id : **MED111149078**Visit ID : **712217638**

Email Id :

Phone No : **9731020708**Corp Name : **MediWheel**

Address :

Package Name : **Mediwheel Full Body Health Checkup Male Above 40**

S.No	Modality	Study	Accession No	Time	Seq	Signature
1	LAB	BLOOD UREA NITROGEN (BUN)				
2	LAB	GLUCOSE - FASTING				
3	LAB	GLUCOSE - POSTPRANDIAL (2 HRS)				
4	LAB	GLYCOSYLATED HAEMOGLOBIN (HbA1c)				
5	LAB	LIPID PROFILE				
6	LAB	LIVER FUNCTION TEST (LFT)				
7	LAB	URIC ACID				
8	LAB	URINE GLUCOSE - FASTING				
9	LAB	URINE GLUCOSE - POSTPRANDIAL (2 Hrs)				
10	LAB	COMPLETE BLOOD COUNT WITH ESR				
11	LAB	THYROID PROFILE/ TFT(T3, T4, TSH)				
12	LAB	TOTAL PROSTATE SPECIFIC ANTIGEN - PSA				
13	LAB	STOOL ANALYSIS - ROUTINE				
14	LAB	URINE ROUTINE				
15	LAB	CREATININE				

✓ ER is normal in size and shows slightly increased echotexture

Patient Details Print Page

		BLOOD GROUP & RH TYPE (Forward Reverse)			
	LAB	BUN/CREATININE RATIO	✓		
18	OTHERS	physical examination	MYS2686781102651		
19	US	ULTRASOUND ABDOMEN	MYS2686781103462		
20	OTHERS	Treadmill / 2D Echo ✓	MYS2686781127528		
21	OTHERS	Dental Consultation	MYS2686781134969		
22	OTHERS	EYE CHECKUP ✓	MYS2686781135592		
23	X-RAY	X RAY CHEST ✓	MYS2686781145199		
24	OTHERS	Consultation Physician	MYS2686781148004		
25	ECHO	ELECTROCARDIOGRAM ECG	MYS2686781149333		

done.

Bp - 130/90 mmHg
pulse 83 bpm
wg! - 87
Ht! - 78
wg! - 34
Ht! - 38

Registered By
(A.JAYASHREE)

Customer Name	MR.SADASHIVAMURTHY	Customer ID	MED111149078
Age & Gender	56Y/MALE	Visit Date	11/06/2022
Ref Doctor	MediWheel		

ABDOMINO-PELVIC ULTRASONOGRAPHY

LIVER is normal in size and shows slightly increased echotexture.

No evidence of focal lesion or intrahepatic biliary ductal dilatation.

Hepatic and portal vein radicals are normal.

GALL BLADDER show normal shape and has clear contents.

Gall bladder wall is of normal thickness. CBD is of normal calibre.

PANCREAS has normal shape, size and uniform echopattern.

No evidence of ductal dilatation or calcification.

SPLEEN show normal shape, size and echopattern.

KIDNEYS move well with respiration and have normal shape, size and echopattern.

Cortico- medullary differentiations are well made out.

No evidence of calculus or hydronephrosis.

	Bipolar length (cms)	Parenchymal thickness (cms)
Right Kidney	10.0	1.9
Left Kidney	10.5	1.7

URINARY BLADDER partially distended.

PROSTATE shows normal shape, size and echopattern.


No evidence of ascites.

IMPRESSION:

- **GRADE I FATTY CHANGES IN LIVER.**

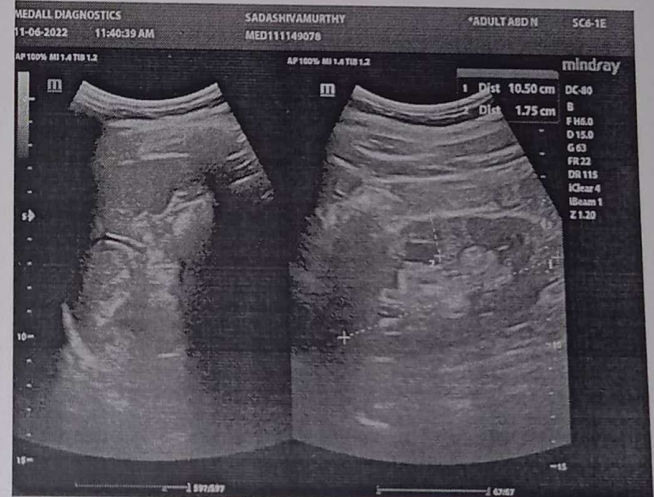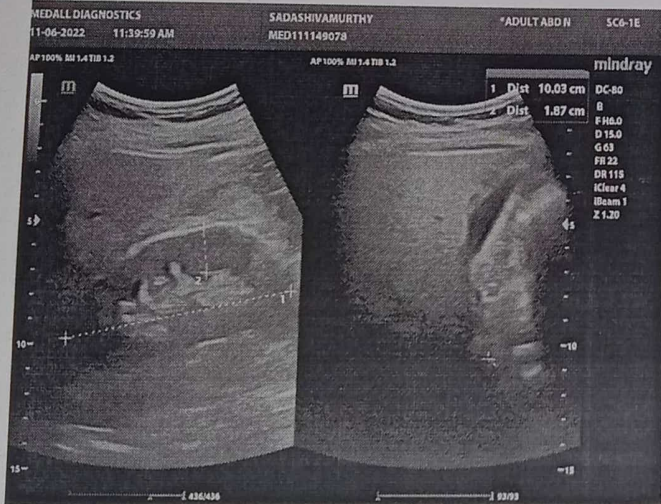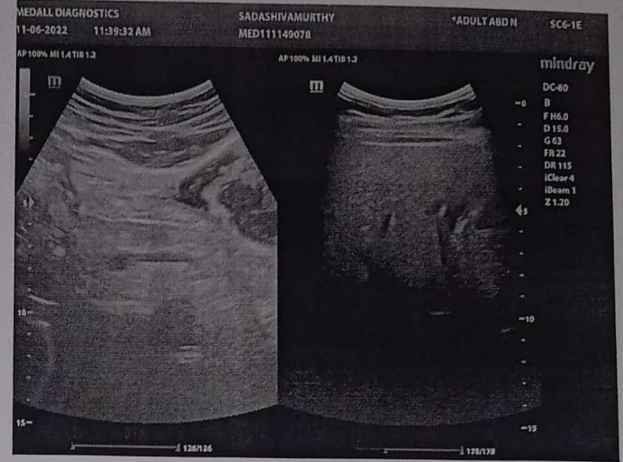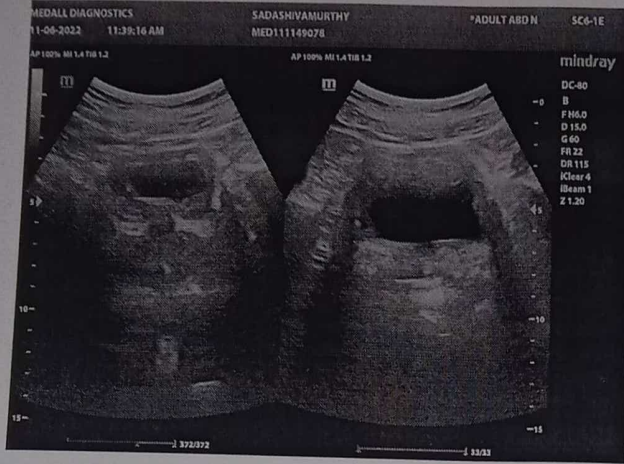CONSULTANT RADIOLOGISTS

DR. ANITHA ADARSH
MB/SV



DR. MOHAN B

Customer Name	MR.SADASHIVAMURTHY	Customer ID	MED11149078
Age & Gender	56Y/MALE	Visit Date	11/06/2022
Ref Doctor	MediWheel		





medall
DIAGNOSTICS
experts who care

Customer Name	MR.SADASHIVAMURTHY	Customer ID	MED111149078
Age & Gender	56Y/MALE	Visit Date	11/06/2022
Ref Doctor	MediWheel		

2 D ECHOCARDIOGRAPHIC STUDY

M mode measurement:

AORTA	:	2.9cms
LEFT ATRIUM	:	3.2cms
LEFT VENTRICLE (DIASTOLE)	:	4.5cms
(SYSTOLE)	:	2.8cms
VENTRICULAR SEPTUM (DIASTOLE)	:	1.0cms
(SYSTOLE)	:	1.3cms
POSTERIOR WALL (DIASTOLE)	:	0.9cms
(SYSTOLE)	:	1.2cms
EDV	:	75ml
ESV	:	30ml
FRACTIONAL SHORTENING	:	37%
EJECTION FRACTION	:	60%
RVID	:	1.6cms

DOPPLER MEASUREMENTS:

MITRAL VALVE	:	'E' - 0.71m/s	'A' - 0.60 m/s	NO MR
AORTIC VALVE	:	0.98m/s		NO AR
TRICUSPID VALVE	:	'E' - 0.81m/s	'A' - 0.42 m/s	NO TR
PULMONARY VALVE	:	0.78m/s		NO PR

name	MR.SADASHIVAMURTHY	Customer ID	MED111149078
Age & Gender	56Y/MALE	Visit Date	11/06/2022
Ref Doctor	MediWheel		

2D ECHOCARDIOGRAPHY FINDINGS:

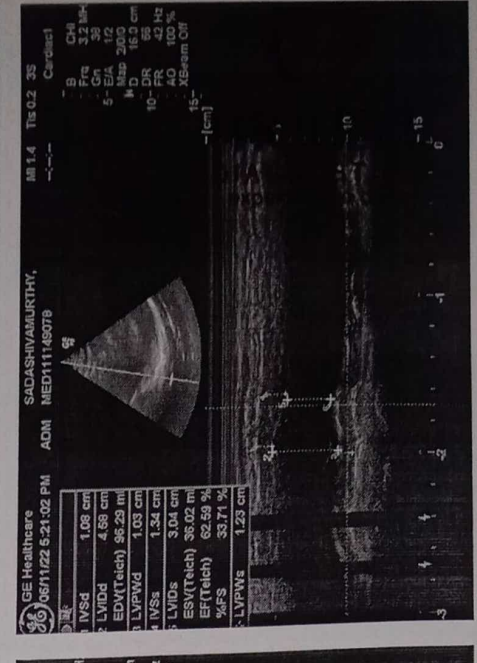
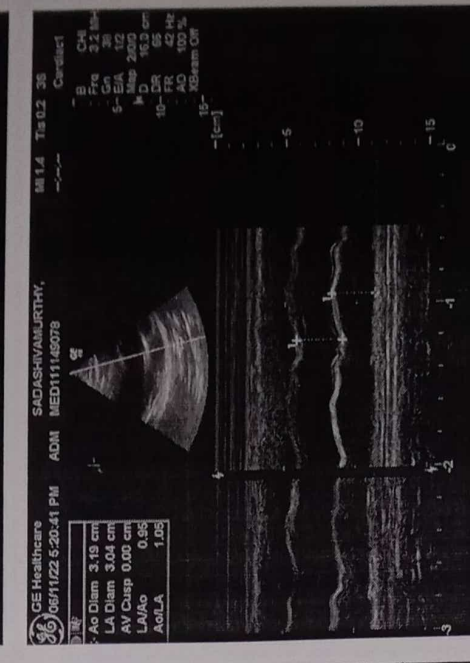
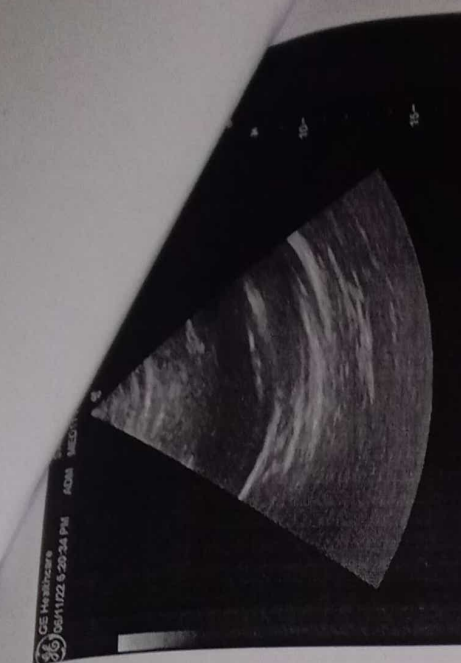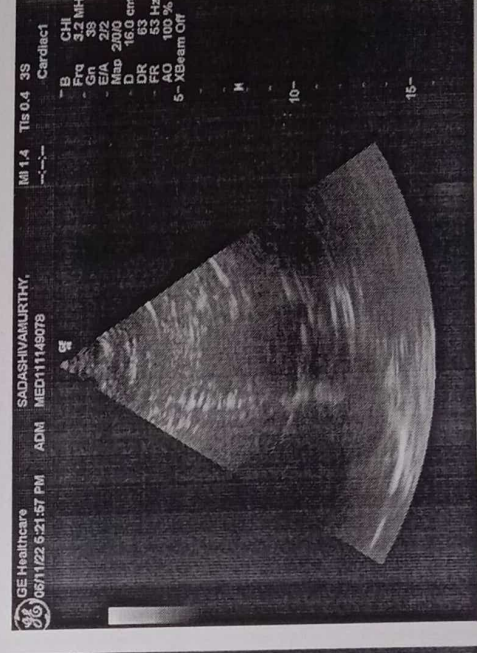
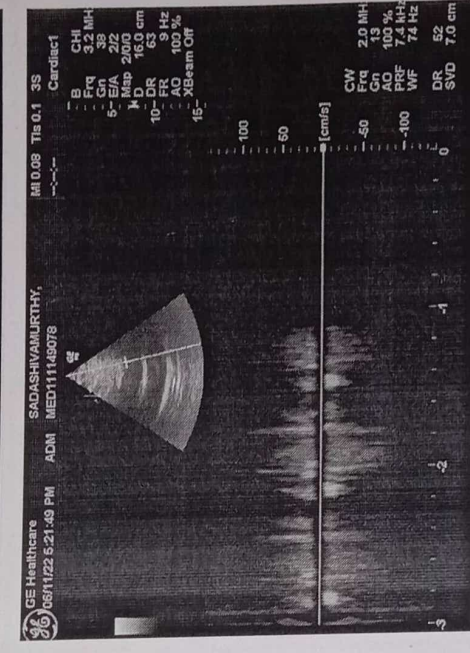
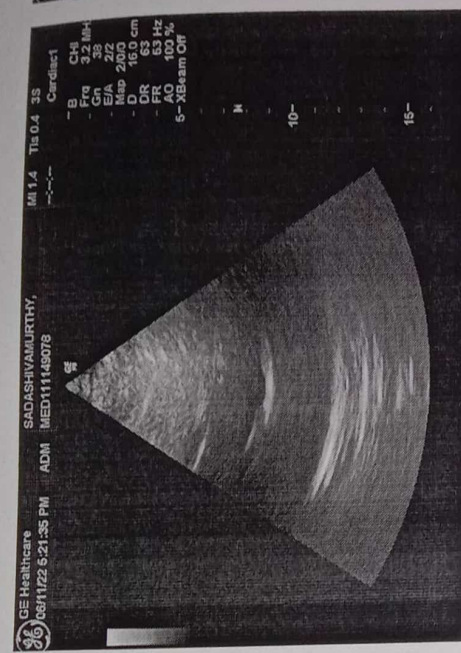
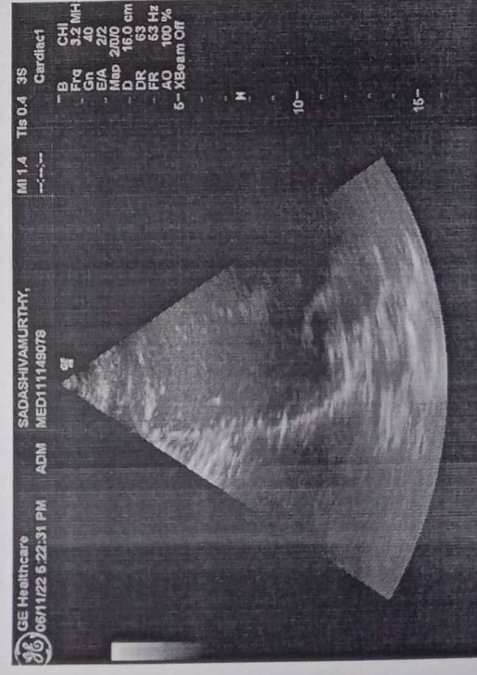
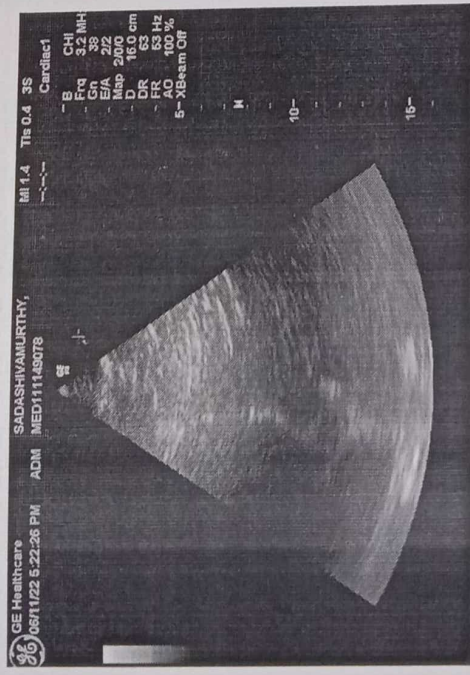
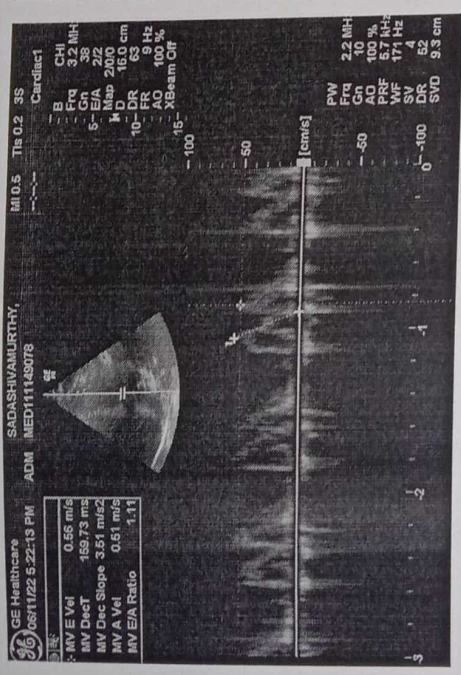
Left ventricle	: Normal size, Normal systolic function. No regional wall motion abnormalities.
Left Atrium	: Normal.
Right Ventricle	: Normal.
Right Atrium	: Normal.
Mitral valve	: Normal, No mitral valve prolapsed.
Aortic valve	: Normal, Trileaflet.
Tricuspid valve	: Normal.
Pulmonary valve	: Normal.
IAS	: Intact.
IVS	: Intact.
Pericardium	: No pericardial effusion.

IMPRESSION:

- NORMAL SIZED CARDIAC CHAMBERS.
- NORMAL LV SYSTOLIC FUNCTION. EF: 60%.
- NO REGIONAL WALL MOTION ABNORMALITIES.
- NORMAL VALVES.
- NO CLOTS/ PERICARDIAL EFFUSION VEGETATION.



DR. NIKHIL B
INTERVENTIONAL CARDIOLOGIST
NB/SA



12:20pm

MEPAU



NETHRADHAMA SUPER SPECIALITY EYE HOSPITAL

(A Unit of Nethradhama Hospitals Pvt. Ltd.)

OPD SHEET

Date: 11/6/22

Patient's Name: Mr. Sadasivaramuethy
56/M

OP No. 1197849
12:15PM

NCI < 13
12

Dr. Richa

MBBS, DOMS, DNB
Consultant-Vitreo Retina
KMC Reg. No. : 105719

BCVA < 6/6, NG
6/6, NG

Colour vision - 38/38 - Normal on
Ishihare chart.

ant segment - BE - WMR

fundus BE - PP - CD - 0.3
RR +.

patient not willing for dilation.

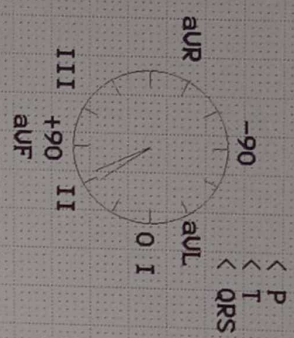
ado

alam

R/A 1 yr / SDS

AGE: 56

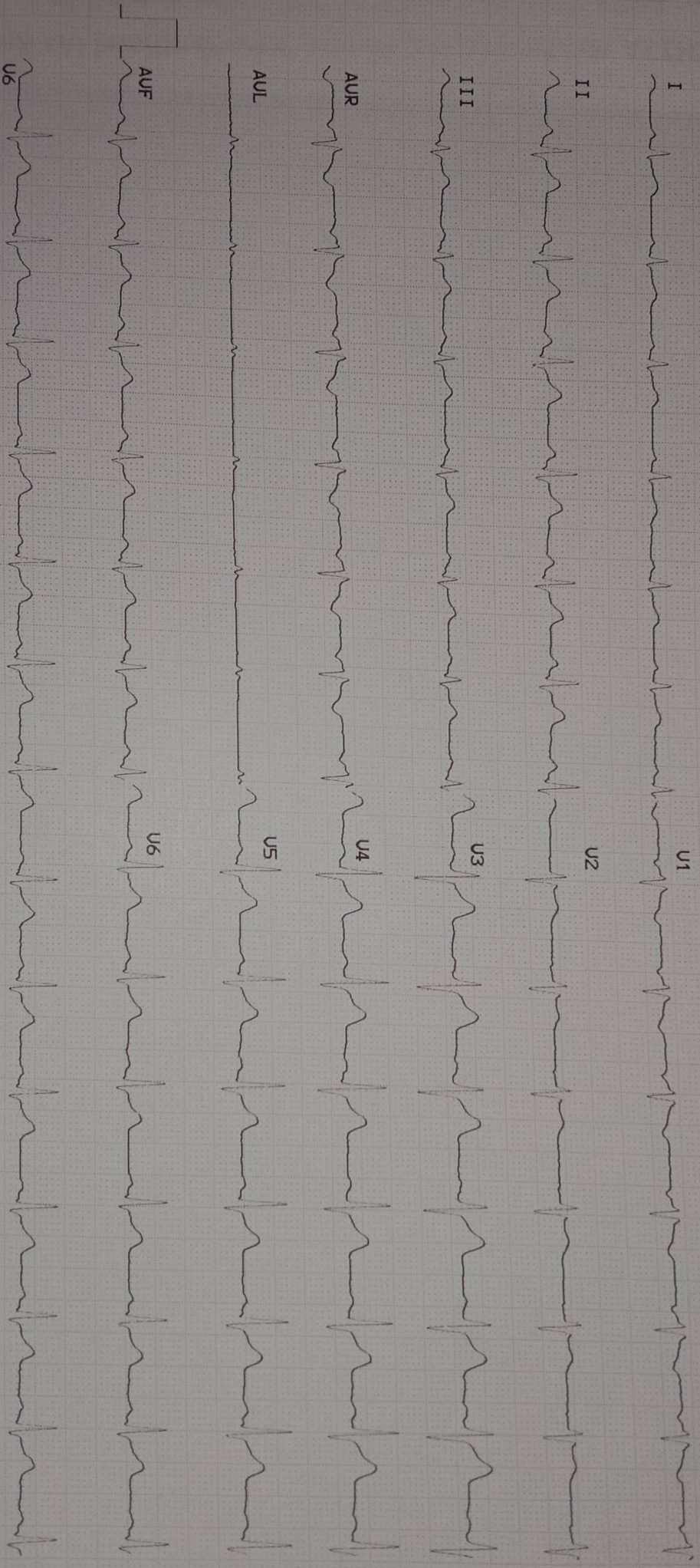
Measurement Results:
 QRS : 112 ms
 QT/QTcB : 368 / 434 ms
 PR : 148 ms
 P : 116 ms
 RR/PP : 720 / 730 ms
 P/QRS/T : 65 / 55 degrees
 QTd/QTcBD : 30 / 35 ms
 Sokolow NK : 1.1 mV
 : 12

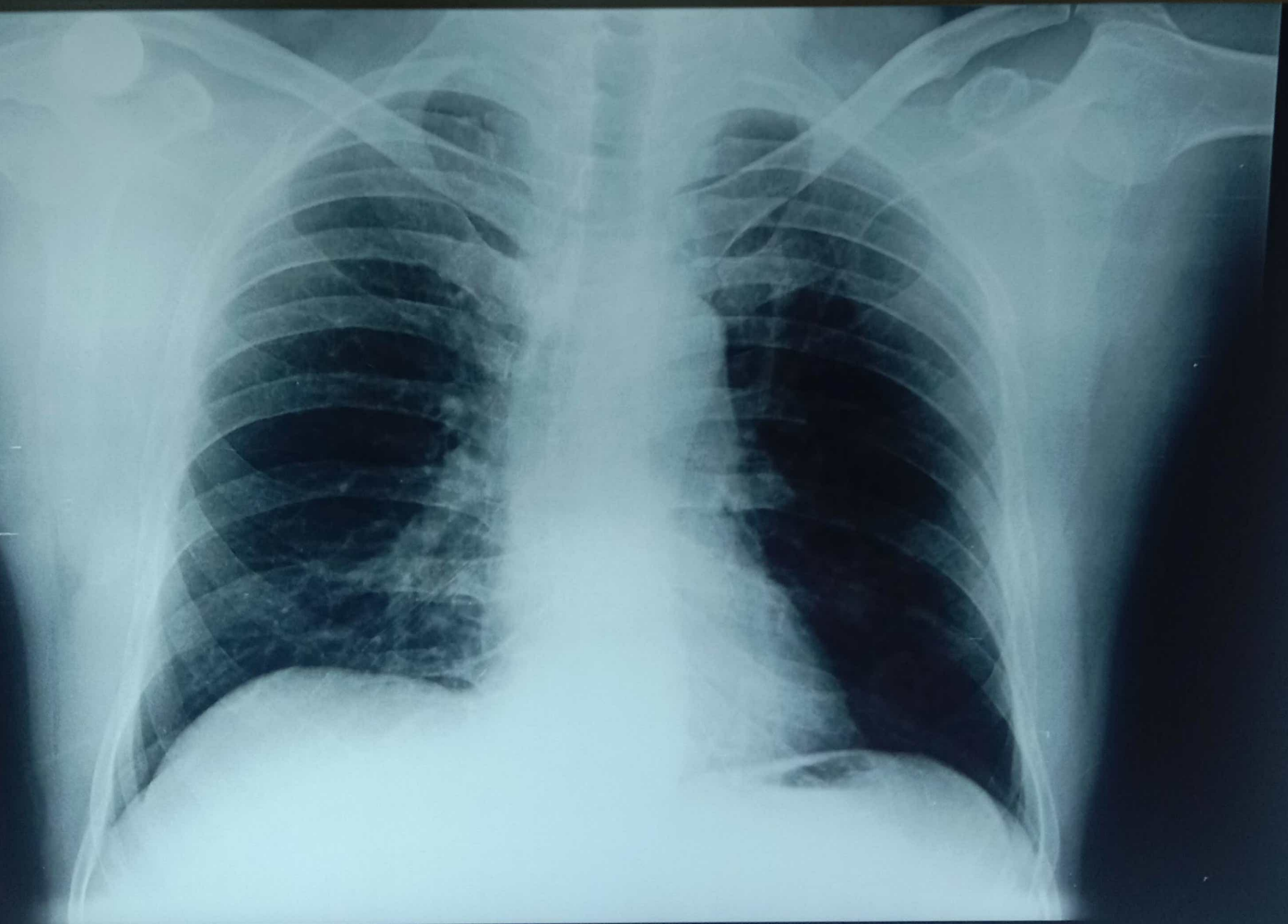


Interpretation: *Normal sinus rhythm*
 incomplete right bundle branch block
 probably normal ECG

Subra

Unconfirmed report.





SADASHIVAMURTHY 66 MED111149078 M CHEST PA 6/11/2022 11:07 AM
MEDALL CLUMAX DIAGNOSTIC