




बैंक ऑफ़ बड़ोदा
Bank of Baroda

नाम
Name


मृदुल अनुज टिग्गा
Mridul Anuj Tigga

E.C. No.

167124


जारीकर्ता प्राधिकारी
Issuing Authority




धारक के हस्ताक्षर
Signature of Holder



Bill of Supply (Interim Bill)




Patient ID : 20230400066
Age / Sex : 42y / M
Patient Name : MRIDUL ANUJ . TIGGA
Dr. Name : DR SAURABH JAIN
Referred By : self
City/Village : Vadodara
Class : Contract
PAN Card : AAQCS5566G

Visit No. : OPD20230400216(OPD)
Bill No. : OPD20230400216
Bill Date : N/A
Speciality : Internal Medicine
Company Name : Mediwheel Health Check Up
GSTIN : 24AAQCS5566G2ZW
Mobile No. : 7978142085

Expense Details	Qty	Rate	Gross Amount	Waive	Net Amount
Visit Charge					
04/04/2023 Physician First Consultation OPD	1.0	0.0	0.00	0.0	0.00
Ophthalmologist First Consultation OPD	1.0	0.0	0.00	0.0	0.00
Dentist First Consultation OPD	1.0	0.0	0.00	0.0	0.00
Visit Charge (Subtotal)			0.0	0.0	0.00
PATHOLOGY					
04/04/2023 CBC, ESR	1.0			0.0	
Urine R/M	1.0			0.0	
STOOL EXAMINATION	1.0			0.0	
Blood Group	1.0			0.0	
FBS & PPBS	1.0			0.0	
TFT (Thyroid Function Test)	1.0			0.0	
Lipid Profile	1.0			0.0	
RENAL FUNCTION TEST	1.0			0.0	
LFT (Liver Function Test)	1.0			0.0	
PSA (Prostate Specific Antigen) Male	1.0			0.0	
HBA1C	1.0			0.0	
MediWheel Full Body Health Check-Up(Male Above 40)	1.0	2500.0	2500.00	0.0	2500.00
PATHOLOGY (Subtotal)			2500.0	0.0	2500.00
Radiology					
04/04/2023 X-RAY CHEST PA	1.0			0.0	
USG WHOLE ABDOMEN SCREENING	1.0			0.0	
X-RAY CHEST PA	1.0	0.0	0.00	0.0	0.00
USG WHOLE ABDOMEN SCREENING	1.0	0.0	0.00	0.0	0.00
Radiology (Subtotal)			0.0	0.0	0.00
Non Invasive Cardiology					
04/04/2023 ECG Charge(OPD Base)	1.0	0.0	0.00	0.0	0.00
ECHO COLOUR DOPPLER SCREENING	1.0	0.0	0.00	0.0	0.00
Non Invasive Cardiology (Subtotal)			0.0	0.0	0.00
Total Bill Amount					2500.00
Net payable amount					2500.00
Bill Outstanding					2500.00

Received With Thanks From MRIDUL ANUJ . TIGGA of Rs 0.0 /-
(Rs Zero Only)

Printed By : (GAYATRI)
For : Savita Hospital Live





PHYSICIAN EXAMINATION

Name :	MRIDUL ANUJ TIGGA	Age :	42/MALE
Reg.No :	20230400066	DOE :	04/04/2023

Physical Examination:

Height:	156CM	Weight:	63 KG	PULSE:	88	Temperature:	NORMAL
---------	-------	---------	----------	--------	----	--------------	--------

BMI :	25.88	BP :	100/70	SPO2	98%
-------	-------	------	--------	------	-----

Chief Complaint :	NO COMPLAINT
Past History :	NAD
General Examination :	NAD
Systemic Examination :	NAD
INVESTIGATION :	NAD
ADVICE :	NAD



DR. SAURABH JAIN



EXAMINATION BY DENTAL

Name :	MRIDUL ANUJ TIGGA	Age/Sex:	42/MALE
Reg No :	20230400066	DOE:	04/04/23

Presenting Complaint :	C/O FOOD LODGEMENT IN LOWER LEFT TOOTH BACK REGION
-------------------------------	---

Medical History :	NO RELEVANT HISTORY
--------------------------	----------------------------

Examination :	OCCLUS PIT ITR	<table border="1"><tr><td></td><td></td></tr><tr><td></td><td>6</td></tr></table>				6
	6					

Impression :	NAD
---------------------	------------

ADVICE	COMPOSITE RESTORATION IRT	<table border="1"><tr><td></td><td></td></tr><tr><td></td><td>6</td></tr></table>				6
	6					



DR RUSSA MALEK



Examination By Ophthalmologist

Name :	MRIDUL ANUJ TIGGA	Age :	42/MALE
Reg.No :	20230400066	DOE :	04/04/2023

Present Complaints :	NO FRESH C/O
Medical History :	NAD
Examination Of Eye :	NAD

External Examination :	NAD	NAD
Ati Seg Examination :	A/S WNL	
Schiotz Tonometry IOP :	P:RRRL	
Fundus :	NILL	

Without Glass	Distant Vision : 6/6	6/6
	Near Vision : N6	N6
With Glass	Distant Vision :	
	Near Vision :	
Colour Vision (With Ishihara Chart) :	WNL	
Advice :	NIL	



DR CHETAN CHAUHAN



Patient Name : Mridul Anuj . Tigga

Sample No. : 20230400124



Patient ID : 20230400066

Visit No. : OPD20230400216

Age / Sex : 42y/Male

Call. Date : 04/04/2023 08:29

Consultant : DR SAURABH JAIN

S. Coll. Date : 04/04/2023 11:55

Ward : -


Report Date : 04/04/2023 15:16

CBC, ESR

Investigation	Result	Normal Value
Hemoglobin :	11.9 gm/dl [L]	13.5 to 18.0 gm/dl
P.C.V. :	37.4 % [L]	42.0 to 52.0 %
M.C.V. :	77.1 fL [L]	78 to 100 fL
M.C.H. :	24.5 pg [L]	27 to 31 pg
M.C.H.C. :	31.8 g/dl [L]	32 to 36 g/dl
RDW :	14.3 % [H]	11.5 to 14.0 %
RBC Count :	4.85 X 10 ⁶ / cumm	4.7 to 6.0 X 10 ⁶ / cumm
Polymorphs :	75 % [H]	38 to 70 %
Lymphocytes :	21 %	15 to 48 %
Eosinophils :	2 %	0 to 6 %
Monocytes :	2 % [L]	3 to 11 %
Basophils :	0 %	0.0 to 1.0 %
Total :	100	< 100 > 100
WBC Count :	6200 /cmm	4000 to 10000 /cmm
Platelets Count :	190000 /cmm	1,50,000 to 4,50,000 /cmm
ESR - After One Hour :	16 mm/hr [H]	1 to 13 mm/hr

Dr.Mehul Desai
M.B.D.C.P
Reg.No.G-9521



Patient Name :	Mridul Anuj . Tigga	Sample No. :	20230400124 
Patient ID :	20230400066	Visit No. :	OPD20230400216
Age / Sex :	42y/Male	Call. Date :	04/04/2023 08:29
Consultant :	DR SAURABH JAIN	S. Coll. Date :	04/04/2023 11:55
Ward :	-	Report Date :	04/04/2023 15:16

Blood Group


Investigation	Result	Normal Value
BLOOD GROUP :		
ABO	A	
Rh	Positive	

FBS & PPBS

Investigation	Result	Normal Value
Blood Sugar (FBS) :	91 mg/dl	74 - 100 mg/dl
Urine Sugar (FUS) :	Nil	
Blood Sugar (PP2BS) :	116 mg/dl	70 to 120 mg/dl
Urine Sugar (PP2US) :	Nil	

HBA1C

Investigation	Result	Normal Value
Glycosylated Hb :	5.6 %	Near Normal Glycemia : 6 to 7 Excellent Control : 7 to 8 Good Control : 8 to 9 Fair Control : 9 to 10 Poor Control : > 10
Average Plasma Glucose of Last 3 Months :	114.02	



Dr.Mehul Desai
M.B.D.C.P
Reg.No.G-9521



Patient Name : Mridul Anuj . Tigga	Sample No. : 20230400124
Patient ID : 20230400066	
Age / Sex : 42y/Male	Visit No. : OPD20230400216
Consultant : DR SAURABH JAIN	Call. Date : 04/04/2023 08:29
Ward : -	S. Coll. Date : 04/04/2023 11:55
	Report Date : 04/04/2023 15:16

Lipid Profile

Investigation	Result	Normal Value
Sample :	Fasting	
Sample Type :	Normal	
Cholesterol (Chol) :	166 mg/dl	Low risk : < 200 Moderate risk : 200 - 239 High risk : > or = 240
Triglyceride :	85 mg/dl	Normal : < 200.0 High : 200 - 499 Very High : > or = 500
HDL Cholesterol :	44 mg/dl	Low risk : >or = 60 mg/dL High risk : Up to 35 mg/dL
LDL :	105 mg/dl [L]	131.0 to 159.0(N) < 130.0(L) > 159.0(H)
VLDL :	17 mg/dl	Up to 0 to 34 mg/dl
LDL/HDL Ratio :	2.39	Low risk : 0.5 to 3.0 Moderate risk : 3.0 to 6.0 Elevted level high > 6.0
Total Chol / HDL Ratio :	3.77	Low Risk : 3.3 to 4.4 Average Risk : 4.4 to 7.1 Moderate Risk : 7.1 to 11.0 High Risk : > 11.0
Total Lipids :	595 mg/dl	400 to 700 mg/dl

Note :- Lipemic samples give high triglyceride value and falsely low LDL value.

Dr.Mehul Desai
M.B.D.C.P
Reg.No.G-9521



Patient Name : Mridul Anuj . Tigga

Sample No. : 20230400124



Patient ID : 20230400066

Visit No. : OPD20230400216

Age / Sex : 42y/Male

Call. Date : 04/04/2023 08:29

Consultant : DR SAURABH JAIN

S. Coll. Date : 04/04/2023 11:55

Ward : -


Report Date : 04/04/2023 15:16

RENAL FUNCTION TEST

Investigation	Result	Normal Value
Creatinine :	1.3 mg/dl	0.6 - 1.4 mg/dl
Urea :	19 mg/ dl	13 - 45 mg/dl
Uric Acid :	7.1 mg/dl	3.5 - 7.2 mg/dl
Calcium :	8.3 mg/dl	8.5 - 10.5
Phosphorus :	3 mg/dl	1.5 - 6.8


Dr.Mehul Desai
M.B.D.C.P
Reg.No.G-9521



Patient Name : Mridul Anuj . Tigga	Sample No. : 20230400124 
Patient ID : 20230400066	Visit No. : OPD20230400216
Age / Sex : 42y/Male	Call. Date : 04/04/2023 08:29
Consultant : DR SAURABH JAIN	S. Coll. Date : 04/04/2023 11:55
Ward : -	Report Date : 04/04/2023 15:16

LFT (Liver Function Test)

Investigation	Result	Normal Value
Total Bilirubin :	1 mg/dl	0.2 to 1.0 mg/dl
Direct Bilirubin :	0.5 mg/dl	0.0 to 0.2 mg/dl
Indirect Bilirubin :	0.5 mg/dl	0.0 to 0.8 mg/dl
AST (SGOT) :	17 U/L	5 to 34 U/L
ALT (SGPT) :	14 U/L	0 to 55 U/L
Total Protein (TP) :	7.6 g/dL	6.4 to 8.3, g/dl
Albumin (ALB) :	4 g/dl	3.5 to 5.2 g/dl
Globulin :	3.6 g/dl [H]	2.3 to 3.5 g/dl
A/G Ratio :	1.11	
Alkaline Phosphatase (ALP) :	126 U/L	40 to 150 U/L
GAMMA GT. :	18 U/L	7 to 35 U/L



Dr. Mehul Desai
M.B.D.C.P
Reg.No.G-9521



Patient Name : Mridul Anuj . Tigga

Sample No. : 20230400124



Patient ID : 20230400066

Visit No. : OPD20230400216

Age / Sex : 42y/Male

Call. Date : 04/04/2023 08:29

Consultant : DR SAURABH JAIN

S. Coll. Date : 04/04/2023 11:55

Ward : -

Report Date : 04/04/2023 15:16

Urine R/M

Investigation	Result	Normal Value
Quantity - :	20 ml	
Colour - :	Straw	
Reaction (pH) :	5.0	4.6-8.0
Turbidity :	Clear	
Deposit :	Absent	Absent
Sp.Gravity :	1.010	1.005-1.010
Protein :	Absent	Absent
Glucose :	Absent	Absent
Bile Salts :	Absent	Absent
Bile pigments :	Absent	Absent
Ketones :	Absent	Absent
Urobilinogen :	Absent	
Blood :	Absent	Absent
Pus Cells :	Absent /hpf	0-5/hpf
Red Blood Cells :	0-1 /hpf	Absent
Epithelial Cells :	0-1 /hpf	

Dr.Mehul Desai
M.B.D.C.P
Reg.No.G-9521



Unipath Specialty Laboratory (Baroda) LLP- Platinum Complex, Opp. HDFC Bank, Nr. Radha Krishna char rasta, Akota, Vadodara - 390020
Mobile: 9998724579 / 8155028222 | Email: info.baroda@unipathllp.in



TEST REPORT

Reg. No. : 30401001504 Reg. Date : 04-Apr-2023 12:39 Collected On : 04-Apr-2023 12:39
Name : Mr. MRUDUL TIGGA Approved On : 04-Apr-2023 14:08
Age : 42 Years Gender : Male Ref. No. : Dispatch At :
Ref. By : Tele No. :
Location : SAVITA SUPERSPECIALTY HOSPITAL @ WAGHODIYA ROAD

Test Name	Results	Units	Bio. Ref. Interval
THYROID FUNCTION TEST			
T3 (triiodothyronine) <i>Method:CLIA</i>	1.06	ng/mL	0.6 - 1.81
T4 (Thyroxine) <i>Method:CLIA</i>	8.30	µg/dL	4.5 - 12.6
TSH (ultra sensitive) <i>Method:CLIA</i>	3.136	µIU/mL	0.55 - 4.78
Sample Type:Serum			

Comments:

Thyroid stimulating hormone (TSH) is synthesized and secreted by the anterior pituitary in response to a negative feedback mechanism involving concentrations of FT3 (free T3) and FT4 (free T4). Additionally, the hypothalamic tripeptide, thyrotropin-releasing hormone (TRH), directly stimulates TSH production. TSH stimulates thyroid cell production and hypertrophy, also stimulate the thyroid gland to synthesize and secrete T3 and T4. Quantification of TSH is significant to differentiate primary (thyroid) from secondary (pituitary) and tertiary (hypothalamus) hypothyroidism. In primary hypothyroidism, TSH levels are significantly elevated, while in secondary and tertiary hypothyroidism, TSH levels are low.

TSH levels During Pregnancy :

- First Trimester : 0.1 to 2.5 µIU/mL
- Second Trimester : 0.2 to 3.0 µIU/mL
- Third trimester : 0.3 to 3.0 µIU/mL

Reference : Carl A.Burtis,Edward R.Ashwood,David E.Bruns. Tietz Textbook of Clinical Chemistry and Molecular Diagnostics. 5th Edition. Philadelphia: WB Saunders,2012:2170

This is an electronically authenticated report.

Test done from collected sample.

Dr. Vishal Jhaveri



Unipath Specialty Laboratory (Baroda) LLP- Platinum Complex, Opp. HDFC Bank, Nr. Radha Krishna char rasta, Akota, Vadodara - 390020
 Mobile: 9998724579 / 8155028222 | Email: info.baroda@unipathllp.in



TEST REPORT

Reg. No. : 30401001504	Reg. Date : 04-Apr-2023 12:39	Collected On : 04-Apr-2023 12:39
Name : Mr. MRUDUL TIGGA		Approved On : 04-Apr-2023 14:13
Age : 42 Years	Gender : Male	Dispatch At :
Ref. By :	Ref. No. :	Tele No. :
Location : SAVITA SUPERSPECIALTY HOSPITAL @ WAGHODIYA ROAD		

Test Name	Results	Units	Bio. Ref. Interval
-----------	---------	-------	--------------------

PROSTATE SPECIFIC ANTIGEN

PSA	0.420	ng/mL	0 - 4
-----	-------	-------	-------

Method: CLIA

Sample Type: Serum

Note:

PSA is a glycoprotein that is produced by the prostate gland, the lining of the urethra, and the bulbourethral gland. Normally, very little PSA is secreted in the blood. Increases in glandular size and tissue damage caused by benign prostatic hypertrophy, prostatitis, or prostate cancer may increase circulating PSA levels.

Digital rectal examination generally does not increase normal prostate-specific antigen (PSA) values. However, cystoscopy, urethral instrumentation, and prostate biopsy may increase PSA levels.

Useful For

1. Evaluating patients with documented prostate problems in whom multiple prostate-specific antigen tests may be necessary per year
2. Monitoring patients with a history of prostate cancer as an early indicator of recurrence and response to treatment.
3. Prostate cancer screening.



----- End Of Report -----

This is an electronically authenticated report.

Test done from collected sample.

Dr Mitesh Rathwa

42 Years

Male

Rate 63

PR 156

QRSD 82

QT 400

QTc 410

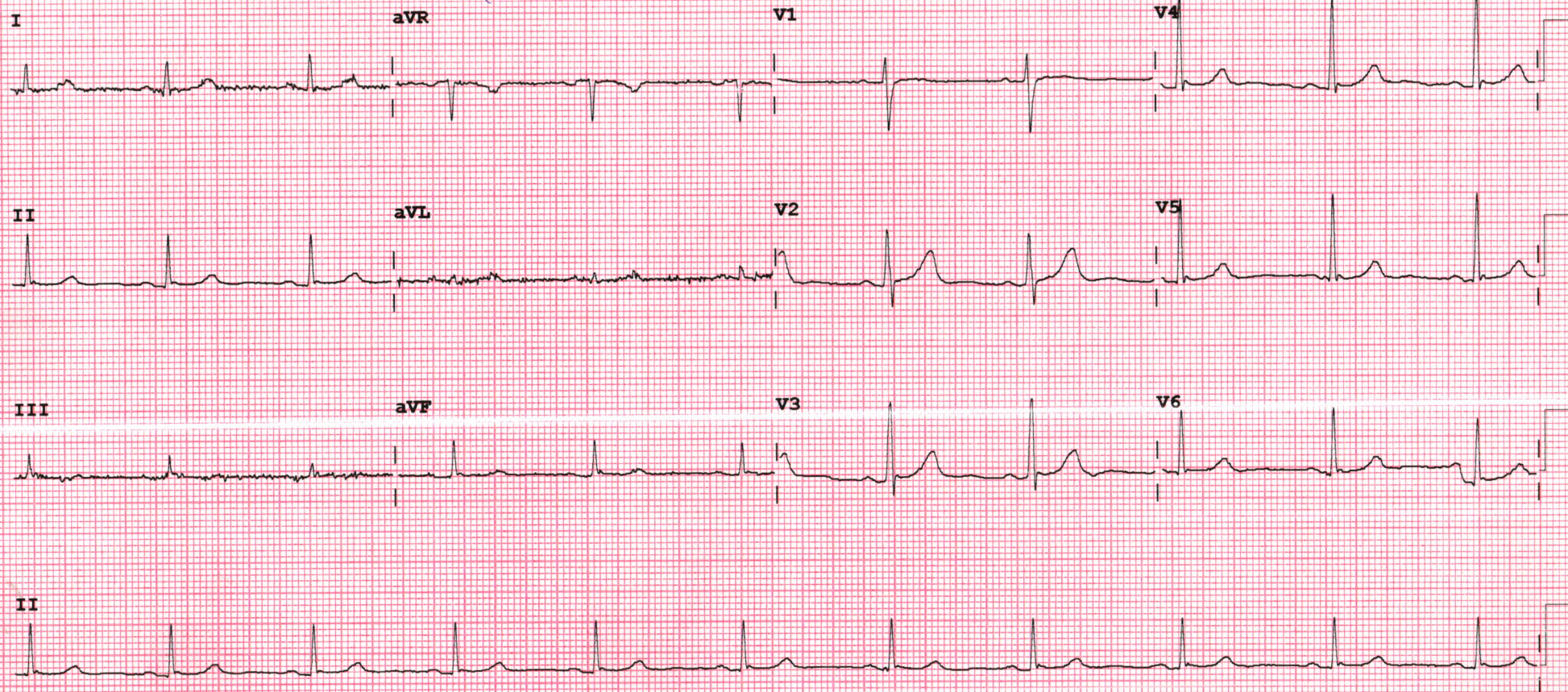
--AXIS--

P 49

QRS 52

T 37

12 Lead; Standard Placement



Device:

Speed: 25 mm/sec

Limb: 10 mm/mV

Chest: 10.0 mm/mV

F 50~ 0.50-150 Hz W

PH09

P?



2D ECHO & COLOUR DOPPLER REPORT

Name : Mridul Anuj Tigga Age/ sex : 42 Years /male, Date : 4/4/23

Observations :

Normal LV size & normal systolic function. LVEF 60 % (Visual).

No RWMA.

No LV diastolic dysfunction.

Mild MR. No MS.

No AR. No AS.

Mild TR. No PAH. Pasp = 35 mmHg.

Normal sized LA, RA & RV with normal RV systolic function.

Normal Main PA.

Intact IAS & IVS.

No intracardiac clot & vegetation.

No PDA & Coarctation.

Normal pericardium, no pericardial effusion.

IVC normal.

Ao : 26 mm, LA :36 mm, IVS:11/15 mm, PW: 11 /16mm. LVID : 37/24 mm

Conclusion:

Normal LV systolic function. LVEF 60%.

No RWMA.

Mild MR. No PAH.

Dr. Nirav Bhalani.

MD, DNB. (Cardiology)





Patient name	MRIDUL TIGGA
Age / Sex	42 Y/M
Date	Tuesday, 04 April 2023

ULTRASOUND OF ABDOMEN

LIVER appears normal in size (13.1 cm) and shows normal parenchymal echogenicity. No evidence of focal lesion. No evidence of dilated IHBR or portal vein. CBD appears normal.

GALL BLADDER is distended. No e/o wall thickening or calculus within.

VISUALIZED PART OF PANCREAS appears normal. MPD is WNL

SPLEEN appears normal in size (9.4 cm) and shows normal parenchymal echogenicity. No evidence of focal lesion.

BOTH KIDNEYS appear normal in size (RK: 10.1 cm & LK: 11.0 cm) and position. Show normal cortical echogenicity. Corticomedullary differentiation is maintained. No calculus or hydronephrosis on either side.

URINARY BLADDER is full. No e/o wall thickening or calculus within.

PROSTATE appears normal in size. No evidence of focal lesion noted.

BOWEL LOOPS appear normal and show normal peristalsis
No evidence of LYMPHADENOPATHY noted.
No evidence of ASCITES or PLEURAL EFFUSION noted.

IMPRESSION:

- NO SIGNIFICANT ABNORMALITY NOTED IN PRESENT SCAN.

DR SHARAD RUNGTA
MD RADIOLOGY

Not all pathologies can be detected on radiograph. Further radiographic evaluation is suggested if required.





NAME: MRIDUL TIGGA	AGE/SEX: 42YRS/M
DATE: Tuesday, April 4, 2023	

CHEST XRAY (PA)

Both lung fields appear normal.

Both hila appear normal

Bilateral costo-phrenic angles appear grossly clear

Mediastinum and cardiac shadow appear normal

Bony thorax appears unremarkable

No evidence of free gas under domes of diaphragm

IMPRESSION:

- NO SIGNIFICANT ABNORMALITY NOTED IN LUNG FIELDS
- NORMAL CARDIAC SHADOW



DR SHARAD RUNGTA
MD RADIOLOGY

Not all pathologies can be detected on radiograph. Further radiographic evaluation is suggested if required.