

<b>Patient's name</b> : DOOMAR CHAND MAHTO	<b>Age/Sex</b> : 49 Years/Male
<b>Referred by</b> : Self	<b>Reg. No</b> : 5430
<b>Date</b> : 27/11/2021	<b>Mobile</b> : 9662599211
<b>Patient's Id</b> : DM105	<b>Ref ID.</b> :

**Fitness Certificate**

**GENERAL EXAMINATION**

Height (cms) : 160

Weight (kgs) : 62.3

Blood Pressure : 120/80mmHg

Pulse : 63/Min

No Clubbing/Cynosis/Pallor/Pedel Oedem

Systemic Examination:

Cardio vascular System - S1,S2 Normal, No Murmur

Respiratory system - AEBE


Central Nervous System - No FND

Abdomen - Soft, Non Tender, No Organomegaly


Comments : He is clinically fit on examination

This is an electronically authenticated report.  
Note:((LL-Very Low, L-Low, HH-Very High)

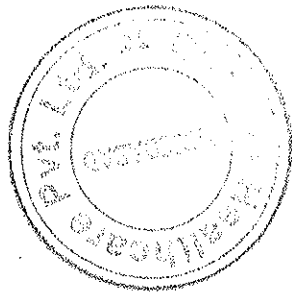
Approved On : 27/11/2021 5:17:00 PM  
Generated On : 27/11/2021 17:34



Dr Jinen M Shah  
DNB (Medicine) FCCS (USA)



*[Handwritten signature]*



*[Handwritten signature]*  
Dr. Jinesh M. Shah  
DND (Medicine) FCCS (USA)  
Reg. No. G-20693

<b>Patient's name</b> : DOOMAR CHAND MAHTO	<b>Age/Sex</b> : 49 Years/Male
<b>Referred by</b> : Self	<b>Reg. No</b> : 5430
<b>Date</b> : 27/11/2021	<b>Mobile</b> : 9662599211
<b>Patient's Id</b> : DM105	<b>Ref ID.</b> :

## HEMOGRAM REPORT

Performed on 5-Part Fully Auto Hematology Analyzer SIEMENS ADVIA 2120I

Test	Result	Unit	Biological Reference Interval
Sample Type:	EDTA		
<b>Haemoglobin:</b>	13.0	gm/dL	13.5 - 18.0
<b>Total WBC Count:</b>	8000	/microlitre	4000 - 10500
<b>Platelets Count:</b>	138000	/microlitre	1,50,000 - 4,50,000
<b>Differential Count:</b>			
Neutrophils:	64	%	40-80
Lymphocytes:	33	%	20-40
Eosinophils:	01	%	Upto 6
Monocytes:	02	%	2-10
Basophils:	00	%	<1-2
<b>RBC indices:</b>			
RBC Count:	5.01	*10 <sup>6</sup> /microL	4.5 - 5.5
HCT:	42.1	%	40 - 50
MCV:	84.0	fL	83-101
MCH:	25.9	pg	27-32
MCHC:	30.9	%	31.5-34.5
RDW:	13.2	%	11.6 - 14.0
<b>Erythrocytes Sedimentation Rate(ESR):</b> (By AUTO ESR-10, USA)			
ESR 1st Hr:	10	mm	2 - 15 mm in 1Hr.
<b>Thick Smear Preparation:</b>			
Haemoparasite:	Malarial parasites are not seen.		
<b>Peripheral Smear Examination:</b>			
RBCs:	Normocytic & Normochromic.		
Platelet:	Platelet decreased on smear.		

----- End of Report -----

  
Dr. KEYUR Patel  
M.B.DCP

This is an electronically authenticated report.  
Note:((LL-Very Low, L-Low, HH-Very High)

Approved On : 27/11/2021 17:08:00  
Generated On : 27/11/2021 17:17

Patient's name : DOOMAR CHAND MAHTO  
Referred by : Self  
Date : 27/11/2021  
Patient's Id : DM105

Age/Sex : 49 Years/Male  
Reg. No : 5430  
Mobile : 9662599211  
Ref ID. :

**LIPID PROFILE**

(Performed on Semi Auto Chemistry Analyzer BeneSphera)

Test	Result	Unit	Biological Reference Interval
Sample Type: Fasting Serum			
<b>S.Cholesterol</b> (Oxidase Peroxidase)	245	mg/dL	< 200 Desirable 200-239 Boderline High > 240 High
<b>S.HDLC (Direct)</b> (Phosphotungsstic Acid)	43.7	mg/dL	< 40 Low > 60 High
<b>S.Triglyceride</b> (GPO-POD)	205.1	mg/dL	< 150 mg/dl Normal 150-199 Boderline High 200-499 High > 500 Very High
<b>S.VLDL</b> (Calculated)	41.02	mg/dL	10-40 Normal
<b>S.LDLC</b> (Calculated)	160.28	mg/dL	< 100 Optimal 100-129 Near to above optimal 130-159 Boderline high 160-189 High >190 Very High
<b>S.Cholesterol / HDLC Ratio</b> (Calculated)	5.61		< 4 Normal 4-6 Borderline 6-8 Risklevel > 8 High Risk
<b>S.LDLC / HDLC Ratio</b> (Calculated)	3.67		< 3 Normal 3-4 Borderline 4-6 Risk Level > 6 High Risk
<b>Cholesterol / HDLC Ratio</b> (Calculated)	5.61		< 3.5 Normal
<b>Triglyceride / HDLC Ratio</b> (Calculated)	4.69		< 2 Normal > 4 Risk Level > 6 High Risk
<b>Non HDLC</b> (Calculated)	201.3		< 130 Normal 130 - 159 Near Normal 160 - 189 Borderline 190 - 219 Risklevel > 220 High Risk

----- End of Report -----



Dr. KEYUR Patel  
M.B.DCP

This is an electronically authenticated report.  
Note: (LL-Very Low, L-Low, HH-Very High)

Approved On : 27/11/2021 17:08:00  
Generated On : 27/11/2021 17:17

Patient's name : DOOMAR CHAND MAHTO  
Referred by : Self  
Date : 27/11/2021  
Patient's Id : DM105

Age/Sex : 49 Years/Male  
Reg. No : 5430  
Mobile : 9662599211  
Ref ID. :

**LIVER FUNCTION TEST**

(Performed on Fully Auto DRY Chemistry Analyzer VITROS-250)

Test	Result	Unit	Biological Reference Interval
Sample Type: Serum			
<b>S.Bilirubin</b>			
Total Bilirubin (Azobilirubin)	1.46	mg/dl	0 - 1.2
Conjugated Bilirubin (Dual Wavelength spectrophotometric)	0.30	mg/dl	0 - 0.4
Unconjugated Bilirubin (Dual Wavelength spectrophotometric)	1.16	mg/dl	0.0 - 1.1
<b>S.G.P.T. (ALT)</b> (Kinetic with Pyridoxal 5-Phosphate)	49.3	IU/L	0 - 49
<b>S.G.O.T. (AST)</b> (Kinetic with Pyridoxal 5-Phosphate)	43.8	IU/L	Up to 46
<b>S.ALP (Alkaline Phosphatase)</b> (4-Nitrophenyl phosphate)	212.1	U/L	80 - 306
<b>S.Protein</b>			
Total Protein (Biuret)	7.74	gm/dl	6.3 - 8.2
Albumin (BCG)	5.08	gm/dl	3.5 - 5.2
Globulin (Calculated)	2.66	gm/dl	1.9 - 3.5
Albumin Globulin Ratio	1.91		
<b>S.GammaGT</b> (L-Gamma Glutamyl-4-Nitroanalide)	35.0	IU/L	15-73

----- End of Report -----



Dr. KEYUR Patel  
M.B.DCP

This is an electronically authenticated report.  
Note:(LL-Very Low, L-Low, HH-Very High)

Approved On : 27/11/2021 17:08:00  
Generated On : 27/11/2021 17:17

Patient's name : DOOMAR CHAND MAHTO  
Referred by : Self  
Date : 27/11/2021  
Patient's Id : DM105

Age/Sex : 49 Years/Male  
Reg. No : 5430  
Mobile : 9662599211  
Ref ID. :

**RENAL FUNCTION TEST**

(Performed on Fully Auto DRY Chemistry Analyzer VITROS-250)

Test	Result	Unit	Biological Reference Interval
Sample Type: Serum			
<b>S.Urea</b> (Urease with indicator dye)	24.0	mg/dl	Male: 19.6-43.6 Female: 15.2-37.0
<b>S.Creatinine</b> (Enzymatic)	0.81	mg/dL	0.55 - 1.30
<b>S.Uric Acid</b> (Uricase)	5.86	mg/dL	Male: 3.5-8.5 Female: 2.5-6.2

**BLOOD GLUCOSE LEVEL**

Test	Result	Unit	Biological Reference Interval
Sample Type: Flouride			
Fasting Blood Glucose (Hexokinase) Collection Time: Collection Time:	113.6	mg/dl	70-110
Post Prandial Blood Glucose (2 Hrs) (Hexokinase)	148.8	mg/dl	80-140

Tests Performed on Fully Auto DRY Chemistry Analyzer VITROS-250

----- End of Report -----



Dr. KEYUR Patel  
M.B.DCP

This is an electronically authenticated report.  
Note:((L-Very Low, L-Low, HH-Very High)

Approved On : 27/11/2021 17:08:00  
Generated On : 27/11/2021 17:17

Patient's name : DOOMAR CHAND MAHTO Age/Sex : 49 Years/Male  
Referred by : Self Reg. No : 5430  
Date : 27/11/2021 Mobile : 9662599211  
Patient's Id : DM105 Ref ID. :

**GLYCOSYLATED HAEMOGLOBIN (HbA1C) ESTIMATION**

Test	Result	Unit	Biological Reference Interval
Sample Type: EDTA			
<b>Glycosylated Haemoglobin (HbA1C)</b>	<b>6.80</b>	%	Pre-Diabetic (Adult): 5.7 - 6.4 Diabetic (Adult): >6.5 Therapeutic goal for glycemc control: <7.0
Mean Blood Glucose Level (An average of 2 -3 Months)	148.46		

Method : HPLC on D-10, Bio-Rad,USA

**INTERPRETATION:**

- \* Blood sample can be drawn at any time. Fasting is not required.
- \* Reflects average blood sugar levels for the 2 to 3 months period before the test.
- \* Provides information for evaluating diabetic treatment modalities and tracks control of blood glucose of particular value in diabetic children, diabetics in whom the renal threshold for glucose is abnormal, unstable insulin dependent diabetics where blood sugars vary markedly from day to day.
- \* High value in poorly controlled DM and moves towards normal in patients with optimal control.

----- End of Report -----



Dr. KEYUR Patel  
M.B.DCP

This is an electronically authenticated report.  
Note:(LL-Very Low, L-Low, HH-Very High)

Approved On : 27/11/2021 17:08:00  
Generated On : 27/11/2021 17:17

Patient's name : DOOMAR CHAND MAHTO  
Referred by : Self  
Date : 27/11/2021  
Patient's Id : DM105

Age/Sex : 49 Years/Male  
Reg. No : 5430  
Mobile : 9662599211  
Ref ID. :

Test	SERUM LDH LEVEL		Biological Reference Interval
	Result	Unit	
Sample Type: <b>LDH Activity</b> ( Lactate Dehydrogenase ): Pyruvate to lactate Kinetic Method	152.01	U/L	120 - 246

#Tests Performed on Fully Auto DRY Chemistry Analyzer VITROS-250

**THYROID FUNCTION TEST**  
(by CLIA on SIEMENS ADVIA Centaur XP)

Test	Result	Unit	Biological Reference Interval
Sample Type: Serum			
<b>S.T3</b> (Total Triiodothyronine by CLIA)	1.27	ng/mL	1 - 23 Months: 1.17 - 2.39 2 - 12 Years: 1.05 - 2.07 13 - 20 Years: 0.86 - 1.92 Adult: 0.6 - 1.81
<b>S.T4</b> (Total Thyroxine by CLIA)	8.40	mcg/dL	3.2 - 12.6
<b>S.TSH</b> (Thyroid Stimulating Hormone by CLIA)	3.806	microU/mL	0 -12 Yrs: 0.77 - 5.64 12-19 Yrs: 0.75-3.69 19-100 Yrs: 0.35 -5.50

----- End of Report -----



Dr. KEYUR Patel  
M.B.DCP

This is an electronically authenticated report.  
Note:(LL-Very Low, L-Low, HH-Very High)

Approved On : 27/11/2021 17:07:00  
Generated On : 27/11/2021 17:17



Patient's name	: DOOMAR CHAND MAHTO	Age/Sex	: 49 Years/Male
Referred by	: Self	Reg. No	: 5430
Date	: 27/11/2021	Mobile	: 9662599211
Patient's Id	: DM105	Ref ID.	:

**Prostate Specific Antigen**  
(Carried out on miniVIDAS, Biomerieux)

Test	Result	Unit	Reference Interval
<b>S.PSA :</b> (Prostate Specific Antigen)	0.780	ng/ml	M : Healthy Male upto 4.00

----- End of Report -----



Dr. KEYUR Patel  
M.B.DCP

This is an electronically authenticated report.  
Note:(LL-Very Low, L-Low, HH-Very High)

Approved On : 27/11/2021 17:08:00  
Generated On : 27/11/2021 17:17

**Patient's name** : DOOMAR CHAND MAHTO  
**Referred by** : Self  
**Date** : 27/11/2021  
**Patient's Id** : DM105

**Age/Sex** : 49 Years/Male  
**Reg. No** : 5430  
**Mobile** : 9662599211  
**Ref ID.** :

**URINE ROUTINE ANALYSIS**

Sample Type: Fresh Urine

**Physical Examination**

(Naked Eye Observation)

	Result	Biological Ref. Value
Amount	15 ml	>10 ml
Colour	Pale Yellow	Pale Yellow
Appearance	Clear	Clear

**Chemical Examination**

pH (Dip stick)	7.5	4.5-8.0
Specific Gravity (Bromothymol Blue)	1.015	1.002-1.030
Albumin (Tetrabromophenol)	Absent	Absent
Glucose (Specific Glucose Oxidase/Peroxidase)	Absent	Absent
Bilirubin (Azo-coupling reaction)	Absent	Absent
Acetone (Sodium Nitroprusside Reaction)	Absent	Absent
Urobilinogen (Modified Ehrlich Reaction)	Absent	Absent
Nitrites (Diazotization Reaction)	Absent	Absent

**Microscopic Examination**

(After centrifugation at 1500 RPM for 10min./hpf)

Pus Cells(WBCs)	Occasional	Absent
Red Blood Cells(RBCs)	Occasional	Absent
Epithelial cells	Occasional	
T.Vaginials	Absent	Absent
Spermatozoa	Absent	Absent
Casts	Absent	Absent
Crystals	Absent	Absent
Amorphous Material	Absent	Absent

----- End of Report -----

  
Dr. KEYUR Patel  
M.B.DCP

This is an electronically authenticated report.  
Note:((LL-Very Low, L-Low, HH-Very High)

Approved On : 27/11/2021 17:07:00  
Generated On : 27/11/2021 17:17

<b>Patient's name</b> : DOOMAR CHAND MAHTO	<b>Age/Sex</b> : 49 Years/Male
<b>Referred by</b> : Self	<b>Reg. No</b> : 5430
<b>Date</b> : 27/11/2021	<b>Mobile</b> : 9662599211
<b>Patient's Id</b> : DM105	<b>Ref ID.</b> :

**Electrocardiogram**

**Findings**

Normal Sinus Rhythm.

Within Normal Limit.

----- End of Report -----

This is an electronically authenticated report.  
Note:((LL-Very Low, L-Low, HH-Very High)

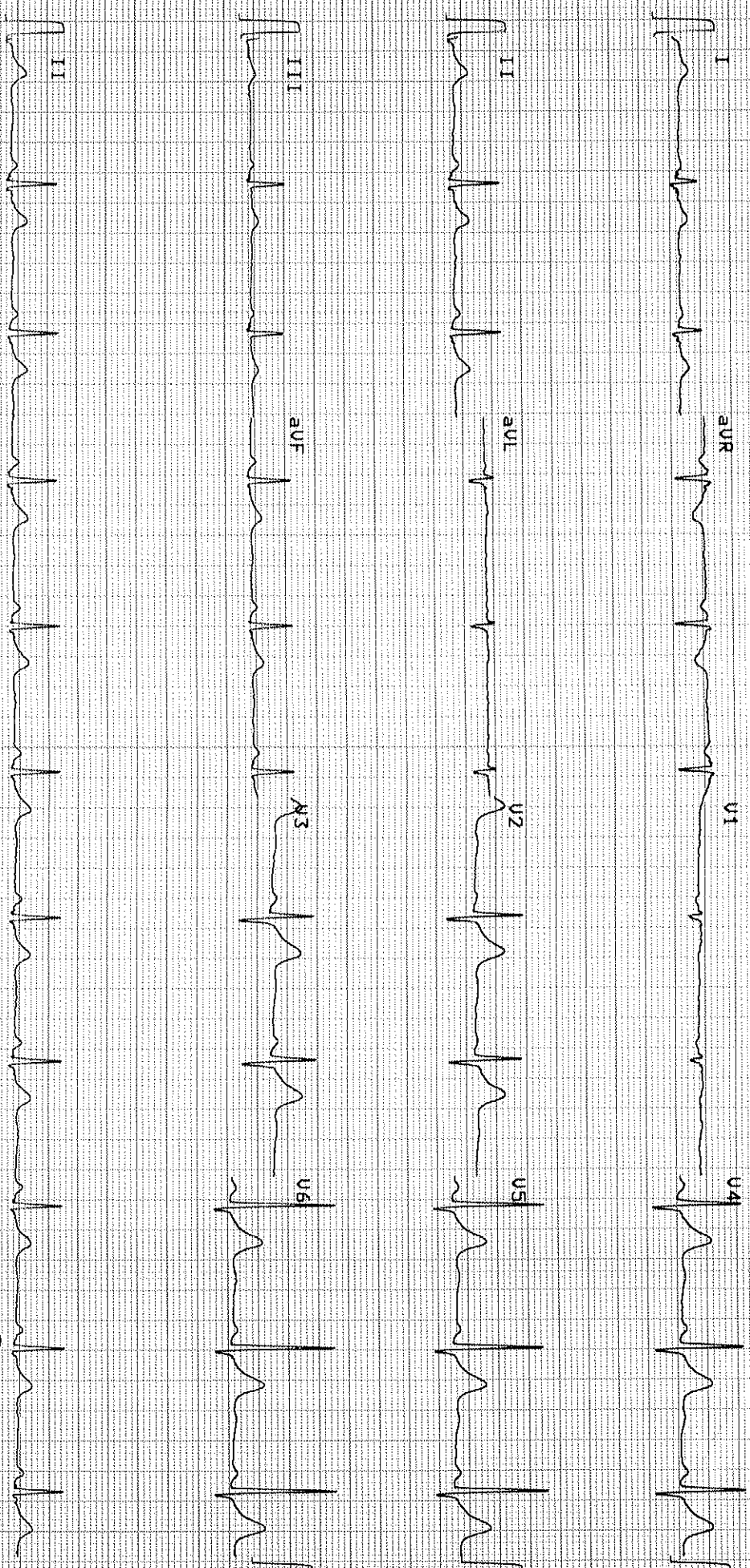
Approved On : 27/11/2021 5:17:00 PM  
Generated On : 27/11/2021 17:34



Dr Jinen M Shah  
DNB (Medicine)FCCS (USA)

Doomar  
Chandwaha  
9  
49 years  
160 cm / 62 kg  
Male

HR 63/min  
Axis: P 52°  
          QRS 71°  
          T 48°  
Intervals: RR 958 ms  
              P 186 ms  
              PR 132 ms  
              QR5 84 ms  
              QT 362 ms  
              QTc 373 ms  
              (Bazett)  
              10 mm/mV



10 mm/mV  
25 mm/s

0.05-25 Hz F50 S5F S85 27.11.2021 08:56:13

CURIOUS HEALTHCARE

*[Handwritten Signature]*

BT-102plus 1.24

<b>Patient's name</b> : DOOMAR CHAND MAHTO	<b>Age/Sex</b> : 49 Years/Male
<b>Referred by</b> : Self	<b>Reg. No</b> : 5430
<b>Date</b> : 27/11/2021	<b>Mobile</b> : 9662599211
<b>Patient's Id</b> : DM105	<b>Ref ID.</b> :

### 2D Echo Colour Doppler

#### OBSERVATION:

2 D Echo and color flow studies were done in long and short axis, apical and

Sub coastal views.


1. Normal LV size. No RWMA at rest.
2. Normal RV and RA. No Concentric LVH.
3. All Four valves are structurally normal.
4. Good LV systolic function. LVEF = 60%.
5. Reduced LV Compliance.
6. Trivial TR. Mild MR. No AR.
7. No PAH. RVSP = 22 mmHG.
8. Intact IAS and IVS.
9. No Clot, No Vegetation.
10. No pericardial effusion.

#### CONCLUSION

1. Normal LV size with Good LV systolic function.
2. No Concentric LVH . Reduced LV Compliance
3. Trivial TR with No PAH. Mild MR. No AR
4. No RWMA at rest.

**This echo doesn't rule out any kind of congenital cardiac anomalies.**

This is an electronically authenticated report.  
Note:((LL-Very Low, L-Low, HH-Very High)




Dr Jinen M Shah  
DNB (Medicine) FCCS (USA)

Patient's name : DOOMAR CHAND MAHTO  
Referred by : Self  
Date : 27/11/2021  
Patient's Id : DM105

Age/Sex : 49 Years/Male  
Reg. No : 5430  
Mobile : 9662599211  
Ref ID. :

Approved On : 27/11/2021 5:17:00 PM  
Generated On : 27/11/2021 17:34



Patient's name : DOOMAR CHAND MAHTO  
Referred by : Self  
Date : 27/11/2021  
Patient's Id : DM105

Age/Sex : 49 Years/Male  
Reg. No : 5430  
Mobile : 9662599211  
Ref ID. :

**X RAY CHEST PA**

Both lung fields appear clear.

No evidence of any active infiltrations or consolidation.

Cardiac size appears within normal limits.

Both costo-phrenic angles appear free of fluid.

Both domes of diaphragm appear normal.

Bony thorax appears normal.


**COMMENT: No significant abnormality is detected.**

----- End of Report -----

This is an electronically authenticated report.  
Note:((LL-Very Low, L-Low, HH-Very High)

  
Dr. Jalmin Shah  
DMRD  
Consultant Radiologist

Approved On : 27/11/2021 4:24:00 PM  
Generated On : 27/11/2021 16:24



<b>Patient's name</b> : DOOMAR CHAND MAHTO	<b>Age/Sex</b> : 49 Years/Male
<b>Referred by</b> : Self	<b>Reg. No</b> : 5430
<b>Date</b> : 27/11/2021	<b>Mobile</b> : 9662599211
<b>Patient's Id</b> : DM105	<b>Ref ID.</b> :

**USG ABDOMEN**

**Liver** appears normal in size, show homogenous increased parenchymal echo. No evidence of focal solid or cystic lesion seen. No evidence of dilatation of intra-hepatic biliary or portal radicals. PV is normal in caliber.

**Gall bladder** is normally distended. No evidence of calculus or mass seen. Gall bladder wall thickness appears normal.

**Pancreas** Visualized portion appears normal in size and echopattern. No evidence of focal lesions.

**Spleen** appears normal in size & normal in echopattern. No evidence of focal lesions.

**Both kidneys** are normal in size, shape and position. C.M. differentiation on both sides is maintained. No evidence of hydronephrosis, calculus or solid mass on either side.

**Urinary bladder** contour is normal, No evidence of calculus or mass.

**Prostate** is normal in size and show homogenous echo, outline is smooth.

*No evidence of para-aortic lymph adenopathy.*

*No evidence of dilated small bowel loops.*

*No evidence of free fluid in peritoneal cavity.*

**COMMENTS :**


**Fatty changes in liver.**

----- End of Report -----

This is an electronically authenticated report.  
Note: (LL-Very Low, L-Low, HH-Very High)

  
**Dr. Jaimin Shah**  
DMRD  
Consultant Radiologist

Approved On : 27/11/2021 4:25:00 PM  
Generated On : 27/11/2021 16:25





---

<b>Patient's name</b> : DOOMAR CHAND MAHTO	<b>Age/Sex</b> : 49 Years/Male
<b>Referred by</b> : Self	<b>Reg. No</b> : 5430
<b>Date</b> : 27/11/2021	<b>Mobile</b> : 9662599211
<b>Patient's Id</b> : DM105	<b>Ref ID.</b> :

---

### Eye Check - Up

#### RIGHT EYE

SP: +0.25  
CY: -0.50  
AX: 62

#### LEFT EYE

SP: +0.25  
CY: +0.00  
AX: 00

	<b>Without Glasses</b>	<b>With Glasses</b>
<b>Right Eye</b>	6/5	n.a
<b>Left Eye</b>	6/5	n.a

**Near Vision:** Right Eye -N/6, Left Eye - N/6


**Fundus Examination:** Within Normal Limits.

**Colour Vision:** Normal

**Comments:** Normal

**Dr.Kejal Patel**  
MB,DO(Ophth)

Approved On : 27/11/2021 5:24:00 PM  
Generated On : 27/11/2021 17:34

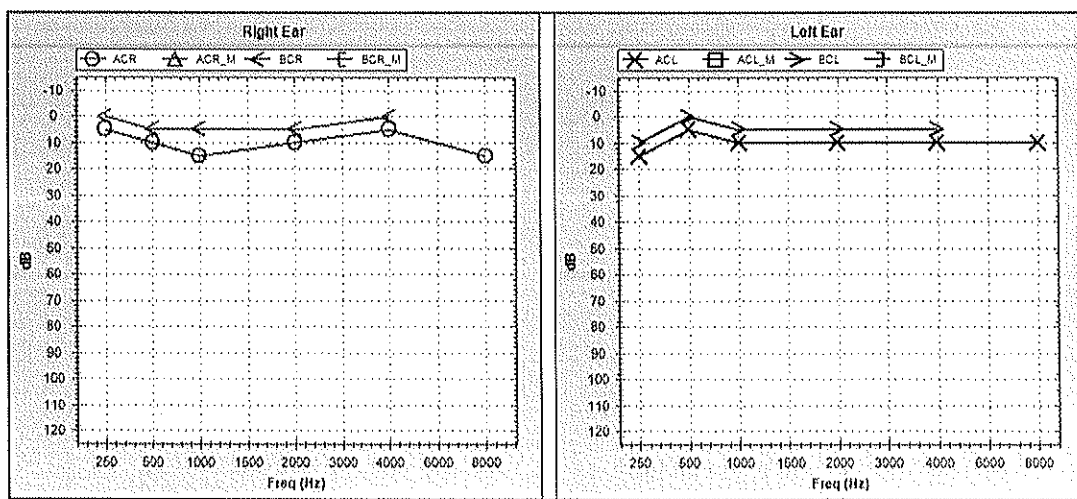


CLIENT NAME: DOOMARCHAND MAHTO.

AGE:- 49Y / M

DATE:- 27/11/2021

## AUDIOGRAM



EAR	MODE	Air Conduction		Bone Conduction		Colour Code	Threshold in dB	RIGHT	LEFT
		Masked	UnMasked	Masked	UnMasked				
LEFT		□	×	☐	>	Blue	AIR CONDUCTION	11	11
RIGHT		△	○	☐	<	Red	BONE CONDUCTION		
NO RESPONSE : Add ↓ below the respective symbols							SPEECH		

Comments:-

Bilateral Hearing Sensitivity Within Normal Limits.

