

# Patho Treat

DIAGNOSTIC CENTRE & POLYCLINIC

TEST REPORT

Regd. Off : 75, Dum Dum Road, Kolkata - 700 074

Phone No.: (033) 2560 3641 / 3642, (033) 6526 0026, (Infront of Motijheel College of Commerce)

Associate Code :	D1	Received On :	24/02/2022
Patient's Name :	MRS SUNAINA LAL	Reported On :	24/02/2022
ID Number :	11777/B-864	Age/Sex :	43Y/FEMALE
Referred By :	SELF	Sample Source :	

ClinicPro/debjan.

Page 1 of 1

## ULTRASONOGRAPHY OF WHOLE ABDOMEN

### LIVER

It is enlarged (15.6 cm ) in size. Parenchymal echotexture is raised. No focal parenchymal lesion is seen. Intrahepatic biliary radicles not dilated.

### PORTA

PV : Normal in diameter with echofree lumen. PV measures 0.9 cm.

CD : Normal in caliber. No calculus is seen up to traceable part. CD measures 0.3 cm.

### GALL BLADDER

Gall bladder is normally distended with normal wall thickness. No intraluminal calculus is noted.

### PANCREAS

Normal in size, shape & outline. No focal S.O.L. or calcification noted. Main pancreatic duct – not dilated.

### SPLEEN

Spleen is normal in size (8.1 cm). Parenchymal echotexture is normal. Splenic vein at its hilum is not dilated.

### KIDNEY

Both kidneys are normal in size , shape and outline. Cortical echogenicity appears normal on both sides. Central echocomplexes are normal. Corticomedullary differentiation is maintained. No evidence of stone, hydronephrosis or any mass lesion seen on either side.

DR. S. PAL  
M.B.B.S.(KOL),  
APUSC-CBET(WBUHS)  
CONSULTANT SONOLOGIST

  
DR. V. J. VIMAL  
MD,DMRD  
CONSULTANT RADIOLOGIST

Checked by.....



# Patho Treat

DIAGNOSTIC CENTRE & POLYCLINIC

TEST REPORT

Regd. Off : 75, Dum Dum Road, Kolkata - 700 074

Phone No.: (033) 2560 3641 / 3642, (033) 6526 0026, (Infront of Motijheel College of Commerce)

## URETERS

Not visualized hence not dilated.

## URINARY BLADDER

Urinary bladder is sub optimally distended and normal in wall thickness. No intraluminal pathology or intramural mass lesion seen.

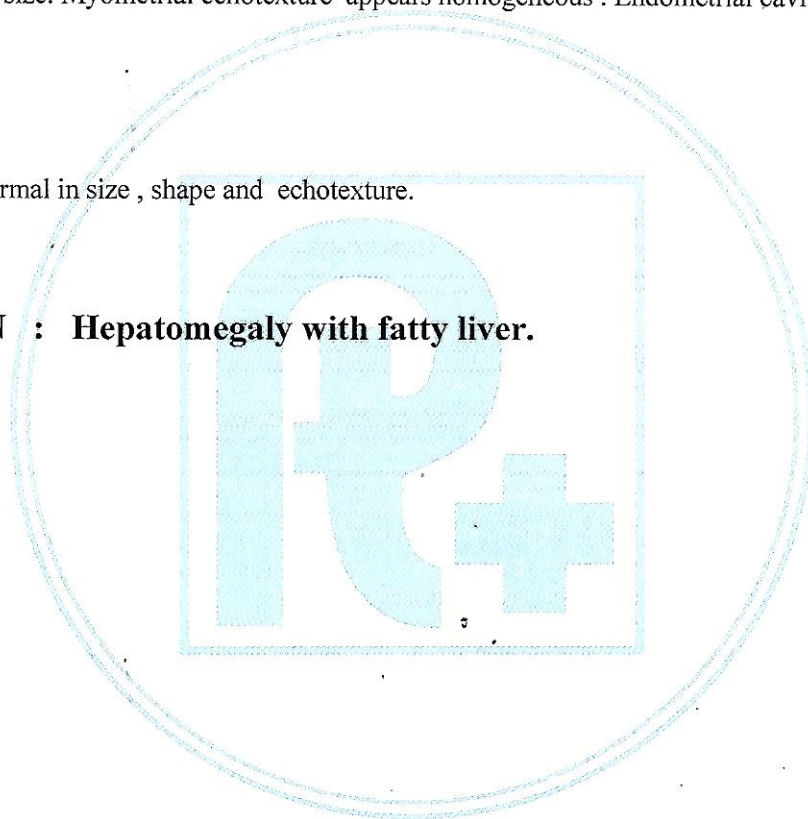
## UTERUS

Uterus is normal in size. Myometrial echotexture appears homogeneous. Endometrial cavity in midline location and well collapsed.

## OVARIES

Both ovaries are normal in size, shape and echotexture.

**IMPRESSION : Hepatomegaly with fatty liver.**



**DR. S. PAL**  
M.B.B.S.(KOL),  
APUSC-CBET(WBUHS)  
CONSULTANT SONOLOGIST

  
**DR. V. J. VIMAL**  
MD,DMRD  
CONSULTANT RADIOLOGIST

Checked by.....