

Patient Name	: Mr. K Birupakshya Patro	Age	: 39Yrs 5Mths 17Days
UHID	: CIND.0000170807	OP Visit No.	: CINDOPV237474
Printed On	: 23-08-2024 11:20 AM	Advised/Pres Doctor	: --
Department	: Radiology	Qualification	: --
Referred By	: Self	Registration No.	: --
Employee Id	: U319368R1295		

---

## DEPARTMENT OF RADIOLOGY

---

### ULTRASOUND ABDOMEN PELVIS

**LIVER:** Appears normal in size, shape and echopattern. No focal parenchymal lesions identified. No evidence of intra/extrahepatic biliary tree dilatation noted. Portal vein appears to be of normal size.

**GALLBLADDER:** Moderately distended.

**SPLEEN:** Appears normal in size, shape and echopattern. No focal parenchymal lesions identified.

**PANCREAS:** Obscured by bowel gas. However, the visualized portion appear normal.

**KIDNEYS:** Both kidneys appear normal in size, shape and echopattern. Corticomedullary differentiation appears maintained. No evidence of calculi or hydronephrosis on either side.

Right kidney measures 11.0x5.2 cm.

Left kidney measures 11.3x5.7 cm.

**URINARY BLADDER:** Distended and appears normal. No evidence of abnormal wall thickening noted.

**PROSTATE:** Prostate is normal in size and echo-pattern.

No free fluid is seen.

### **IMPRESSION:**

---

---

**NO SIGNIFICANT SONOGRAPHIC ABNORMALITY DETECTED.**

---End Of The Report---



Dr.RAMESH G

--

--

Radiology

Patient Name	: Mr. K Birupakshya Patro	Age	: 39Yrs 5Mths 17Days
UHID	: CIND.0000170807	OP Visit No.	: CINDOPV237474
Printed On	: 23-08-2024 09:01 AM	Advised/Pres Doctor	: --
Department	: Radiology	Qualification	: --
Referred By	: Self	Registration No.	: --
Employer Id	: U319368R1295		

## DEPARTMENT OF RADIOLOGY

### X RAY CHEST PA

Both lungs fields appear normal.

Both hilae are normal.


Both costophrenic and cardiophrenic angles are normal.

The cardiac and mediastinal shadows appear normal.

Bones and soft tissues appear normal.

**IMPRESSION : NORMAL STUDY.**

---End Of The Report---




Dr.DHANALAKSHMI B

--

--

Radiology

<b>Name :</b> Mr. K Birupakshya Patro  <b>Address :</b> Horamavu Bangalore Karnataka INDIA 560043  <b>Plan :</b> ARCOFEMI MEDIWHEEL MALE AHC CREDIT PAN INDIA OP AGREEMENT	<b>Age :</b> 39Y 5M 16D  <b>sex :</b> Male	<b>UHID :</b> CIND.0000170807  CIND.0000170807  <b>OP No:</b> CINDOPV237474 <b>Bill No:</b> CIND-OCR-100812 <b>Date:</b> Aug 23rd, 2024, 9:12 AM
---	--	---

Sno.	Service Type/Service Name	Department	
1	ARCOFEMI - MEDIWHEEL - RADIOLOGY PACK E MALE - 2D ECHO - PAN INDIA - FY2324		
1	ULTRASOUND - WHOLE ABDOMEN	Ultrasound Radiology	<input type="checkbox"/>
2	PULMONARY FUNCTION TEST - 6	Cardiology	<input type="checkbox"/>
3	X-RAY CHEST PA - 10	X Ray Radiology	<input type="checkbox"/>
4	ECG	Cardiology	<input type="checkbox"/>
5	2 D ECHO - 9 9:30 AM	Cardiology	<input type="checkbox"/>

*6. Dysmedic respiration.*

*HT - 181  
 WT - 82.8kg  
 BP - 110/76  
 PR - 65  
 Temp - 98.4  
 Heart - 97*

**Apollo Health and Lifestyle Limited**

(GIN - U85110TG2000PLC115819)  
 Regd. Office: #7-1-G177A, 615 & 616, Imperial Towers, 7th Floor, Ameerpet, Hyderabad 500038, Telangana.  
 www.apolloh.com | Email ID: enquiry@apolloh.com, Ph No: 040-4904 7777, Fax No: 4904 7744

**APOLLO CLINICS NETWORK**

Telangana: Hyderabad (AS Rao Nagar | Chanda Nagar | Kondapur | Nallakunta | Nizampet | Musliconda | Uppal) | Andhra Pradesh: Vijay (Sonthamma Peta) | Karnataka: Bangalore (Basavanagudi) | Belandur | Electronics City | HSI Layout | Indira Nagar | JP Nagar | Kundalahalli | Koramangla | Sarjapur Road | Mysore (Vr Mahalle) | Tamil Nadu: Chennai (Anna Nagar | Arambakkam | Kotturambakam | T Nagar | Velayudhakkam | Velachery) | Maharashtra: Pune (Aundh | Nigdi Pradhikaran | Viman Nagar | Wanowrie | Kharadi) | Uttar Pradesh: Ghaziabad (Indrapuram)

GSTIN: 29AADCA0733E1Z3

Address:  
 2112, 1st Floor, 100 Feet Road, Raj 2nd Stage,  
 Indira Nagar, 560038



Mr k birupakshya patro  
ID: 170807

07.03.1985  
39 Years

Male

23.08.2024 9:53:23

APOLLO CLINIC  
INDIRANAGAR  
BANGALORE

Location:  
Room:  
Order Number:  
Indication:  
Medication 1:  
Medication 2:  
Medication 3:

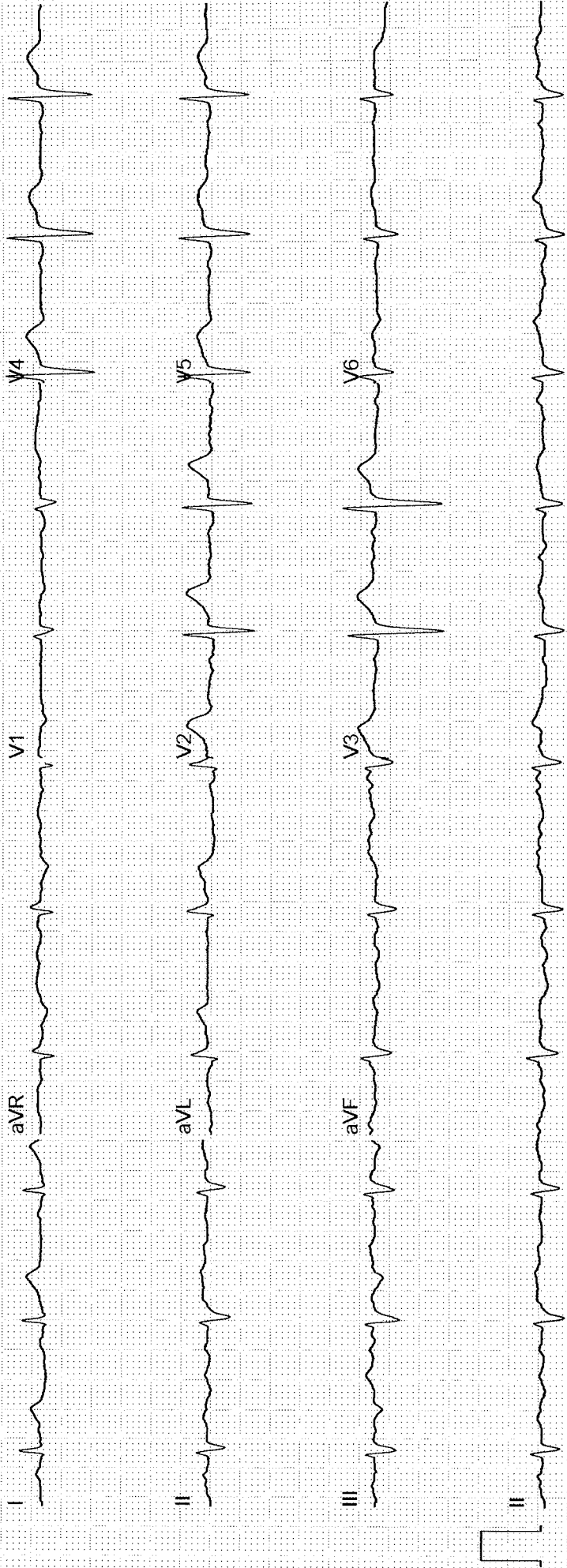
66 bpm  
-- / -- mmHg

QRS: 100 ms  
QT / QTcBaz: 418 / 438 ms  
PR: 160 ms  
P: 54 ms  
RR / PP: 902 / 909 ms  
P / QRS / T: 53 / -36 / 1 degrees

*NSR, T → IV*  
*Cashelate Chiri Chilly*

Technician:  
Ordering Ph:  
Referring Ph:  
Attending Ph:

*Dr. Vignesh Kumar K*  
*(MBBS, MD, DM (Cardio))*  
*Consultant Cardiologist*  
*KMC No: 7984A*



<b>NAME: MR K BIRUPAKSHA P</b>	<b>AGE/SEX: 39/M</b>	<b>OP NUMBER: 170807</b>
<b>Ref By : SELF</b>	<b>DATE: 23-08-2024</b>	

**M mode and doppler measurements:**

CM	CM	M/sec	
<b>AO: 2.7</b>	<b>IVS(D): 0.9</b>	<b>MV: E Vel: 0.9</b>	<b>A Vel : 0.4</b>
<b>LA: 3.6</b>	<b>LVIDD(D): 4.5</b>	<b>AV Peak: 0.6</b>	
	<b>LVPW(D): 1.0</b>	<b>PV peak: 0.7</b>	
	<b>IVS(S): 1.2</b>		
	<b>LVID(S): 2.7</b>		
	<b>LVEF: 60%</b>		
	<b>LVPW(S): 1.2</b>		

**Descriptive findings:**

<b>Left Ventricle</b>	<b>Normal</b>
<b>Right Ventricle:</b>	<b>Normal</b>
<b>Left Atrium:</b>	<b>Normal</b>
<b>Right Atrium:</b>	<b>Normal</b>
<b>Mitral Valve:</b>	<b>Normal</b>
<b>Aortic Valve:</b>	<b>Normal</b>
<b>Tricuspid Valve:</b>	<b>Normal</b>
<b>IAS:</b>	<b>Normal</b>
<b>IVS:</b>	<b>Normal</b>
<b>Pericardium:</b>	<b>Normal</b>

ID: 170807 Age: 39 (07/03/1985)

Patro

Gender: Male Height: 181 cm  
 Ethnicity: Asian Weight: 82 kg BMI: 25

**FVL (ex/in)**

Your FEV1 / Predicted: 66 %

Test Date: 23/08/2024 AM 10:03:31 Interpretation: Predicted Value Selection: GOLD(2008)/Hardie Best Value: 1.12/1.02  
 Post Time: Hankinson (NHANES III), 1999 BTPS (IN/EX) \* 1.00

Parameter	Pred	LLN	Best	Pre			Final	%Pred
				Trial 1	Trial 2	Trial 3		
FVC [L]	5.53	4.56	3.80*	3.77*	3.80*	3.28*	69	
FEV1 [L]	4.40	3.59	2.92*	2.92*	2.92*	2.41*	66	
FEV1/FVC	0.800	0.703	0.769	0.775	0.769	0.735	96	
FEF25-75 [L/s]	4.14	2.49	2.49	2.57	2.49	2.18*	60	
PEF [L/s]	10.48	8.08	6.34*	5.89*	6.34*	2.74*	61	
FET [s]	-	-	7.1	6.7	7.1	6.6	-	
FIVC [L]	5.53	4.56	4.03*	3.95*	4.03*	3.73*	73	
PIF [L/s]	-	-	7.15	7.15	7.15	4.51	2.70	

\* Indicates value outside normal range or significant post change.

Session Quality: Pre C (FEV1 Var=0.00L (0.1%); FVC Var=0.03L (0.7%))

System Interpretation: Pre Restriction probable; further examination recommended

**Dear K Birupakshya patro,**

Greetings from Apollo Clinics,

Your corporate health check appointment is confirmed at **INDIRANAGAR clinic** on **2024-08-23** at **08:00-08:15**.

Payment Mode	
Corporate Name	<b>ARCOFEMI HEALTHCARE LIMITED</b>
Agreement Name	<b>[ARCOFEMI MEDIWHEEL MALE AHC CREDIT PAN INDIA OP AGREEMENT]</b>
Package Name	<b>[ARCOFEMI - MEDIWHEEL - RADIOLOGY PACK E MALE - 2D ECHO - PAN INDIA - FY2324]</b>



**INDIAN UNION DRIVING LICENCE**


**ORISSA STATE** FORM-7

Number: OR-0720070008100  
 Name: K. BIRURAKSHYA PATRO  
 S/D/W of: K. BABU PATRO  
 Address: BADA DANDA STREET, BHEJIRUT, BHANJANAGAR, GANJAM 0  
 Issued on: 23-06-2007  
 DoB: 07-03-1985 **BG.O+ve**

Is licence to drive

Vehicle Class	LMV	MCWC		
Date of issue	22-05-2007	23-06-2007		

Valid till (Transport) 22-06-2027  
 Valid till (Non-Transport)

  
 Signature of Licence Holder  
 Issuing Authority  
 OR-072012000