

<b>NAME: MR.ARGHA HALDER</b>	<b>AGE:35YRS</b>	<b>SEX:MALE</b>
<b>REF BY: CORPORATE</b>	<b>MR NO:FSIN-0000</b>	<b>DATE: 21.05.2021</b>

**ULTRASOUND OF WHOLE ABDOMEN**

**LIVER:** Liver is **Enlarged Moderate fatty changes seen**. The intrahepatic tubular structures are normal. no focal area of altered echogenicity is noted. The porta hepatis is normal. The common bile duct at porta measures **0.29cm** . The portal vein measures **0.78cm** at porta.

**GALL BLADDER:** : Gall bladder is distended. Wall is normal limits. No calculus or mass is seen within the gall bladder.

**PANCREAS:** It is normal in size, Shape, Outline and echotexture. Pancreatic duct is not dilated.

**SPLEEN:** It is normal in size **11.96cm**, Shape, Outline and echotexture. No parenchymal lesion is noted.

**RIGHT KIDNEY:** kidneys are normal in position, size, shape, outline and echotexture. The cortico medullary differentiation is maintained. No calculus or hydronephrosis is seen.

**RIGHT KIDNEY:** measures – **9.46cm**.

**LEFT KIDNEY:** kidneys are normal in position, size, shape, outline and echotexture. The cortico medullary differentiation is maintained. No calculus or hydronephrosis is seen.

**LEFT KIDNEY:** measures – **9.70cm**.

**URINARY BLADDER:** : It is well distended with normal wall thickness . No calculus or mass is seen within the urinary bladder. The post void residual volume of urine is insignificant.

**PROSTATE:** It is normal in size, Shape & homogenous echotexture. The prostatic outline is smooth. The periprostatic plane is normal. It is normal size measures **2.99cmX3.08cmX2.77cm**  
**Vol-13.33ml**

**IMPRESSION:**

- **HEPATOMEGALY WITH MODERATE FATTY CHANGES.**



**DR.SUSMITA CHOWDHURY**  
**MBBS,MD.**  
**CONSULTANT SONOLOGIST**



Patient Name: Mr. ARGHA HALDER 35/M

May 21, 2021  
Time: 13:49:44

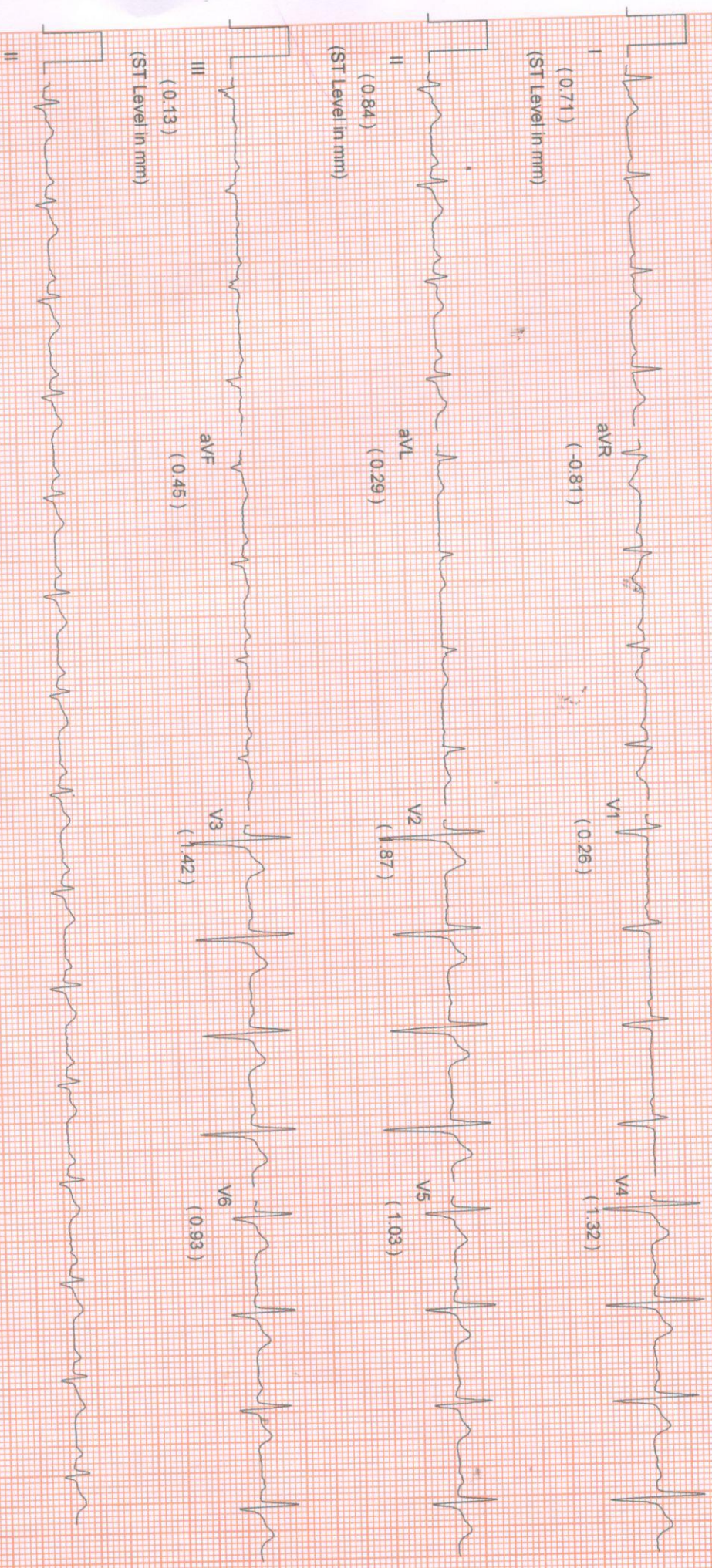
Resting ECG Report

QT / QTc : 0.296 / 0.364 Sec  
P-QRS-T Axis (49)-(18)-(26) deg

PR Interval: 0.15 sec  
QRS Duration : 0.096 Sec

RR Interval: 0.66 sec

HR : 90 bpm  
BP : 120 / 80 mmHg



Comments :-



<b>NAME: MR.ARGHA HALDER</b>	<b>MR NO: FSIN-0000</b>	<b>DATE : 21.05.2021</b>
<b>AGE: 35YRS.</b>	<b>SEX:MALE</b>	<b>REF BY: CORPORATE</b>

**ECG REPORT**

HR : 90b/min  
AXIS : NORMAL  
RHYTHM : SINUS  
PR INTERVAL : 0.15 sec  
QT INTERVAL : 0.364 sec  
QRS DURATION : 0.096 sec  
T-WAVE : NORMAL

**IMPRESSION:**

- RESTING ECG IS WITHIN NORMAL LIMITS.



**Dr. SIDDHARTHA KUNDU**  
MBBS (Cal), PGDCC, CCEBDM  
Clinical Cardiologist  
Ex Sr Resident, Cardiology Dept  
B.R Singh Hospital, Eastern Railway

