

Customer Name	MR. RAJESH B	Customer ID	MED112042191
Age & Gender	38Y/MALE	Visit Date	27/01/2024
Ref Doctor	MediWheel		

2 D ECHOCARDIOGRAPHIC STUDY

M mode measurement:

AORTA	:	2.5cms
LEFT ATRIUM	:	2.6cms
LEFT VENTRICLE (DIASTOLE)	:	4.1cms
(SYSTOLE)	:	2.0cms
VENTRICULAR SEPTUM (DIASTOLE)	:	0.7cms
(SYSTOLE)	:	1.1cms
POSTERIOR WALL (DIASTOLE)	:	0.8cms
(SYSTOLE)	:	1.1cms
EDV	:	65ml
ESV	:	23ml
FRACTIONAL SHORTENING	:	36%
EJECTION FRACTION	:	66%
RVID	:	1.4cms

DOPPLER MEASUREMENTS:

MITRAL VALVE	:	'E' - 0.85m/s	'A' - 0.38 m/s	NO MR
AORTIC VALVE	:	0.97m/s		NO AR
TRICUSPID VALVE	:	'E' - 0.71m/s	'A' - 0.27m/s	NO TR
PULMONARY VALVE	:	0.68m/s		NO PR



Customer Name	MR. RAJESH B	Customer ID	MED112042191
Age & Gender	38Y/MALE	Visit Date	27/01/2024
Ref Doctor	MediWheel		

2D ECHOCARDIOGRAPHY FINDINGS:

Left ventricle : Normal size, Normal systolic function.
No regional wall motion abnormalities.

Left Atrium : Normal.

Right Ventricle : Normal.

Right Atrium : Normal.

Mitral valve : Normal, No mitral valve prolapse.

Aortic valve : Normal, Trileaflet.

Tricuspid valve : Normal.

Pulmonary valve : Normal.


IAS : Intact.

IVS : Intact.

Pericardium : No pericardial effusion.

IMPRESSION:

- NORMAL SIZED CARDIAC CHAMBERS.
- NORMAL LV SYSTOLIC FUNCTION. EF: 66 %.
- NO REGIONAL WALL MOTION ABNORMALITIES.
- NORMAL VALVES.
- NO CLOTS/ PERICARDIAL EFFUSION VEGETATION.

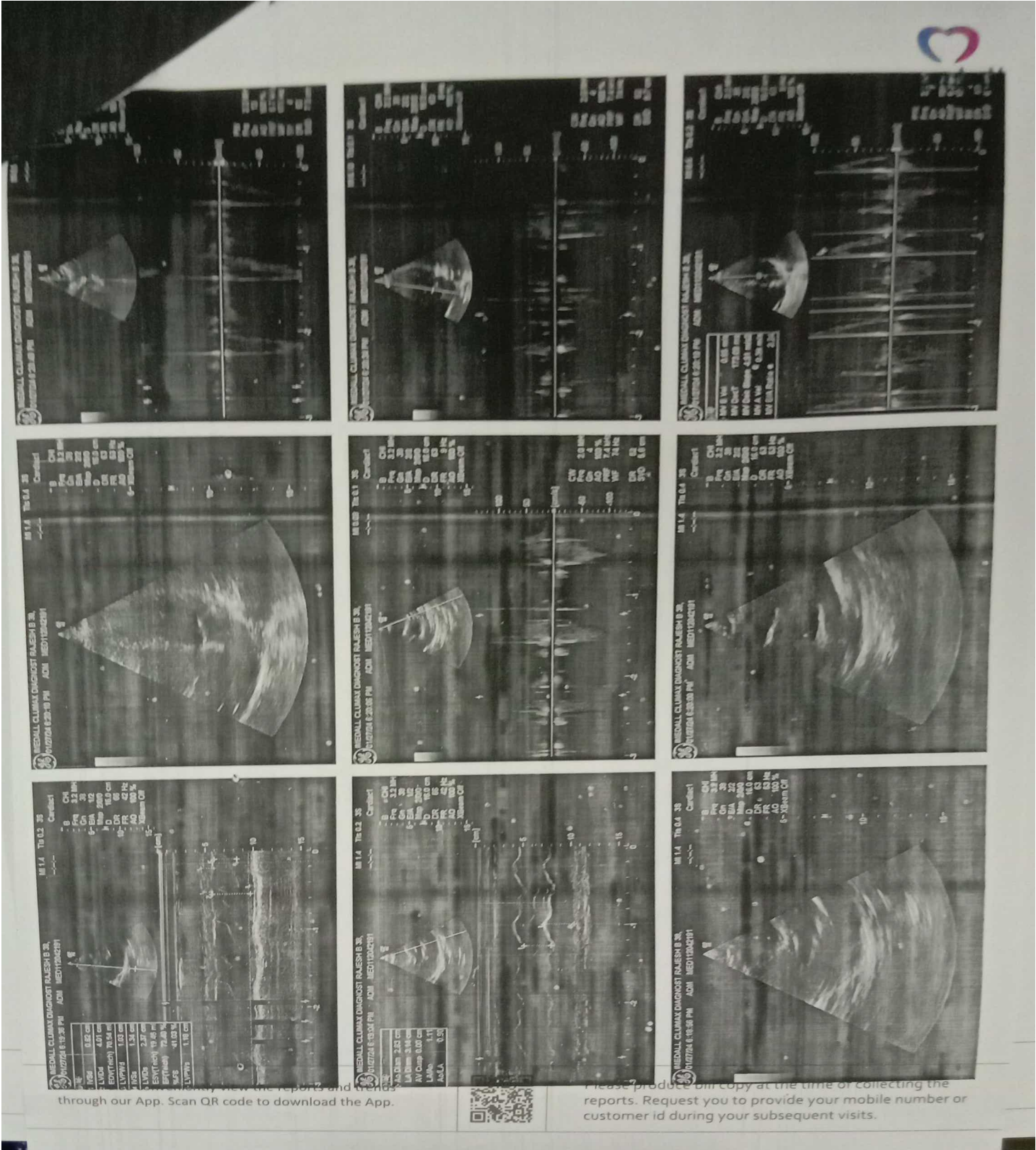


DR. NIKHIL B
INTERVENTIONAL CARDIOLOGIST
NB/mm

You can also conveniently view the reports and trends through our App. Scan QR code to download the App.



Please produce bill copy at the time of collecting the reports. Request you to provide your mobile number or customer id during your subsequent visits.



through our App. Scan QR code to download the App.



request you to provide your mobile number or customer id during your subsequent visits.

Customer Name	MR. RAJESH B	Customer ID	MED112042191
Age & Gender	38Y/MALE	Visit Date	27/01/2024
Ref Doctor	MediWheel		

ABDOMINO-PELVIC ULTRASONOGRAPHY

LIVER is normal in size and shows slightly increased echotexture.

No evidence of focal lesion or intrahepatic biliary ductal dilatation.

Hepatic and portal vein radicals are normal.

GALL BLADDER not imaged – post cholecystectomy status.

PANCREAS has normal shape, size and uniform echopattern.

No evidence of ductal dilatation or calcification.

SPLEEN show normal shape, size and echopattern.

KIDNEYS move well with respiration and have normal shape, size and echopattern.

Cortico- medullary differentiations are well made out.

No evidence of calculus or hydronephrosis.

	Bipolar length (cms)	Parenchymal thickness (cms)
Right Kidney	10.1	1.8
Left Kidney	9.8	1.7

URINARY BLADDER show normal shape and wall thickness.

It has clear contents.

PROSTATE shows normal shape, size and echopattern.


No evidence of ascites.

IMPRESSION:

> **GRADE I FATTY CHANGES IN LIVER.**

CONSULTANT RADIOLOGISTS

DR. ANITHA ADARSH
RB/mm



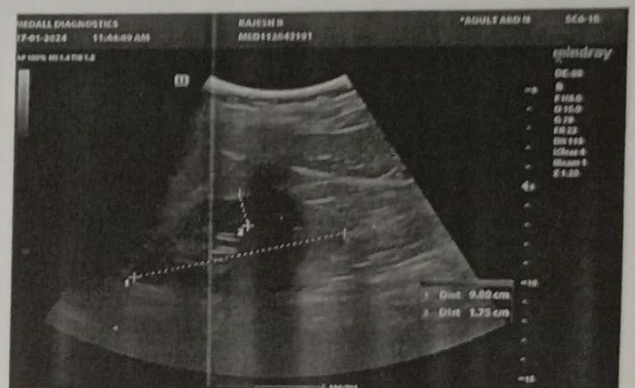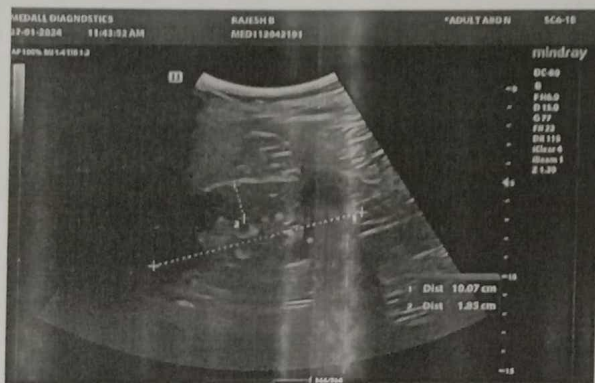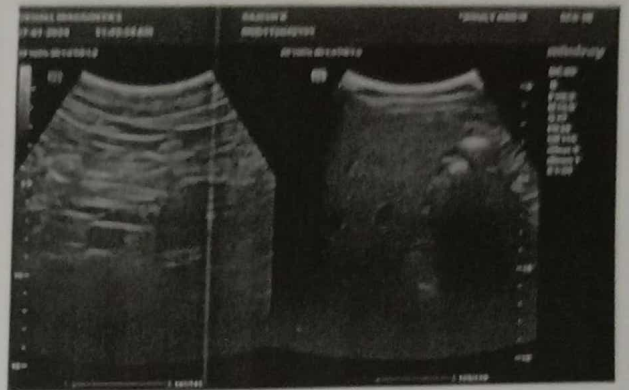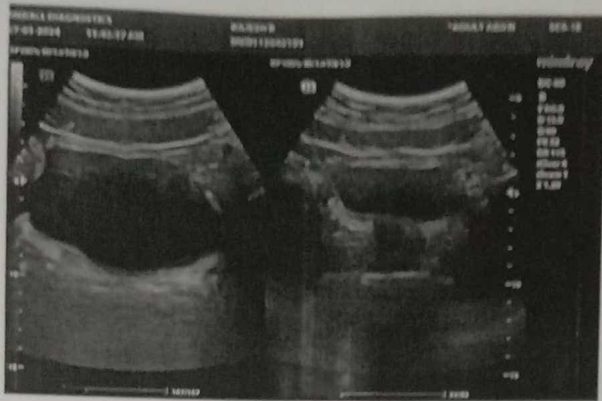DR. MOHAN B



Medall Diagnostics
Ballal Circle(Ashoka circle) - Mysore



Customer Name	MR.RAJESH B	Customer ID	MED112042191
Age & Gender	38Y/MALE	Visit Date	27/01/2024
Ref Doctor	MediWheel		



You can also conveniently view the reports and trends through our App. Scan QR code to download the App.



Please produce bill copy at the time of collecting the reports. Request you to provide your mobile number or customer id during your subsequent visits.

FITNESS CERTIFICATE


NAME: Mr. Rajesh. B	AGE: 38
Hi: 177 CMS	WE: 70 KGS SEX: male

PARAMETERS	MEASUREMENTS
PULSE / BP (supine)	72 / mt / /mmHg 110/70
INSPIRATION	33
EXPIRATION	33
CHEST CIRCUMFERENCE	34
PREVIOUS ILLNESS	Nil
VISION	
FAMILY HISTORY	FATHER: Nil MOTHER: Nil

REPORTS: *within normal limits*

DATE: *29/01/2024*

PLACE: *Mysuru*

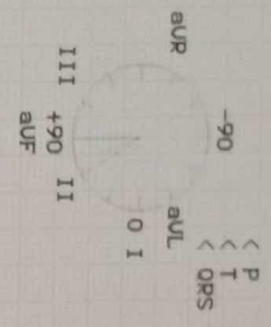

Dr. NIKHIL. B.
 M.D., D.M. (Cardiologist)
 CONSULTANT Physician International Cardiologist
 KMC Reg. No.: 90111



AGE: 38

Measurement Results:

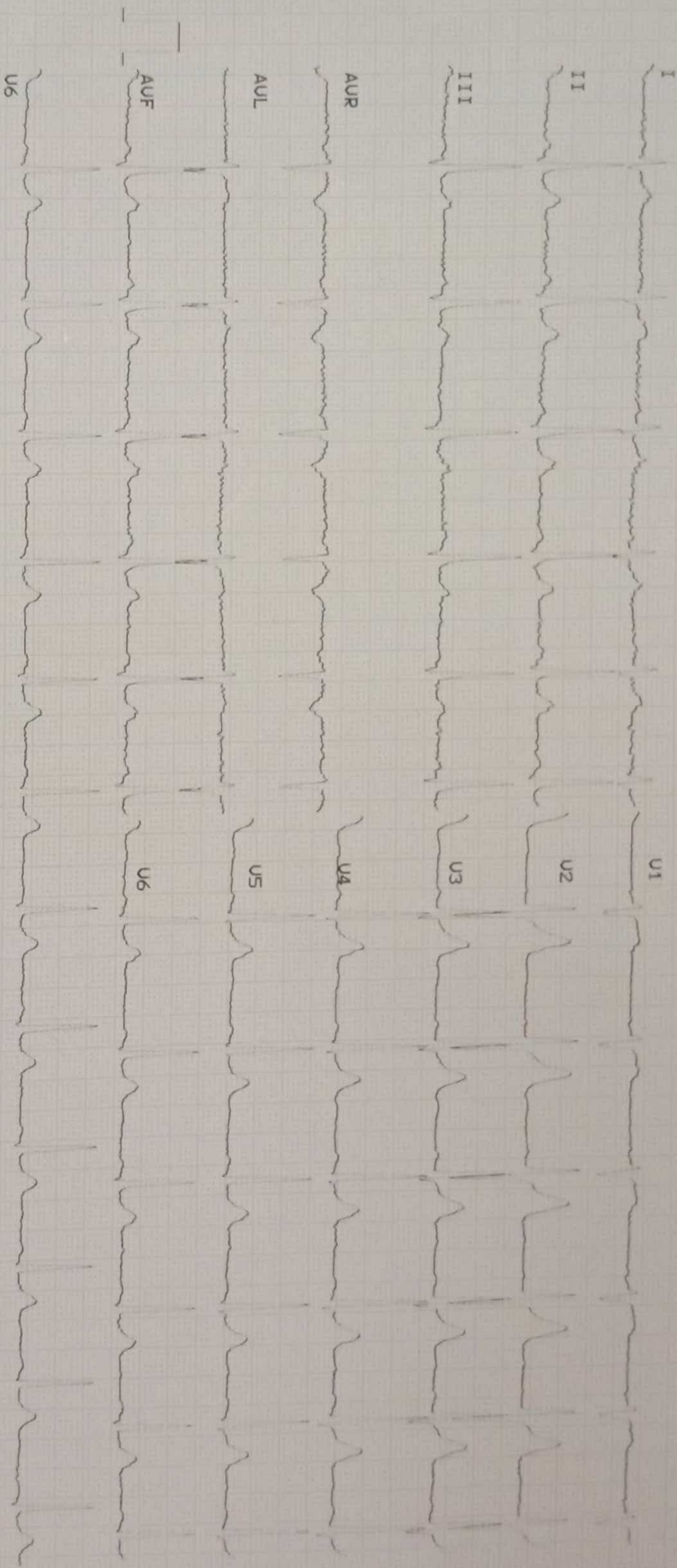
QRS	368 /	102 ms
QT/QTcB	410 ms	
PR	134 ms	
P	100 ms	
RR/PP	806 /	805 ms
P/ORS/T	70 / 90 /	60 degrees
OTD/QTcBD	64 /	71 ms
Sokolow	2.1 mV	
NK	10	



Interpretation:
 Normal sinus rhythm
 suspected right ventr hypertrophy
 minor right axis deviation
 probably abnormal ECG

Mr

Unconfirmed report.





NETHRADHAMA SUPER SPECIALITY EYE HOSPITAL

NO 1118 GEETHA ROAD, CHAMARAJAPURAM
MYSORE-570005, KARNATAKA

CASE SHEET

Name: RAJESH B

OP No: 6OP1284373

Gender: Male

Age: 38

Date: 27/01/2024

Complaint

S.No	Eye	Complaint	Duration	Type	Remarks
2	BE	FOR MEDICAL CHECK UP	1	Days	

Diagnosis

Eye	ICDCode	ICD	Version	Remarks
BE	H52.7	Disorder of refraction - H52.7 - 10	10	
BE	5357	AS WNL - 5357 - 9	9	

SCHIRMER'S Test & TBUT

IOP

Type	NCT			DVT Flag		DVT		DVT	
Target	BD	AD	CL	RE	LE	DVT1	DVT2	DVT3	DVT4
RE	13			LE					
LE	15			Time		12:00 AM	12:00 AM	12:00 AM	12:00 AM

AR

RE	SPH	CYL	AXIS	LE	SPH	CYL	AXIS
BD	+0.25	-0.50	100	BD	+0.25		
AD				AD			

Drug Used:

VisionDetail

RE	UCVA	PG	PH	LE	UCVA	PG	PH

DV	6/6			DV	6/6		
NV	N6			NV	N6		

Subjective

RE	SPH	CYL	AXIS	VA	LE	SPH	CYL	AXIS	VA
Dist	0			6/6	Dist	0			6/6
Near				N6	Near				N6

Color Vision

Chart Type	1
RE	38/38
LE	38/38
Remarks	

Recommendations

User Name	Recommendations
Dr ROOPASHREE C.R	AS BE CORNEA CLEAR, AC VH-III AND QUIET FUNDUS RE LARGE DISC, CDR 0.45, LE CDR 0.35, BE FR +, ADV REVIEW SOS/1YR

This visit was Electronically Signed by Mr. JOHN STEEPHAN on 1/27/2024 12:23:11 PM.

This visit was Electronically Signed by Dr ROOPASHREE C.R on 1/27/2024 12:33:21 PM.

NETHRADHAMA
 Super Speciality Eye Hospital
 (A Unit of Nethradhama Hospitals Pvt. Ltd
 No. 1118, Geetha Road, Chamarajapuram
 Mysore-570006 Ph : 0821-4293000