

Diwakar Diagnostic Centre
E-7/636, Arera Colony, Bhopal

1058 / NAINA YEWALE / 29 Yrs / F / 0 Cms / 0 Kg Date: 25-Mar-2023 Refd By : BOB


Report

(GEM213180307)(R)Allengers



Report :

TEST OBJECTIVE : ROUTINE CHECK UP
RISK FACTOR : FEMALE
ACTIVITY : MODERATE ACTIVE
MEDICATION : NONE
REASON FOR TERMINATION : FATIGUE, HEART RATE ACHIEVED
EXERCISE TOLERANCE : GOOD
EXERCISE INDUCED ARRHYTHMIAS : NO
HAEMODYNAMIC RESPONSE : NORMAL
CHRONOTROPIC RESPONSE : NORMAL
FINAL IMPRESSION : STRESS TEST IS NEGATIVE FOR EXERCISE INDUCED ISCHAEMIC HEART DISEASE





1058 / NAINA YEWALE / 29 Yrs / F / 0 Cms / 0 Kg Date: 25-Mar-2023 Refd By : BOB

Stage	Time	Duration	Belt Speed (mph)	Elevation	METs	Rate	% THR Achieved	BP	RPP	PVC	Comments
Supine	00:10	0:01	00.0	00.0	01.0	106	55 %	114/70	120	00	
Standing	00:29	0:01	00.0	00.0	01.0	104	54 %	114/70	118	00	
HV	00:36	0:01	00.0	00.0	01.0	104	54 %	114/70	118	00	
Warm Up	01:01	0:02	01.7	10.0	01.0	109	57 %	114/70	124	00	
ExStart	01:05	0:06	01.7	10.0	01.1	127	66 %	114/70	144	00	
BRUCE Stage 1	04:05	3:00	01.7	10.0	04.7	144	75 %	118/78	169	00	
BRUCE Stage 2	07:05	3:00	02.5	12.0	07.1	170	89 %	128/82	217	00	
PeakEx	07:10	0:07	00.0	00.0	07.2	172	90 %	128/82	220	00	
Recovery	08:09	1:00	00.0	00.0	01.2	132	69 %	118/78	155	00	
Recovery	09:09	2:00	00.0	00.0	01.0	109	57 %	114/70	124	00	
Recovery	10:09	3:00	00.0	00.0	01.0	110	58 %	114/70	125	00	
Recovery	10:15	3:05	00.0	00.0	01.0	110	58 %	114/70	125	00	

Findings :

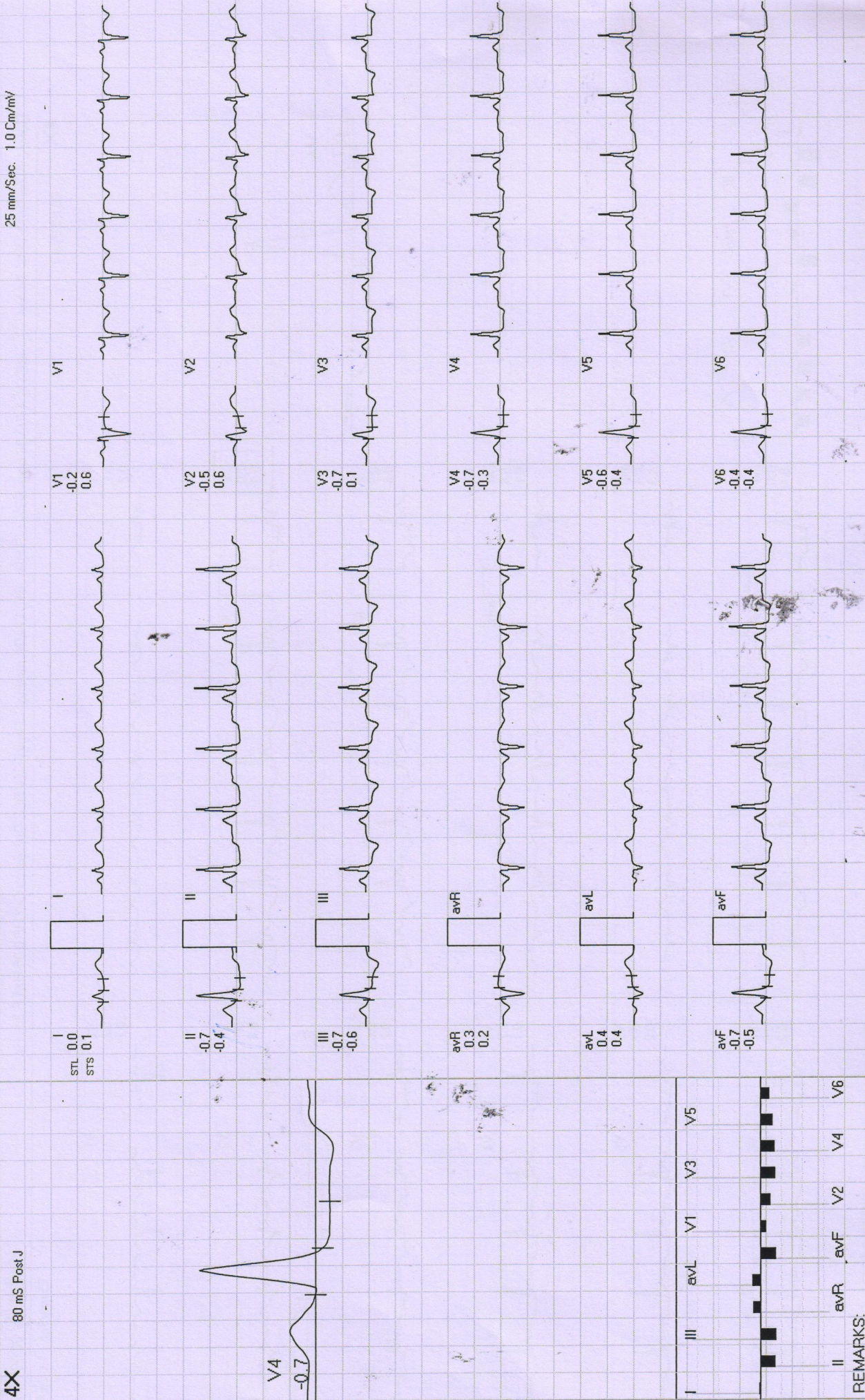
- Exercise Time : 06:06
- Max HR Attained : 172 bpm 90% of Target 191
- Max BP Attained : (Sys) 128/82
- Max WorkLoad Attained : 7.2 Fair response to induced stress
- Test End Reasons : Fatigue, Heart Rate Achieved

Date: 25-Mar-2023 11:02:34 AM METS: 1.0/ 104 bpm 54% of THR BP: 114/70 mmHg Raw ECG/ BLC On/ Match On/ HF 0.05 Hz/LF 20 Hz

ExTime: 00:28 0.0 mph, 0.0%

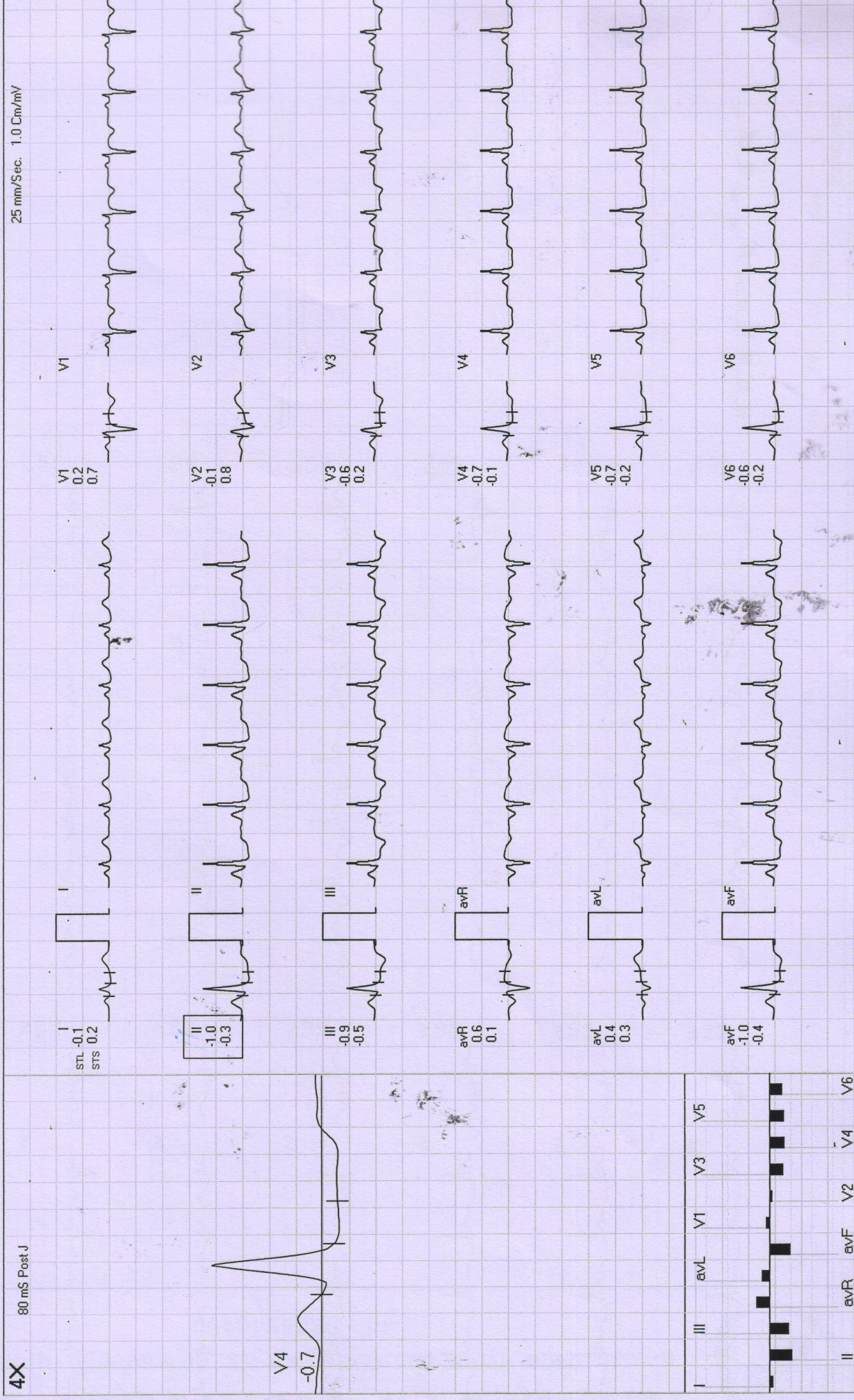
4X

80 mS Post J



Date: 25-Mar-2023 11:02:34 AM METS: 1.0 / 106 bpm 55% of THR BP: 114/70 mmHg Raw ECG/BLC On/ Notch On/ HF 0.05 Hz/LF 20 Hz

ExTime: 00:09 0.0 mph, 0.0%

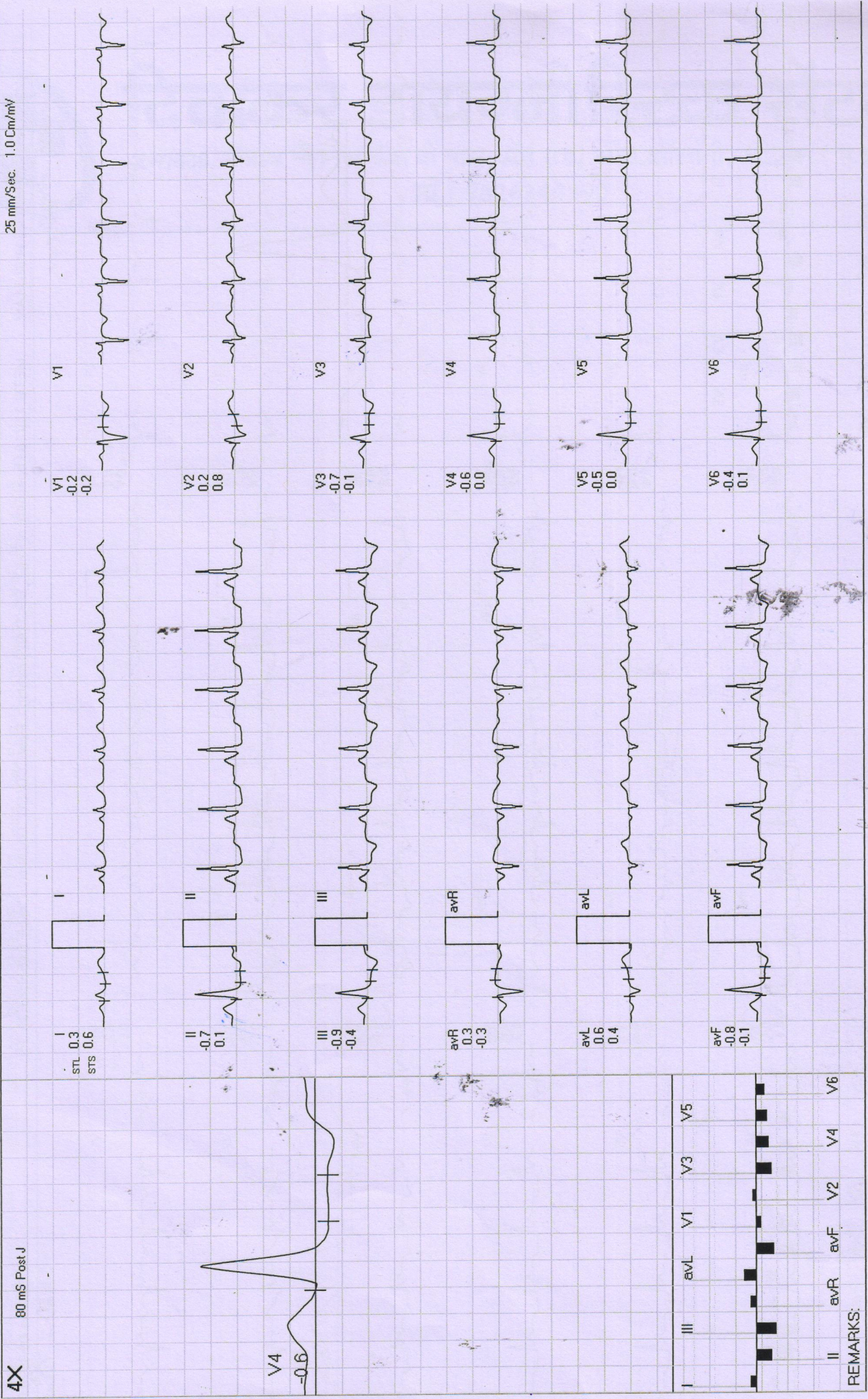




Date: 25-Mar-2023 11:02:34 AM METS: 1.0 / 109 bpm 57% of THR BP: 114/70 mmHg Raw ECG/BLC On/ Natch On/ HF 0.05 Hz/LF 20 Hz

ExTime: 01:00 1.0 mph, 0.0%

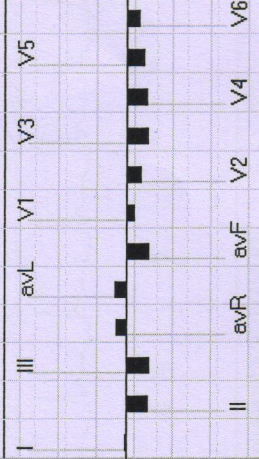
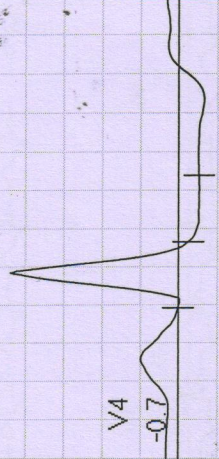
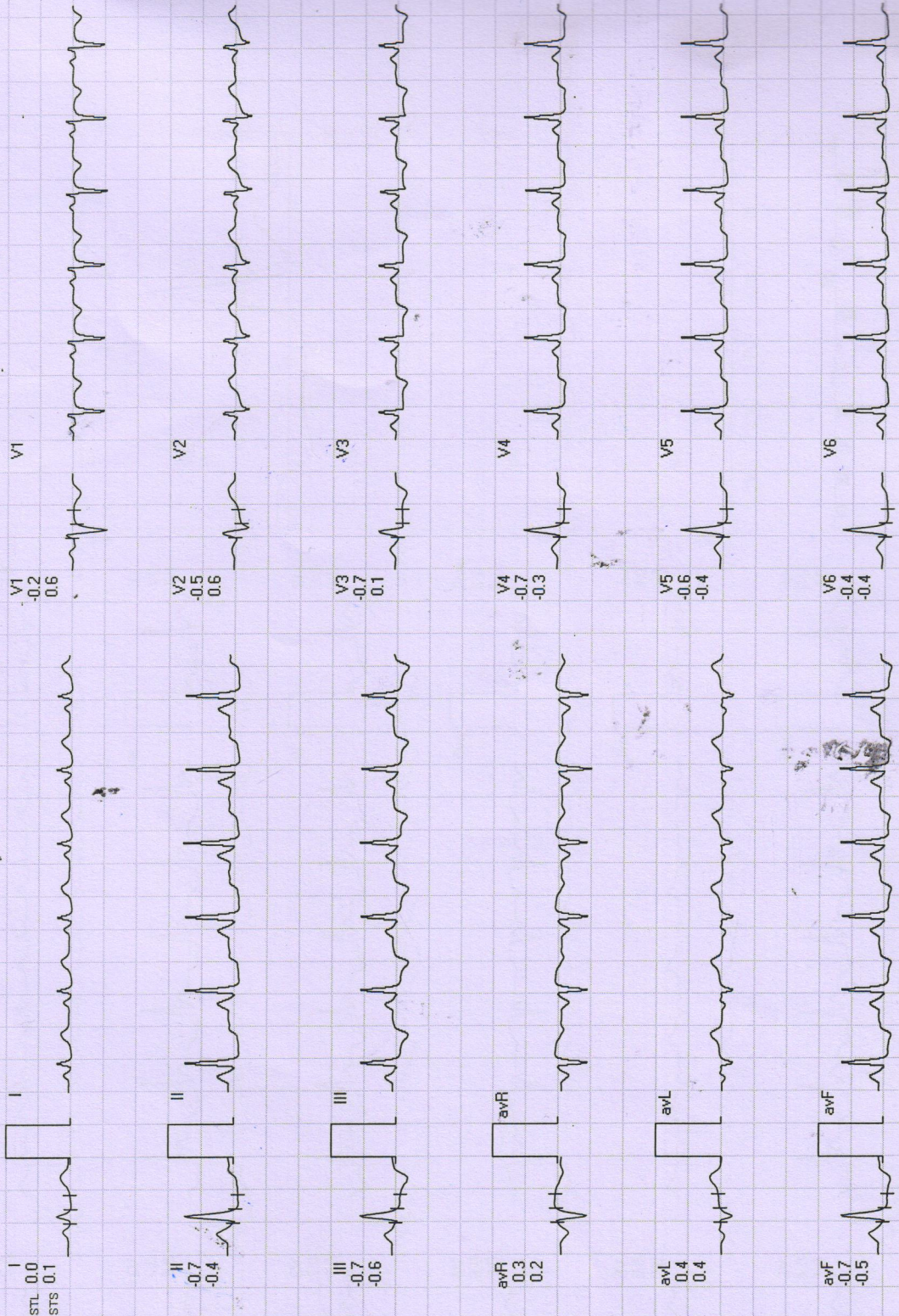
4X 80 mS Post J



REMARKS:

4X 80 mS Post J

25 mm/Sec. 1.0 Cm/mV



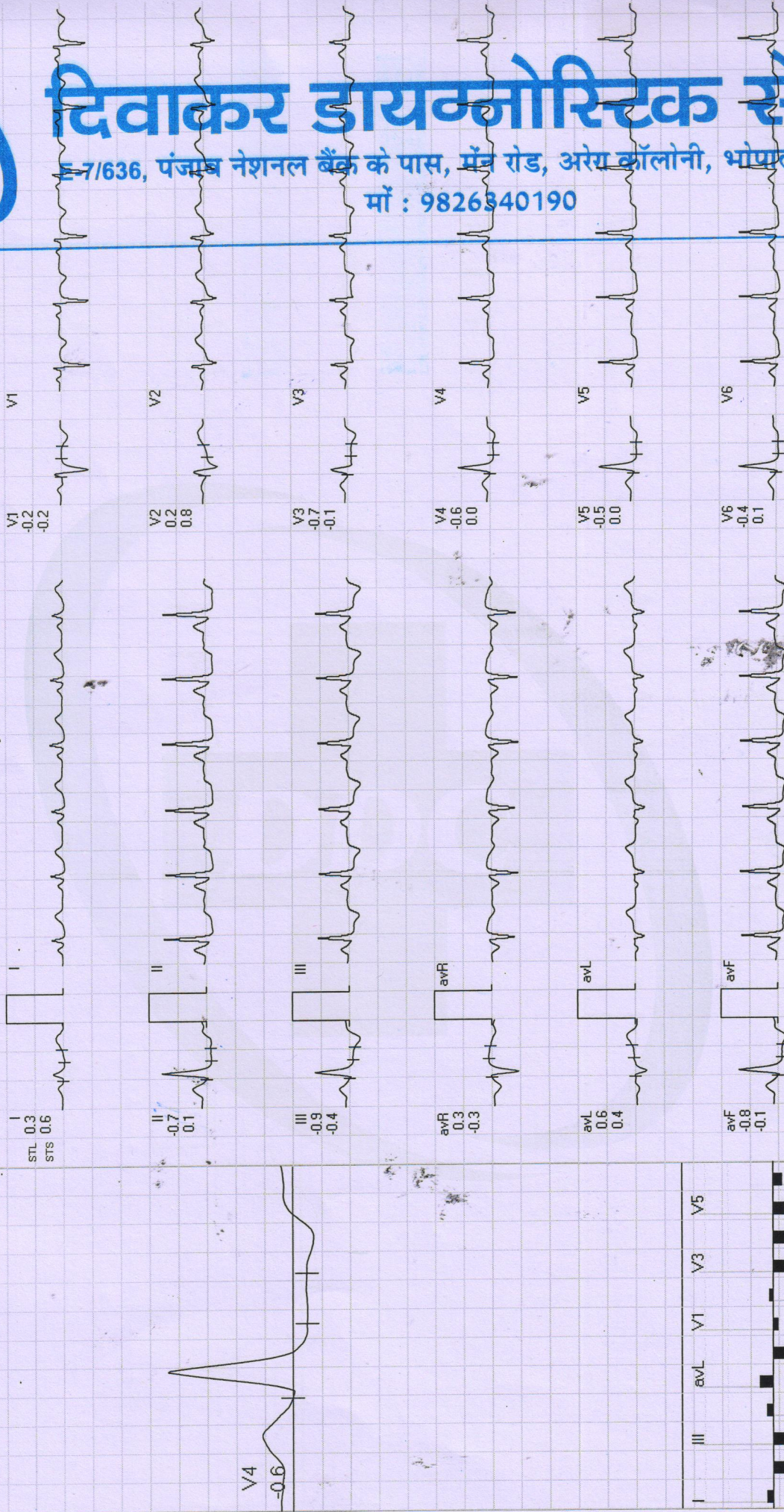
REMARKS:




ExTime: 00:30 0.0 mph 0.0%
25 mm/Sec 1.0 cm/mV

दिवाकर डायग्नोस्टिक सेंटर

7/636, पंजाब नेशनल बैंक के पास, मैन रोड, अरेग कॉलोनी, भोपाल (म.प्र.)
मॉ : 9826340190



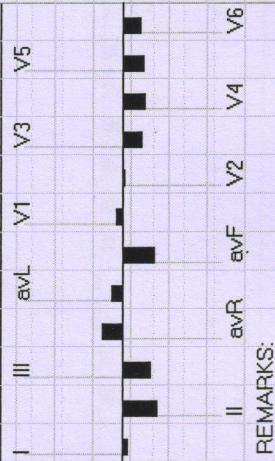
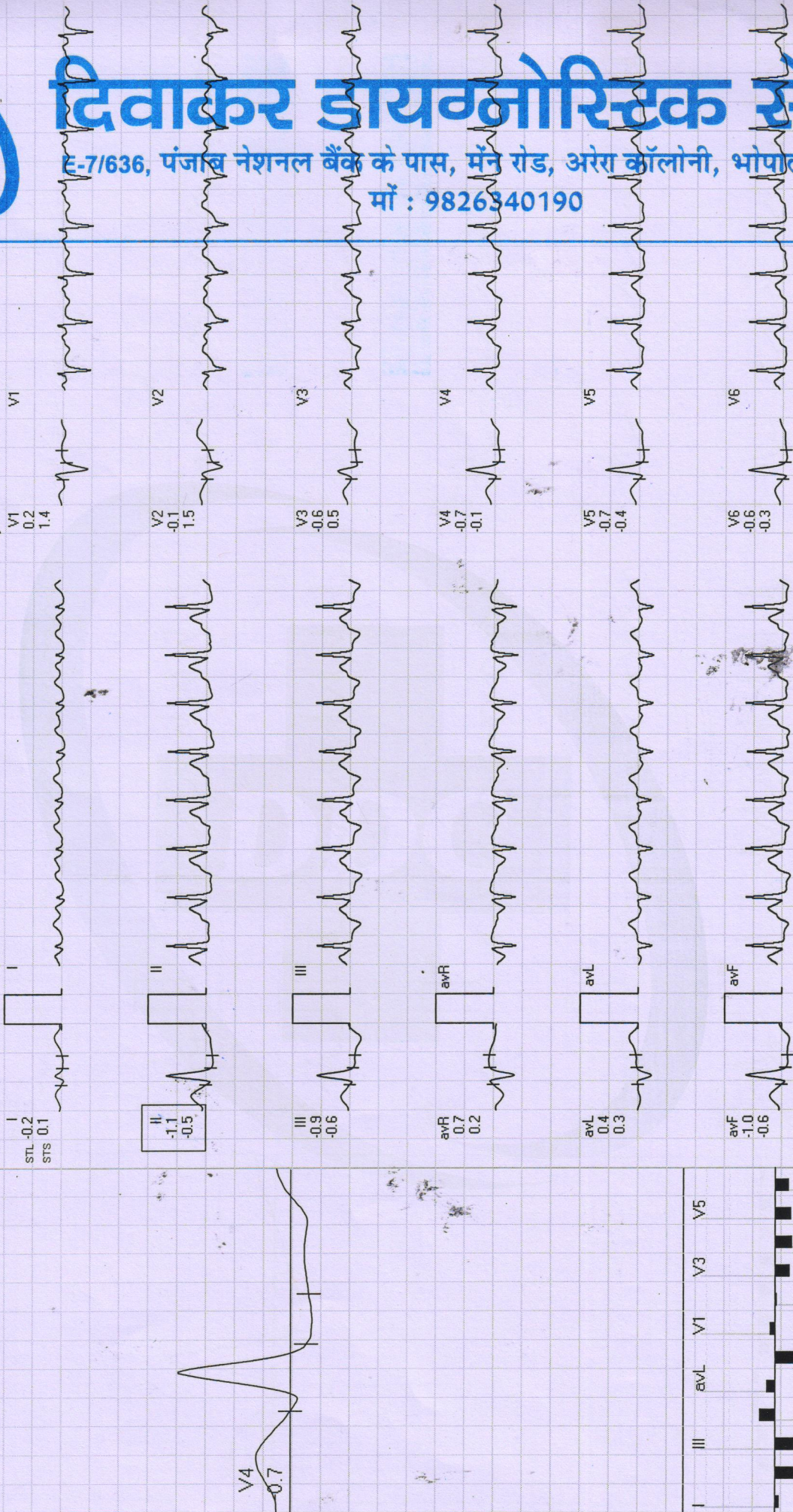
REMARKS:



ExTime: 03:00 17 mph, 10.0%
25 mm/Sec. 1.0 Cm/mV

Date: 25-Mar-2023 11:02:34 AM METS: 4.7/144 bpm 75% of THR BP: 118/78 mmHg Raw ECG/BLC On/ Notch On/ HF 0.05 Hz/LF 20 Hz

4X 60 mS Post J

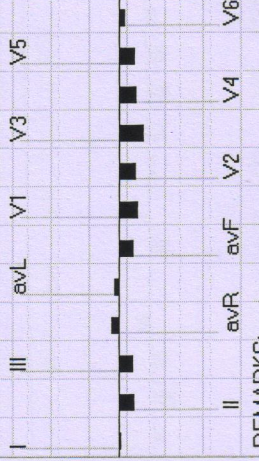

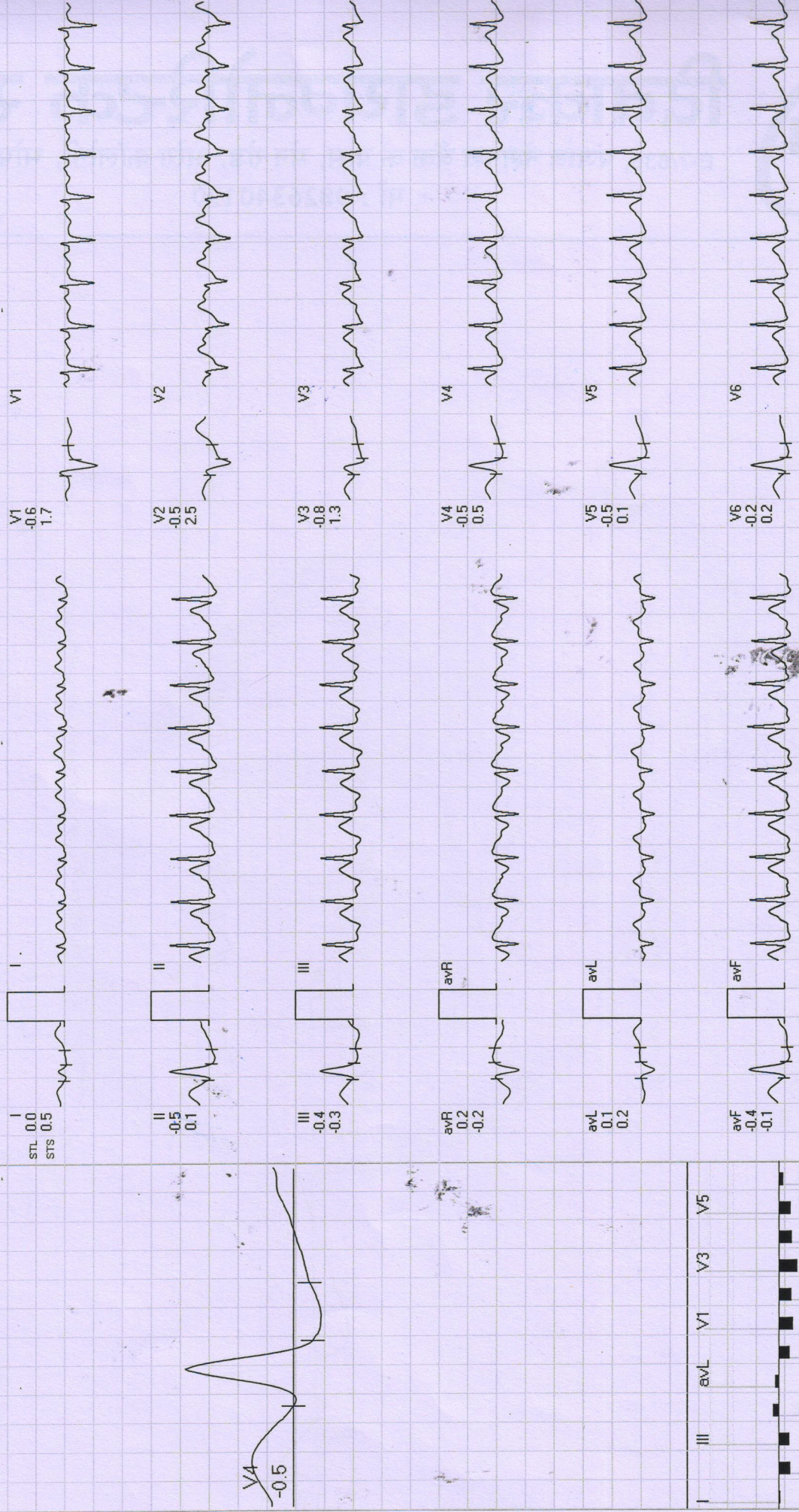


REMARKS:

दिवाकर डायग्नोस्टिक सेंटर
 E-7/636, पंजाब नेशनल बैंक के पास, मैन रोड, अरंग कॉलोनी, भोपाल (म.प्र.)
 मॉ : 9826340190

4X

60 mS Post J



REMARKS:



PeakEx

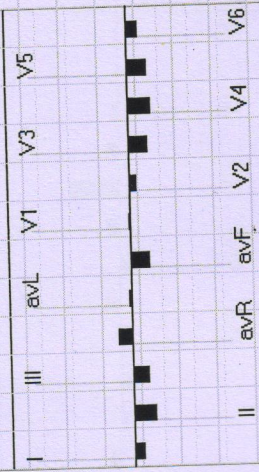

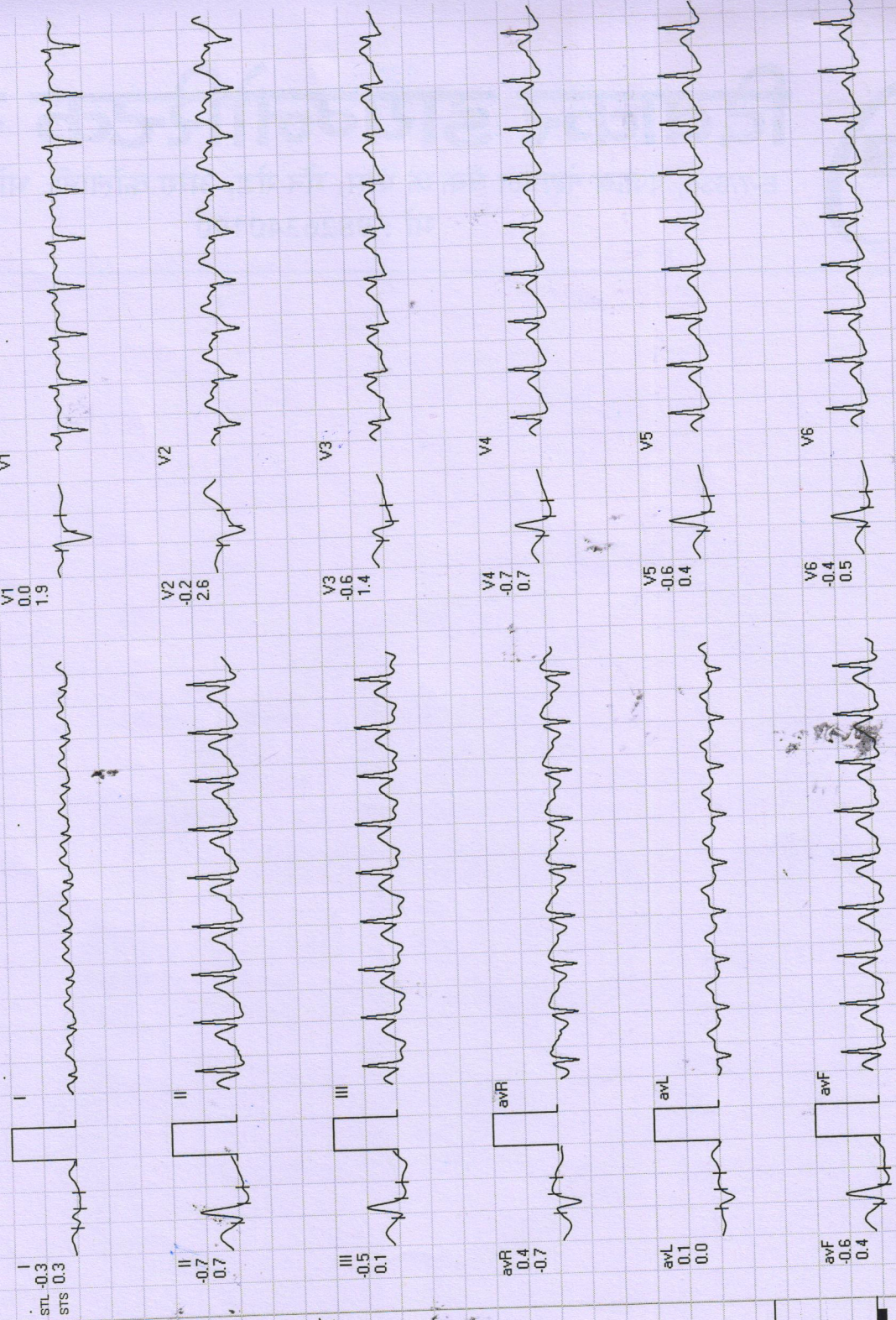
ExTime: 06:05 3.4 mph. 14.0%
25 mm/Sec. 1.0 Cm/mV

Diwakar Diagnostic Centre

1058 / NAINA YEWALE / 29 Yrs / F

Date: 25-Mar-2023 11:02:34 AM METS: 7.2 / 172 bpm 90% of THR BP: 128/82 mmHg Raw ECG/BLC On/ Natch On/ HF 0.05 Hz/LF 20 Hz

4X 60 mS Post J



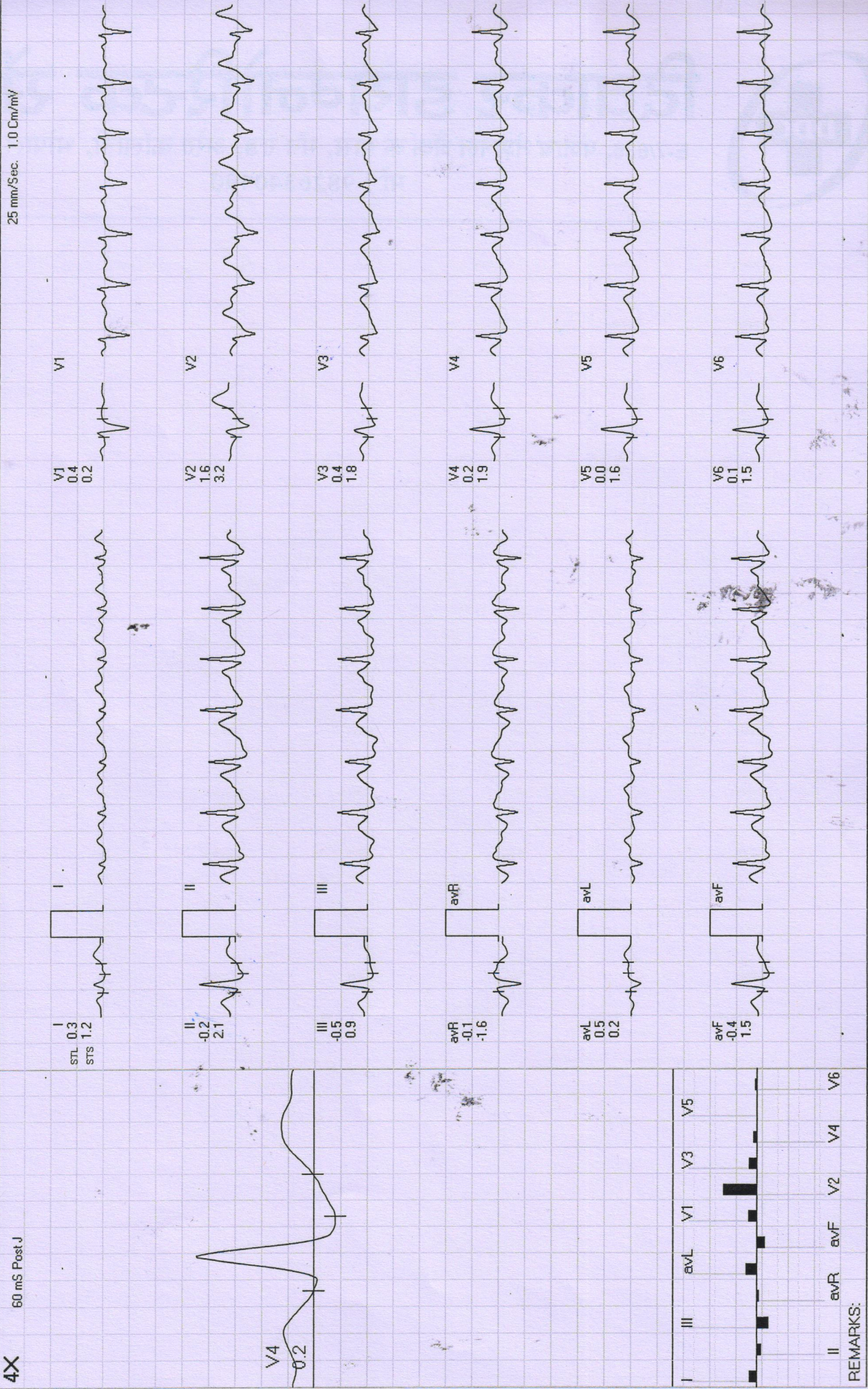
REMARKS:

(GEM213180307)(A)Allengers

Date: 25-Mar-2023 11:02:34 AM METS: 1.1/132 bpm 69% of THR BP: 118/78 mmHg Rew ECG/BLC On/ Notch On/ HF 0.05 Hz/LF 20 Hz

ExTime: 06:05 0.0 mph, 0.0%

4X 60 mS Post J



REMARKS:

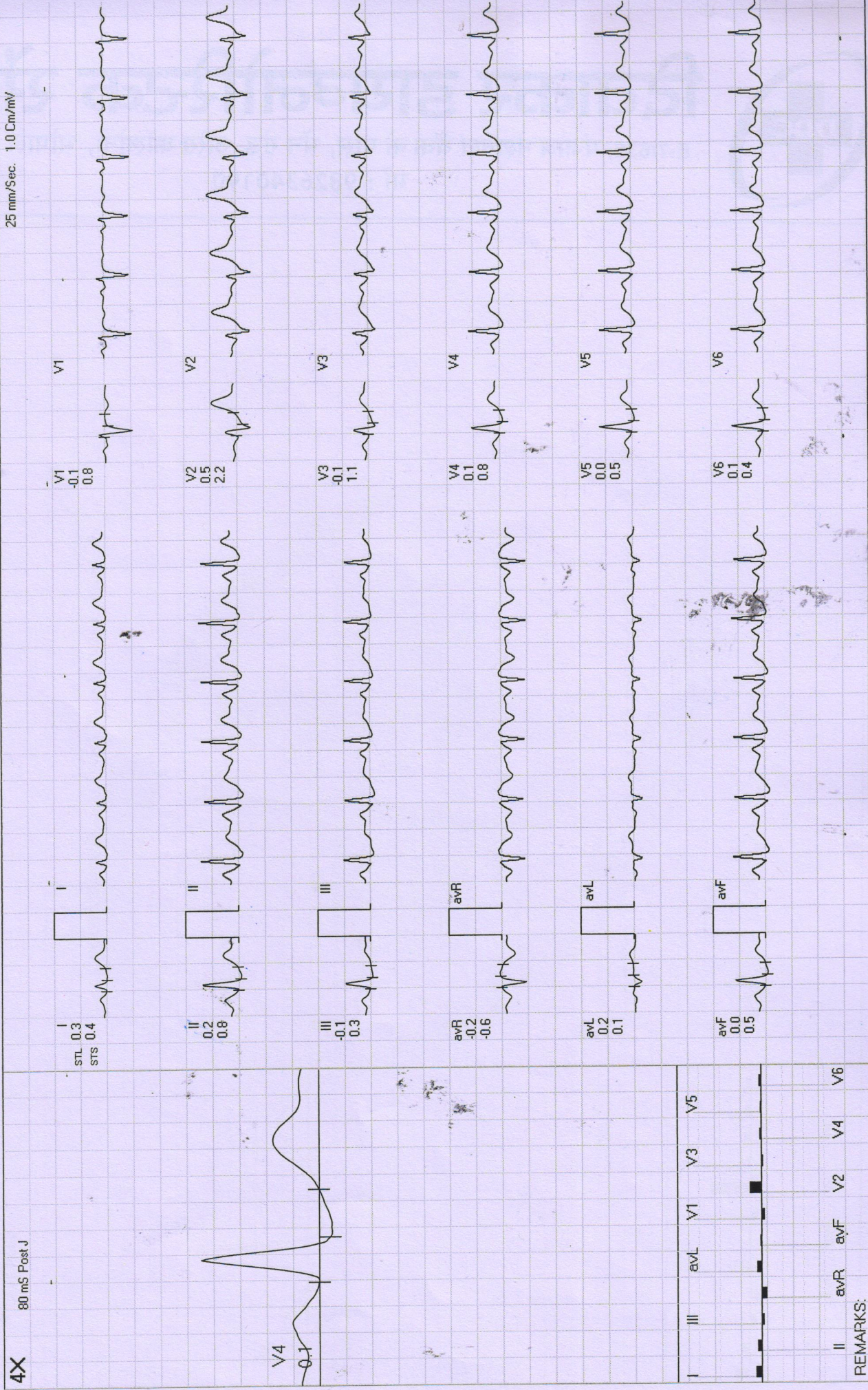


Date: 25-Mar-2023 11:02:34 AM METS: 1.0/ 109 bpm 57% of THR BP: 114/70 mmHg Raw ECG/ BLC On/ Natch On/ HF 0.05 Hz/LF 20 Hz

ExTime: 06:05 0.0 mph, 0.0%

4X

80 mS Post J

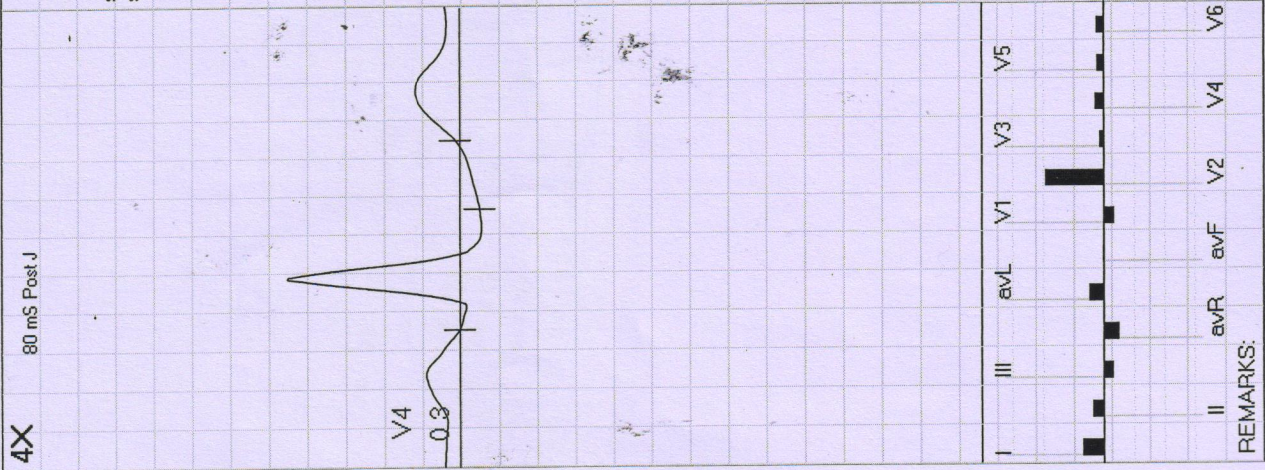


REMARKS:


Date: 25-Mar-2023 11:02:34 AM METS: 1.0/110 bpm 57% of THR BP: 114/70 mmHg Raw ECG/BLCOn/Notch On/ HF 0.05 Hz/LF 20 Hz

ExTime: 06:05 0.0 mph, 0.0%

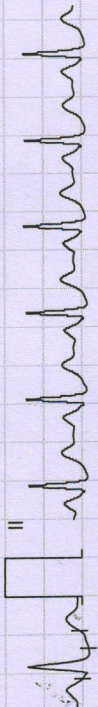
4X 80 mS Post-J



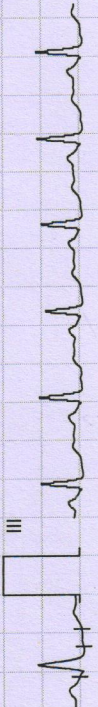
I
STL 0.7
STS 1.1



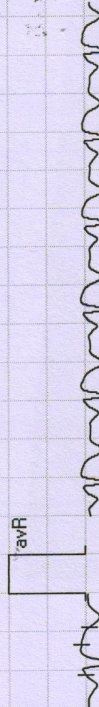II
0.3
1.4



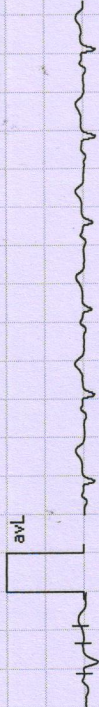
III
-0.3
0.3




avR
-0.5
-1.3



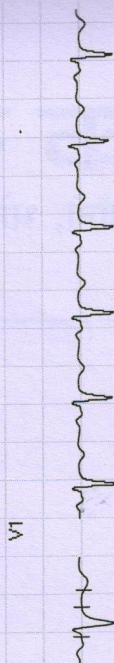
avL
0.5
0.4




avF
0.0
0.9



V1
-0.3
-0.3



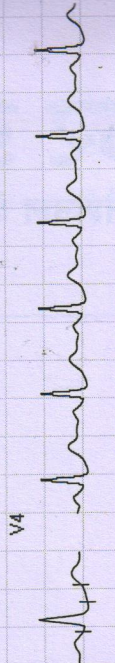
V2
1.9
2.7



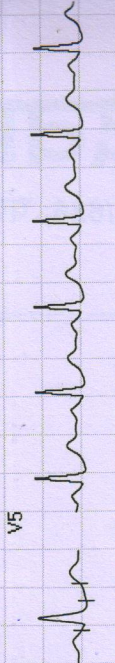
V3
0.1
0.7



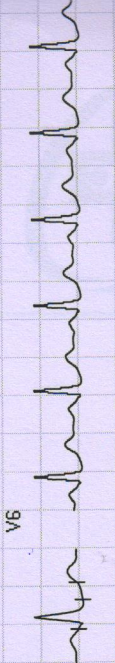
V4
0.3
1.1



V5
0.2
1.0



V6
0.2
1.0



REMARKS:

PTO

Right Kidney is normal in size, shape and position. Corticomedullary differentiation (CMD) is well maintained. Normal cortical thickness is noted. No E/O hydronephrosis or calculus is noted.

Pancreas appear normal in size, shape and echo texture with smooth contour. No peripancreatic pathology seen. (Not seen due to gases) Spleen is normal / enlarged in size and normal in echo texture. IVC and aorta appear to be normal. No evidence of lymphadenopathy is noted. No evidence of free fluid is noted.

Gall Bladder is physiologically well distended / collapsed. No E/O echogenic foci in GB lumen. GB wall is normal / thickened. No E/O pericholecystic collection. common duct reveals normal course and caliber.

Liver appears normal / enlarged in size and shape with smooth in outline. Normal / increased parenchymal echogenicity is noted. No E/O focal lesion / IHBR dilatation is seen. Hepatic veins and portal veins appear normal. No E/O Subdiaphragmatic Collection.

Indication :
WHOLE ABDOMEN ULTRASOUND REPORT

Name : Mrs. Neena Bakhar
R/B: Health Check up
Date: 25/3/23
Age: 29/F
YRS/JF

श्री. सविता सिंगानिक
34, भूल, मारिनी अदि आकेड, शाहपुरा मस्जिद के पास
भरत नगर रोड, ई-7/194, अररा कॉलोनी, भोपाल - 462038
Mob. : 8989649694, 9516333619
Clinic Registration : CL/5392/Jun/2017
PNDT Registration : MPPCPNDT/BPL/2017/206



Left Kidney is normal in size, shape and position. CMD is well maintained. Normal cortical thickness is noted. No E/O hydronephrosis or calculus is noted.

Urinary Bladder is well distended (physiological) / collapsed. Its contents are echo free. No E/O bladder wall thickening is noted. ~~Post-void residue is~~ insignificant.

Prostate is normal in size, shape and echo texture with smooth outline. No E/O focal lesion is noted.


Uterus is ante/~~retro~~ verted and normal in size, shape and echotexture with smooth outline. No E/O focal lesion is noted, endometrial echo appear normal. Cervical and vaginal shadows appear normal.

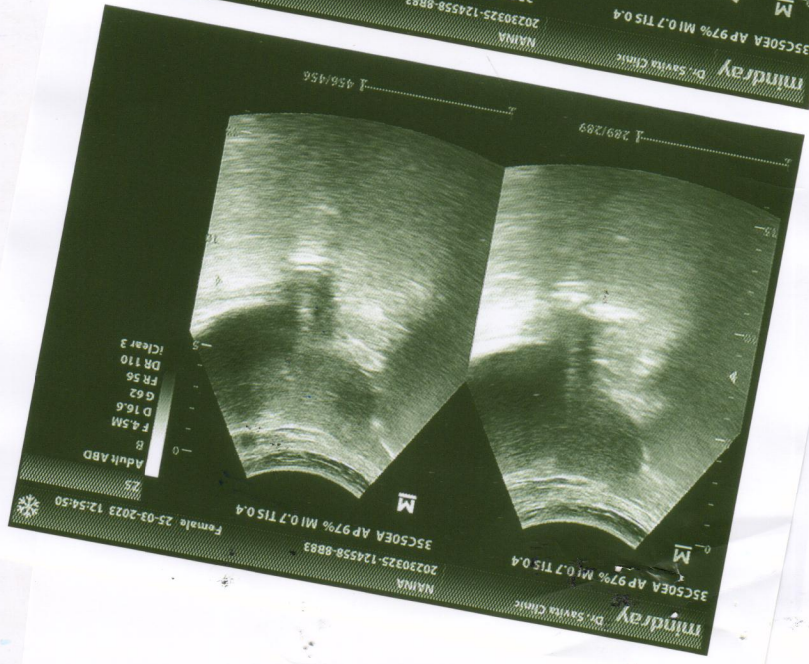
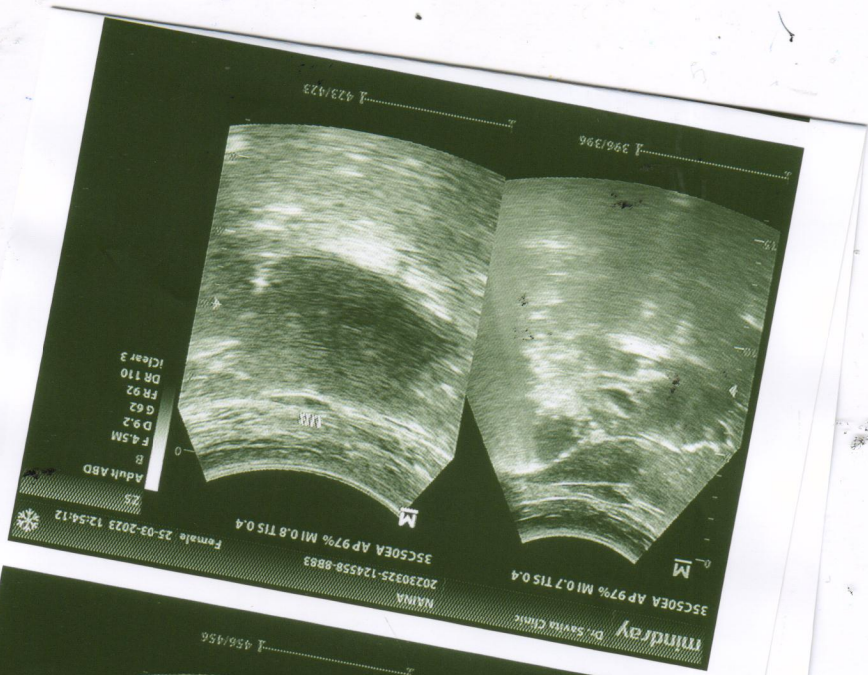
Right Ovary appears Enlarged / Normal in size, shape and echo texture.

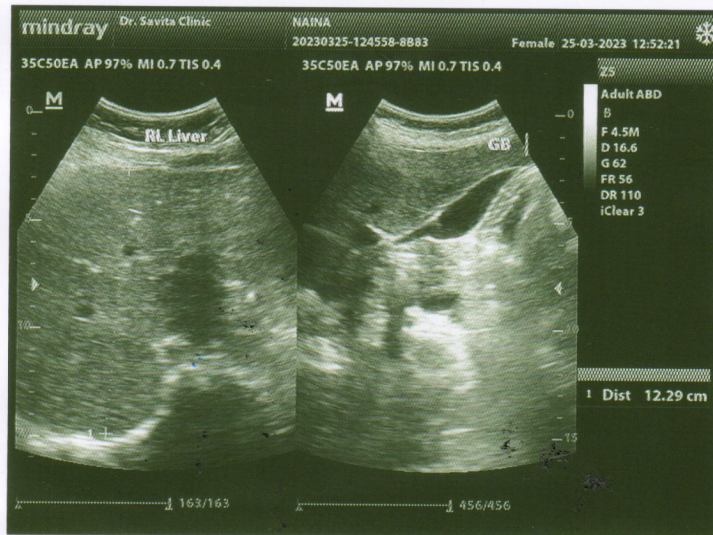
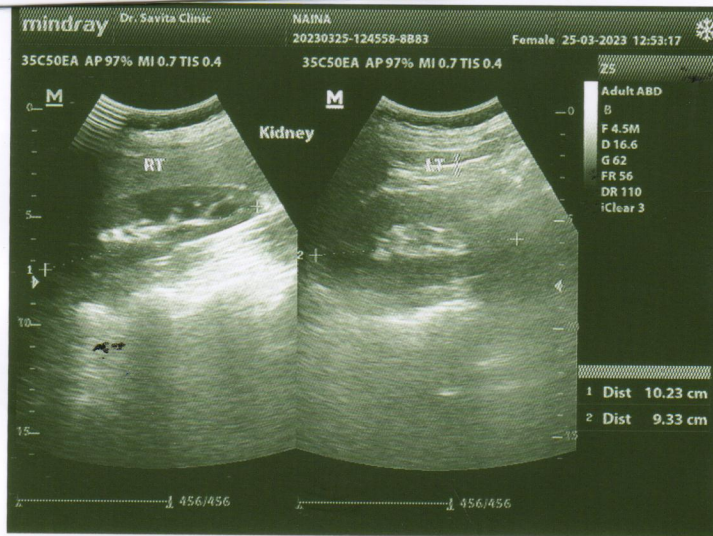
Left Ovary appears Enlarged / Normal in size, shape and echo texture.

Impression : Normal study.

Advised clinical Correlation.









दिव्यकर डायग्नोस्टिक सेंटर
 E-7/636, पंजाब नेशनल बैंक के पास, मंत्र रोड, अरुणा कॉलोनी, श्रीपाल (म.प्र.)
 फॉन : 9826340190


Pt Name :- Mrs. Naina Yawale
 Age :- 29/F
 Lab. No. :- 02
 Date :- 25/03/2023

EXAMINATION OF BLOOD

TEST	RESULT	NORMAL VALUE
Haemoglobin	10.5gms%	Female 12-16gms%, Male 14-18gms%
Red Cell count	5.15	4.5-5.6 million/cumm
Platelet Count	1.76	1.5-5.6 Lac/cumm
Leucocytes per.cumm	5800/cumm	5000-11000/cumm
Neutrophils	40%	50-70%
Lymphocytes	50%	20-40%
Eosinophils	04%	0-7%
Monocytes	06%	2-8%
PCV	33.9	37-47
MCV	65.9	76-96
MCH	20.3	27-32
MCHC	30.9	31-35
Blood Group	"O" Positive	Male 0-9, Female 0-20mm/FHR
Total Serum Cholesterol	165.0	100-250 mg%
Serum Triglyceride	130.0	Up to 150 mg%
Serum Cholesterol HDL	44.0	Up to 65 mg%
Serum Cholesterol LDL	95.0	Up to 125 mg%
LDL	26.0	Up to 30 mg%
S.Bilirubin(Total)	0.9	0.2-1.0mg/dl
Direct	0.5	0.0-0.25mg/dl
Indirect	0.4	
SGOT	25.0	5-35U/L
SGPT	31.0	8-40U/L
Alk Phosphatase	8.9	3-13 KA units
S. Protein(Total)	7.0	6.0-8.0mg%
Albumin	4.9	3.7-5.3mg%
Globulin	2.4	1.5 to 3.5 mg%
Blood Urea	22.0	Up to 40 mg%
S.Creatine	0.98	0.5-1.4mg/dl
S. Uric Acid	6.0	3.5-7.5mg%
GGTP	24.0	5-35 UL/Dl
Fasting Blood Sugar	96.2	Up to 110 mg%
Glycosylated Hemoglobin	5.2	Below - 6.0 % -Non Diabetic control
HBA1c		6-7 % -Excellent control
Thyrod Stimulating Hormone(TSH)	4.02	Above- 8 % -Poor control

Dr. B. M. Agarwal
 Pathologist
 MBBS, DCP
 Consultant Pathologist

All test have technical limitation. Collaborative clinic pathological interpretation is mandatory. In case of disparity test may be repeated immediately. Typographical mistakes should be get correct instantly. This report is not valid for medico legal purpose





डिवाकर डायग्नोस्टिक सेंटर
E-7/636, पंजाब रेगनल बँक के पास, मैन रोड, अररा कॉलोनी, थापल (म.प्र.)
फॉ : 9826340190

Pt Name :- Mrs. Naina Yawale
Age :- 29/F
Lab. No. :- 02
Date :- 25/03/2023

URINE ANALYSIS

<u>A. PHYSICAL EXAMINATION</u>	
1. Colour	Pale Yellow
2. Appearance	Clear
3. Specific Gravity	Q.N.S.
<u>B. CHEMICAL EXAMINATION</u>	
1. Reaction	Acidic
2. Albumin	Nil
3. Sugar	Nil
4. Bile Salts	Absent
<u>C. MICROSCOPIC EXAMINATION</u>	
Pus Cells	2-3/HPF
R.B.C.	Nil
Epithelial Cell	2-3/HPF
Cast	Nil
Crystals (Cal. Oxa)	Nil
Bacteria	Nil
Amorphous	Nil
T. Vaginitis	Nil

Dr. B. M. Agarwal
MBBS, DCP
Pathologist



Norma Yewale

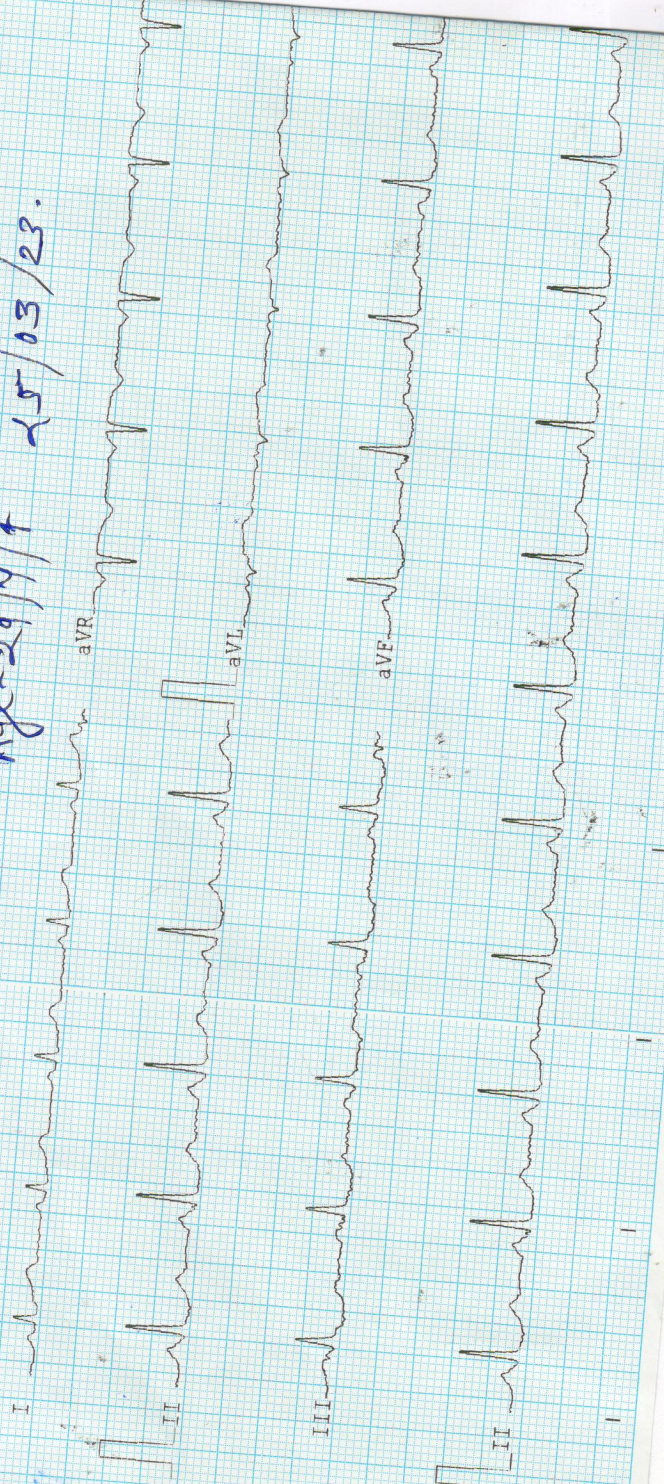
Age-29/Y/f 15/03/23

A
Patient Information
ID:
Name:
Age Y/M:
Gender:
Height: cms
Weight: Kg
BP:
Smoker:
Time/Date: 05.09:00 18-01-67

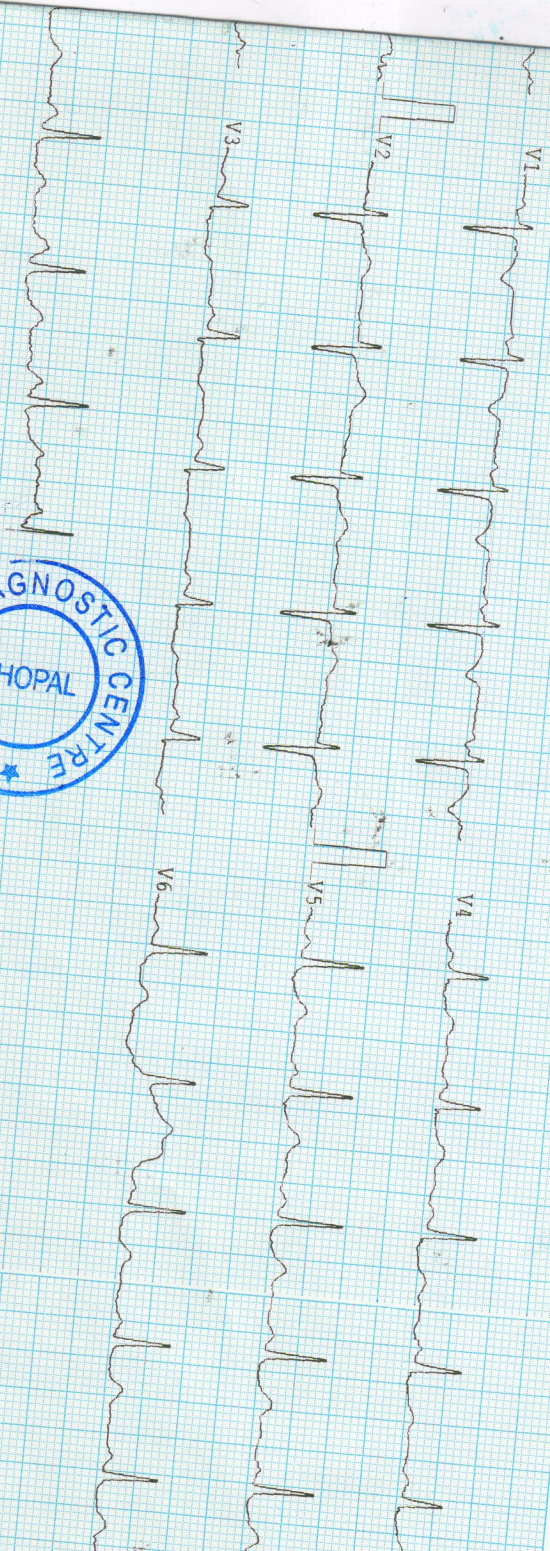

ECG Settings
Printing Mode: AUTO 3
Gain: 10 mm/mV
Speed: 25 mm/Sec
Filter: 35 Hz
Notes: ON
Rhythm Lead: II

ALLENGERS PISCES-A-103 (Ver-2.09)

ARROW CE



ARROW CE



Observations :-

HR :- 86 bpm
R-R :- 694 ms
P-R :- 066 ms
QRS :- 61 ms
QT/QTc :- 328/393 ms
P Axis :- 19 °
R Axis :- 63 °
T Axis :- 16 °

Remarks :-

Unconfirmed report

INDIAN UNION DRIVING LICENCE

Form 7



संस्कृत मंत्र

MADHYA-PRADESH STATE



Holder's Signature

Number: MPDAN-2017-0244679
Name: NAINA YEWALE
SID/W of Address: SH PRAKASH YEWALE
Address: F/1131 E-8 TRILANGA COLONY BHO PAL MP



Issued on: 02-05-2017
DOB: 12-07-1993 BG:
is Licence to drive

Vehicle Class	MCWGCR	LUM/RT
Date of Issue	02-05-2017	02-05-2017
Valid till (Transport)		
Valid till (Non-Transport)	01-05-2027	

HOLDER SIGNATURE

Authentication

SANJAY TIWARI

