

Health Check up Booking Request(bobS7476), Beneficiary Code-154275

messages

ediwheel <wellness@mediwheel.in>
 : healthcare.medicals@gmail.com
 :: customercare@mediwheel.in

Fri, Feb 2, 2024 at 2:52 PM



Mediwheel
 ...Your wellness partner

011-41195959

Dear Healthcare Medical Centre and Diagnostic

We have received a booking request for the details are following. Please provide your confirmation by clicking on the yes button.

Are you sure to confirm the booking? Yes No

Name : MS. BHATT CHARANI YASH
Package Name : Mediwheel Full Body Health Checkup Male Below 40
Package Code : PKG10000474
Location : SHOP 29, BLDG NO D-1H,SATELLITE GARDENS PHASE
 2,GOKULDHAM, NEAR SATELLITE TOWERS,GOREGAON EAST,
Contact Details : 9930860408
E-mail id : CHARANI.BHATT@bankofbaroda.com
Booking Date : 02-02-2024
Appointment Date : 03-02-2024

Member Information		
Booked Member Name	Age	Gender
Yash hemantkumar bhatt	39 year	Male

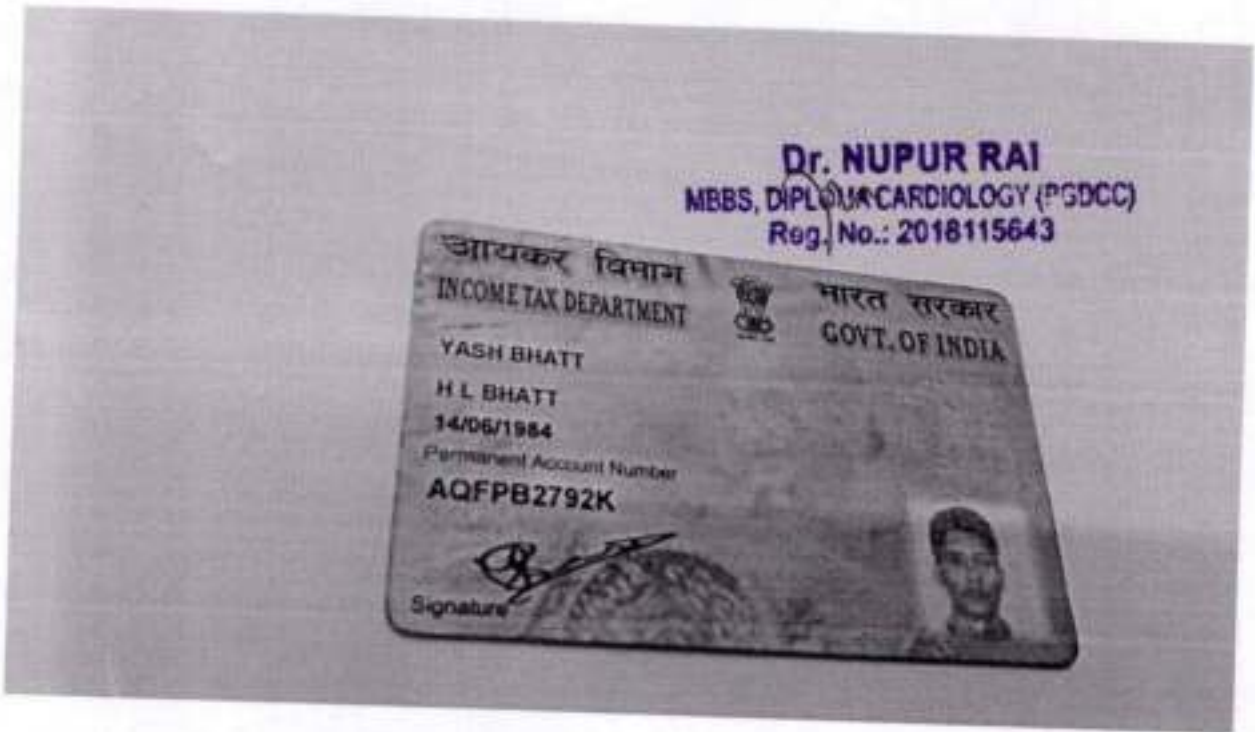
Please login to your account to confirm the same. Also you mail us for confirmation

Hospital Package Name : Mediwheel Full Body Health Checkup Male Below 40

User Package Name : Mediwheel Full Body Health Checkup Male Below 40

21 Tests included in this Package :

- Stool Test
- Thyroid Profile
- ESR
- Blood Glucose (Fasting)
- General Physician Consultation
- TMT OR 2D ECHO
- Blood Group
- Blood Glucose (Post Prandial)
- Chest X-ray
- ECG
- USG Whole Abdomen
- Eye Check-up consultation
- Urine Sugar Fasting
- Urine Sugar PP
- Dental Consultation
- Urine analysis
- CBC
- HbA1c
- Lipid Profile
- Kidney Profile
- Liver profile



Dr. NUPUR RAI
 MBBS, DIPLOMA IN CARDIOLOGY (PGDCC)
 Reg. No.: 2018115643

(Handwritten signature)

HEALTHCARE MEDICAL CENTRE & DIAGNOSTICS
 Satellite Gardens, Film City Road,
 Near Satellite Tower, Goregaon (E), Mumbai - 400063.
 Ph.- 40126565 / 7977374838 / 7977362922



- COMPU. PATHOLOGY • ALLERGY TESTING
- DIGITAL WHOLE BODY X-RAYS
- DIGITAL 3D SONOGRAPHY
- DIGITAL WHOLE BODY COLOUR DOPPLER
- DIGITAL 2-D ECHO WITH COLOUR DOPPLER
- E.C.G. • LUNG FUNCTION TEST
- MAMMOGRAPHY & BONE MINERAL DENSITOMETRY

- COMPUTERISED STRESS TEST
- DENTAL
- ADVANCED DENTISTRY
- PHYSIOTHERAPY
- AUDIOMETRY & SPEECH THERAPY
- FULL BODY HEALTH CHECK-UPS
- CORPORATE HEALTH CHECKUPS



HEALTHCARE

MEDICAL CENTRE & DIAGNOSTICS

NAME	MR YASH BHATT	DATE	03/02/2024
HEIGHT: 181 CM	WEIGHT : 69.7 KG	AGE	39 YRS
REFERRED BY	MEDIWHEEL	SEX	MALE
PRESENT COMPLAINT: NIL			
CURRENT MEDICATION: NIL			
PAST HISTORY : H/O RIGHT KNEE LIGAMENT SURGERY			
ALLERGY: NIL	BOWEL: NORMAL	APPETITE: GOOD	
HABITS: NIL	SLEEP: NORMAL	BLADDER: NORMAL	
FAMILY HISTORY: MOTHER H/O CA COLONE /UTERUS			
GENERAL EXAMINATION:		ADVICE-	
BP: 128/76 MMHG P: 67 /MIN		<i>Fit for employment</i>	
PALLOR: NAD			
OEDEMA: NAD			
ICTERUS: NAD			
OTHERS: NAD			
RS: AE BE CLEAR			
CVS: S1S2 NAD			
PA: NAD			
CNS: NAD			
INVESTIGATION:			

[Signature]
Dr. NUPUR RAI
 MBBS, DIPLOMA CARDIOLOGY (PGDCC)
 Reg. No: 2018115843
 DR. Y. P. MEHTA [M.D.]

HEALTHCARE MEDICAL CENTRE & DIAGNOSTICS
 Satellite Gardens, Film City Road,
 Near Satellite Tower, Corogoon (E), Mumbai - 400063.
 Ph.- 40126565 / 7977374834 / 7977362922

- COMPU. PATHOLOGY • ALLERGY TESTING
- DIGITAL WHOLE BODY X-RAYS
- DIGITAL 3D SONOGRAPHY
- DIGITAL WHOLE BODY COLOUR DOPPLER
- DIGITAL 2-D ECHO WITH COLOUR DOPPLER
- E.C.G. • LUNG FUNCTION TEST
- MAMMOGRAPHY & BONE MINERAL DENSITOMETRY

- COMPUTERISED STRESS TEST
- DENTAL
- ADVANCED DENTISTRY
- PHYSIOTHERAPY
- AUDIOMETRY & SPEECH THERAPY
- FULL BODY HEALTH CHECK-UPS
- CORPORATE HEALTH CHECKUPS



DENTAL CHECK UP

NAME	Mr. Yash Bhatt	DATE	03/02/21
REFERRED BY	Meekulmet	AGE - 59 YRS 3	SEX M

CHIEF COMPLAINT :	NIL
PAST DENTAL HISTORY :	NIL
HABITS :	NIT
ORAL EXAMINATION :	<p>O/E orally hygiene</p> <ul style="list-style-type: none"> - No plaque formation - No teeth staining - NO Mouth Ulcers
TREATMENT :	

HEALTHCARE MEDICAL CENTRE & DIAGNOSTICS
 Satellite Gardens, Film City Road,
 Near Satellite Tower, Goregaon (E), Mumbai - 400083.
 Ph. - 40126565 / 7977374838 / 7977382922

- COMPUT. PATHOLOGY - ALLERGY TESTING
- DIGITAL WHOLE BODY X-RAYS
- DIGITAL 3D SONOGRAPHY
- DIGITAL WHOLE BODY COLOUR DOPPLER
- DIGITAL 2-D ECHO WITH COLOUR DOPPLER
- E.C.G. - LUNG FUNCTION TEST
- MAMMOGRAPHY & BONE MINERAL DENSITOMETRY

- COMPUTERISED STRESS TEST
- DENTAL
- ADVANCED DENTISTRY
- PHYSIOTHERAPY
- AUDIOMETRY & SPEECH THERAPY
- FULL BODY HEALTH CHECK-UPS
- CORPORATE HEALTH CHECKUPS



NAME	MR YASH BHATT	DATE	03.02.2024
INVESTIGATION	X-RAY CHEST PA	AGE	39 YRS
REF. BY DR.	MEDIWHEEL	SEX	MALE

X-RAY CHEST (PA VIEW)

Both the lungs are equally translucent

The cardiac & aortic silhouettes are normal.

The pleural spaces are clear.

No hilar or mediastinal mass is seen.

Domes of diaphragm are normal in position and contour.

No skeletal abnormality is seen.

CONCLUSION : NO EVIDENCE OF PULMONARY, PLEURAL OR CARDIAC PATHOLOGY IS NOTED.

Report with compliments to **MEDIWHEEL**

Thank you for the opportunity to participate in the care of your patient.
Please bring this report next time for comparison.

DR. DHANANJAY RASTOGI
{CONSULTING RADIOLOGIST}
(MBBS , DMRD.)

- COMPU. PATHOLOGY • ALLERGY TESTING
- DIGITAL WHOLE BODY X-RAYS
- DIGITAL 3D SONOGRAPHY
- DIGITAL WHOLE BODY COLOUR DOPPLER
- DIGITAL 2-D ECHO WITH COLOUR DOPPLER
- E.C.G. • LUNG FUNCTION TEST
- MAMMOGRAPHY & BONE MINERAL DENSITOMETRY

- COMPUTERISED STRESS TEST
- DENTAL
- ADVANCED DENTISTRY
- PHYSIOTHERAPY
- AUDIOMETRY & SPEECH THERAPY
- FULL BODY HEALTH CHECK-UPS
- CORPORATE HEALTH CHECKUPS



HEALTHCARE

MEDICAL CENTRE & DIAGNOSTICS

NAME	MR YASH BHATT	DATE	03.02.2024
INVESTIGATION	USG ABDOMEN & PELVIS	AGE	39YRS
REF. BY DR.	MEDIWHEEL	SEX	MALE

REAL TIME ABDOMINAL ULTRASOUND REPORT

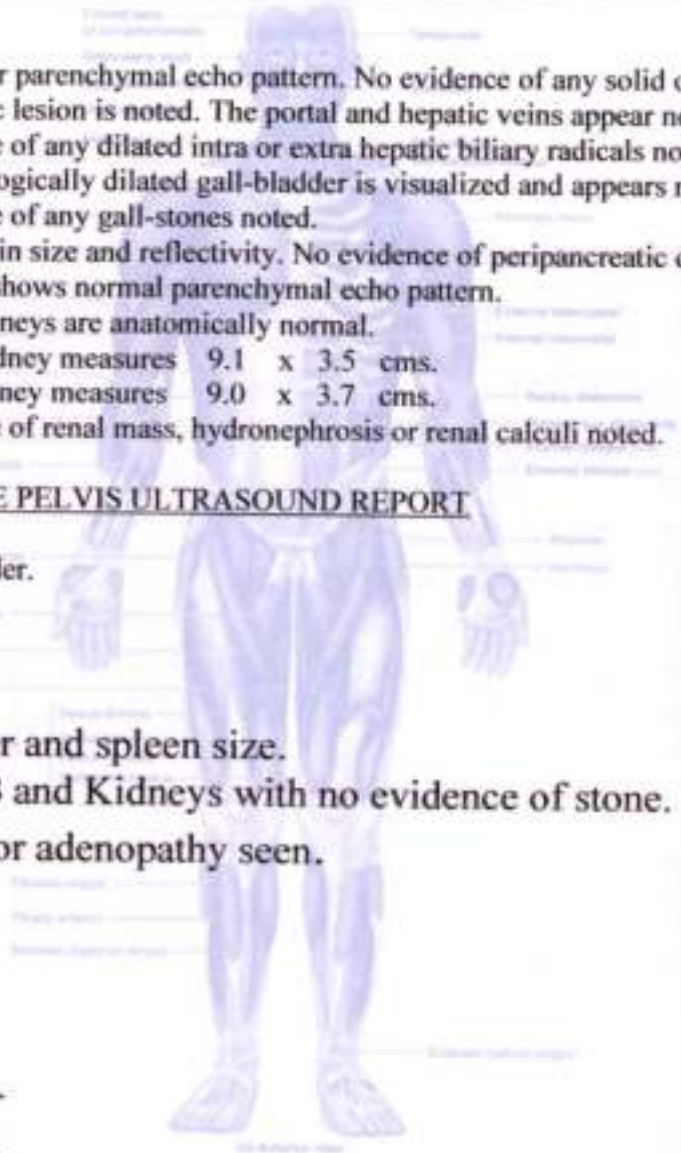
- LIVER** : Normal liver parenchymal echo pattern. No evidence of any solid or cystic intra-hepatic lesion is noted. The portal and hepatic veins appear normal. No evidence of any dilated intra or extra hepatic biliary radicals noted.
- GALL-BLADDER**: The physiologically dilated gall-bladder is visualized and appears normal. No evidence of any gall-stones noted.
- PANCREAS** : It is normal in size and reflectivity. No evidence of peripancreatic collection is seen.
- SPLEEN** : The spleen shows normal parenchymal echo pattern.
- KIDNEYS** : Both the kidneys are anatomically normal.
 The right kidney measures 9.1 x 3.5 cms.
 The left kidney measures 9.0 x 3.7 cms.
 No evidence of renal mass, hydronephrosis or renal calculi noted.

REAL TIME PELVIS ULTRASOUND REPORT

- Anatomically normal urinary bladder.
- Prostate corresponding to 21 gms.

- CONCLUSION:** Normal liver and spleen size.
 Normal GB and Kidneys with no evidence of stone.
 No ascites or adenopathy seen.

DR. DHANANJAY RASTOGI
 {CONSULTING RADIOLOGIST}
 (MBBS , DMRD.)



- COMPU. PATHOLOGY
- DIGITAL X-RAY
- DIGITAL SONOGRAPHY
- DIGITAL COLOR DOPPLER
- 2D ECHO CARDIOGRAPHY
- MAMMOGRAPHY & BONE MINERAL DENSITOMETRY (BMD)
- ECG ■ PFT
- COMPU. TREADMILL TEST
- PHYSIOTHERAPY
- DENTAL
- HEALTH CHECK-UP



MEDICAL CENTRE & DIAGNOSTICS

ELECTROCARDIOGRAM (ECG)

MR YASH BHATT

ELBAJ587 03-Feb-2024



ECG

PATIENT MR. Yash Bhatt

AGE 39 SEX Male

REF. BY DR. Mediwheel

DATE 3/2/24

INTERPRETATION : Normal

Dr. N

HEALTHCARE MEDICAL CENTRE & DIAGNOSTICS
 Satellite Gardens, Firoz City Road,
 Satellite Tower, Gurgaon (Haryana) - 100063,
 Ph: 40126563 / 7977374600 / 7977374322

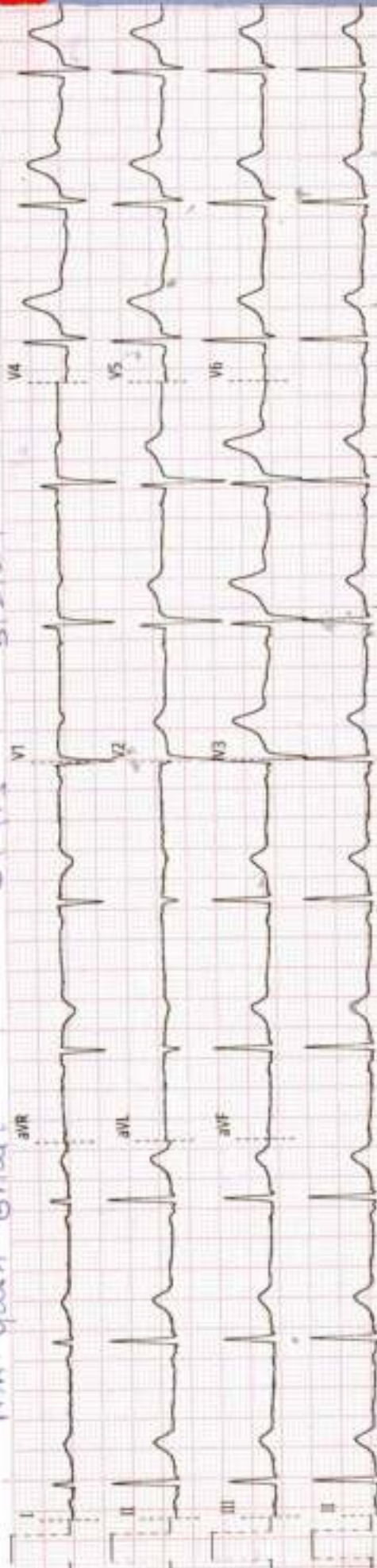Dr. NUPUR RAI

MBBS, DIPLOMA IN RADIOLOGY (DRCCL)
 Reg. No.: 2018115643

MR. YASH GHATT

39 yrs

3/2/24



0.6Hz - 35Hz - AC 50Hz 25mm/s 10mm/mV IMAC 300 1.0.25 Sequential

AG

History :

B.P. :

Drugs :

Standard :

Auricular Rate : 76 bpm

Ventricular Rate : 76

Rhythm : NS

Mechanism :

Voltage :

Axis :

P. Waves :

PR Interval :

Q. Waves :

QRS Interval : (N)

ST Segment :

T. Waves :

QT Interval :

Extra Systoles :

REMARKS & CONCLUSIONS : None

- COMPU. PATHOLOGY - ALLERGY TESTING
- DIGITAL WHOLE BODY X-RAYS
- DIGITAL 3D SONOGRAPHY
- DIGITAL WHOLE BODY COLOUR DOPPLER
- DIGITAL 2-D ECHO WITH COLOUR DOPPLER
- E.C.G. - LUNG FUNCTION TEST
- MAMMOGRAPHY & BONE MINERAL DENSITOMETRY

- COMPUTERISED STRESS TEST
- DENTAL
- ADVANCED DENTISTRY
- PHYSIOTHERAPY
- AUDIOMETRY & SPEECH THERAPY
- FULL BODY HEALTH CHECK-UPS
- CORPORATE HEALTH CHECKUPS



HEALTHCARE

MEDICAL CENTRE & DIAGNOSTICS

DATE: 03/02/24

TO,

Mediuhet

This is regarding your client Miss/Mrs./Mr. Yash Bhatt

Proposal number _____

Visited to our centre on 03/02/24 for her/his proposed tests.

All tests are done as scheduled except

Pending/skipped tests: ophthalmological (eye checkup)

Reason: It is already done outside.

We are canceling / will reschedule it as per her/his convenience.

Thank you.

Client's sign

HEALTHCARE MEDICAL CENTRE & DIAGNOSTICS
 Seresta Gardens, Film City Road,
 Near Satellite Tower, Goregaon (E), Mumbai - 400063.
 Ph.- 40126665 / 7917374535 / 7917352922

Dr. NUPUR RAI
 MBBS, Medical Radiology (F.S.DCC)
 Medical Examiner
 Reg. No.: 2018115543

HEALTHCARE MEDICAL CENTRE & DIAGNOSTICS

FILM CITY ROAD GOREGAON EAST MUMBAI 400063

MR YASH BHATT
 ID : 683
 DATE : 03-02-2024
 AGE/SEX : 39 / M
 HT/WT : 181 / 69
 REF. BY : MEDIMBESL

TREADMILL TEST REPORT
 PROTOCOL : BRUTE
 HISTORY : Checked/Physical fitness,
 INDICATION : CARDIAC EVALUATION FOR ANNUAL CHECKUP
 MEDICATION : NONE

STAGE	TOTAL TIME	STAGE TIME	SPEED Km/Hr	GRATE %	H.R. bpm	B.P. mmHg	RRP x100	ST-TAVELS (MM)			METS
								II	V1	V5	
SUBLINE											
STANDING					96	128 / 76	110	1	-0.2		1.4
WARMUP					94	129 / 76	101	1	-0.1		1.4
Stage 1	2:55	0:6	2.7	10	94	128 / 76	101	0.9	-0.2		1.3
Stage 2	5:55	2:55	4	12	108	130 / 80	140	0.6	-0.1		1.1
PR-EXERCISE	8:25	2:25	5.4	14	127	140 / 90	177	0	0		1.1
RECOVERY 1	9:38	0:58			163	150 / 100	244	-0.3	-0.2		1.1
RECOVERY 1	10:40	2:0			131	140 / 90	183	1	-0.1		2.2
RECOVERY 2	11:35	2:55			115	130 / 80	149	0.3	0.3		1.2
RECOVERY 2					109	120 / 70	129	-0.1	0.3		1

RESULTS

EXERCISE DURATION : 8:25
 MAX HEART RATE : 163 bpm 90 % of target heart rate 181 bpm
 MAX BLOOD PRESSURE : 150 / 100 mm Hg
 REASON OF TERMINATION : Achieved THR,
 BP RESPONSE : Normal,
 ARRYTHMIA : None,
 H.R. RESPONSE : Normal Chronotropic Response,
 IMPRESSIONS :
 FAIR EFFORT, TOLERANCE
 NO ANGINA
 NO ARRYTHMIA
 NORMAL HR, BP RESPONSE
 NO SIGNIFICANT ST CHANGES NOTED DURING TEST AS COMPARED TO ECG
 STRESS TEST NEGATIVE FOR INDUCIBLE ISCHEMIA

MAX WORK LOAD : 9.44 METS

HEALTHCARE MEDICAL CENTRE & DIAGNOSTICS
 Satellite Gardens, Film City Road,
 Near Satellite Tower, Carvecon (E), Mumbai - 400063.
 Ph. 40126565 / 7977374838 / 7977352922

Technician : 1

Dr. NUPUR RAI
 MBBS, DIPLOMA CARDIOLOGY (PGDCC)
 Reg. No.: 2018115643

(MD)

HEALTHCARE MEDICAL CENTRE & DIAGNOSTICS

MR YASH BHATT
I.D. 653
Age 39/M
Date 03-02-2024

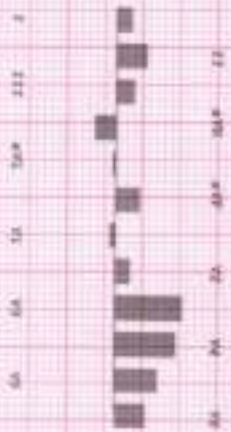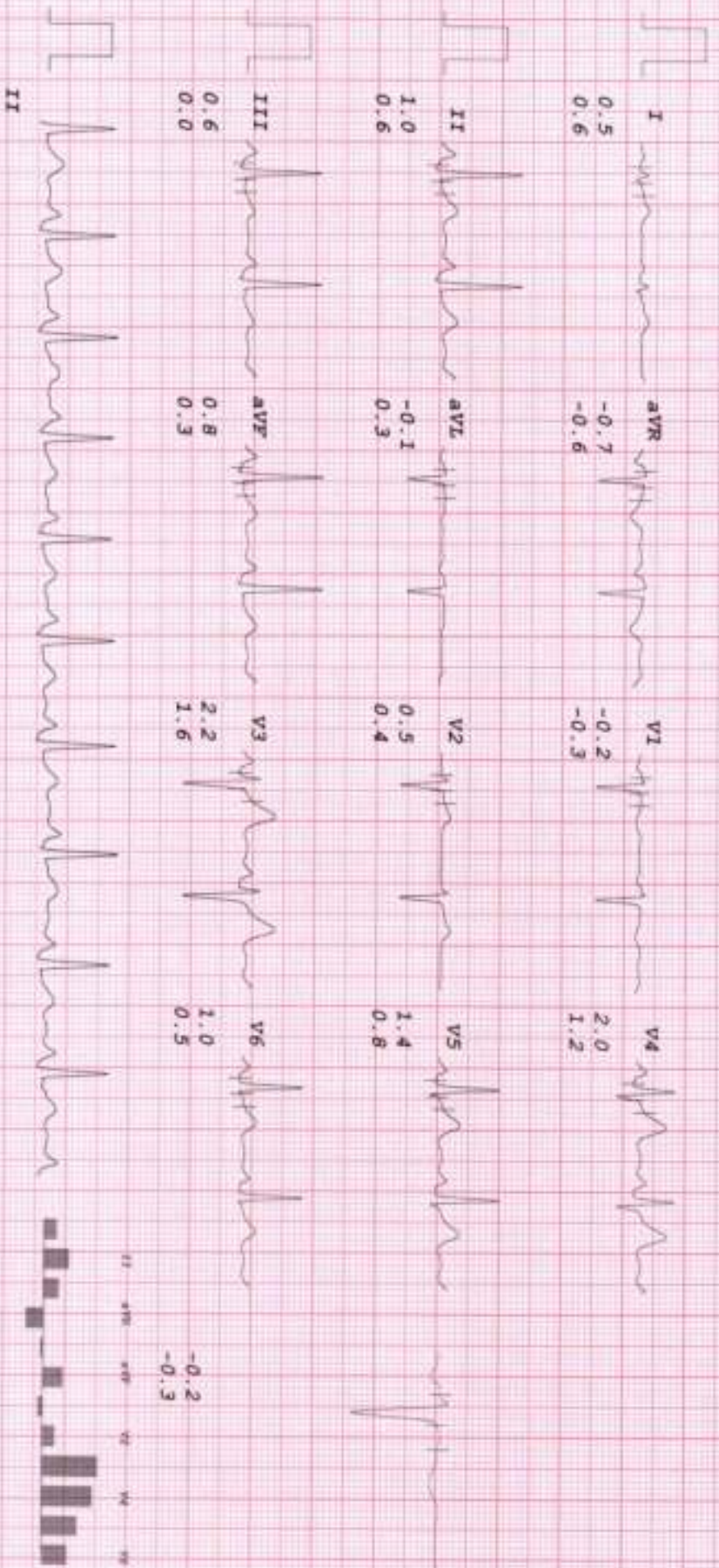
RATE 86bpm
B.P. 128/76

PRIEST
SUPINE

ST @ 10mm/mV
60ms PostU

LINKED MEDIAN

Mag. X 2



HEALTHCARE MEDICAL CENTRE & DIAGNOSTICS

MR. YASH BHATT
I.D. 653
Age 39/M
Date 03-02-2024

RATE 84bpm
B.P. 128/76

PRIEST
STANDING

ST @ 15mm/mV
8cms PostJ

LINKED MEDIAN

Mag. X 2

V1

I
0.5
0.3

avR
-0.7
-0.3

V1
-0.1
-0.1

V4
1.9
1.1

II
1.0
0.3

avL
0.0
0.2

V2
0.6
0.5

V5
1.4
0.7

III
0.5
0.0

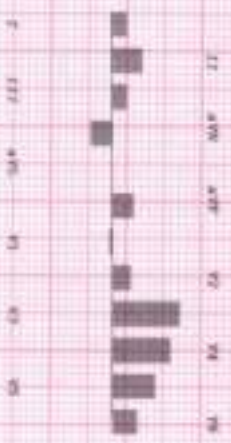avF
0.7
0.2

V3
2.2
1.6

V6
0.8
0.4

-0.1
-0.1

II



(Handwritten signature)

HEALTHCARE MEDICAL CENTRE & DIAGNOSTICS

MR YASH BHATT

I.D. 653

Age 39/M

Date 03-02-2024

RATE 84bpm

B.P. 128/76

PRETEST

HYPERVENT

PHASE TIME 0:06

ST @ 10mm/mV

80mm Paper

LINKED MEDIAN

Mag. X 2

V1

I
0.5
0.4

AVR
-0.7
-0.4

V1
-0.2
-0.2

V4
2.0
1.3

II
0.9
0.3

AVL
0.0
0.3

V2
0.6
0.5

V5
1.3
0.8

III
0.5
-0.1

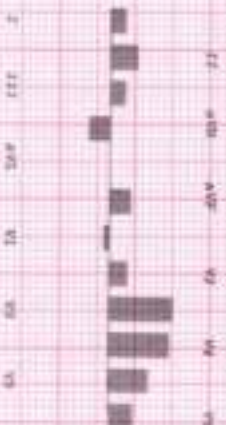AVF
0.7
0.1

V3
2.1
1.7

V6
0.8
0.3

-0.2
-0.2

II



YB

HEALTHCARE MEDICAL CENTRE & DIAGNOSTICS

MR. YASH BHATT
 I.D. 653
 Age 39/M
 Date 03-02-2024

RATE 108bpm
 B.P. 130/80

Brice
 Stage 1
 TOTAL TIME 2:55
 PHASE TIME 2:55

ST @ 10mm/mV
 80ms PostJ
 Speed 2.7 km/hr
 SLOPE 10 %

LINKED MEDIAN

Mag. X 2

I
 0.4
 0.3

AVR
 -0.5
 -0.4

V1
 -0.1
 0.1

V4
 1.7
 1.5

V1

II
 0.6
 0.5

AVL
 0.1
 0.1

V2
 0.6
 0.6

V5
 1.1
 0.9

III
 0.2
 0.2

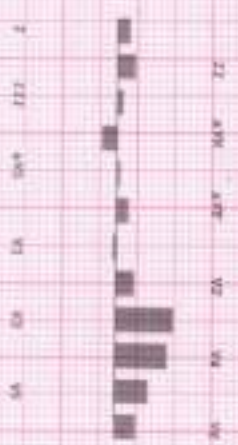
AVF
 0.4
 0.3

V3
 1.9
 1.9

V6
 0.7
 0.8

-0.1
 0.1

II



Handwritten signature

HEALTHCARE MEDICAL CENTRE & DIAGNOSTICS

MR YASH BHATT
I.D. 653
Age 59/M
Date 03-02-2024

RATE 127bpm
B.P. 140/90

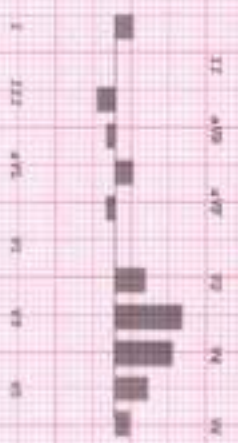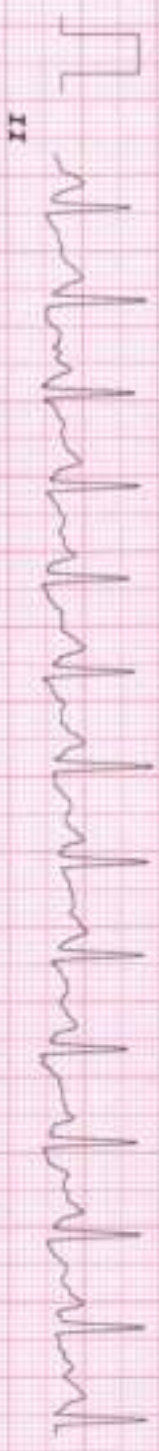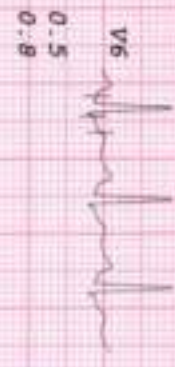
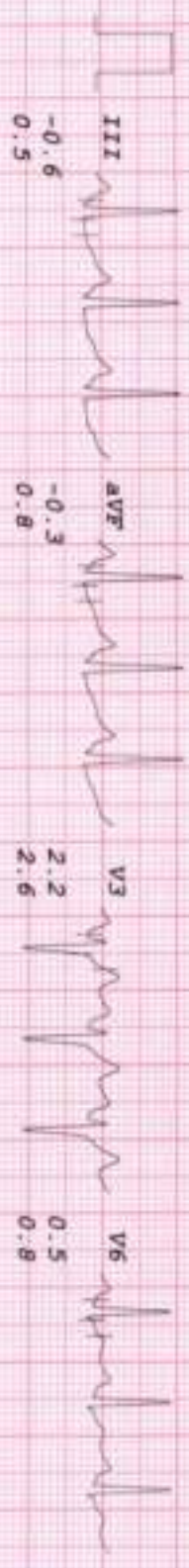
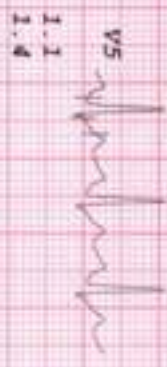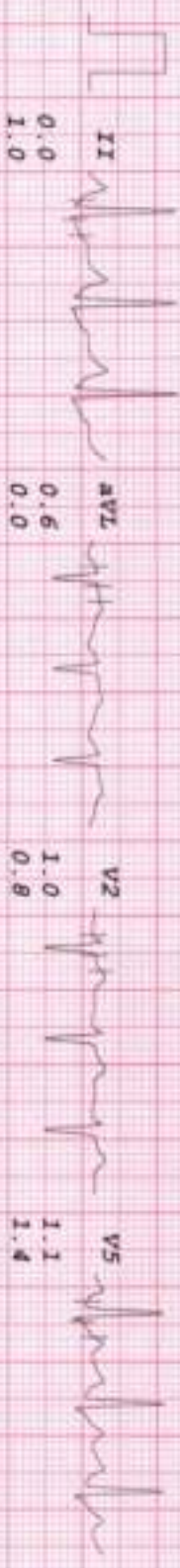
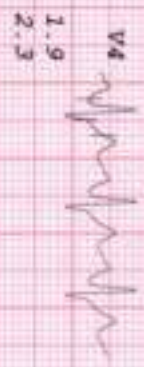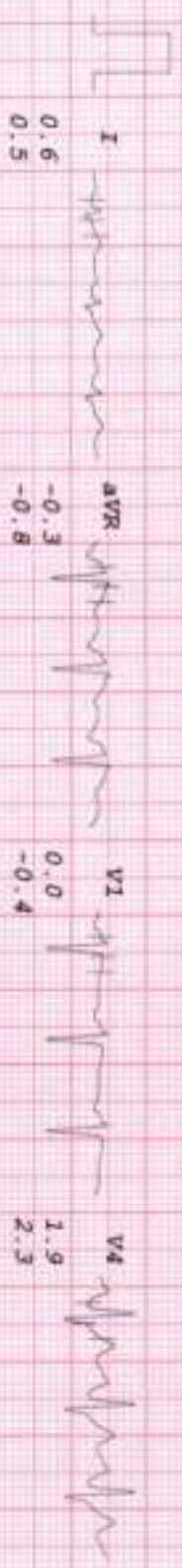
Bruce
Stage 2
TOTAL TIME 5:55
PHASE TIME 2:55

ST # 10mm/mV
80ms PostJ
Speed 4 km/hr
SLOPE 12 %

LINKED MEDIAN

Mag. X 2

III



YB

HEALTHCARE MEDICAL CENTRE & DIAGNOSTICS

MR YASH BHATT
 I.D. 653
 Age 39/M
 Date 03-02-2024

Rate 163bpm
 B.P. 150/100

Brice
 PK-EXERCISE
 TOTAL TIME 8:25
 PHASE TIME 2:25

ST @ 10mm/mv
 80ms PostJ
 Speed 5.4 km/hr
 SLOPE 14 %

LINKED MEDIAN

Mag. X 2

III

I
 0.8
 1.3

aVR
 -0.2
 -1.7

VI
 0.2
 -0.8

V4
 1.8
 3.4

II
 -0.3
 2.1

aVL
 1.0
 0.3

V2
 1.4
 0.7

V5
 1.0
 2.2

III
 -1.1
 0.8

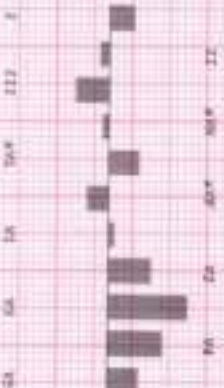
aVF
 -0.7
 1.4

V3
 2.6
 3.6

V6
 0.4
 2.0

-1.1
 0.8

II



(Handwritten signature)

HEALTHCARE MEDICAL CENTRE & DIAGNOSTICS

MR YASH BHATT
 I.D. 653
 Age 39/M
 Date 03-02-2024

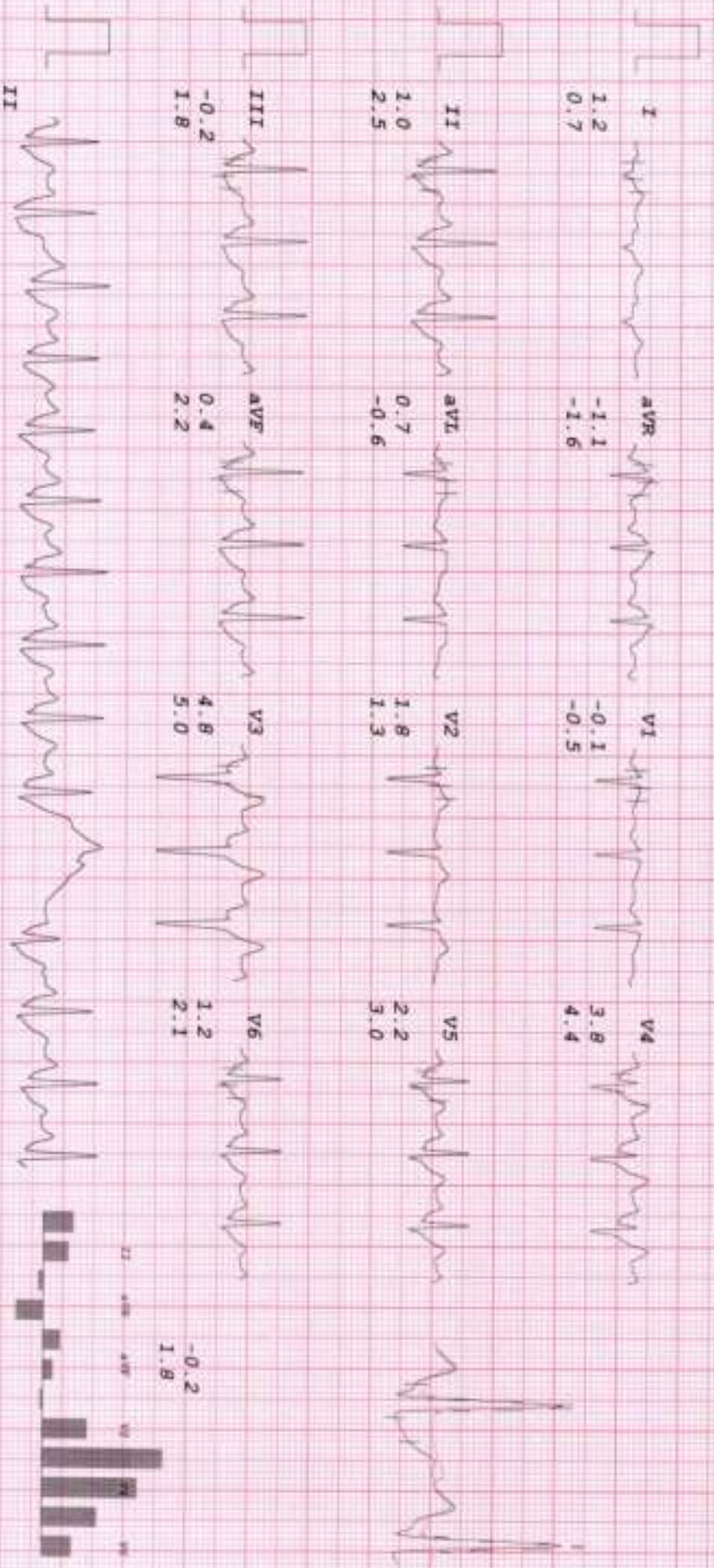
RATE 131bpm
 H.P. 140/90

HRUCE
 RECOVERY
 TOTAL TIME 9:36
 PHASE TIME 0:56

ST @ 10mm/mV
 80ms PQRST

RECOVERY 1
LINKED MEDIAN

Mag. X 2



Handwritten signature

HEALTHCARE MEDICAL CENTRE & DIAGNOSTICS

MR YASH BHATT
 I.D. 653
 Age 39/M
 Date 03-02-2024

RATE 115bpm
 R.P. 130/80

Brucce
 RECOVERY
 TOTAL TIME 10:40
 PHASE TIME 2:00

SF # 10mm/mV
 50ms PAST

RECOVERY 2
 LINKED MEDIAN

Mag. X 2

III

I
 0.8
 0.8

avR
 -0.4
 -1.3

V1
 0.3
 -0.4

V4
 2.5
 3.0

II
 0.1
 1.9

avL
 0.7
 -0.2

V2
 1.4
 0.9

V5
 1.2
 2.1

III
 -0.6
 1.1

avF
 -0.3
 1.5

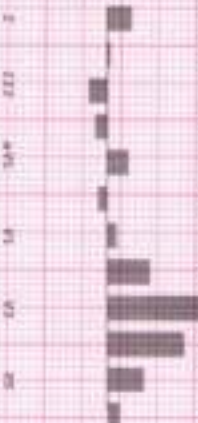
V3
 3.8
 3.7

V6
 0.4
 1.3

II

-0.6
 1.1

II avR avL V1 V2 V3 V4 V5 V6



Yash

HEALTHCARE MEDICAL CENTRE & DIAGNOSTICS

MR YASH BHATT
 I.D. 653
 Age 39/M
 Date 03-02-2024

RATE 108bpm
 B.P. 120/70

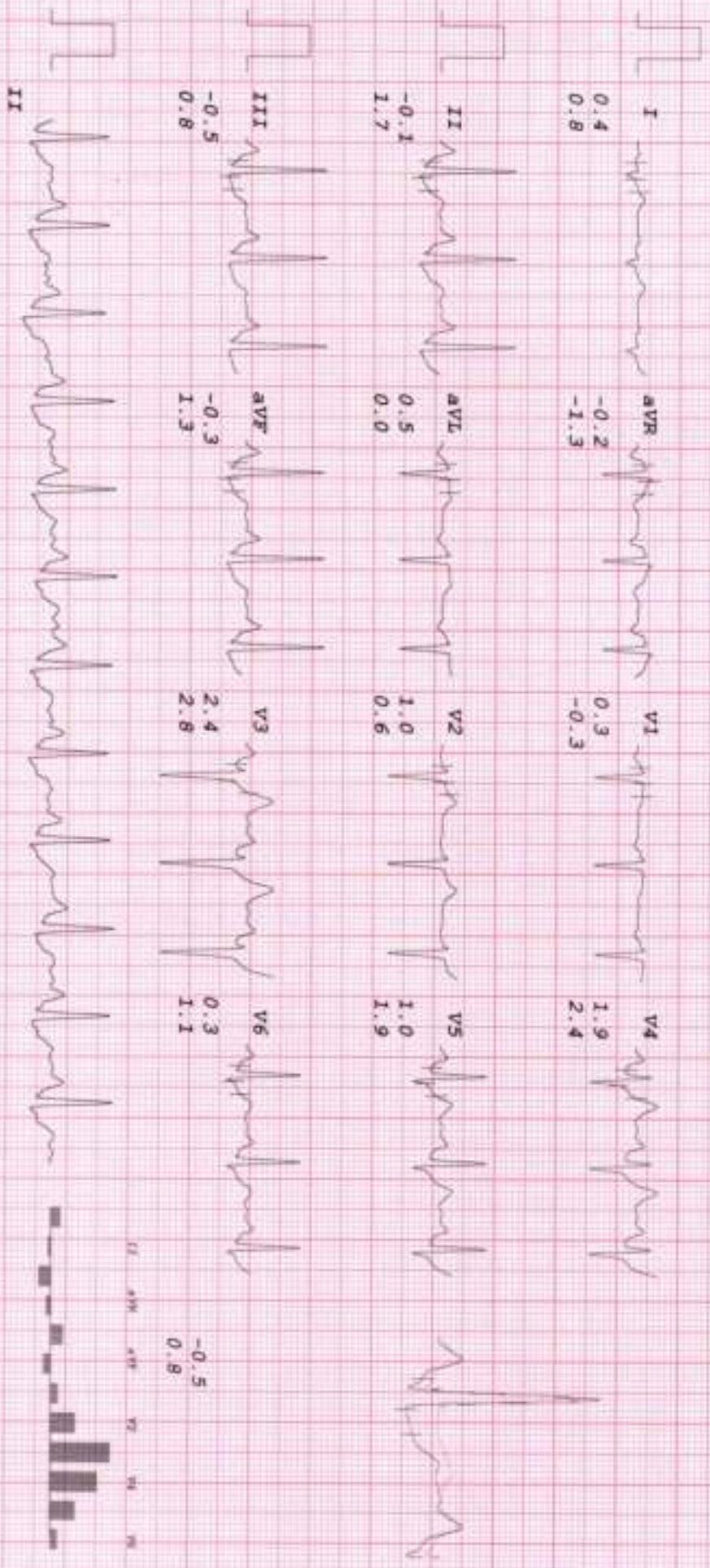
BRUCE
 RECOVERY
 TOTAL TIME 11:35
 PHASE TIME 2:55

ST @ 10mm/mV
 80ms PostJ

LINKED MEDIAN

Mag. X 2

III



Y.B.